



## Case report

# Chronic-Relapsing cutaneous leukocytoclastic vasculitis in a young patient with reduced EBV-specific T cell response using enzyme-linked immunospot (ELISPOT) assay successfully treated with Valaciclovir



Caterina Foti<sup>a,\*</sup>, Elvira Favoino<sup>b</sup>, Maria Scarasciulli<sup>c</sup>, Anna Maria Colacicco<sup>c</sup>, Hamidreza Jahantigh<sup>d</sup>, Angela Stufano<sup>d</sup>, Piero Lovreglio<sup>d</sup>, Paola Mascia<sup>a</sup>, Chiara Barlusconi<sup>a</sup>, Federico Perosa<sup>b</sup>, Paolo Romita<sup>a</sup>, Agata Calvario<sup>c</sup>

<sup>a</sup> Department of Biomedical Science and Human Oncology, Dermatological Clinic, University of Bari "Aldo Moro", Bari, Italy

<sup>b</sup> Department of Biomedical Science and Human Oncology (DIMO), Rheumatic and Systemic Autoimmune Diseases Unit, University of Bari Medical School, Bari, Italy

<sup>c</sup> Microbiology and Virology Unit - Interdisciplinary Department of Medicine (DIM) - University of Bari "Aldo Moro"- AOU Policlinico Bari, Italy

<sup>d</sup> Interdisciplinary Department of Medicine, University of Bari "Aldo Moro", 70124 Bari, Italy

## ARTICLE INFO

## Article history:

Received 16 September 2021

Received in revised form 3 November 2021

Accepted 4 November 2021

Available online xxxxx

## ABSTRACT

Among different pathogens, opportunistic viral infection caused by EBV is particularly relevant. This gammaherpesvirus, belonging to the Herpesviridae family, may complicate the disease course in different clinical settings by inducing pathological EBV pictures in patients with a defective immunologic response. Our report evaluated EBV-specific T cell responses by IFN- $\gamma$  ELISPOT assay, which revealed defective EBV specific immunological response.

© 2021 Published by Elsevier Ltd.  
CC-BY-NC-ND 4.0

## Introduction

Small vessel vasculitis (SVV) refers to inflammation in the walls of small vessels (arterioles and intra-parenchymal arteries, capillaries, and venules), but medium size arteries and veins may also be affected. In the wide and heterogeneous group of SVV, cutaneous leukocytoclastic vasculitides (CLV) refer to skin-limited SVV presenting palpable purpura, and/or nodular lesions [1]. CLV is idiopathic in 50% of cases while is associated to possible exogenous (drug, bacteria and/or viral infections) or endogeneous (neoplastic or connective diseases) neo antigens in the remaining cases. The prevalence of CLV in the caucasian population is reasonably low (approximately 20 cases per million annually) and patients of any age above 16 years can be affected, though impacting more grownups than youngsters [2] with slightly higher prevalence in women than men.

Palpable erythema and purpuric macules appear when superficial dermal vessels are affected whereas polymorphic lesions with palpable purpura, vesicular-bullous figures, ulcers, or nodules occur when deeper dermis and subcutaneous tissue are involved.

Histology shows up that the majority of CLV affects small vessels, predominantly venules, in 80% of cases [1], and is characterized by a

neutrophilic inflammatory infiltrate, which corresponds to the feature of LV. CLV belong to the group of hypersensitivity vasculitis inside the major group of small vessel vasculitides (SVV) (along with ANCA-associated).

Within hypersensitivity V group, cryoglobulinemic vasculitis (CV) is triggered by the precipitation of cryoglobulins in the vessels. Cryoglobulins are blood protein that clump together, precipitate and deposit on vascular endothelium when the serum is cooled and re-dissolve when the serum is warmed. Among this group, type III cryoglobulins (polyclonal IgM/IgG) are likely to be associated with rheumatologic disorders, subacute/chronic bacteria infections, protozoan infection and Epstein-Barr virus (EBV).

## Material and methods

## Case presentation

Our case describes a 18-year-old woman admitted to our hospital with a 5-year history of chronic-relapsing maculopapular purpuric lesions on the back of her hands. Her past medical history revealed a prior recovery in December 2017 where a skin biopsy suggested CLV. At that time autoimmunity screening (antinuclear antibody, ANA; antineutrophil cytoplasmic antibodies ANCA, and complement) was negative, while type III cryoglobulins (polyclonal IgGk) and elevated C-reactive protein were found. She assumed azathioprine (50 mg/

\* Corresponding author.

E-mail address: [caterina.foti@uniba.it](mailto:caterina.foti@uniba.it) (C. Foti).

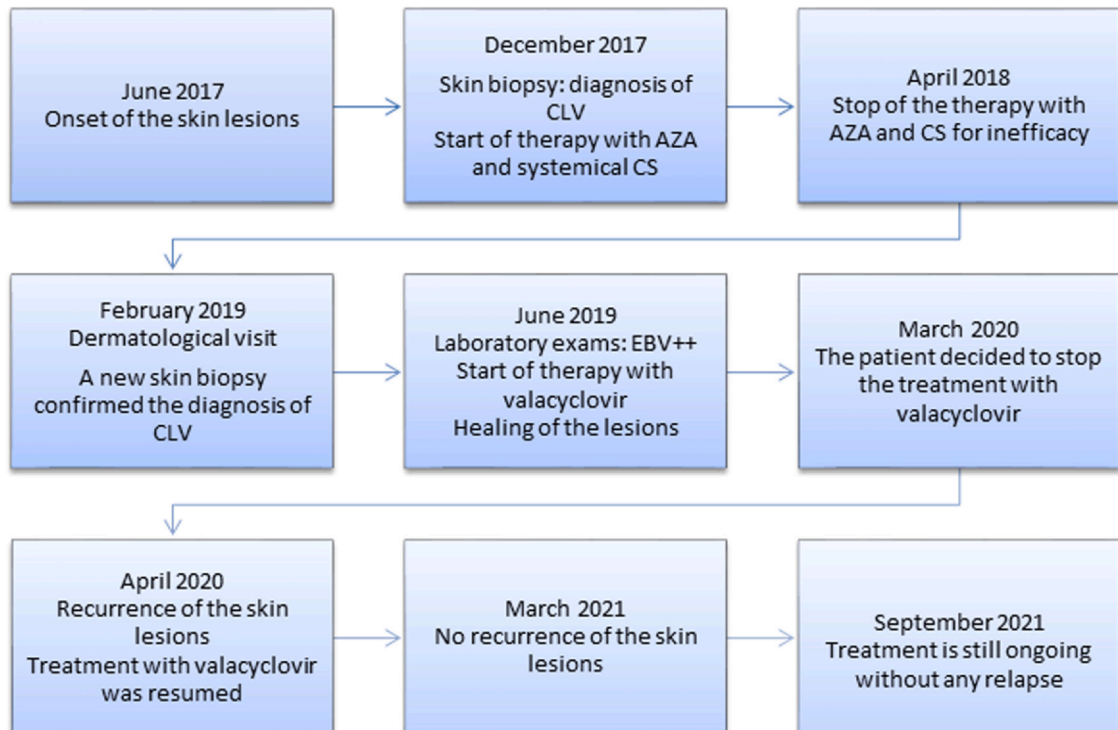
daily) and systemic corticosteroid (1 mgr/kg prednisone slowly tapered) for 1 year without a significant clinical response. Hence, the immunosuppressive treatment was interrupted because of inefficacy. She came to our attention three months after reporting a worsening of her skin lesions in February 2019. Physical examination

at this time revealed erythematous papular-purpuric lesions with the tendency to coalescence into flat-topped plaques localized on the back of the hands. Some of these showed targeted appearance with annular aspect and centrifugal evolution (Fig. 1). Lesions were not pruritic, but painful on palpation.

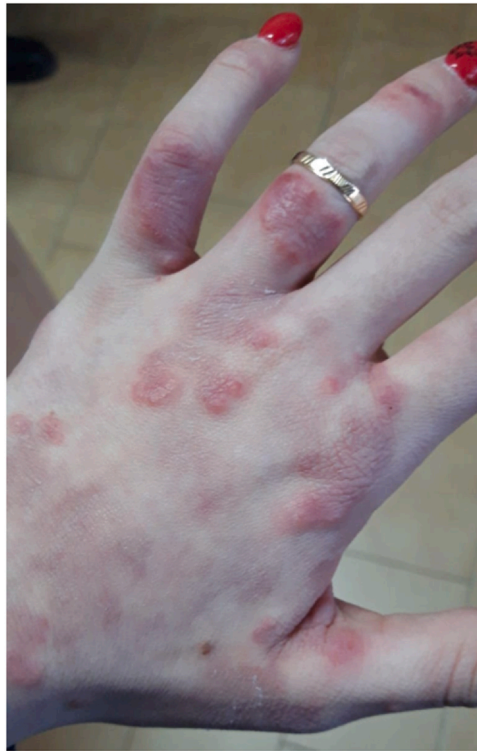

Fig. 1. Maculopapular purpuric lesions of the hands.

Time lapse of the clinical case



CLV: cutaneous leukocytoclastic vasculitides; AZA: azathioprine; CS: corticosteroid; EBV: Epstein-Barr Virus

## Laboratory test

Laboratory routine examinations including erythro-sedimentation rate, blood coagulation tests, C3, C4, ANA, anti-dsDNA, rheumatoid factor (RF), cANCA, pANCA, and other immunoglobulin levels, showed unremarkable findings. A type III cryoglobulins (polyclonal IgGk) was evidenced again. A new skin biopsy was performed, and histopathological findings described focal hyperkeratosis with accentuated granulocyte neutrophilic and eosinophilic infiltration, fibrinoid necrosis of the small vessels of the dermis with a “star-dust” appearance suggestive of cutaneous leukocytoclastic vasculitis.

Herpes viruses DNA extraction and purification from blood specimen collected using vacutainer K2 EDTA keeping the blood from clotting (whole blood) and from fresh skin biopsy was performed using the QIAAsymphony DSP DNA Mini Kit and automated DNA extraction Kit (Qiagen), according to the manufacturer's instructions.

Isolated DNA was amplified and quantified by Real-Time PCR based on Taqman® chemistry to detect DNA of all herpesviruses (mix and standard by ElitechGroup S.p.A Torino-Italy) using ABI PRISM 7500 Instrument (Applied Biosystems). More specifically, the region of EBNA-1 gene of EBV genome was amplified.

Serum IgM and IgG anti-EBV-VCA, and IgG anti-EBV-VCA and EBNA were evaluated using the fully automated chemiluminescence analyzer LIAISON® XL DiaSorin (Saluggia Italy). Then the differentiation of primary from secondary immune response was assessed in an avidity test using EBV-VCA automated MAGO® 4S analyzer according to the manufacturer's instructions.

Virus-specific T-cell response to lytic and latent EBV proteins was evaluated using a normalized enzyme-linked immunospot (ELISPOT) assay according to the manufacturer's instructions (Elispot Interferon- $\gamma$  Based Kit – AID, GmbH). In this assay, cells capable of immediate interferon- $\gamma$  (IFN- $\gamma$ ) secretion upon EBV antigen stimulation were counted as number of spot/well. The results were expressed with Stimulation Index ratio (SI) calculated as the mean number of spots in the sample well divided by the mean number of spots in the sample control well. The test was defined positive when SI was  $> 3$ , negative when SI was  $< 2$ , borderline when SI was between 2 and 3.

## Results

At the time of skin manifestations (Fig. 1), whole blood analysis revealed the presence of EBV-DNA ( $3.5 \times 10^2$  copies/mL), Human Herpes Virus (HHV) 6 DNA ( $1.7 \times 10^2$  copies/ mL), and HHV-7 DNA ( $2.4 \times 10^2$  copies/ mL). Biopsy specimen revealed EBV-DNA ( $1.8 \times 10^2$  copies/mcg), HHV-6 DNA (89 copies/mcg), HHV-7 DNA (20 copies/mcg).

EBV antibody research was positive for both VCA-IgM 160 U/ mL and VCA-IgG 69.2 U/mL (threshold:  $> 40$  U/ mL and  $> 20$  U/ mL, respectively) but negative for EBNA 1-IgG. The avidity test showed a high value  $> 64\%$  ( $> 60\%$  past infection).

The ELISPOT assay was defined as non-responders: SI were 1.05 and 1.4 for EBV Latent Antigen and EBV Lytic Antigen, respectively. Since we were describing a case of CLV associated with EBV chronic reactivation, we prescribed a treatment with Valaciclovir 1000 mg every 8 h continuously with a good clinical response.

## Discussion

Among different pathogens, opportunistic viral infection caused by EBV is particularly relevant [3]. This gammaherpesvirus, belonging to the Herpesviridae family, may complicate the disease course in different clinical settings [4–6] by inducing pathological EBV pictures in patients with a defective immunologic response. The

role of the immune system against this opportunistic infection is well known: T cell-mediated immunity as well as IFN- $\gamma$  playing a pivotal role, are crucial in the control of an infection [7]. IFN- $\gamma$  is a cytokine mainly produced by activated T helper 1(Th1) and T cytotoxic cells that have a central role in activating lymphocytes to enhance antimicrobial and antitumor effects in response to specific antigens. These effective immune responses bring the infection under control.

Therefore, EBV infection may result from a stimulant factor for immune and autoimmune reactions that may cause CLV as previously demonstrated [8–10]. Our report evaluated EBV-specific T cell responses by IFN- $\gamma$  ELISPOT assay, which revealed defective EBV specific immunological response. By using this new approach, we have provided a good estimation of both CD4+ and CD8+ antigen-specific T cell responses [11,12]. The loss of specific T-EBV response could be explained by a long inflammatory activation against low EBV viral load that may destroy, in the long run, the same T response. Although robust protective T cell responses, which help achieving complete viral clearance, are often elicited, exhausted T cell populations with reduced effector properties can emerge, especially during chronic infections [13,14]. Viral persistence is associated with the development of functionally inferior, exhausted T cell responses. Exhaustion develops in a stepwise and progressive manner, ranges in severity, and can culminate in the deletion of the anti-viral T cells [15]. This process has been known for long time [16].

The results of our serological and molecular analysis, suggested an EBV reactivation or persistence even in the presence of VCA IgG IgM positive test; in fact, primary infection named “infection mononucleosis syndrome” was characterized by a high viral load in whole blood ( $> 10.0000$  copies/mL) combined with a very low avidity value ( $< 40\%$  past infection) [17].

In our report, the viral load in whole blood was poor, and it presented low viremia caused probably by chronic B lymphocyte infection, the nest for EBV. In addition, the high avidity test value and the presence of the same viruses at a similar concentration in whole blood as well as in cutaneous biopsy may confirm a re-activation of viral persistence state.

These results agree with the intriguing hypothesis of the lack of EBV-specific T-cell response that can indicate the inability to arise the cellular response perhaps caused by exhausted T cell populations with reduced effector properties especially during chronic infections; so, the robust protective T cell responses, which help achieve complete viral clearance, are impaired [18,19].

Furthermore, the chronic EBV reactivation may have led to a secondary cryoglobulin type III production with subsequent typical acral vasculitis as an immune complex precipitation.

During the treatment with valaciclovir, we observed a good clinical response and skin lesions slowly disappeared. The patient reported a mild recurrence only when she suddenly decided to stop the treatment for about 1 month. Once the treatment was resumed, the skin lesions completely disappeared without any scar or secondary hyperpigmentation and with no clinical recurrence observed in 12 months follow-up and until today. The treatment is still ongoing.

In conclusion, based on this clinical findings, clinicians should always perform a broad viral panel, especially for HHVs, upon whole blood and skin biopsies in all cases of CV. Hence, it may be useful to investigate immunologic virus-specific response using ELISPOT assay, which should be considered in all cases of relapsing and recalcitrant forms of CLV, not responsive to standard immune-suppressive therapies. Furthermore, this innovative technique, providing new insight into the pathogenesis of virus-associated diseases, may help clinicians to identify patients with a defective immune-specific virus response that may benefit from different fitting therapies.

## References

- [1] Prete M, Indiveri F, Perosa F. Vasculitides: proposal for an integrated nomenclature. *Autoimmun Rev* 2016;15(2):167–73. (Feb).
- [2] Gyselbrecht L, De Keyser F, Ongenaes K, Naeyaert JM, Praet M, Veys EM. Etiological factors and underlying conditions in patients with leukocytoclastic vasculitis. *Clin Exp Rheumatol* 1996;14(6):665–8.
- [3] Houen G, Trier NH. Epstein-Barr virus and systemic autoimmune diseases. *Front Immunol* 2020;11.
- [4] Handous I, Achour B, Marzouk M, Rouis S, Hazgui O, Brini I, et al. Co-infections of human herpesviruses (CMV, HHV-6, HHV-7 and EBV) in non-transplant acute leukemia patients undergoing chemotherapy. *Virology* 2020;17(1):1–15.
- [5] Cohen JL. Primary immunodeficiencies associated with EBV disease. *Epstein Barr Virus* 2015;1:241–65.
- [6] Tangye SG, Palendira U, Edwards ES. Human immunity against EBV—lessons from the clinic. *J Exp Med* 2017;214(2):269–83.
- [7] Ohga S, Nomura A, Takada H, Hara T. Immunological aspects of Epstein-Barr virus infection. *Crit Rev Oncol/Hematol* 2002;44(3):203–15.
- [8] Karakayali B, Yilmaz S, Çakir D, Günes PG, Güven S, Islek I. Henoch-Schonlein purpura associated with primary active Epstein-Barr virus infection: a case report. *Pan Afr Med J* 2017;27(1):29.
- [9] Ranganath R, Pandey AR, Pavan M. Crescentic glomerulonephritis and leukocytoclastic vasculitis associated with acute EBV infection. *Nephrology* 2011;16(6):617. –617.
- [10] Kanai K, Kuwabara S, Mori M, Arai K, Yamamoto T, Hattori T. Leukocytoclastic-vasculitic neuropathy associated with chronic Epstein-Barr virus infection. *Muscle Nerve J Am Assoc Electrodiagn Med* 2003;27(1):113–6.
- [11] Yang J, Lemas VM, Flinn IW, Krone C, Ambinder RF. Application of the ELISPOT assay to the characterization of CD8+ responses to Epstein-Barr virus antigens. *Blood J Am Soc Hematol* 2000;95(1):241–8.
- [12] Calarota SA, Baldanti F. Enumeration and characterization of human memory T cells by enzyme-linked immunospot assays. *Clin Dev Immunol* 2013;2013:637649.
- [13] Kahan SM, Wherry EJ, Zajac AJ. T cell exhaustion during persistent viral infections. *Virology* 2015;479–480:180–93. <https://doi.org/10.1016/j.virol.2014.12.033>. (May).
- [14] Zajac AJ, Murali-Krishna K, Blattman JN, Ahmed R. Therapeutic vaccination against chronic viral infection: the importance of cooperation between CD4+ and CD8+ T cells. *Curr Opin Immunol* 1998;10(4):444–9.
- [15] Klenerman P, Hill A. T cells and viral persistence: lessons from diverse infections. *Nat Immunol* 2005;6(9):873–9.
- [16] Ambinder RF, Lin L. Mononucleosis in the laboratory. *J Infect Dis* 2005;192(9):1503–4.
- [17] Balfour Jr. HH, Holman CJ, 1 Hokanson KM, Lelonek MM, Giesbrecht JE, White DR, et al. A prospective clinical study of Epstein-Barr virus and host interactions during acute infectious mononucleosis. *J Infect Dis* 2005;192:1505–12.
- [18] Cavanagh MM, Qi Q, Weyand CM, Goronzy JJ. Finding balance: T cell regulatory receptor expression during aging. *Aging Dis* 2011;2(5):398–413.
- [19] Yi JS, Cox MA, Zajac AJ. T-cell exhaustion: characteristics, causes and conversion. *Immunology* 2010;129(4):474–81.