



# Impact of the Liver Imaging Reporting and Data System on Research Studies of Diagnosing Hepatocellular Carcinoma Using MRI

Yura Ahn<sup>1</sup>, Sang Hyun Choi<sup>1</sup>, Jong Keon Jang<sup>1</sup>, So Yeon Kim<sup>1</sup>, Ju Hyun Shim<sup>2</sup>,  
Seung Soo Lee<sup>1</sup>, Jae Ho Byun<sup>1</sup>

<sup>1</sup>Department of Radiology and Research Institute of Radiology, University of Ulsan College of Medicine, Asan Medical Center, Seoul, Korea;

<sup>2</sup>Department of Gastroenterology, Liver Center, University of Ulsan College of Medicine, Asan Medical Center, Seoul, Korea

**Objective:** Since its introduction in 2011, the CT/MRI diagnostic Liver Imaging Reporting and Data System (LI-RADS) has been updated in 2014, 2017, and 2018. We evaluated the impact of CT/MRI diagnostic LI-RADS on liver MRI research methodology for the diagnosis of hepatocellular carcinoma (HCC).

**Materials and Methods:** The MEDLINE, EMBASE, and Cochrane databases were searched for original articles reporting the diagnostic performance of liver MRI for HCC between 2011 and 2019. The MRI techniques, image analysis methods, and diagnostic criteria for HCC used in each study were investigated. The studies were classified into three groups according to the year of publication (2011–2013, 2014–2016, and 2017–2019). We compared the percentage of studies adopting MRI techniques recommended by LI-RADS, image analysis methods in accordance with the lexicon defined in LI-RADS, and diagnostic criteria endorsed by LI-RADS. We compared the pooled sensitivity and specificity between studies that used the LI-RADS and those that did not.

**Results:** This systematic review included 179 studies. The percentages of studies using imaging techniques recommended by LI-RADS were 77.8% for 2011–2013, 85.7% for 2014–2016, and 84.2% for 2017–2019, with no significant difference ( $p = 0.951$ ). After the introduction of LI-RADS, the percentages of studies following the LI-RADS lexicon were 0.0%, 18.4%, and 56.6% in the respective periods ( $p < 0.001$ ), while the percentages of studies using the LI-RADS diagnostic imaging criteria were 0.0%, 22.9%, and 60.7%, respectively ( $p < 0.001$ ). Studies that did not use the LI-RADS and those that used the LI-RADS version 2018 showed no significant difference in sensitivity and specificity (86.3% vs. 77.7%,  $p = 0.102$  and 91.4% vs. 89.9%,  $p = 0.770$ , respectively), with some difference in heterogeneity ( $I^2 = 94.3\%$  vs. 86.7% in sensitivity and  $I^2 = 86.6\%$  vs. 53.2% in specificity).

**Conclusion:** LI-RADS imparted significant changes in the image analysis methods and diagnostic criteria used in liver MRI research for the diagnosis of HCC.

**Keywords:** Liver; Hepatocellular carcinoma; Magnetic resonance imaging; Liver imaging reporting and data system; Systematic review

## INTRODUCTION

Hepatocellular carcinoma (HCC) is the third most common cause of cancer-related death worldwide and the most common primary hepatic malignancy [1]. Unlike most other

cancers, HCC can be diagnosed using imaging characteristics without mandatory pathologic confirmation, and accurate imaging diagnosis of HCC is crucial in the management of patients with HCC.

Before the implementation of the Liver Imaging

**Received:** February 12, 2021 **Revised:** November 22, 2021 **Accepted:** December 8, 2021

**Corresponding author:** Sang Hyun Choi, MD, PhD, Department of Radiology and Research Institute of Radiology, University of Ulsan College of Medicine, Asan Medical Center, 88 Olympic-ro 43-gil, Songpa-gu, Seoul 05505, Korea.

• E-mail: edwardchoi83@gmail.com

This is an Open Access article distributed under the terms of the Creative Commons Attribution Non-Commercial License (<https://creativecommons.org/licenses/by-nc/4.0>) which permits unrestricted non-commercial use, distribution, and reproduction in any medium, provided the original work is properly cited.

Reporting and Data System (LI-RADS), the diagnostic imaging criteria for HCC were not clearly defined, and there was a risk of subjective analysis of imaging findings, such as the possibility of disagreement between readers regarding the presence of arterial-phase hyperenhancement [2,3]. Therefore, to overcome these limitations and standardize the imaging diagnosis of HCC, CT/MRI LI-RADS was introduced in 2011 [2]. This system was later updated in 2014 by adopting the use of hepatobiliary agents [4], in 2017, by refining the diagnostic criteria [5], and in 2018, by unifying with the American Association for the Study of Liver Disease (AASLD) 2018 HCC clinical practice guidance [6]. CT/MRI diagnostic LI-RADS provides a comprehensive lexicon with definitions for all imaging features, an algorithm for the diagnosis of definite HCC, an ordinal approach to risk stratification for each observation according to the probability of HCC (i.e., LR-1 to LR-5), and guidance for imaging acquisition and management [7].

Since its introduction, many studies have adopted the CT/MRI diagnostic LI-RADS [8-11]. Therefore, we sought to investigate the changes that the LI-RADS imparted in terms of the study methodology.

Liver MRI is increasingly used for the evaluation of HCC, as it enhances lesion detection as well as lesion characterization. Compared to the relatively simple image characteristics on CT, MRI provides more comprehensive information from multiparametric MRI sequences [10,12]. Given the complexity of MRI analysis, we assumed that the LI-RADS would exert considerable effects on the way that MRI studies were performed. Therefore, we aimed to evaluate the impact of CT/MRI diagnostic LI-RADS on research methodology using liver MRI for the diagnosis of HCC in at-risk patients.

## MATERIALS AND METHODS

This study was reported in accordance with the Preferred Reporting Items for Systematic Review and Meta-analysis of Diagnostic Test Accuracy Studies [13].

### Literature Search Strategy

A systematic literature search of MEDLINE, EMBASE, and Cochrane databases was performed to identify original articles reporting the performance of liver MRI for the diagnosis of HCC. The search query was developed to provide a sensitive literature search to avoid missing relevant articles. The search terms included "Hepatocellular

carcinoma," "Magnetic resonance imaging," "Diagnosis," and "Differential diagnosis." The search terms are described in detail in Supplementary Table 1. The literature search was limited to studies published in the English language from January 1, 2011, to December 31, 2019, with consideration of the dates for the introduction and updating of the LI-RADS.

### Inclusion and Exclusion Criteria

After removal of duplicates, the articles were reviewed according to eligibility: 1) population: patients at risk of HCC with focal observations, 2) index test: liver MRI for HCC diagnosis, 3) reference standard: pathologic diagnosis or imaging follow-up, and 4) study design: observational studies (prospective or retrospective) and clinical trials. We included studies that only enrolled the LI-RADS target population and those that enrolled an extended LI-RADS target population, such as patients with chronic hepatitis C without cirrhosis. Studies investigating the diagnosis of HCC included those reporting the differential diagnosis of HCC from other tumors, as well as those performing evaluations for diagnostic purposes. The exclusion criteria were as follows: 1) animal studies, case reports, review articles, and scientific abstracts and 2) studies that were not within the field of interest of this study. Articles were first screened by their titles and abstracts, and full-text reviews were performed following the selection of potentially eligible abstracts. Both steps were performed by two independent reviewers who eliminated only those articles that were clearly ineligible. Articles with any degree of ambiguity or those that generated differences in opinion between the two independent reviewers were re-evaluated at a consensus meeting with a third reviewer.

### Data Extraction

The following data were extracted from the selected studies onto a predefined data form: 1) study characteristics, including authors, year of publication, journal, institution, study design (prospective versus retrospective), and study type (cohort study versus case-control study), 2) subject characteristics, including age, sex, and the number of patients and lesions, 3) MRI techniques, including magnetic field strength, imaging sequences, and contrast agents, 4) imaging analysis methods, including imaging review, definition of major features (non-rim arterial-phase hyperenhancement [APHE], non-peripheral washout, and enhancing capsule), and use of the LI-

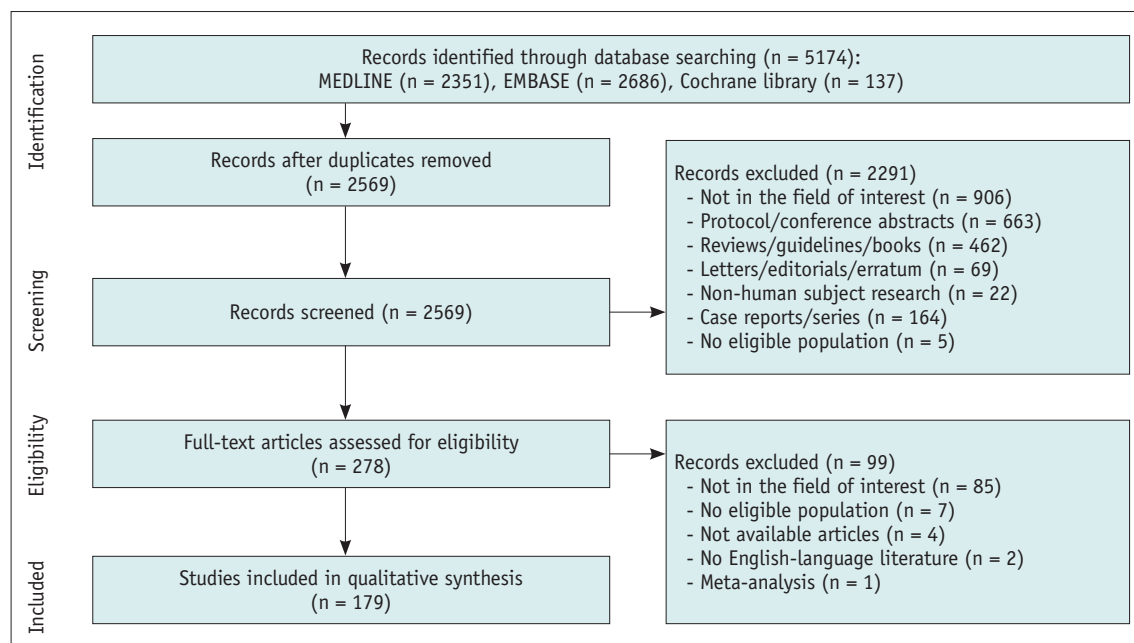
RADS lexicon, and 5) diagnostic imaging criteria (AASLD, European Association for the Study of Liver [EASL], LI-RADS, the Organ Procurement and Transplantation Network [OPTN], Korean Liver Cancer Association-National Cancer Center [KLCA-NCC], or the National Comprehensive Cancer Network [NCCN]). To determine diagnostic performance (per-lesion sensitivity and specificity), the number of true positives, true negatives, false positives, and false negatives for HCC were extracted. Data were extracted by two independent reviewers, with a consensus meeting held in the presence of a third reviewer to discuss all discrepancies.

### Outcome Measurement and Statistical Analysis

To evaluate changes in the research methodology of liver MRI for diagnosing HCC after the introduction of LI-RADS, the MRI techniques, image analysis methods, and diagnostic imaging criteria for HCC were investigated for each individual study. The studies were classified into three groups according to the year of publication (2011–2013, 2014–2016, and 2017–2019), and the chi-square test was used to perform between-group comparisons of the percentages of studies using the imaging techniques recommended by the LI-RADS (unenhanced T1-weighted out-of-phase/in-phase imaging, T2-weighted imaging, multiphase T1-weighted imaging including precontrast, arterial, portal venous, and delayed phases with extracellular contrast agent or gadobenate dimeglumine

and precontrast, arterial, portal venous, transitional, and hepatobiliary phases with hepatobiliary contrast agent), the percentages of studies using image analysis methods in accordance with the terms of the lexicon defined in the LI-RADS (non-rim APHE, non-peripheral washout, and enhancing capsule), and the percentages of studies using diagnostic imaging criteria endorsed by the LI-RADS. Additionally, the chi-square test was used to perform between-group comparisons of the percentages of studies using their own pre-specified definition of major features, their own diagnostic imaging criteria, and with unclear criteria. For these studies, we further investigated how they defined the major features for diagnosing HCC and how they made an imaging diagnosis of HCC.

To evaluate the clinical impact of the use of LI-RADS, we compared the study characteristics, including study design, study type, geographic distribution, journal field, and the Journal Citation Reports 2020 impact factor for the publishing journals between studies that used the LI-RADS lexicon and those that did not. Study quality was evaluated using the Quality Assessment of Diagnostic Accuracy Studies 2 (QUADAS-2) criteria. Additionally, we used a bivariate random effects model to calculate the meta-analytic pooled per-lesion sensitivity and specificity of studies that used the LI-RADS lexicon diagnostic imaging criteria for HCC and those that did not. These summary estimates were calculated using the LI-RADS version.



**Fig. 1. Flow diagram of the article selection process.** An article may have been excluded for multiple reasons, but only one major reason per article is presented.

## RESULTS

### Literature Search

A total of 2569 studies were screened after the removal of duplicate articles (Fig. 1). Of these, 2291 studies were excluded based on their titles and abstracts, and 99 studies were excluded after full-text reviews. Ultimately, 179 studies were included in this study. A summary of the included studies is provided in Supplementary Table 2.

### Characteristics of the Included Studies

The characteristics of the 179 included studies are summarized in Table 1. Of the 179 studies, 144 (80.4%) reported the performance of liver MRI for diagnosing HCC, and 35 (19.6%) reported the differential diagnosis of HCC

**Table 1. Study Characteristic of the 179 Included Studies**

Variables	No. of Articles (%)
<b>Main outcome</b>	
Diagnostic performance of liver MRI	144 (80.4)
Differential diagnosis of HCC from other tumor	35 (19.6)
<b>Study design</b>	
Prospective	36 (20.1)
Retrospective	143 (79.9)
<b>Study type</b>	
Cohort study	166 (92.7)
Case-control study	13 (7.3)
<b>Year of publication</b>	
2011	19 (10.6)
2012	17 (9.5)
2013	18 (10.1)
2014	11 (6.1)
2015	14 (7.8)
2016	24 (13.4)
2017	23 (12.8)
2018	24 (13.4)
2019	29 (16.2)
<b>Geographic distribution</b>	
North America	25 (14.0)
Europe	36 (20.1)
Asia	115 (64.2)
Others*	3 (1.7)
<b>Journal field</b>	
Radiology/imaging journal	127 (70.9)
Gastroenterology/hepatology journal	30 (16.8)
Others <sup>†</sup>	22 (12.3)

\*Others includes Australia and Egypt, <sup>†</sup>Others includes internal medicine, oncology, and surgery journals. HCC = hepatocellular carcinoma

from other tumors. Thirty-six (20.1%) of the included studies were prospective studies and 143 (79.9%) were retrospective studies. One hundred and ten (61.5%) studies included only the LI-RADS target population as study subjects, whereas 69 (38.5%) included an extended LI-RADS target population. Fifty-four (30.2%) studies were published between 2011 and 2013, 49 (27.4%) between 2014 and 2016, and 76 (42.5%) between 2017 and 2019. Most studies were conducted in Asia (n = 115, 64.2%), followed by Europe (n = 36, 20.1%), and North America (n = 25, 14.0%).

### Imaging Technique for Liver MRI

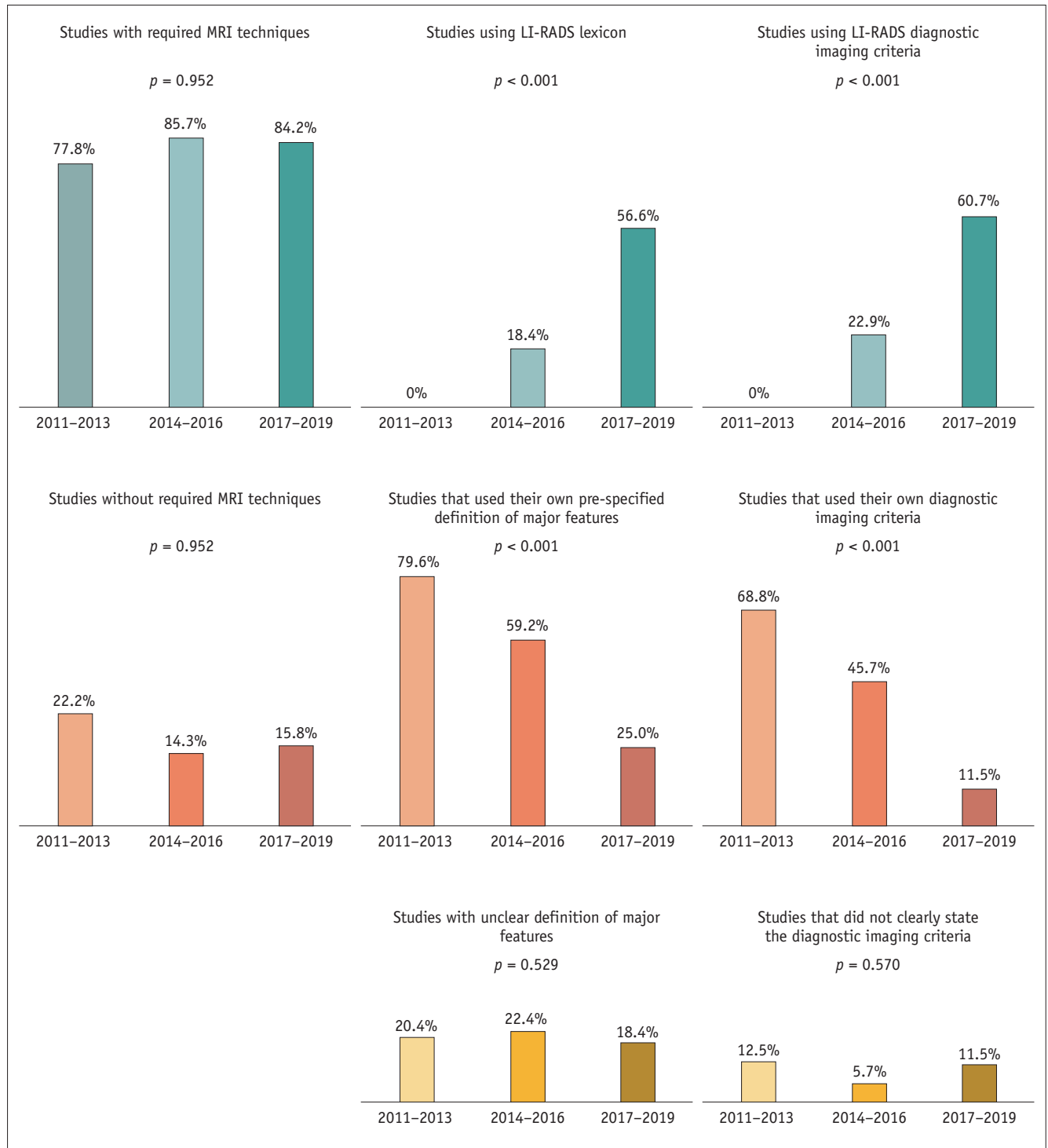
Of the 179 studies, 1.5T MRI was used in 71 (39.7%), 3T MRI in 58 (32.4%), and both 1.5T and 3T MRI in 44 (24.6%). The remaining six studies used MRI of less than 1.5T or did not state the magnetic field strength. Regarding the contrast agent, 36 studies (20.1%) used extracellular contrast agents, 114 (63.7%) used hepatobiliary contrast agent, 7 (3.9%) used both contrast agents, and 18 (10.1%) used gadobenate dimeglumine. Two studies did not perform contrast-enhanced MRI, and two studies did not clearly state whether contrast was used.

The percentage of studies with all the required image sequences recommended by the LI-RADS was 82.7% (n = 148). The percentage of studies with all required image sequences was not significantly different across the three groups: 77.8% during 2011–2013, 85.7% during 2014–2016, and 84.2% during 2017–2019 (p = 0.951) (Fig. 2). Among the 31 studies without all the required image sequences recommended by the LI-RADS, unenhanced T1-weighted out-of-phase/in-phase imaging was the sequence most frequently absent or not clearly stated. Supplementary imaging was performed using diffusion-weighted imaging in 117 (65.4%) studies and arterial subtraction images in 21 (11.7%) studies.

### Imaging Analysis of Liver MRI

In the 179 studies, imaging analysis was performed by multiple independent reading (n = 63, 35.2%), multiple consensus reading (n = 96, 53.6%), and single reading (n = 18, 10.1%). Two studies did not provide clear details on how the imaging reading was performed.

The percentage of studies using the LI-RADS lexicon was 29.1% (n = 52) between 2011 and 2019. After the introduction of LI-RADS, the percentage of studies using the LI-RADS lexicon gradually increased over time, from



**Fig. 2. Graphs showing the research methodology across the study period.** The percentage of studies using the LI-RADS recommended MRI techniques was not significantly different across the study period, whereas the percentages of studies using the LI-RADS lexicon and studies using LI-RADS as diagnostic imaging criteria gradually increased. LI-RADS = Liver Imaging Reporting and Data System

0% (0/54) during 2011–2013 to 18.4% (9/49) during 2014–2016, and 56.6% (43/76) during 2017–2019 ( $p < 0.001$ ) (Fig. 2). Regarding the LI-RADS version used, 50.0% (26/52) of studies used v2014, 21.2% (11/52) used v2017,

and 17.3% (9/52) used v2018. In contrast, the percentage of studies that did not use the LI-RADS lexicon, but instead used their own pre-specified definition of major features, gradually decreased over time, from 79.6% (43/54) during

2011–2013 to 59.2% (29/49) during 2014–2016, and 25.0% (19/76) during 2017–2019 ( $p < 0.001$ ) (Fig. 2). The definitions of the major features used in the 91 studies with their own pre-specified major features are summarized in Table 2. Of these 91 studies, 70 (76.9%) used ‘non-rim APHE,’ without clarifying that the lesion signal intensity was compared with normal liver parenchyma or without identifying ‘non-rim,’ and 58 (63.7%) studies used ‘non-peripheral washout,’ without clarifying that the lesion signal intensity was compared with normal liver parenchyma, without identifying ‘non-peripheral,’ or without visually

assessing temporal reduction. The remaining 36 studies performed imaging analysis without pre-specifying the definition of major features, such as evaluation of the signal intensity of each imaging sequence or enhancement pattern. The percentage of studies with unclear definitions of major features was 20.4% (11/54) during 2011–2013, 22.4% (11/49) during 2014–2016, and 18.4% (14/76) during 2017–2019 ( $p = 0.529$ ) (Fig. 2).

### Diagnostic Imaging Criteria for HCC

The diagnostic imaging criteria for HCC were evaluated

**Table 2. The Definition of Major Features in the 91 Studies with Their Own Pre-Specified Major Features**

	Pre-Specified Definition	No. of Studies (%)
Non-rim APHE	Arterial hyperenhancement or hypervascularity	8 (8.8)
	- Comparison with liver parenchyma	
	- No specific enhancing area mentioned, i.e., non-rim-like enhancement	
	Arterial hyperenhancement using the subtraction image, or higher lesion intensity on arterial-phase than on pre-contrast image	6 (6.6)
	- No specific enhancing area mentioned, i.e., non-rim-like enhancement	
Peaks of contrast enhancement on arterial-phase or wash-in		6 (6.6)
	- No comparison with liver parenchyma	
Hyperenhancement or hypervascularity on arterial-phase		70 (76.9)
	- No comparison with liver parenchyma	
	- No specific enhancing area mentioned, i.e., non-rim-like enhancement	
NA		1 (1.1)
Nonperipheral washout	Hypointensity compared with surrounding liver parenchyma on PV or EP (TP)	18 (19.8)
	- No specific hypointensity area mentioned, i.e., nonperipheral	
	- No visually-assessed temporal reduction	
	Hypointensity compared with liver parenchyma	1 (1.1)
	- No specific dynamic phase mentioned	
	- No specific hypointensity area mentioned, i.e., nonperipheral	
	- No visually-assessed temporal reduction	
	Hypointensity/washout on PV or EP (TP)	58 (63.7)
	- No comparison with liver parenchyma	
	- No specific hypointensity area mentioned, i.e., nonperipheral	
- No visually-assessed temporal reduction		
No specific dynamic phase mentioned		11 (12.1)
	No comparison with liver parenchyma	
	No specific hypointensity area mentioned, i.e., nonperipheral	
	No visually-assessed temporal reduction	
	NA	3 (3.3)
Enhancing capsule	Peripheral rim enhancement on PV or EP (TP)	15 (16.5)
	Peripheral rim enhancement, but no specific dynamic phase mentioned	1 (1.1)
	No specific definition of enhancing capsule	13 (14.3)
	No specific dynamic phase mentioned	
	NA	62 (68.1)

APHE = arterial-phase hyperenhancement, EP = equilibrium-phase, NA = not available, PV = portal venous-phase, TP = transitional-phase

in 144 studies that reported the performance of liver MRI. Of these 144 studies, 73 (50.7%) used diagnostic imaging criteria for HCC endorsed by the international guidelines, including LI-RADS (n = 42); AASLD 2010 (n = 17); both AASLD 2010 and EASL 2012 (n = 3); both LI-RADS and AASLD 2010 or EASL 2012 or EASL 2018 (n = 3); EASL 2018 (n = 2); EASL 2012 (n = 1); both AASLD 2010 and AASLD 2005 (n = 1); AASLD 2005 and EASL 2001 (n = 1); AASLD 2005 (n = 1); and OPTN (n = 1). The remaining study compared four diagnostic imaging criteria: AASLD 2005, EASL 2001, KLCA-NCC 2009, and NCCN 2009.

The percentage of studies using LI-RADS as diagnostic imaging criteria was 28.6% (6/21) in North America, 24.2% (8/33) in Europe, and 33.7% (29/86) in Asia. The LI-RADS was used as the diagnostic imaging criteria in 36.7% (36/98) of articles published in radiology/imaging journals and 18.5% (5/27) published in gastroenterology/hepatology journals. The percentage of all included studies using LI-RADS diagnostic imaging criteria for HCC was 31.3% (n = 45) between 2011 and 2019. After the introduction of the LI-RADS, the percentage gradually increased over time as follows: 0% (0/48) during 2011–2013, 22.9% (8/35) during 2014–2016, and 60.7% (37/61) during 2017–2019 ( $p < 0.001$ ) (Fig. 2). These temporal changes were also noted in each region, i.e., 0% (0/8) during 2011–2013, 33.3% (2/6) during 2014–2016, and 57.1% (4/7) during 2017–2019 in North America, 0% (0/11) during 2011–2013, 28.6% (2/7) during 2014–2016, and 40.0% (6/15) during 2017–2019 in Europe, 0% (0/28) during 2011–2013, 18.2% (4/22) during 2014–2016, and 69.4% (25/36) during 2017–2019 in Asia. In North America, 33.3% of studies used the LI-RADS during 2014–2016, which was the highest percentage, while more than 50% of the studies in both North America

and Asia used the LI-RADS during 2017–2019. Europe showed a gradually increasing percentage of studies using the LI-RADS between 2011 and 2019, reaching 40.0% between 2017 and 2019. Among the three studies from other regions (i.e., Egypt and Australia), only one study published in Egypt in 2018 used the LI-RADS. Regarding the LI-RADS version used, 48.9% (22/45) of studies used v2014, 17.8% (8/45) used v2017, and 20.0% (9/45) used v2018. In contrast, the percentage of studies that did not use diagnostic imaging criteria endorsed by the international guidelines, but instead used their own diagnostic imaging criteria (i.e., modified AASLD/EASL/LI-RADS), showed a gradual significant decrease over time as follows: 68.8% (33/48) during 2011–2013, 45.7% (16/35) during 2014–2016, and 11.5% (7/61) during 2017–2019 ( $p < 0.001$ ) (Fig. 2). The detailed results of the 56 studies that used their own diagnostic imaging criteria are summarized in Table 3. Of these 56 studies, 18 (32.1%) applied washout in the portal venous or equilibrium/transitional-phase with other ancillary features, and ten (17.9%) applied washout in the portal venous, equilibrium/transitional, or hepatobiliary-phase. The remaining 15 studies were unclear regarding how the imaging diagnosis of HCC was made. The percentage of studies that did not clearly state the diagnostic imaging criteria was 12.5% (6/48) during 2011–2013, 5.7% (2/35) during 2014–2016, and 11.5% (7/61) during 2017–2019 ( $p = 0.570$ ) (Fig. 2).

### Clinical Impact of the Use of LI-RADS

Of the 179 studies, 52 used the LI-RADS lexicon and 127 did not. Studies that used the LI-RADS lexicon were more frequently published in radiology/imaging journals than those that did not use the LI-RADS lexicon (84.6%

**Table 3. The Imaging Diagnoses in 56 Studies with Their Own Diagnostic Imaging Criteria**

Pre-Specified Diagnostic Imaging Criteria		No. of Studies (%)
APHE AND washout on PV/EP (TP)	APHE AND washout on PV or EP (TP) AND other ancillary features	9 (16.1)
	APHE AND washout on PV or EP (TP), OR other ancillary features	9 (16.1)
APHE AND washout on PV/EP (TP) or HBP hypointensity	APHE AND washout on PV, EP (TP) or HBP hypointensity	10 (17.9)
	APHE AND washout on PV or HBP hypointensity	2 (3.6)
	APHE AND washout on EP (TP) or HBP hypointensity	2 (3.6)
	APHE AND washout on PV, EP (TP) or HBP hypointensity AND other ancillary features	2 (3.6)
	APHE AND HBP hypointensity	4 (7.1)
	APHE AND washout on PV, EP (TP) AND HBP hypointensity, OR other ancillary features	3 (5.4)
No contrast-enhanced MRI	Other MRI features with no use of contrast-enhanced MRI	5 (8.9)
Various MRI features	Various combinations of MRI features	10 (17.9)

APHE = arterial-phase hyperenhancement, EP = equilibrium-phase, HBP = hepatobiliary-phase, PV = portal venous-phase, TP = transitional-phase

**Table 4. Meta-Analytic Pooled Sensitivity and Specificity of Studies Using or Not Using the LI-RADS Diagnostic Imaging Criteria for Hpatocellular Crcinoma**

	No. of Studies	Pooled Sensitivity, % (95% CI)	I <sup>2</sup> Statistics, %	Pooled Specificity, % (95% CI)	I <sup>2</sup> Statistics, %
LI-RADS v2013	2	50.0 (19.7, 80.3)	NA*	96.0 (92.5, 100.0)	NA*
LI-RADS v2014	13	61.9 (49.4, 73.0)	96.0	92.9 (89.0, 95.4)	81.2
LI-RADS v2017	9	67.0 (62.7, 71.0)	66.8	93.1 (90.0, 95.3)	48.9
LI-RADS v2018	10	77.7 (71.0, 83.3)	86.7	89.9 (86.3, 92.5)	53.2
Studies that did not use the LI-RADS diagnostic imaging criteria	69	86.3 (83.0, 89.0)	94.3	91.4 (88.9, 93.5)	86.6

\*I<sup>2</sup> statistics could not be calculated due to the small number of studies using LI-RADS v2013. CI = confidence interval, LI-RADS = Liver Imaging Reporting and Data System, NA = not available

[44/52] vs. 65.4% [83/127],  $p = 0.010$ ), and were less frequently published in gastroenterology/hepatology journals (7.7% [4/52] vs. 20.5% [26/127],  $p = 0.033$ ) (Supplementary Table 3). The mean impact factor of all the 179 articles was 3.5. The percentage of studies with an impact factor  $\geq 3.5$  was significantly higher in studies that used the LI-RADS lexicon than in those that did not (44.2% [23/52] vs. 26.8% [34/127],  $p = 0.033$ ).

Of the 144 studies reporting the performance of liver MRI, 45 studies used the LI-RADS diagnostic imaging criteria for HCC, and 99 did not. Regarding the risk of bias, the flow and timing domains showed the highest percentage of studies with a high risk of bias (61.8% [89/144]), followed by the patient selection domain (16.0% [23/144]) (Supplementary Fig. 1). In the flow and timing domain, patients did not receive the same reference standard in 50.0% (72/144) of the studies, and there was an inappropriate interval between the index test and reference standard in 13.2% (19/144) of studies. The percentage of studies with a high risk of bias did not differ significantly according to the LI-RADS diagnostic imaging criteria ( $p \geq 0.108$ ). The pooled sensitivity of the LI-RADS v2018 was 77.7%, which was higher than that of the LI-RADS v2014 (77.7% vs. 61.9%,  $p = 0.025$ ) and v2017 (77.7% vs. 67.0%,  $p = 0.019$ ) (Table 4, Supplementary Fig. 2). The pooled specificity of LI-RADS v2018 was similar to that of LI-RADS v2014 (89.9% vs. 92.9%,  $p = 0.285$ ) or v2017 (89.9% vs. 93.1%,  $p = 0.109$ ). No significant difference in sensitivity (77.7% vs. 86.3%,  $p = 0.102$ ) and specificity (89.9% vs. 91.4%,  $p = 0.770$ ) were noted between studies using the LI-RADS v2018 and those that did not. When comparing studies that used the LI-RADS v2017 and v2018 with those that did not, study heterogeneity in terms of both sensitivity and specificity was found to be higher in studies that did not use the LI-RADS diagnostic imaging criteria

(I<sup>2</sup> for sensitivity = 94.3% vs. 66.8% for the LI-RADS v2017 and 86.7% for v2018; I<sup>2</sup> for specificity = 86.6% vs. 48.9% for the LI-RADS v2017 and 53.2% for v2018).

## DISCUSSION

The LI-RADS is a comprehensive system for categorizing liver findings in patients with risk factors for HCC, allowing the radiology community to apply consistent terminology, reduce imaging interpretation variability, enhance communication with referring clinicians, and facilitate quality assurance and research [6]. This systematic review shows that LI-RADS lexicons for imaging features and LI-RADS diagnostic imaging criteria have been increasingly used over the last decade, from 0% in 2011–2013 to 56.6% and 60.7% from 2017 to 2019, respectively. This study also confirms that LI-RADS helps to standardize liver imaging for the diagnosis of HCC.

Although the percentage of studies including all the LI-RADS-required image sequences did not significantly change after the introduction of LI-RADS, 84.2% of studies published between 2017 and 2019 used all the MRI sequences recommended by the LI-RADS. As the performance of liver MRI for diagnosing HCC can differ according to imaging techniques [6,14], reducing the variability in imaging acquisition is important, and it might be the cornerstone for the standardization of liver MRI. However, given that the remaining 15.8% of studies did not use all required image sequences or did not clearly state their use, the LI-RADS needs to further improve the standardization of imaging techniques by providing more detailed methods.

We found that the percentage of studies using the LI-RADS lexicon increased after the introduction of the LI-RADS. In other words, the proportion of studies that performed



image analysis using the same definition of each imaging feature increased. Because image analysis for HCC depends on the relative size and conspicuity of the enhancing areas, and given that the image features are assessed relative to the heterogeneous background of the liver, which may often be cirrhotic, the characterization of imaging features as being present or absent can differ according to the area of the background liver used for comparison [3]. Therefore, a lexicon of imaging features is an important factor for standardizing imaging analysis. In addition, because it is difficult to synthesize data into a meta-analysis if different definitions are used, the implementation of a lexicon is also important for future meta-analyses to facilitate more evidence-based practice.

The use of the LI-RADS as a diagnostic imaging criterion for HCC has also increased since the introduction of the LI-RADS. After being fully integrated with the AASLD 2018 HCC practice guidelines, the LI-RADS can be more widely used in clinical practice and research. This study showed that the LI-RADS has been globally used as a diagnostic criterion for HCC, including in 28.6% of studies performed in North America, 24.2% performed in Europe, and 33.7% performed in Asia. Regarding the temporal changes in each region, the LI-RADS was most frequently used in North America during 2014–2016, but North America and Asia have increasingly used the LI-RADS after that period. In addition, Europe showed a gradual increase in the use of the LI-RADS. These results imply that the trend for using the LI-RADS is spreading globally, particularly in Asia.

Several recent studies reported the different diagnostic performance of liver MRI across different diagnostic imaging criteria, with relatively high sensitivity being the aim of the guidelines of the Asian Pacific Association for the Study of the Liver and KLCA-NCC, and with relatively high specificity being the aim of AASLD and EASL [15,16]. Because the diagnostic imaging criteria for HCC vary according to different clinical environments and countries, it is reasonable to use appropriate diagnostic imaging criteria in consideration of the geographic background [10,15]. However, this means that it might be difficult to compare reported data on the performance of each diagnostic imaging criterion across the published literature. In our study, we found decreased study heterogeneity after the use of the LI-RADS diagnostic imaging criteria for HCC, particularly with regard to specificity, indicating the possibility of more reliable and less biased comparisons between studies. In addition, the diagnostic performance

of the LI-RADS also improved across the version with increasing sensitivity (61.9% in v2014, 67.0% in v2017, and 77.7% in v2018) and no significant decrease in specificity. Furthermore, the impact factor of studies with the LI-RADS was higher than that of studies without the LI-RADS. Therefore, the use of the LI-RADS has clinical implications, as well as leading to standardization in the imaging diagnosis of HCC.

This study has some limitations. First, as we analyzed published studies, there was a limitation in the acquisition of detailed information about how imaging analysis was performed in the primary research studies. Although we robustly reviewed the supplementary materials of each individual study, as well as the research methods described in the main text, further data would need to be collected to make a more solid conclusion. Second, while this study only evaluated the impact of the LI-RADS on the research methodology of liver MRI, the impact of the LI-RADS on clinical practice and the management of patients with HCC are also important. However, to the best of our knowledge, studies on how the application of LI-RADS affects patient outcomes are scarce, and a systematic review on this issue is not currently feasible.

In conclusion, this systematic review demonstrated that the LI-RADS imparted significant changes to the image analysis methods and diagnostic criteria used in the research methodology for liver MRI for the diagnosis of HCC. However, as non-standard methods or ambiguities in the image analysis and diagnostic imaging criteria still remain, efforts to spread the use of LI-RADS should continue.

## Supplement

The Supplement is available with this article at <https://doi.org/10.3348/kjr.2021.0393>.

## Availability of Data and Material

All data generated or analyzed during the study are included in this published article (and its supplementary information files).

## Conflicts of Interest

So Yeon Kim and Seung Soo Lee who is on the editorial board of the *Korean Journal of Radiology* was not involved in the editorial evaluation or decision to publish this article. All remaining authors have declared no conflicts of interest.

### Author Contributions

Conceptualization: Sang Hyun Choi. Data curation: Yura Ahn, Jong Keon Jang. Formal analysis: Sang Hyun Choi, Yura Ahn, Jong Keon Jang. Funding acquisition: Sang Hyun Choi. Investigation: Sang Hyun Choi, Yura Ahn, Jong Keon Jang. Methodology: Sang Hyun Choi. Supervision: Sang Hyun Choi. Visualization: Yura Ahn. Writing—original draft: Sang Hyun Choi, Yura Ahn. Writing—review & editing: Sang Hyun Choi, So Yeon Kim, Ju Hyun Shim, Seung Soo Lee, Jae Ho Byun.

### ORCID iDs

Yura Ahn

<https://orcid.org/0000-0002-9188-1186>

Sang Hyun Choi

<https://orcid.org/0000-0002-6898-6617>

Jong Keon Jang

<https://orcid.org/0000-0002-2938-6635>

So Yeon Kim

<https://orcid.org/0000-0001-6853-8577>

Ju Hyun Shim

<https://orcid.org/0000-0002-7336-1371>

Seung Soo Lee

<https://orcid.org/0000-0002-5518-2249>

Jae Ho Byun

<https://orcid.org/0000-0003-2076-9979>

### Funding Statement

SH Choi received a National Research Foundation of Korea (NRF) grant funded by the Korean government (MSIT) (grant number: NRF-2019R1G1A1099743). The other authors have no conflicts of interest to declare.

### REFERENCES

1. El-Serag HB, Rudolph KL. Hepatocellular carcinoma: epidemiology and molecular carcinogenesis. *Gastroenterology* 2007;132:2557-2576
2. Mitchell DG, Bruix J, Sherman M, Sirlin CB. LI-RADS (liver imaging reporting and data system): summary, discussion, and consensus of the LI-RADS management working group and future directions. *Hepatology* 2015;61:1056-1065
3. Chernyak V, Sirlin CB. Editorial for "interreader agreement of liver imaging reporting and data system on MRI: a systematic review and meta analysis". *J Magn Reson Imaging* 2020;52:805-806
4. American College of Radiology. CT/MRI LI-RADS v2014 flash cards. ACR.org Web site. <https://www.acr.org/-/media/ACR/Files/Clinical-Resources/LIRADS/LI-RADS-2014-Flash-Cards.pdf>. Accessed November 21, 2021
5. American College of Radiology. CT/MRI LI-RADS® v2017 core. ACR.org Web site. [https://www.acr.org/-/media/ACR/Files/RADS/LI-RADS/LIRADS\\_2017\\_Core.pdf](https://www.acr.org/-/media/ACR/Files/RADS/LI-RADS/LIRADS_2017_Core.pdf). Accessed November 21, 2021
6. American College of Radiology. CT/MRI LI-RADS® v2018 core. ACR.org Web site. <https://www.acr.org/-/media/ACR/Files/RADS/LI-RADS/LI-RADS-2018-Core.pdf?la=en>. Accessed November 21, 2021
7. Elsayes KM, Hooker JC, Agrons MM, Kielar AZ, Tang A, Fowler KJ, et al. 2017 version of LI-RADS for CT and MR imaging: an update. *Radiographics* 2017;37:1994-2017
8. Fowler KJ, Tang A, Santillan C, Bhargavan-Chatfield M, Heiken J, Jha RC, et al. Interreader reliability of LI-RADS version 2014 algorithm and imaging features for diagnosis of hepatocellular carcinoma: a large international multireader study. *Radiology* 2018;286:173-185
9. Kang JH, Choi SH, Lee JS, Park SH, Kim KW, Kim SY, et al. Interreader agreement of liver imaging reporting and data system on MRI: a systematic review and meta-analysis. *J Magn Reson Imaging* 2020;52:795-804
10. Kim DH, Choi SH, Park SH, Kim KW, Byun JH, Kim SY, et al. Meta-analysis of the accuracy of liver imaging reporting and data system category 4 or 5 for diagnosing hepatocellular carcinoma. *Gut* 2019;68:1719-1721
11. van der Pol CB, Lim CS, Sirlin CB, McGrath TA, Salameh JP, Bashir MR, et al. Accuracy of the liver imaging reporting and data system in computed tomography and magnetic resonance image analysis of hepatocellular carcinoma or overall malignancy—a systematic review. *Gastroenterology* 2019;156:976-986
12. Corwin MT, Fananapazir G, Jin M, Lamba R, Bashir MR. Differences in liver imaging and reporting data system categorization between MRI and CT. *AJR Am J Roentgenol* 2016;206:307-312
13. McInnes MDF, Moher D, Thombs BD, McGrath TA, Bossuyt PM, Clifford T, et al. Preferred reporting items for a systematic review and meta-analysis of diagnostic test accuracy studies: the PRISMA-DTA statement. *JAMA* 2018;319:388-396
14. Maubon AJ, Ferru JM, Berger V, Soullage MC, DeGraef M, Aubas P, et al. Effect of field strength on MR images: comparison of the same subject at 0.5, 1.0, and 1.5 T. *Radiographics* 1999;19:1057-1067
15. Byun J, Choi SH, Byun JH, Lee SJ, Kim SY, Won HJ, et al. Comparison of the diagnostic performance of imaging criteria for HCCs ≤ 3.0 cm on gadoxetate disodium-enhanced MRI. *Hepatol Int* 2020;14:534-543
16. Lee S, Kim SS, Chang DR, Kim H, Kim MJ. Comparison of LI-RADS 2018 and KLCA-NCC 2018 for noninvasive diagnosis of hepatocellular carcinoma using magnetic resonance imaging. *Clin Mol Hepatol* 2020;26:340-351