



Subtrochanteric femoral fracture with postoperative chronic osteomyelitis treated successfully by 1-stage operation: a case report

Genying Chi, Haiyong Ren, Bingyuan Lin, Kai Huang

Department of Orthopedics, Tongde Hospital of Zhejiang Province, Hangzhou, China

Correspondence to: Kai Huang. Department of Orthopedics, Tongde Hospital of Zhejiang Province, 234 Gucui Road, Hangzhou, China.

Email: zjhzhuangkai@163.com.

Abstract: Chronic osteomyelitis is a chronic infectious disease of bone tissue, which can cause necrosis of bone and surrounding soft tissue, and is a common complication of open fracture, internal fixation, diabetic foot and blood-borne bone infection. Traumatic osteomyelitis is caused by bone tissue infection after open fracture surgery or open reduction of fracture or other bone and joint surgery. The lesion is near the fracture end. Intramedullary infection is the most serious infection in acute stage, with high fever, chills and other toxemia symptoms, similar to acute hematogenous osteomyelitis. The other is the skin and muscle necrosis infection near the fracture, which makes Fractures that lose blood supply are exposed to air and become dry and necrotic, and the course of disease turns to chronic, often accompanied by infectious nonunion or bone damage. The course of disease is prolonged and the treatment is difficult. Subtrochanteric femoral fracture with postoperative chronic osteomyelitis is a rare condition requiring complex treatment. In the present study, we report on a 49-year-old male patient who received open reduction with intramedullary nail fixation due to subtrochanteric femoral fracture, but later suffered postoperative infection and developed chronic osteomyelitis. On the basis of the complete removal of the osteomyelitis lesion, we performed a 1-stage operation where free vascularized fibula was used to repair the bone defect, followed by effective internal fixation. The patient was followed up for 24 months and finally recovered from chronic osteomyelitis, with good functional recovery of the hip joint and a Harris score of 85.

Keywords: Subtrochanteric femoral fracture; chronic osteomyelitis; free fibula; 1-stage operation; case report

Submitted Jan 08, 2021. Accepted for publication Mar 05, 2021.

doi: 10.21037/atm-21-413

View this article at: <http://dx.doi.org/10.21037/atm-21-413>

Introduction

Subtrochanteric femoral fracture accounts for 10–34% of all hip fractures (1). At present, surgery is the preferred treatment for subtrochanteric femoral fracture. Of the various materials for internal fixation in subtrochanteric femoral fracture, the intramedullary nail system is the preferred choice (2). The incidence of postoperative infection after internal fixation using intramedullary nails is <1%. However, intramedullary infection is one of the rarest but most severe infections following intramedullary nailing. If not properly treated, intramedullary infection is likely to evolve into chronic traumatic osteomyelitis. At present,

chronic osteomyelitis caused by post-traumatic infection remains the greatest challenge for surgeons. In the present study, we report on a patient who had subtrochanteric femoral fracture with postoperative chronic osteomyelitis, who was treated successfully by 1-stage operation. Subtrochanteric fracture is common, but infection after subtrochanteric fracture is rare, and it has disastrous consequences for patients. We not only cured the infection, but also reconstructed the bone, and the patient's bone function recovered well. The advantage is that we only got better curative effect after one-stage operation.

We present the following case in accordance with the

CARE reporting checklist (available at <http://dx.doi.org/10.21037/atm-21-413>).

Case presentation

The patient (male, 49 years old) had a right comminuted subtrochanteric femoral fracture due to a fall from height on August 3, 2017. He was initially treated at a hospital about 1,200 km from our hospital; therefore, we could not acquire the imaging data upon his first visit to the local hospital. According to his discharge records, he was diagnosed with a right comminuted subtrochanteric femoral fracture (Seinsheimer type V). After admission to our hospital, he immediately received traction of the right tibial tuberosity. On August 7, 2017, he received open reduction with internal fixation using intramedullary nails for right comminuted subtrochanteric femoral fracture under general anesthesia. The operation lasted 8h. The patient achieved primary incision healing and was later discharged. All procedures performed in studies involving human participants were in accordance with the ethical standards of the institutional and/or national research committee(s) and with the Helsinki Declaration (as revised in 2013). Written informed consent was obtained from the patient.

At 11 months postoperatively, the patient had proximal incision redness and ulceration, with the formation of a sinus tract (*Figure 1A*). Upon his visit to our hospital, he underwent X-ray and CT examinations, which revealed intense hyperostosis and osteosclerosis in the right proximal femur, with local bone destruction (*Figure 1B,C*). The patient was diagnosed with chronic osteomyelitis in the right proximal femur. After careful evaluation and discussion, the patient underwent removal of the chronic osteomyelitis lesion in the right proximal femur + removal of internal fixation + transplantation of the free fibula + internal fixation using locking plates in the proximal femur. The patient was placed in the supine position and methylene blue was injected via the sinus tract for staining to determine the orientation of the sinus tract. A longitudinal incision was made in the lateral thigh, and thorough debridement was performed. Intramedullary nails, Kirschner wires, and steel wires were removed (*Figure 1D,E*). Necrotic skin, soft tissues, and the sinus tract were also removed, as well as bone-adhering scars and inflammatory granuloma. An incision was made on the lesioned bone segment to remove the sequestra and sclerotic bones, which were submitted for pathological examination. Drilling was performed with an abrasion

drill until blood was visible on the bone surface. After thorough debridement, dissection was performed to access the descending branch of the lateral femoral circumflex artery and its accompanying vein. Following Urbaniak's technique (3), a lateral incision was made in the middle-upper third of the contralateral calf. The fibula was exposed along the peroneus longus, peroneus brevis, and musculus soleus. The fibula was incised at the distal end at 5 cm below the fibular head. The fibula was severed at the distal end of the fibular artery and fibular vein in parallel with the plane of the broken end of the fibula. The incision length of the fibula was 10 cm in the patient. The proximal femur is the primary weight-bearing portion, and 1 fibula alone can't bear all the weight. Therefore, the fibula, with a length of 20 cm was harvested, double folded, and then packed into the medullary cavity as a bone graft. The anastomosis of blood vessels was performed under a microscope (*Figure 1F,G,H*). Next, internal fixation was performed using the locking plate in the proximal femur, with the indwelling of the drainage tube in the incision. Finally, the incision was closed layer by layer (*Figure 1I*).

The patient was monitored carefully by nurses postoperatively, with regular dressing and routine medications, including anti-coagulation, anti-spasm, and anti-infection therapies. The patient received postoperative antibiotics via intravenous drip and underwent blood tests for re-examination. Antibiotics were discontinued if the white blood cell count, erythrocyte sedimentation rate, and C-reactive protein (CRP) level were normal twice consecutively. Antibiotics via intravenous drip were given for 4 weeks in total. After discharge, the patient received guidance for functional training and regular follow-up. Follow-up included response to treatment for osteomyelitis and recovery of functional activities.

Our patient underwent 24 months of follow-up, and the findings were good incision healing in the right hip without redness, exudation, tenderness pain, or abnormal mobility; flexion of the right hip joint at $>90^\circ$ (*Figure 1J*); and good incision healing at the donor site in the left calf without redness, exudation, pain, or discomfort. The patient achieved good functional recovery. Re-examination by X-ray indicated that the transplanted fibula was in the right place, with good healing, normal bone density, and no relapse of osteomyelitis. The results of C-reactive protein and erythrocyte sedimentation rate tests were normal, and the Harris hip score was 85. The patient's osteomyelitis resolved, and the target of functional recovery of the hip joint was achieved.

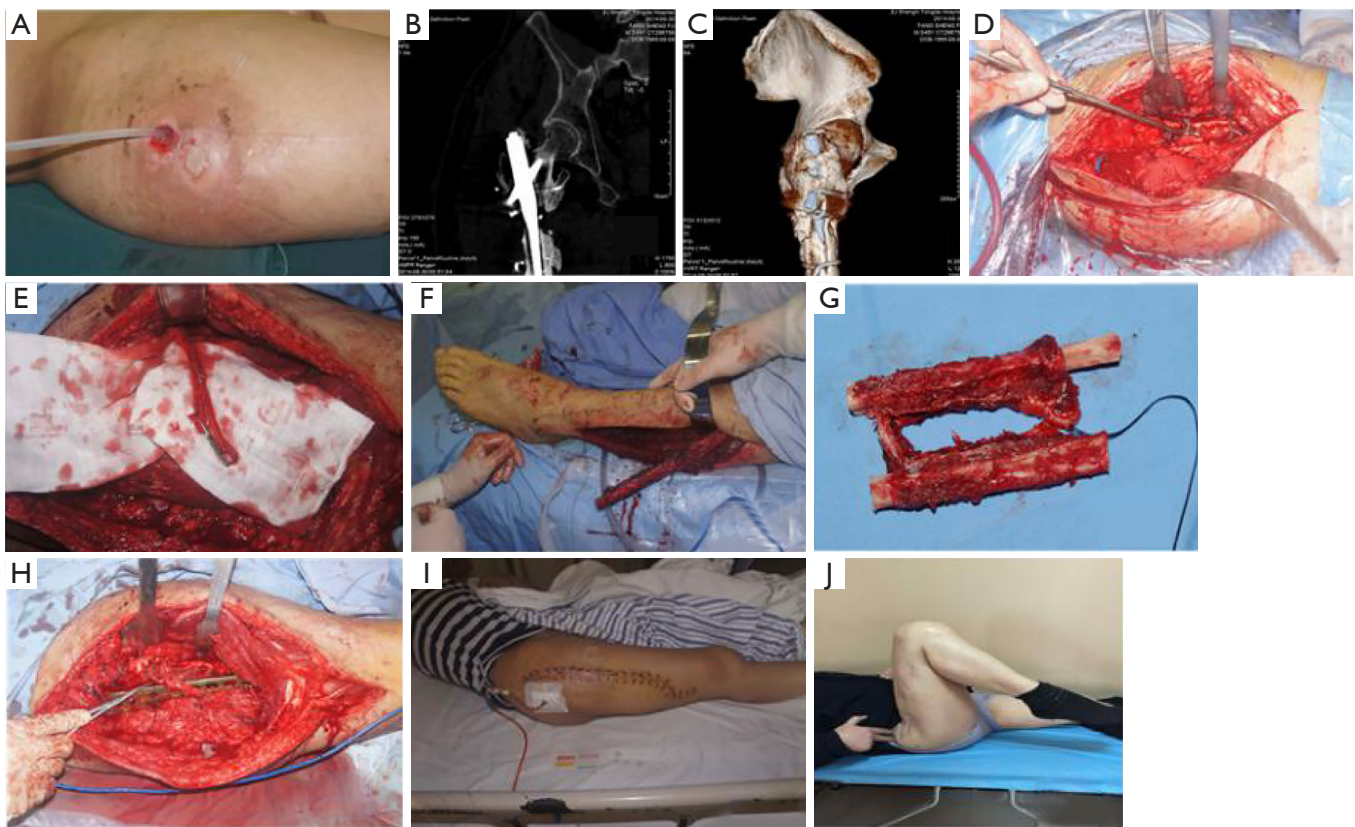


Figure 1 Illustration of each stage of patient's operation. (A) The patient had proximal incision redness and ulceration, with the formation of a sinus tract; (B,C) CT reconstruction images of the patient before operation; (D,E,F,G,H) Removed the chronic osteomyelitis lesion in the right proximal femur + removed internal fixation + transplantation of the free fibula + internal fixation using locking plates in the proximal femur; (I) suture the incision and place a drainage tube; (J) the flexion of the right hip joint at over 90°.

Discussion and review of the literature

In our reported case, chronic osteomyelitis in the proximal femur was combined with extensive soft tissue infection around the lesion at the broken end and the formation of a large number of scar tissues. The challenges of surgical treatment for this case were 2 folds. First, thorough debridement had to be ensured. Apart from the infected and necrotic bones, necrotic skin and soft tissues with the sinus tract, bone-adhering scars, and inflammatory granuloma also needed to be removed. Although new techniques for treating osteomyelitis are regularly emerging, thorough debridement remains the most important factor for the successful treatment of chronic traumatic osteomyelitis (4-7). Thorough debridement in our patient was the prerequisite for the success of a 1-stage operation without relapse of osteomyelitis (8). Second, repair of the bone defect. Conventional treatments for bone defects

generally include transplantation of the fibular segment without a blood supply, inlay bone grafting of cancellous bone, autologous bone marrow transplantation, Ilizarov technique (9), bony fusion, or allograft bone transplantation (10,11). However, these methods share 1 defect: the bone graft lacks a blood supply. The conditions of re-infection, necrosis, or non-union are likely to occur after transplantation, resulting in surgical failure.

To sum up, we have the following suggestions for the treatment of chronic osteomyelitis after operation of subtrochanteric fracture of femur: (I) the infected site should be fully debrided; (II) the invalid internal fixation needs to be replaced; (III) if necessary, bone grafting should be needed to reconstruct the bone structure; (IV) it is necessary to use local antibiotics for chronic osteomyelitis infection after operation of subtrochanteric fracture of femur.

Free vascularized fibular grafting (FVFG) was first introduced in the late 1970s (12). Since then, FVFG has been extensively used for the repair of different bone defects. In our reported case, FVFG had the following advantages: (I) transplantation of the well-vascularized fibular graft reduced the time of bone healing; (II) FVFG not only facilitated bone repair and bone remodeling but also enhanced the anti-infection capacity (6,13); and (III) the fibular graft, when double folded, can repair the extensive bone defect in the femur while ensuring sufficient strength and facilitating an early start to functional training (14).

For internal fixation after bone grafting, we selected the locking plates in the proximal femur. The locking plates not only conform to the principles of biochemical fixation but also reduce the peeling of distal soft tissues and the damage to the blood supply (15). For similar surgeries, the locking plates are the most ideal and reliable materials for internal fixation.

In 2017, Gracitelli *et al.* (16) noted in their study that proximal humerus fractures (PHF) are common fractures among older adults. The most commonly used implants for PHF include the locking plate and the locking intramedullary nail. The authors performed a literature review of biomechanical and clinical studies that compared the locking plate and intramedullary nail for PHF osteosynthesis.

In 2018, Li *et al.* (17) published a meta-analysis based on 1,384 individuals. Their analysis showed that intramedullary nails were superior to locking plates in incision length, perioperative bleeding time, operation time, and fracture healing time. However, there were no differences between treatments in constant score or postoperative complications (18).

In 2019, Li *et al.* (19) published a study on about 18 cases of open fracture secondary chronic tibia osteomyelitis. The aim of the study was to discuss the method and curative effects of vacuum sealing drainage (VSD) treatment combined with skin flap transplantation and antibiotic bone cement for chronic tibia osteomyelitis. The satisfaction and recurrence rates of their study cases postoperatively were 94.4% and 5.6%, respectively. The average functional recovery postoperatively was 81.5% of normal function (20).

Conclusions

In the present study, we report on our successful experience with the 1-stage operation for our patient. The findings

can be summarized as follows. First, thorough debridement is important for surgical success (21). Second, the microsurgical technique still plays an irreplaceable role, especially in those with an extensive bone defect. Therefore, FVFG is recommended for the 1-stage operation in similar cases. Finally, the choice of locking plates for internal fixation in the proximal femur is correct and it plays a very important role in the recovery of the patient.

Acknowledgments

Funding: National Natural Science Foundation of China(No. 81603644); Zhejiang Province Public Welfare Technology Application Research Project (LGF21H270004); Natural Science Foundation of Zhejiang Province (LY20H270002); Medical science and technology project of Zhejiang Province (2020RC048, 2021KY600); Chinese Medicine Research Program of Zhejiang Province (2020ZQ006, 2021ZB060).

Footnote

Reporting Checklist: The authors have completed the CARE reporting checklist. Available at <http://dx.doi.org/10.21037/atm-21-413>

Conflicts of Interest: All authors have completed the ICMJE uniform disclosure form (available at <http://dx.doi.org/10.21037/atm-21-413>). The authors have no conflicts of interest to declare.

Ethical Statement: The authors are accountable for all aspects of the work in ensuring that questions related to the accuracy or integrity of any part of the work are appropriately investigated and resolved. All procedures performed in studies involving human participants were in accordance with the ethical standards of the institutional and/or national research committee(s) and with the Helsinki Declaration (as revised in 2013). Written informed consent was obtained from the patient.

Open Access Statement: This is an Open Access article distributed in accordance with the Creative Commons Attribution-NonCommercial-NoDerivs 4.0 International License (CC BY-NC-ND 4.0), which permits the non-commercial replication and distribution of the article with the strict proviso that no changes or edits are made and the original work is properly cited (including links to both the

formal publication through the relevant DOI and the license).
See: <https://creativecommons.org/licenses/by-nc-nd/4.0/>.

References

1. Yeh WL, Su CY, Chang CW, et al. Surgical outcome of atypical subtrochanteric and femoral fracture related to bisphosphonates use in osteoporotic patients with or without teriparatide treatment. *BMC Musculoskeletal Disord* 2017;18:527.
2. Lundy DW. Subtrochanteric femoral fractures. *J Am Acad Orthop Surg* 2007;15:663-71.
3. Tropet Y, Garbuio P, Coral HP. One-stage emergency treatment of open tibial shaft fractures with bone loss. Specifics and indications. *Ann Chir Plast Esthet* 2000;45:323-35.
4. Chang BY, Li HG, Li ZY, et al. Treatment of chronic osteomyelitis of tibia with debridement and vacuum sealing drainage (VSD) of cavitas medullaris. *Zhongguo Gu Shang* 2011;24:952-4.
5. Lew DP, Waldvogel FA. Osteomyelitis. *Lancet* 2004;364:369-79.
6. Liu XW, Wang PF, Fu QG, et al. Treatment of Seinsheimer type V subtrochanteric femoral fractures with dynamic hip screw and shape memory alloy bow-teeth screw. *Zhongguo Gu Shang* 2010;23:288-90.
7. Kawakami R, Ejiri S, Hakozaki M, et al. Surgical treatment options for septic non-union of the tibia: two staged operation, Flow-through anastomosis of FVFG, and continuous local intraarterial infusion of heparin. *Fukushima J Med Sci* 2016;62:83-9.
8. Shen Y, Hu X, Wen C, et al. Treatment of post-traumatic chronic calcaneal osteomyelitis and soft tissue defect by using combined muscle and skin flaps of calf. *Zhongguo Xiu Fu Chong Jian Wai Ke Za Zhi* 2013;27:1061-4.
9. Gubin AV, Borzunov DY, Malkova TA. The Ilizarov paradigm: thirty years with the Ilizarov method, current concerns and future research. *Int Orthop* 2013;37:1533-9.
10. Molenaars RJ, Schoolmeesters BJA, Viveen J, et al. There is a role for allografts in reconstructive surgery of the elbow and forearm. *Knee Surg Sports Traumatol Arthrosc* 2019;27:1840-6.
11. Anderson JJ, Boone JJ, Hansen M, et al. Ankle arthrodesis fusion rates for mesenchymal stem cell bone allograft versus proximal tibia autograft. *J Foot Ankle Surg* 2014;53:683-6.
12. Poul J, Veselý J, Gál P, et al. Treatment of congenital pseudarthrosis of tibia by vascularized fibular graft. *Acta Chir Orthop Traumatol Cech* 2006;73:10-7.
13. Ryan SP, Wooster B, Jiranek W, et al. Outcomes of Conversion Total Hip Arthroplasty From Free Vascularized Fibular Grafting. *J Arthroplasty* 2019;34:88-92.
14. Liu S, Tao S, Tan J, et al. Long-term follow-up of fibular graft for the reconstruction of bone defects. *Medicine (Baltimore)* 2018;97:e12605.
15. Donnelly KJ, Tucker A, Kerr B, et al. A review of atypical subtrochanteric femoral fractures in Northern Ireland between 2010 and 2014. *Eur J Orthop Surg Traumatol* 2018;28:607-13.
16. Gracitelli MEC, Malavolta EA, Assunção JH, et al. Locking intramedullary nails versus locking plates for the treatment of proximal humerus fractures. *Expert Rev Med Devices* 2017;14:733-9.
17. Li M, Wang Y, Zhang Y, et al. Intramedullary nail versus locking plate for treatment of proximal humeral fractures: A meta-analysis based on 1384 individuals. *J Int Med Res* 2018;46:4363-76.
18. Kregor PJ, Obremskey WT, Kreder HJ, et al. Unstable pertrochanteric femoral fractures. *J Orthop Trauma* 2014;28 Suppl 8:S25-8.
19. Li J, Zhang H, Qi B, et al. Outcomes of Vacuum Sealing Drainage Treatment Combined with Skin Flap Transplantation and Antibiotic Bone Cement on Chronic Tibia Osteomyelitis: A Case Series Study. *Med Sci Monit* 2019;25:5343-9.
20. Errani C, Ceruso M, Donati DM, et al. Microsurgical reconstruction with vascularized fibula and massive bone allograft for bone tumors. *Eur J Orthop Surg Traumatol* 2019;29:307-11.
21. Qin L, Zhu Z, Song D, et al. Effectiveness of modified Urbaniak operation to treat avascular necrosis of the femoral head. *Zhongguo Xiu Fu Chong Jian Wai Ke Za Zhi* 2016;30:25-9.

(English Language Editor: R. Scott)

Cite this article as: Chi G, Ren H, Lin B, Huang K. Subtrochanteric femoral fracture with postoperative chronic osteomyelitis treated successfully by 1-stage operation: a case report. *Ann Transl Med* 2021;9(6):514. doi: 10.21037/atm-21-413