

Single Case

Mycosis Fungoides with Dermal Mucin Deposition: An Unusual Variant of the Most Challenging Primary Cutaneous Lymphoma

Alessandra Filosa^a Stefano Simonetti^b Magda Zanelli^c
Maurizio Zizzo^d Luca Stingeni^b Giovanni Martino^e Guido Collina^a
Stefano Ascani^f

^aPathology Unit, Azienda Sanitaria Unica Regionale Area Vasta 5 Ospedale G. Mazzoni, Ascoli Piceno, Italy; ^bDermatology Unit, Ospedale Santa Maria della Misericordia, University of Perugia, Perugia, Italy; ^cPathology Unit, Azienda Unità Sanitaria Locale/IRCCS di Reggio Emilia, Reggio Emilia, Italy; ^dSurgical Oncology Unit, Azienda Unità Sanitaria Locale – IRCCS di Reggio Emilia, Reggio Emilia, Italy; ^eInstitute of Hematology-CREO, Ospedale Santa Maria della Misericordia, University of Perugia, Perugia, Italy; ^fPathology Unit, Ospedale di Terni, University of Perugia, Terni, Italy

Keywords

Cutaneous T-cell lymphoma · Mycosis fungoides · Mucin

Abstract

Mycosis fungoides (MF) is defined as an epidermotropic primary cutaneous T-cell lymphoma composed of small-to-medium-sized T lymphocytes with cerebriform nuclei and with a T-helper phenotype. LeBoit first described an unusual variant of MF with dermal acid mucin deposition. Such a variant was still considered in the list of clinicopathological variants of MF by Cerroni and colleagues. We herein report a case of patch-stage MF with abundant papillary dermal mucin deposition in a clinical setting of an erythematous patch on the lower abdomen and thigh.

© 2021 The Author(s)
Published by S. Karger AG, Basel

Introduction

Mycosis fungoides (MF) is defined as an epidermotropic primary cutaneous T-cell lymphoma composed of small-to-medium-sized T lymphocytes with cerebriform nuclei and with a T-helper phenotype. MF is the most common type of cutaneous lymphoma, representing almost 50% of all primary cutaneous lymphomas. The classic clinical presentation of the disease is an evolution of patches, plaques, and tumors. MF patches are erythematous lesions usually in sun-protected areas. Plaques are characterized by infiltrated, irregular, variably scaling, erythematous, or reddish-brown lesions. Tumors are always the last step of disease evolution, with nodules concurrent with other, different-stage lesions. Histologically, the presence of many intraepidermal lymphocytes in areas with only scant spongiosis represents a useful clue for diagnosis. The most common immunophenotypic profile for MF is CD3, CD4 and CD45RO positivity, and CD20, CD8 and CD30 negativity. Several clinicopathological variants of MF have been described.

In 1986, Nickoloff [1] reported a series of cases of patch-and-plaque-stage MF in which significant spongiosis was observed in the epidermis, and documented the presence of colloidal iron-positive material in these zones of spongiosis. LeBoit [2] first described an unusual variant of MF with dermal acid mucin deposition. Such a variant was still considered in the list of clinicopathological variants of MF by Cerroni et al. [3]. More recently, Fairbee et al. [4] reported a case of MF associated with extensive dermal fibrosis and mucin deposition. At the present level of knowledge, mucin deposition is only a concurrent epiphenomenon of the disease, truly justifying the placement of mucinous MF between the clinicopathological variants of MF.

We herein report a case of patch-stage MF with abundant papillary dermal deposition in a clinical setting of an erythematous patch on the lower abdomen and thigh. We extensively describe the clinicopathological characteristics of our patient, hypothesizing on a possible interaction between stromal background and neoplastic cells in the mucin deposition pathway.

Case Report

A 49-year-old man presented to the Department of Dermatology of Perugia Hospital for a longstanding lesion in the sun-protected area of his left thigh and lower abdomen. The lesion was reported to initially have been a discrete patch having evolved into a wide and centrally sclerotic lesion also involving the periumbilical area. The lesion was slightly brown with a light-colored central area (Fig. 1a). The patient underwent surgical biopsy of the lesion. The histological examination of the biopsy specimen revealed an atrophic epidermis with moderate lymphocytic infiltrate in a perivascular band-like pattern. The lymphocytes were mostly middle-sized with an irregular nuclear contour and a cerebriform appearance. The lymphocytes showed evident epidermotropism without spongiosis (Fig. 1b) and merged with abundant mucinous material in a band-like pattern deposition in the entire papillary dermis. The mucinous material resulted positive on Alcian blue staining at pH 2.5 (Fig. 1c). The lymphoid infiltrate was composed of lymphocytes with a T-helper phenotype. Immunohistochemical analysis showed positivity of the lymphoid elements for CD3 (Fig. 1d) and CD4, with variable expression of T-cell associated antigens CD2, CD5, and CD7. Immunohistochemical analysis of these elements revealed their negativity for CD8 as well as for other cytotoxic markers such as granzyme, perforin, and TIA-1. Neoplastic cells resulted also negative for CD20, CD56,

CD68, PGM1, and CD1a, which indeed revealed an increase in the number of Langerhans cells. The interstitial tissue between collagen bundles of the dermis showed a slight increase in the number of tryptase-positive mast cells and occasional, isolated, plasmacytoid dendritic cells positive for anti-CD123 antibody. A TCR monoclonal gene rearrangement was detected by PCR in the neoplastic lymphoid cells.

Discussion

MF is the most common type of cutaneous lymphoma, representing almost 50% of all primary cutaneous lymphomas. It is composed of small-to-medium-sized epidermotropic T lymphocytes with cerebriform nuclei and with a T-helper phenotype [5]. The term “mycosis fungoides” should be used only for the classic clinical presentation characterized by the evolution of patches, plaques, and tumors or for variants showing a similar clinical course. On microscopy, early lesions of MF reveal a patchy lichenoid or band-like infiltrate in a fibrotic papillary dermis. Small lymphocytes predominate. Epidermotropism of solitary lymphocytes is usually found, but Pautrier’s microabscesses are uncommon. The presence of “halo” lymphocytes (i.e., lymphocytes with slightly larger nuclei surrounded by a small halo) aligned along the basal layer of the epidermis (so-called basilar epidermotropism) and of many intraepidermal lymphocytes with only scant spongiosis (“disproportionate” epidermotropism) represents a useful clue. Unusual histopathologic patterns in early phases include (1) the presence of prominent spongiosis; (2) interface alteration, sometimes with several necrotic keratinocytes similar to the picture of erythema multiforme; (3) marked pigment incontinence with melanophages in the papillary dermis; (4) extravasation of erythrocytes simulating the picture of lichen aureus; and (5) marked dermal edema [3, 5].

In our case, we described a classic clinical MF setting with peculiar histopathological findings. Abundant dermal mucin deposition is only rarely reported in patients with MF. Interestingly, in 1986, Nickoloff [1] reported a series of cases of patch-and-plaque-stage MF in which significant spongiosis was observed in the epidermis, and documented the presence of colloidal iron-positive material in these zones of spongiosis. Nickoloff proposed that MF should be added to the list of diseases in which there is epidermal mucinosis. Few years after, LeBoit [2] first described an unusual variant of MF with dermal acid mucin deposition. Such a variant was still considered in the list of clinicopathological variants of MF by Cerroni et al. [3]. More recently, Fairbee et al. [4] reported a case of MF associated with extensive dermal fibrosis and mucin deposition. Clinically, the patient showed indurated plaques with diffuse tightening of the skin reminiscent of scleromyxedema, which was later associated with nodules and lymphadenopathy. In Fairbee’s patient, the histologic features showed some overlap with the fibromucinosis. Skin biopsies showed diffusely thickened collagen bundles in the dermis and mucin deposition with a dense infiltrate of atypical lymphocytes showing an immunophenotypic pattern indicative of MF.

Our case shares with that of Fairbee the abundant dermal mucin deposition and the clinical presentation of the lesion resembling a sclerotic plaque. We observed only slight dermal fibrosis with focal collagen deposition in the mid dermis. The relation between abnormal T lymphocytes and dermal fibrosis is unknown. The histology and immunophenotype of the dermal spindle cell population (factor XIIIa positive) supports a dermal dendritic cell origin. Dermal dendrocytes are known to proliferate in response to tissue injury and inflammation. Cytokines have been implicated as potent effectors of inflammation and inducing proliferation

and differentiation of dermal dendrocytes. As cytokines capable of evoking these responses may be elaborated by lymphocytes, it is possible that the abnormal lymphocytes were responsible for the fibrosis in the case described by Fairbee [4, 6]. Moreover, as revealed in a recent study by Pileri et al. [7], tolerogenic cytokine expression by MF and immature dendritic cells could lead to accumulation of immature plasmacytoid dendritic cells recruited from blood, determining an increase in immunosuppression and eventually favoring tumor spread. In addition, factor XIIIa- and CD34-positive dermal dendrocytes are known to produce and secrete acid mucopolysaccharides (hyaluronic acid) in conjunction with a variety of inflammatory, mucinosis, and neoplastic conditions (i.e., dermatofibrosarcoma protuberans). This could lead to suggesting a possible role of dermal dendrocytes in mucin deposition also in our case. Unfortunately, the follow-up of our patient was too short to predict any clinical and biological evolution and to elaborate any theoretical speculation. Thus, at the present level of knowledge, mucin deposition is only to be considered a concurrent epiphenomenon of the disease, truly justifying the placement of mucinous MF between the clinicopathological variants of MF.

Statement of Ethics

The subject of this study has given written informed consent to publish his case (including publication of images).

Conflict of Interest Statement

The authors declare no conflicts of interest.

Funding Sources

No funding was received.

Author Contributions

Substantial contributions to the conception or design of the work; or the acquisition, analysis, or interpretation of data for the work: Alessandra Filosa, Stefano Ascani, and Guido Collina. Drafting the work or revising it critically for important intellectual content: Guido Collina. Final approval of the version to be published: Alessandra Filosa. Agreement to be accountable for all aspects of the work in ensuring that questions related to the accuracy or integrity of any part of the work are appropriately investigated and resolved: Stefano Simonetti, Magda Zannelli, Maurizio Zizzo, Luca Stingeni, and Giovanni Martino.

References

- 1 Nickoloff BJ. Epidermal mucinosis in mycosis fungoides. *J Am Acad Dermatol*. 1986 Jul;15(1):83–6.
- 2 LeBoit PE. Variants of mycosis fungoides and related cutaneous T-cell lymphomas. *Semin Diagn Pathol*. 1991 May;8(2):73–81.
- 3 Cerroni L, Gatter K, Kerl H. *Skin lymphoma: the illustrated guide*. 3rd ed. Wiley-Blackwell; 2009.
- 4 Fairbee SI, Morgan MB, Tannenbaum MT, Glass LF. Fibromucinous T-cell lymphoma: a new clinicopathologic variant of mycosis fungoides? *Am J Dermatopathol*. 2000 Dec;22(6):515–8.
- 5 Ahn CS, ALSayyah A, Sangüeza OP. Mycosis fungoides: an updated review of clinicopathologic variants. *Am J Dermatopathol*. 2014 Dec;36(12):933–48.
- 6 Hu SW, Ratch H, Naeem R, Latkowski JA, Kamino H. Mycosis fungoides with epidermal mucinosis: a variant of mycosis fungoides with a spongiosis-like pattern. *J Cutan Pathol*. 2015 Oct;42(10):730–8.
- 7 Pileri A, Agostinelli C, Sessa M, Quaglino P, Santucci M, Tomasini C, et al. Langerhans, plasmacytoid dendritic and myeloid-derived suppressor cell levels in mycosis fungoides vary according to the stage of the disease. *Virchows Arch*. 2017 May;470(5):575–82.

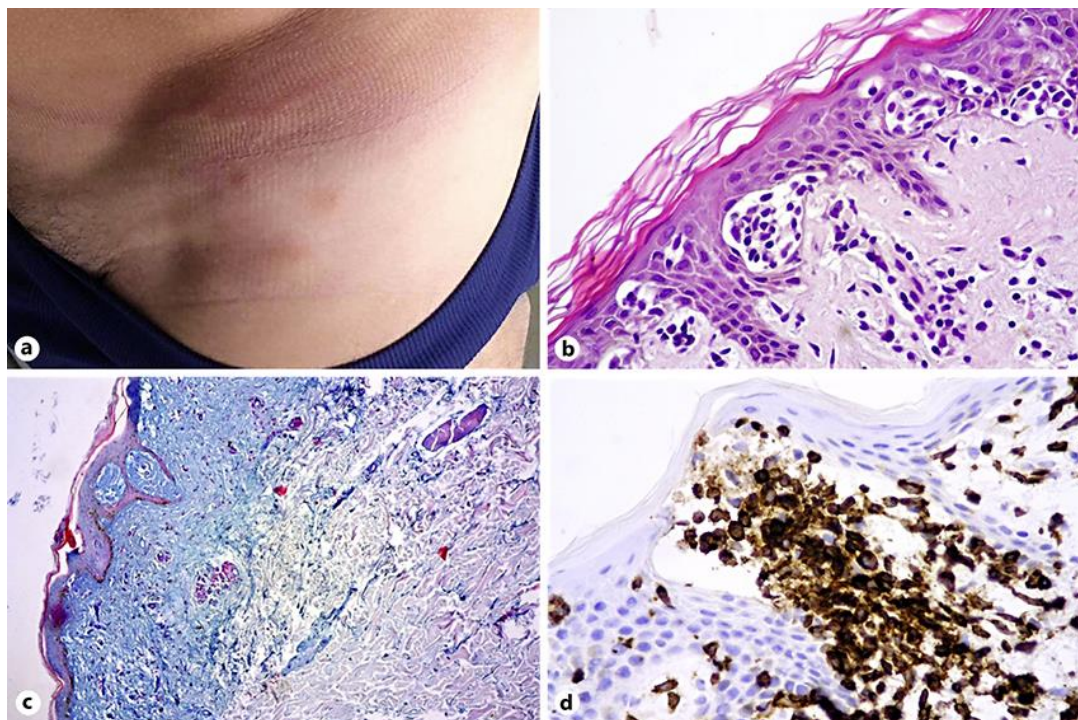


Fig. 1. **a** Slightly brown lesion on the left thigh. **b** The lymphocytes showed evident epidermotropism without spongiosis. **c** Abundant mucinous material in a band-like pattern deposition in the entire papillary dermis. The mucinous material resulted positive on Alcian blue staining at pH 2.5. **d** Immunohistochemical analysis showed positivity of the lymphoid elements for CD3.