



# Femoral Fixation With Curve Cross-Pin System in Arthroscopic Posterior Cruciate Ligament Reconstruction

Ezio Adriani, M.D., Berardino Di Paola, M.D., Andrea Alfieri, M.D., and Edoardo De Fenu, M.D.

**Abstract:** Posterior cruciate ligament (PCL) ruptures account for 1% to 44% of all acute ligament injuries of the knee. In this paper we wanted to try out a system for femoral fixation. Hamstring tendons are harvested and standard tibial tunnel is prepared using the transtibial PCL guide; by identifying the PCL footprint, the femoral half tunnel 27 to 30 mm with in-out technique is performed. The femoral rod of a curve cross-pin system is inserted into the anterolateral access within the femoral half tunnel. The guide block is placed 2.5 cm anterior (in a coronal plane) and 2.5 cm proximal to the lateral epicondyle. The arc attachment is assembled and the bone stock assessed with the bone gauge pin in contact with the cortex of the medial femoral condyle. Then the first sleeve over trocar is assembled, and the graft is passed through the tunnel and fixed on the femur with the pins and on the tibia with interferential screw. After biomechanical studies we obtained a maximum load at 930.95 N and maximum stiffness at 58.92 N/mm.

Posterior cruciate ligament (PCL) ruptures account for 1% to 44% of all acute ligament injuries of the knee. Sixty percent of PCL tears are caused by sport injuries and 25% by road accidents.<sup>1</sup>

The interest in PCL reconstruction has increased over the years as evidence showing that PCL deficiency is often associated with meniscal and cartilage degeneration has emerged. Furthermore, the number of studies reporting on the results of surgical reconstruction of isolated PCL tears or combined lesions has grown. Several factors can affect the outcome of PCL reconstruction surgery such as tunnel positioning, tibial and femoral fixation, and graft choice.<sup>2-5</sup>

While the choice of the surgical technique (inlay vs transtibial) will not be addressed in this paper, the choice of the graft material and the fixation technique will be tackled as they are an essential part of the pre-operative planning. Currently, quadruple hamstring graft is the most commonly used autograft thanks to its length and mechanical properties, large cross-sectional area, low donor site morbidity, and greater ease of passage in the joint due to the absence of bone blocks.<sup>6</sup> Finally, it does not damage the extensor mechanism of the knee, which is considered the main PCL agonist. As with anterior cruciate ligament (ACL) reconstruction, graft fixation is paramount in PCL reconstruction surgery, although it still accounts for the weak link. Appropriate fixation must provide biomechanical support between the graft and the bone in the early post-operative period and until graft incorporation.<sup>7</sup> However, the techniques used for PCL graft fixation were originally developed for ACL reconstruction. Hoehner et al.<sup>6</sup> have classified the femoral fixation techniques as follows:

1. Anatomic: when graft fixation is achieved close to anatomic insertion site of the ligament with a metal or bioabsorbable interference screw, and
2. Extra-anatomic: when the graft is fixed far from the ligament attachment site with an endobutton, a staple, or a screw and washer.

From the Mater Dei Clinic (E.A., B.D.P., A.A.) and Policlinico Umberto I (E.D.F.), Rome, Italy.

The authors report the following potential conflicts of interest or sources of funding: E.A. receives support from Depuy. Full ICMJE author disclosure forms are available for this article online, as [supplementary material](#).

Received July 21, 2017; accepted September 22, 2017.

Address correspondence to Ezio Adriani, M.D., Mater Dei Clinic Rome, Department of Orthopaedics, Bertoloni 34, Rome 00197, Italy. E-mail: [ezioadriani@gmail.com](mailto:ezioadriani@gmail.com)

© 2017 by the Arthroscopy Association of North America. Published by Elsevier. This is an open access article under the CC BY-NC-ND license (<http://creativecommons.org/licenses/by-nc-nd/4.0/>).

2212-6287/17886

<https://doi.org/10.1016/j.eats.2017.09.004>

Recently, hybrid systems were introduced implying 2 different fixation techniques. Niedzwietzki et al.<sup>1</sup> have shown that hybrid femoral fixation (extracortical + anatomic) is biomechanically superior to either technique when used individually. Other investigators have highlighted the mechanical properties of transverse femoral fixation in ACL reconstruction. In 2004, In et al.<sup>8</sup> suggested the use of a cross-pin system for femoral fixation in PCL reconstruction. The authors of that study drilled the femoral tunnel using the in-out technique, which involves placing the guide pin for the cannulated reamer 8 mm proximal to the cartilage of the medial femoral condyle. The femoral tunnel was drilled at a diameter of 8 mm and to a depth of 35 mm. The graft was then fixed with Rigidfix (Mitek, Norwood, MA) by inserting the guide through the anterolateral portal. Later, Rossi et al.<sup>9</sup> reported in a cadaver study a high risk of iatrogenic damage associated with this technique. During dissection, the cartilage of the medial condyle was damaged and the investigators recommended care in the use of this technique. The Rigidfix curve cross-pin system (Mitek) was recently introduced for ACL fixation. The system involves drilling the femoral half tunnel through the anteromedial portal.

In this paper we illustrate the use of a curve cross-pin system for the femoral fixation of the PCL graft in cadaver knees as we believe that transverse fixation can be used successfully also for PCL reconstruction. The advantage over the conventional technique is that after introducing the guide through the anterolateral portal, the pins to fix the graft are introduced in the femoral tunnel in a retrograde fashion beginning at the lateral

condyle, thereby preventing iatrogenic damage to the medial femoral condyle.

## Surgical Technique

### Preparation of the Hamstring Autograft

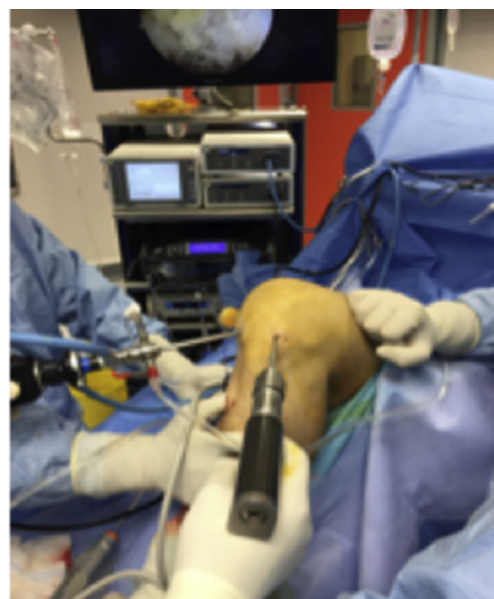
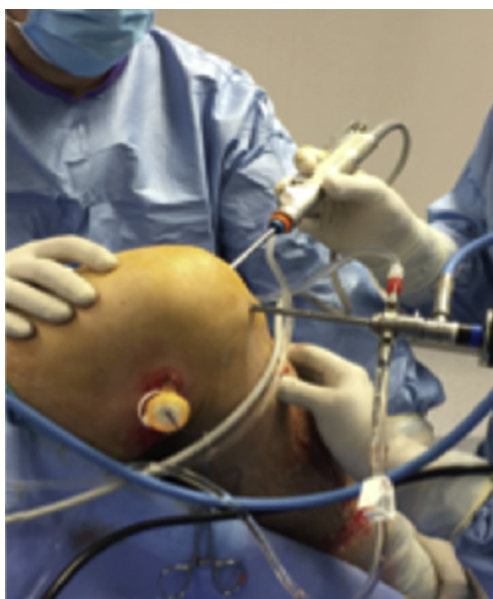Through a skin incision over the pes anserinus the hamstring tendons are harvested. The residual muscle tissue is removed. The tendons are quadrupled and placed on a graft preparation station. A high-strength nonabsorbable suture (Othocord no. 2, Mitek; or Fiberwire no. 5, Arthrex, Naples, FL) is attached to the proximal loop of the graft. The loop is then whip stitched with vicryl no. 2 to tubularize the graft. The 4 ends of the graft are prepared with vicryl no. 2. Using a surgical marking pen, the graft is marked at 30 mm from the apex of the loop where the passing suture is attached. The graft diameter is then measured.

### Portals

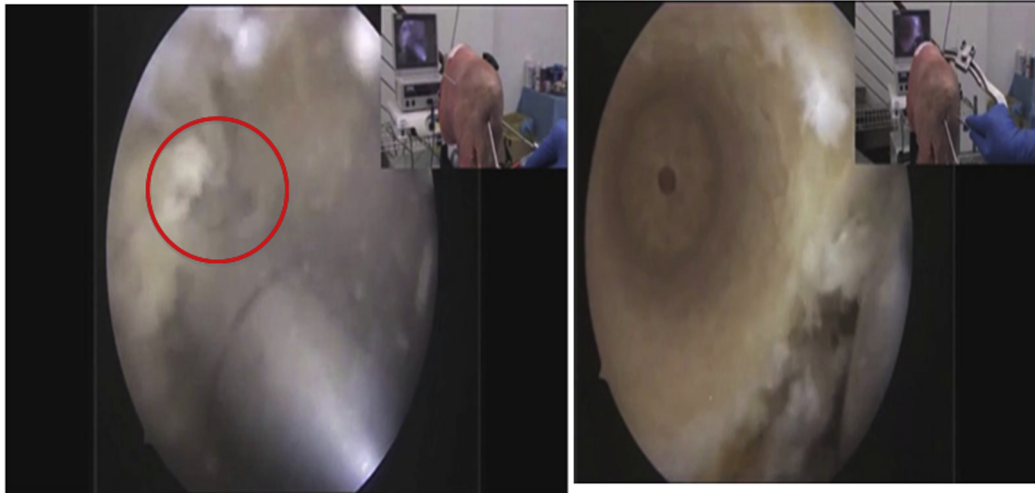
The anteromedial parapatellar portal is established. The anterolateral portal is then established slightly lower than normal to drill the femoral tunnel with the in-out technique. The posteromedial portal is finally established to visualize the PCL tibial attachment site.

### Joint Preparation

The arthroscope is placed through the anterolateral portal and the shaver through the anteromedial portal to debride the remnants of the femoral attachment of the PCL. The arthroscope is then shifted to the anteromedial portal and the shaver to the posteromedial portal to remove the remnants of the tibial attachment.



**Fig 1.** Cadaver left knee, supine position, knee positioned at 90°. The femoral half tunnel is drilled in-out: with the arthroscope in the anteromedial portal, the femoral half tunnel is drilled from the anterolateral portal.



**Fig 2.** Cadaver left knee, supine position, knee positioned at 90°. The femoral half tunnel is drilled to a depth of 27 to 30 mm.

### Tibial Tunnel Drilling

The tibial tunnel is drilled using the TransTibial PCL guide and a cannulated reamer sized equal to the diameter of the graft. A high-strength nonabsorbable passing suture is placed in the tibial tunnel.


### Femoral Half Tunnel Drilling

The native PCL footprint is identified on the lateral surface of the medial femoral condyle. The femoral aimer is placed through the lower anterolateral portal, and the femoral half tunnel is drilled in-out with a cannulated reamer matching the diameter of the graft (Fig 1, Video 1). The femoral half tunnel is drilled to a depth of 27 to 30 mm to accommodate the curve guide (Fig 2).

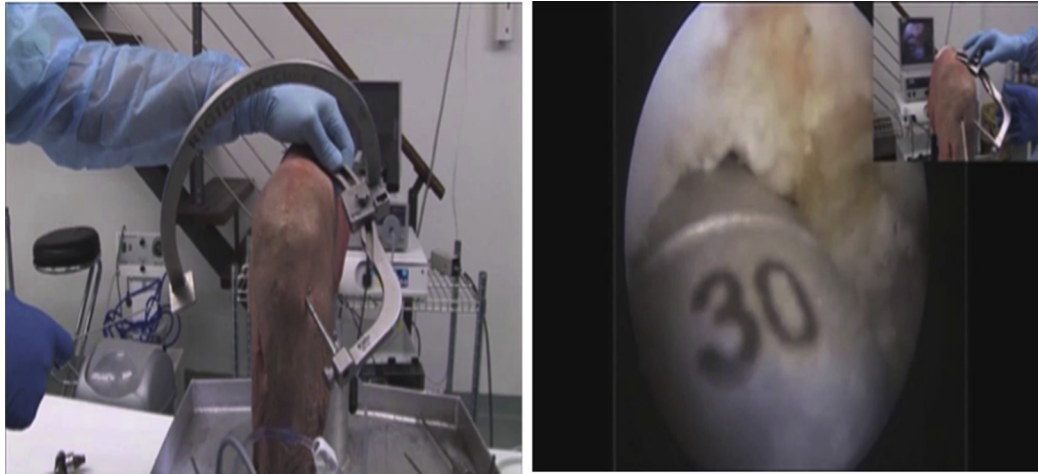
### Fixation Preparation With a Curve Cross-Pin System

The curve guide is assembled (Video 1). The guide block and the femoral rod are attached to the guide

frame. The femoral rod size should match the femoral tunnel diameter (Fig 3). With the arthroscope in the anteromedial portal the guide frame is inserted through the lower anterolateral portal. The femoral rod is then inserted in the femoral half tunnel until the 30 mm marking is reached (Fig 4). At this stage, the guide block must be accurately placed on the lateral femoral condyle to insert the trocars, the sleeves, and the pins (Video 1). The same technique used for ACL reconstruction and tested on anatomical samples was used here. The guide block is placed 2.5 cm anterior (in a coronal plane) and 2.5 cm proximal to the lateral epicondyle (Fig 5, Video 1). The arc attachment is assembled, and the bone stock assessed with the bone gauge pin in contact with the cortex of the medial femoral condyle. The medial bone stock is the distance between the tip of the pin and the medial femoral condyle cortex (Fig 6,



**Fig 3.** The curve guide is assembled. The guide block and the femoral rod are attached to the guide frame. The femoral rod size should match the femoral tunnel diameter.



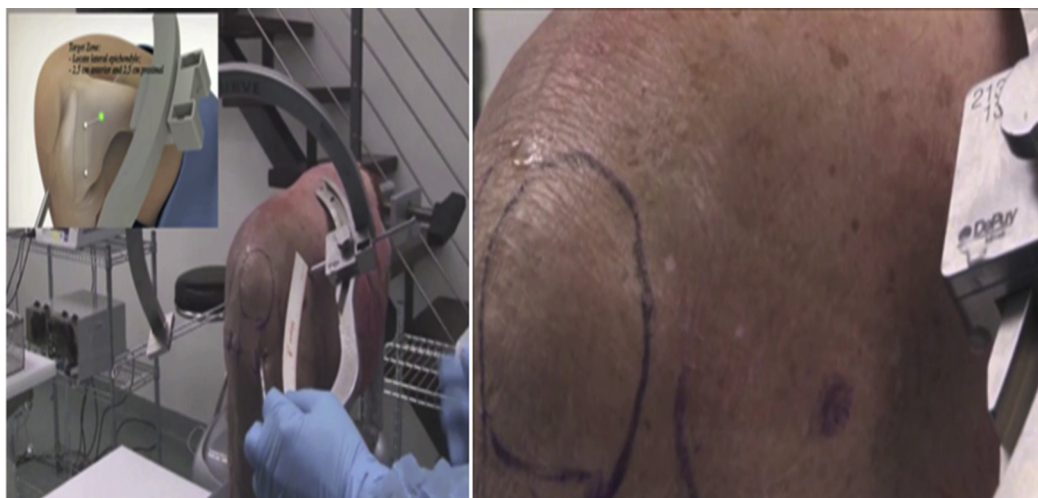**Fig 4.** Cadaver left knee, supine position, knee positioned at 90°. With the arthroscope in the anteromedial portal, the guide frame is inserted through the lower anterolateral portal. The femoral rod is then inserted in the femoral half tunnel until the 30 mm marking is reached.

**Video 1)** if the laser line on the bone gauge pin is visible to ensure there is sufficient bone stock; if the laser line is not visible, then slightly adjust the guide block position up or down on the frame and/or rotate the guide frame about the tunnel axis (**Video 1**). If the bone stock acceptable, assemble the first sleeve over the trocar. The trocars are inserted starting at the lateral femoral condyle and aiming downward and lateral medially (**Fig 7**). During this phase, it is preferable to leave the bone gauge pin for greater stabilization of the guide frame (**Video 1**). A passing suture is then placed through the femoral rod size (**Video 1**). The bone gauge pin is inserted through the trocars to confirm the correct centered position of the pin within the half tunnel under arthroscopic visualization (**Fig 8, Video 1**). A possible problem the

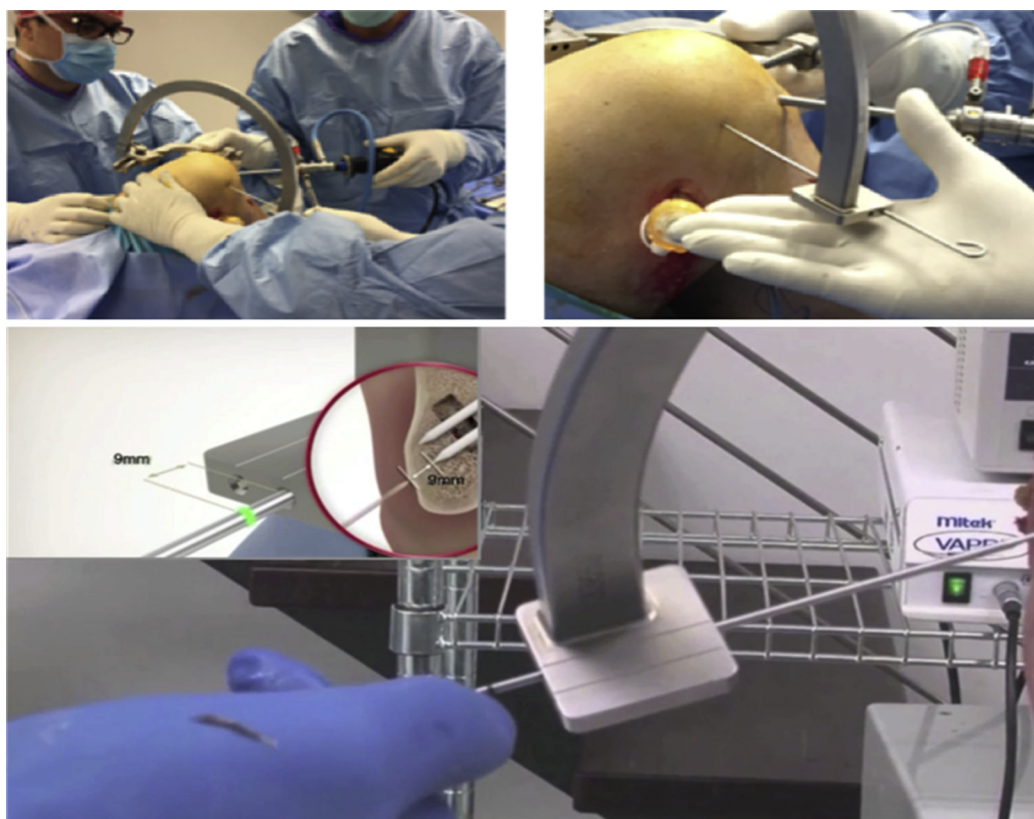
surgeon may have is with individuals with large muscle masses because the guide frame may conflict with the thigh of the patient. This can be solved with a resized guide frame that presents a shorter arm (**Fig 9**).

#### Graft Passage

The tibial and femoral passing sutures are retrieved through the anterolateral portal. A loop is formed in the femoral passing suture, and the tibial passing suture is inserted through it. The loop containing the tibial passing suture is pulled out of the femoral tunnel as a single passing suture. (**Video 1**). The graft is placed on the passing suture at the entrance of the tibial tunnel and passed through it with the assistance of a blunt instrument placed in the posteromedial portal (**Fig 10**).



**Fig 5.** Cadaver left knee, supine position, knee positioned at 90°. Target zone: the guide block is placed 2.5 cm anterior (in a coronal plane) and 2.5 cm proximal to the lateral epicondyle.



**Fig 6.** Cadaver left knee, supine position, knee positioned at 90°. The arc attachment is assembled, and the bone stock assessed with the bone gauge pin in contact with the cortex of the medial femoral condyle. The medial bone stock is the distance between the tip of the pin and the medial femoral condyle cortex.

### Femoral Fixation

The graft is fixed on the femur with the pins making sure that the laser line is flush with the trocar (Fig 11, Video 1).

### Tibial Fixation

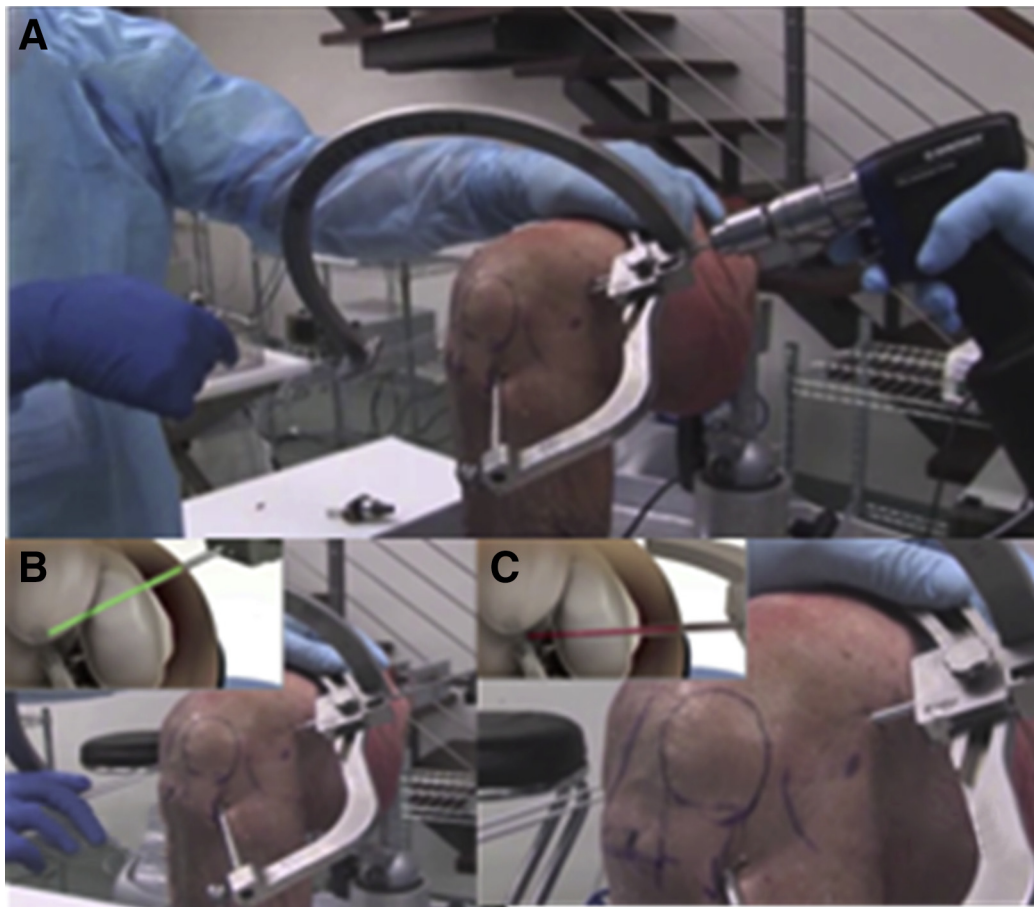
The knee is cycled through flexion and extension to condition the graft. With the knee at 70° of flexion, the graft is fixed using an interference screw 2 mm larger than the graft diameter while performing an anterior drawer maneuver.

The postoperative rehabilitation protocol implies partial weight bearing with a brace locked in extension. The brace we recommend has a posterior pad to support the calf and reduce the effect of gravity on the graft. We prefer not to mobilize the knee for 7 days and start progressive recovery of range of motion with continuous passive motion machine use for 4 to 5 weeks and muscle strengthening exercises.

### Discussion

The techniques used for PCL graft fixation were originally developed for ACL reconstruction and then adapted to PCL reconstruction. Biomechanical requirements of the PCL differ from those of the ACL and so

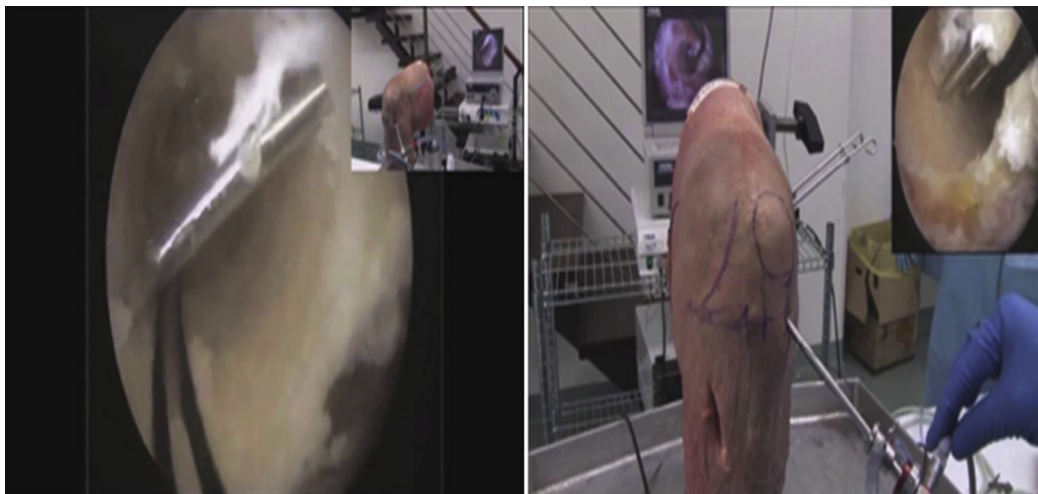may the fixation techniques.<sup>1,6</sup> The main differences relate to graft length, angulation of the graft at the bone tunnels, bone tunnel length, and tunnel bone quality for fixation purposes. In vitro and in vivo studies assessing the forces of the intact PCL are and will be essential to develop PCL-specific fixation systems. Today we know that the PCL is the main structure hampering the posterior translation of the tibia.<sup>6</sup> The forces in the PCL are determined by the degree of flexion and are greater above 90°, even though the PCL bundles are affected differently. The anterolateral bundle is more affected at 90° of flexion and less during extension; the posteromedial bundle is more affected by extension and full flexion.<sup>10</sup> The forces in the native PCL and the graft also depend on the posterolateral structures of the knee. Such forces increase by 30% with early flexion when the posterolateral structures of the knee are not intact.<sup>11,12</sup> The activity of the femoral biceps and the effect of gravity—which lowers the proximal tibia loading the PCL—can also play a role. Assessing how the graft is loaded during daily activity and rehabilitation is, however, more difficult. Morrison<sup>13</sup> has determined that the peak load on the PCL during gait amounts to 330 N. Zheng et al.<sup>14</sup> have estimated that the peak load reached with extension is 950 N and increases to 1,860 N



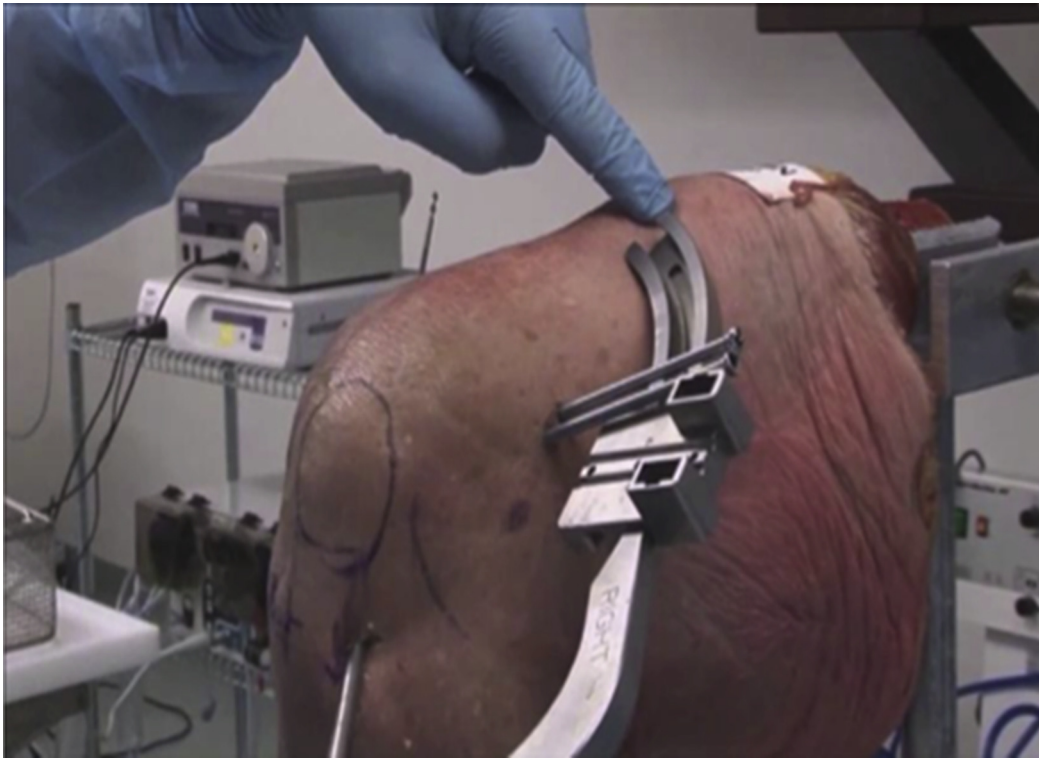**Fig 7.** Cadaver left knee, supine position, knee positioned at  $90^\circ$ . Place the trocars for the pins from lateral to medial (A). Take care to move with the drill directed from above downward (B) in order to avoid the possible protrusion in the intercondylar notch (C).

during the squat and leg press. Toutongi et al.<sup>15</sup> suggest that load can reach up to 2,500 N during the squat. Unlike ACL reconstruction, the strength requirements for PCL

graft fixation are not fully known. Consequently, it is essential to protect the graft by performing a plasty of the posterolateral structures of the knee, limiting flexion to



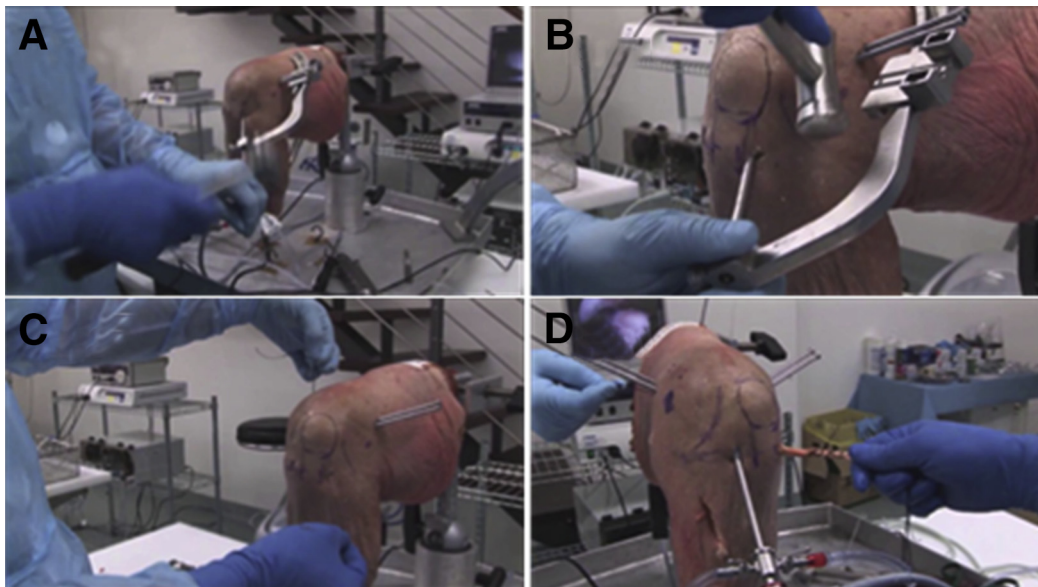
**Fig 8.** Cadaver left knee, supine position, knee positioned at  $90^\circ$ . The bone gauge pin is inserted through the trocars to confirm the correct centered position of the pin within the half tunnel.



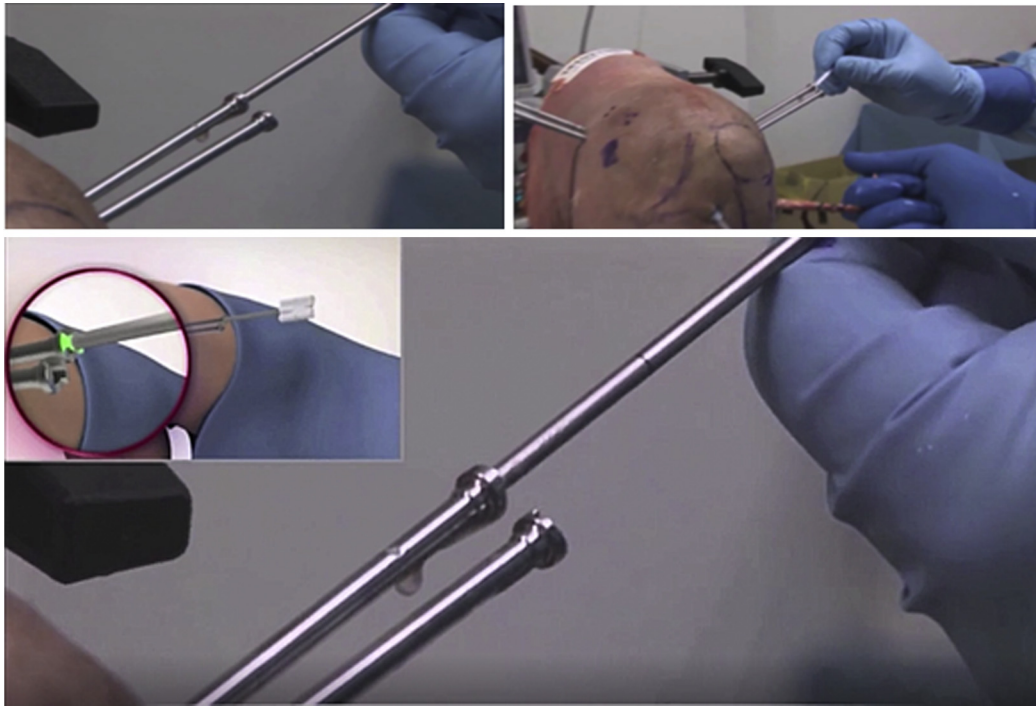
**Fig 9.** Cadaver left knee, supine position, knee positioned at 90°. Individuals with large muscle masses present a possible problem because the guide frame may conflict with the thigh of the patient. This can be solved with a resized guide frame that presents a shorter arm.

30° and isometric exercise in the early postoperative period, reducing the effect of gravity by applying a posterior support to the tibia.<sup>11</sup>

As with ACL fixation techniques, PCL fixation methods imply numerous variables that make a comparison between currently available studies difficult.



**Fig 10.** Cadaver left knee, supine position, knee positioned at 90°. The guide wire is passed through the femoral tunnel (A). The guide frame is removed (B). A passing suture is then placed through the femoral rod size. A loop is formed in the femoral passing suture, and the tibial passing suture is inserted through it. The loop containing the tibial passing suture is pulled out of the femoral tunnel as a single passing suture (C). The graft is placed (D) on the passing suture at the entrance of the tibial tunnel and passed through it with the assistance of a blunt instrument placed in the posteromedial portal.



**Fig 11.** Cadaver left knee, supine position, knee positioned at 90°. The graft is fixed on the femur with the pins making sure that the laser line is flush with the trocar.

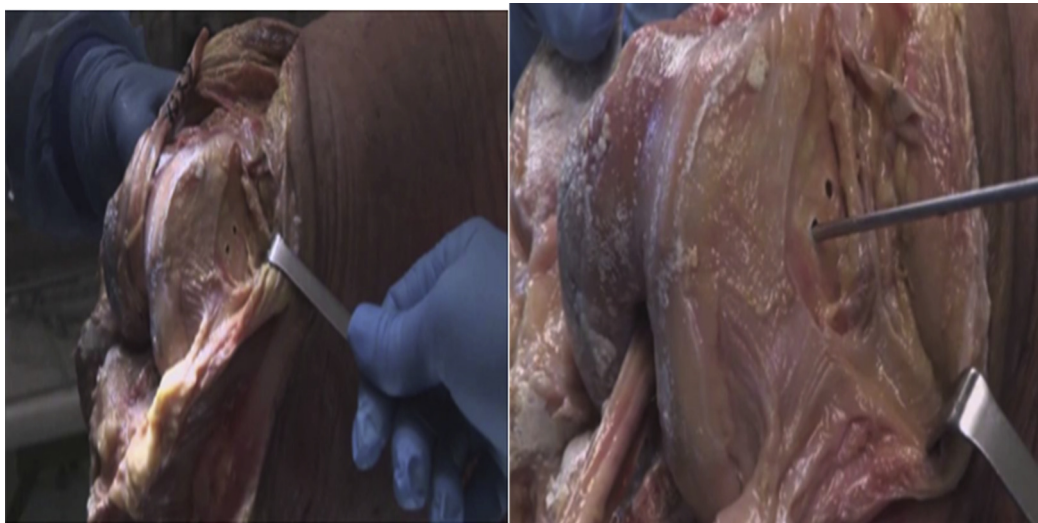Such variables are samples used for the tests (cadaver bone, swine bone, bovine bone, all with different bone density), age of the sample, and loading conditions. Consequently, there are some features that must be taken into due account when selecting a fixation system, that is, pullout strength, stiffness, elongation strength and sliding, ability to foster graft healing and incorporation, and ease of revision.<sup>10,15</sup>

We consider such characteristics as “prerequisites” for an ideal fixation system. For this reason we used the

Rigidfix system in transtibial ACL reconstruction and the Rigidfix curve system with the anteromedial technique. The Rigidfix system includes 2 poly-l-lactic acid or PEEK (polyether ether ketone) pins with a yield strength of 930.95 N.

On top of the characteristics previously mentioned, we like the cross-pin fixation of the Rigidfix system for its superior biomechanical properties.

In et al.<sup>8</sup> have already suggested the use of the standard 3.3 mm Rigidfix system for PCL fixation. In 12



**Fig 12.** Cadaver left knee, supine position, knee positioned at 90°. This technique avoids the involvement of noble structures in the lateral portion of the knee, in particular the proximal insertion of the lateral collateral ligament.



**Table 1.** Advantages and Disadvantages of the Technique

## Advantages

- No pins conflict with external “noble” structures or articular cartilage (Fig 12).
- Biomechanical seal suitable for fixing posterior cruciate ligament (PCL).
- It is a reproducible technique with a relatively short learning curve.
- It offers the advantage of transverse fixation and without disturbing elements for the biological integration of the graft through a 360° graft-bone contact of the tunnel.
- Fixation close to the articular rhyme and absence of bungee effect of the graft.
- Suitable for all soft-tissue grafts (auto or allograft).
- Possible use for femoral fixation of both anterior cruciate ligament (ACL) and PCL in double-cross reconstructions.
- It does not interfere with accessory actions on the knee involving lateral or medial structures.
- No interference with revision procedures (reusable pins that do not need to be removed).

## Disadvantages

- Not suitable with double bundle.
- Risk of protrusion pins from cortical medial femoral condyle.
- Not suitable if the femoral half tunnel is shallow: it requires at least 27 mm of depth.
- Risk of conflict for the guide in patients with large muscle mass with relative difficulty in positioning the sleeves for the pins.
- Not suitable with grafts involving bone in the half femoral tunnel.
- After ACL reconstruction, there have been some case reports describing the breaking of the cross pin resulting in its joint migration (poly-l-lactic acid pin): to avoid this risk we suggest using the PEEK (polyether ether ketone) pin.

cadaver knees, the investigators drilled a bone tunnel with a diameter of 8 mm and length of 35 mm. The tunnel was drilled 8 mm proximal to the articular surface of the medial femoral condyle in the 2 o'clock position for the right knees and the 10 o'clock position for the left knees. The guide was inserted through the anterolateral portal. In 2007, in a similar study on 22 cadaver knees, Rossi et al.<sup>9</sup> assessed the iatrogenic damage that was possibly caused by the Rigidfix system. The investigators drilled the femoral tunnel following the technique described by In et al. The guide was inserted through the anterolateral portal with an angle of 0°, 45°, and 90° relative to the horizontal plane. The authors of that study reported a 75% risk of cartilage damage when the guide was used with a 0° angle, 85% risk with an angle of 45°, and 100% risk with an angle of 90°. The damage was related to the use of at least one trocar placed on the articular surface of the medial femoral condyle. To avoid such risk, In et al.<sup>8</sup> suggest

palpating the femoral condyle and adjusting the pin insertion. However, once the femoral tunnel is drilled, the surgeon is left with little freedom to vary the position of the guide.

The trocars for the pins are placed on the lateral femoral condyle, and the PCL femoral tunnel is reached in a retrograde fashion thereby avoiding damage to the articular surface. The risk of damage is further reduced by measuring the medial bone stock, that is, the distance between the tip of the pin and the cortex and/or cartilage of the medial condyle. In our cadaver study, we also analyzed the trajectory of trocar placement in the lateral soft tissues after accurate dissection. The trocar was inserted slightly obliquely and aiming downward starting at a point above the coronal plane of the femur to bypass important structures. As pointed out by Clark et al.<sup>16</sup> cross-pin fixation provides good biomechanical properties and is not associated with the risk of tunnel widening—as is the case with the

**Table 2.** Pearls and Pitfalls of the Technique

Pearls and Pitfalls
Excessively horizontal tunnel can reduce medial bone stock and increase the risk of cross-pin protrusion.
The insertion of the pin sleeves must take place from the lateral condyle upstream to reduce the risk of protrusions in the intercondylar fossa or in the back of the knee.
If the laser line on the gauge pin is not visible, it indicates that the bone stock is not suitable to avoid pin's protrusion risk from the medial cortical/medial femoral condyle. You can correct this element working on the direction of the guide block.
Always check the position of the pin with the half tunnel with arthroscopic vision: if incorrect, corrections may be made with 3 approaches: <ul style="list-style-type: none"> <li>Repositioning the guide</li> <li>Varying the angles of the guide block</li> <li>Working freehand</li> </ul>
There may be a risk of conflict between the guide and the thigh muscle structures as in the reconstruction of the anterior cruciate ligament. In part, this problem has been solved by adopting shorter guides, partly solved by making sure that you do not create tunnels that are too horizontal, which would also reduce the bone stock medial.
The graft is fixed on the femur with the pins making sure that the laser line is flush with the trocar: do not overdrive the cross pins to avoid the risk of protrusion.
The guide must be inserted accurately into the tunnel in depth, otherwise the risk of protrusion of the articulated pin will increase.

extracortical systems—or graft damage caused by the interference screws that would compromise the graft incorporation and healing. Furthermore, the system prevents iatrogenic damage to the articular surface of the medial femoral condyle.

This technique avoids the involvement of noble structures in the lateral portion of the knee (in particular the proximal insertion of the lateral collateral ligament) as demonstrated on astronauts (Fig 12).

The reduction of the biomechanical holding of the pins represents one of the main risks of this technique. This adverse event can happen when the pin does not cross the femoral tunnel centrally or if the pin breaks. The pin trajectory in the bone tunnel can be easily controlled arthroscopically before the introduction and eventually corrected (Fig 8).

Some case reports described the break of the cross pin after ACL reconstruction and the consequent migration in the joint.<sup>17</sup> The bioabsorbable device can become weaker during in vivo clinical settings, and, if abnormally stressed, it can break. We recommend the use of a PEEK, according to our current practice, to avoid this adverse event. The main limitation of using this system is that it cannot be used to fix grafts with bone block (Tables 1 and 2).

## References

1. Niedzwietzki P, Zantop T, Weimann A, Herbolt M, Raschke MJ, Petersen W. Femoral fixation of hamstring grafts in posterior cruciate ligament reconstruction: biomechanical evaluation of different fixation techniques is there an acute angle effect? *Am J Sports Med* 2007;35:780-786.
2. Barrett GR, Savoie FH. Operative management of acute PCL injuries with associated pathology: long term results. *Orthopedics* 1991;14:687-692.
3. Fanelli GC, Edson CJ. Posterior cruciate ligament injuries in trauma patients: part II. *Arthroscopy* 1995;11:526-529.
4. Lipscomb AB, Anderson AF, Norwig ED, Hovis WD, Brown DL. Isolated posterior cruciate ligament reconstruction: long-term results. *Am J Sports Med* 1993;21:490-496.
5. Voos JE, Mauro CS, Wentz T, Warren RF, Wickiewicz TL. Posterior cruciate ligament: anatomy, biomechanics, and outcomes. *Am J Sports Med* 2012;40:222-231.
6. Hoehner J, Scheffler S, Weiler A. Graft choice and graft fixation in PCL reconstruction. *Knee Surg Sports Traumatol Arthrosc* 2003;11:297-306.
7. Shelbourne KD, Nitz P. Accelerated rehabilitation after anterior cruciate ligament reconstruction. *Am J Sports Med* 1990;18:292-299.
8. In Y, Bahk WJ, Kwon OS. Cross-pin femoral fixation for hamstring posterior cruciate ligament reconstruction. *Arthroscopy* 2004;20:29-33.
9. Rossi R, Bonasia DE, Assom M, Bruzzone M, Castoldi F. Cross-pin femoral fixation in PCL reconstruction: a cadaver study. *Knee Surg Sports Traumatol Arthrosc* 2007;15:1194-1197.
10. Markolf KL, Zemanovic JR, Mc Allister DR. Cyclic loading of posterior cruciate ligament replacements fixed with tibial tunnel and tibial inlay methods. *J Bone Joint Surg Am* 2002;84:518-524.
11. Harner CD, Vogrin TM, Höher J, Ma CB, Woo SL. Biomechanical analysis of a posterior cruciate ligament reconstruction. Deficiency of the posterolateral structures as a cause of graft failure. *Am J Sports Med* 2000;28:32-39.
12. Vogrin TM, Höher J, Aroen A, Woo SL, Harner CD. Effects of sectioning the posterolateral structures on knee kinematics and in situ forces in the posterior cruciate ligament. *Knee Surg Sports Traumatol Arthrosc* 2000;8:93-98.
13. Morrison JB. Mechanics of the knee joint in relation to normal walking. *J Biomech* 1970;3:51-61.
14. Zheng N, Llesig GS, Escakmilla RF, Barrentine SW. An analytical model of the knee for estimation of internal forces during exercise. *J Biomech* 1998;31:963-967.
15. Toutongji DE, Lu TW, Leardini A, Catani F, O'Connor JJ. Cruciate ligament forces in the human knee during rehabilitation exercises. *Clin Biomech* 2000;15:176-187.
16. Clark R, Olsen RE, Larson BJ, et al. Cross-pin femoral fixation: a new technique for hamstring anterior cruciate ligament reconstruction of the knee. *Arthroscopy* 1998;14:258-267.
17. Han I, Kim YH, Yoo JH, Seong SC, Kim TK. Broken bioabsorbable femoral cross-pin after anterior cruciate ligament reconstruction with hamstring tendon graft: a case report. *Am J Sports Med* 2005;33:1742-1745.