

# Oral tacrolimus for severe recalcitrant eosinophilic cellulitis



Mirmovich Morvay, MD,<sup>a</sup> Reuven Bergman, MD,<sup>a,b</sup> and Emily Avitan-Hersh, MD, PhD<sup>a,b</sup>  
Haifa, Israel

**Key words:** eosinophilic cellulitis; tacrolimus; Wells syndrome.

## INTRODUCTION

Eosinophilic cellulitis (EC) is an uncommon benign inflammatory dermatosis, primarily described by Wells in 1971 as “recurrent granulomatous dermatitis with eosinophilia.”<sup>1</sup> Despite its benign nature, EC has a significant deleterious effect on quality of life due to severe pruritus in many cases. Systemic corticosteroids are commonly used as the first-line therapy.<sup>2</sup> Prolonged therapy however is limited due to significant side effects. Other treatment modalities include cyclosporine, dapsone, antihistamines, interferon alfa/gamma, anti-tumor necrosis factor-alfa, psoralen plus ultraviolet A, colchicine, antimalarials, azathioprine, minocycline, and griseofulvin.<sup>2</sup> All of these adjuvants have limited efficiency and some cases are refractory. Tacrolimus is a calcineurin immunomodulator, used mainly to prevent organ transplant rejection.<sup>3</sup> It has rarely been used as an adjuvant in several dermatologic conditions including plaque psoriasis, pyoderma gangrenosum, Behcet disease, Sezary syndrome (cutaneous T cell lymphoma), and cutaneous graft-versus-host disease.<sup>4</sup> One report has described a favorable outcome of EC after cotreatment with corticosteroids and oral tacrolimus.<sup>5</sup> We report herein the case of a 43-year-old female with recurrent, longstanding, and recalcitrant EC, treated successfully with oral tacrolimus.

## CASE REPORT

A 43-year-old female presented to our clinic with multiple erythematous, edematous infiltrated plaques, some with annular configuration and raised borders, located on the trunk and extremities (Fig 1). Her history was significant for hypothyroidism, hyperlipidemia, obesity, and previous excision of a

### Abbreviation used:

EC: eosinophilic cellulitis

carcinoid tumor of the appendix. Nineteen years prior to admission, she was diagnosed with EC but was lost to follow up. Previous treatments included topical and oral corticosteroids (prednisone 40 mg/d), dapsone (200 mg/d), and azathioprine (200 mg/d), with no relief. Treatment was discontinued and the patient later experienced spontaneous remission that lasted almost 2 decades. Several months before her admission, an exacerbation occurred, with the reappearance of widespread annular plaques on the trunk and extremities, accompanied by severe pruritus. The differential diagnosis included eosinophilic annular erythema and recurrence of EC. Upon admission, a 4-mm punch biopsy was performed. The pathologic examination revealed throughout the dermis a dense perivascular and interstitial infiltrate of mononuclear cells and numerous eosinophils with several “flame figures,” consistent with EC (Figs 2 and 3). Laboratory evaluation revealed normal blood eosinophil counts and IgE levels. Results of additional tests such as serum protein electrophoresis, immunoglobulin, and complement tests, and serological tests for antinuclear antibodies and antineutrophil cytoplasmic antibodies were within normal limits. Pulmonary function tests and echocardiography showed no abnormalities. Treatment with oral prednisone 1 mg/kg/day (80 mg daily) in combination with oral methotrexate (17.5 mg/week) failed to induce remission. Methotrexate was withdrawn, and oral cyclosporine (500 mg/d) was initiated with complete remission.

From the Department of Dermatology, Rambam Health Care Campus, Haifa, Israel<sup>a</sup> and Bruce Rappaport Faculty of Medicine, Technion Institute of Technology, Haifa, Israel.<sup>b</sup>

Funding sources: None.

Conflicts of interest: None disclosed.

IRB approval status: Not applicable.

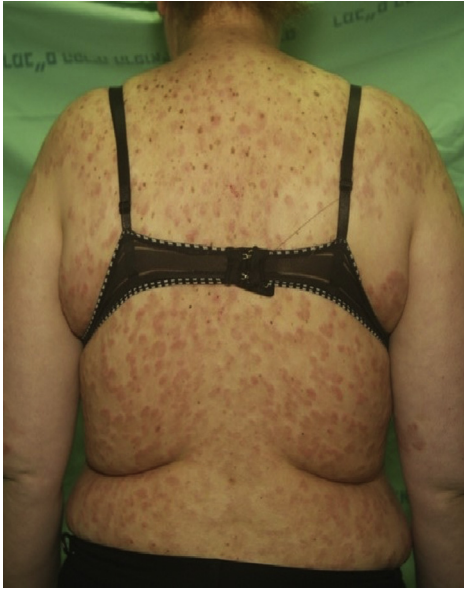Correspondence to: Mirmovich Morvay, MD, HaAliya HaShniya St 8, Haifa, Israel, 3109601. E-mail: [orna.mir@gmail.com](mailto:orna.mir@gmail.com).

JAAD Case Reports 2020;6:1211-3.

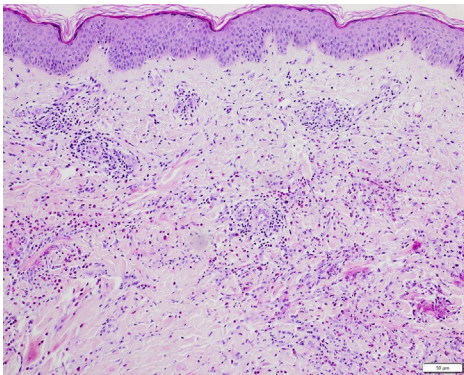
2352-5126

© 2020 Published by Elsevier on behalf of the American Academy of Dermatology, Inc. This is an open access article under the CC BY-NC-ND license (<http://creativecommons.org/licenses/by-nc-nd/4.0/>).

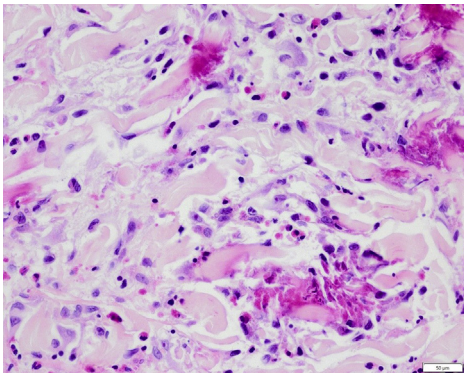
<https://doi.org/10.1016/j.jidcr.2020.10.008>



**Fig 1.** Multiple erythematous, edematous infiltrated plaques, some with annular configuration and raised borders, located on the trunk and extremities.



**Fig 2.** The pathologic examination revealed a dense perivascular and interstitial infiltrate of mononuclear cells and numerous eosinophils with several "flame figures" throughout the dermis, consistent with EC. (Hematoxylin-eosin stain; original magnification:  $\times 100$ ).



**Fig 3.** Higher magnification of a "flame figure" (Hematoxylin-eosin stain; original magnification:  $\times 600$ ).

However, hypertension and hirsutism ensued; therefore, prednisone and cyclosporine were gradually tapered. Six months later, while on cyclosporine, the patient experienced a relapse with reappearance of new lesions, sleep disturbance, pruritus, and general fatigue. Cyclosporine was substituted by mycophenolate mofetil (2 g/d) in combination with prednisone (40 mg/d), to no avail. The patient was then started on oral tacrolimus (3 mg twice daily) in combination with a minimal dosage of oral prednisone (5 mg/d) due to "steroid-induced adrenal insufficiency." After two weeks, a rapid and dramatic response was noticed, with flattening of all active lesions, followed by complete remission shortly afterward (Fig 4) and disappearance of the pruritus.

During the following year, the patient was closely monitored, and the tacrolimus dosage was tapered down and terminated after 2 years. The patient remained disease free, and no relapse occurred after an additional year of follow-up.

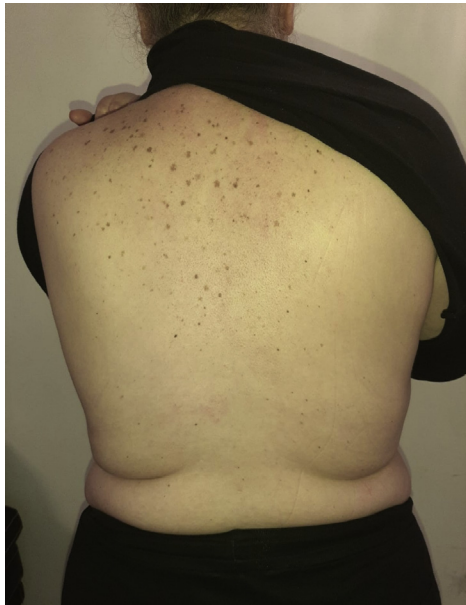## DISCUSSION

EC is a rare inflammatory disorder of unknown etiology. It is characterized clinically by edematous, erythematous papules and plaques and occasionally by vesicles and bullae accompanied by itching and burning sensation. Older resolving lesions can have a morphea-like appearance. Upon resolution, no scarring is left.<sup>6</sup> Systemic nonspecific symptoms such as fever, arthralgia, and malaise may occur.<sup>7</sup>

Early lesions show histopathologically superficial dermal edema combined with a mid- and deep-dermal eosinophilic infiltrates. Later on, the degranulation of eosinophils results in the characteristic "flame figures" that engulf collagen fibers. Older lesions are characterized by a decreasing number of eosinophils but prominent presence of histiocytes and giant cells surrounding the remaining "flame figures."<sup>2</sup>

The natural course of EC is variable; spontaneous resolution can occur after several weeks, but frequent relapses and a protracted course is not uncommon.

Due to its rarity, no randomized controlled therapeutic trials are available, and the treatment is based mostly on small case series and case reports. A variety of treatments have been suggested due to the lack of one efficient therapy.<sup>2,6</sup> Systemic and topical tacrolimus have been rarely used for the treatment of EC.<sup>5,8</sup> Notably, tacrolimus and cyclosporine both efficiently inhibit eosinophil proliferation and interleukin 5 messenger RNA levels.<sup>9</sup> However, tacrolimus (Fk-506) inhibits interleukin 5 messenger RNA levels at lower concentrations. Newer antieosinophilic



**Fig 4.** Complete remission at 1 year following treatment termination.

agents may prove to be effective and should be used in the future.<sup>10</sup>

We present a case of recalcitrant EC with a protracted course, resistant to multiple treatment modalities, which ultimately responded dramatically to oral tacrolimus. Remission has been sustained for

3 years now. We suggest that oral tacrolimus may be considered as part of the armamentarium for recalcitrant EC.

#### REFERENCES

1. Wells CG. Recurrent granulomatous dermatitis with eosinophilia. *Trans St Johns Hosp Dermatol Soc.* 1971;57(1):46-56.
2. Räßler F, Lukács J, Elsner P. Treatment of eosinophilic cellulitis (Wells syndrome) - a systematic review. *J Eur Acad Dermatol Venereol.* 2016;30(9):1465-1479.
3. Scott LJ, McKeage K, Keam SJ, Plosker GL. Tacrolimus: a further update of its use in the management of organ transplantation. *Drugs.* 2003;63(12):1247-1297.
4. Madan V, Griffiths CE. Systemic ciclosporin and tacrolimus in dermatology. *Dermatol Ther.* 2007;20(4):239-250.
5. Ohtsuka T. Oral tacrolimus treatment for refractory eosinophilic cellulitis. *Clin Exp Dermatol.* 2009;34(8):e597-e598.
6. Weins AB, Biedermann T, Weiss T, Weiss JM. Wells syndrome. *J Dtsch Dermatol Ges.* 2016;14(10):989-993.
7. Sinno H, Lacroix JP, Lee J, et al. Diagnosis and management of eosinophilic cellulitis (Wells' syndrome): a case series and literature review. *Can J Plast Surg.* 2012;20(2):91-97.
8. Verma P, Singal A, Sharma S. Idiopathic bullous eosinophilic cellulitis (Wells syndrome) responsive to topical tacrolimus and antihistamine combination. *Indian J Dermatol Venereol Leprol.* 2012;78(3):378-380.
9. Rolfe FG, Valentine JE, Sewell WA. Cyclosporin A and FK506 reduce interleukin-5 mRNA abundance by inhibiting gene transcription. *Am J Respir Cell Mol Biol.* 1997;17(2):243-250.
10. Herout S, Bauer WM, Schuster C, Stingl G. Eosinophilic cellulitis (Wells syndrome) successfully treated with mepolizumab. *JAAD Case Rep.* 2018;4(6):548-550.