
Upper extremity arteriovenous dialysis fistula causing arterialised blood flow in internal jugular vein in patients with brachiocephalic vein occlusion

Sir,

The internal jugular vein (IJV) has become the preferred central vein for anaesthesiologists and it is also an important anatomical landmark for the upper extremity nerve blocks. However, under certain circumstances, the IJV can be mistaken for the carotid artery. The circumstances leading to the mistake include rotation of the head (which changes their relative position and overlap)^[1] and, in particular, the presence of retrograde blood flow.

The reversal of the blood flow through the IJV is a consequence of occlusion of the large veins in the superior mediastinum: The brachiocephalic vein (BCV) or the superior vena cava (SVC). The causes include malignancies, external compression by mediastinal fibrosis or aneurysm or thrombosis of the thoracic aorta, use of catheters or pacemaker electrodes or drug infusions.^[2] In addition to the occlusion, a prerequisite for the flow reversal is the

damage of the IJV valve, which is present in about 90% of people and ensures unidirectional blood flow.^[3] Of note, the IJV valve can be damaged by a central venous catheter. Regardless of its mechanism, the obstruction of SVC or its major tributaries may affect the upper limb function and lead to the development of SVC syndrome. We present here two cases of arterialised blood flow in the IJV in patients with upper extremity arteriovenous fistula (AVF) for dialysis.

In the first patient, who had a right AVF, an orientational sonographic scan was performed before insertion of a central venous line via IJV. The subclavian veins (SCVs) and IJVs were patent bilaterally but the flow in the right IJV was reversed. Subsequent imaging revealed the right BCV occlusion, apparently due to complications of the SCV dialysis catheter placement in the past. Colour Doppler ultrasonography (CDUS) of the neck and right upper arm confirmed BCV occlusion and also showed engorged veins in the upper arm with some collateral veins in the axilla. Since one BCV was obstructed, and the SVC was open, the blood flow on the side of obstruction was mainly directed retrograde through the ipsilateral IJV, sigmoid and transverse sinus, to the contralateral IJV and BCV, to finally reach the SVC [Figure 1a].

In the second patient, who had a left AVF, a sonographic scan was performed before a nerve block.

CDUS demonstrated that the dialysis access in the left upper arm and the SCVs and IJVs were patent on both sides of the body, but with retrograde blood flow in the left IJV and in the right SCV [Figure 1b]. Both BCVs were occluded, with the extension of the occlusion to the SVC. Engorged collateral veins in both axillary regions were also detected. In this case with both BCVs obstructed, the blood flow was retrograde from the subclavian vein on the side of the haemodialysis fistula through the ipsilateral IJV and dural sinuses at the skull base, to finally reach the contralateral IJV. Because the contralateral BCV was also obstructed, blood flow was retrograde through the contralateral SCV and reached the heart via the anastomoses between the axillary vein and thoracic veins. The axillary route relies on the anastomoses between the axillary vein and the venous system of the thoracic wall, such as the lateral thoracic vein. The thoracic venous circulation then reaches the right atrium via the azygos/hemiazygos pathways.^[2]

Obstruction of BCV and/or SCV may seem like a non-frequent clinical entity, but it may actually be underdiagnosed as it has been described in up to 29% of patients with polytetrafluoroethylene grafts, who required haemodialysis.^[4] Furthermore, haemodialysis shunts are a predisposing factor for BCV obstruction even in patients with no history of malignancy or central venous lines.^[5,6] One should

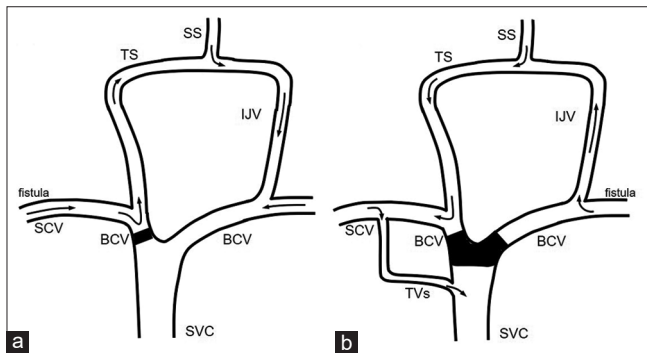


Figure 1: Schematic drawings of the venous flow in the upper body show an obstructed brachiocephalic vein as in the patient 1 (a) and bilateral obstruction as in the patient 2 (b). The arrows indicate the directions of the venous flow. SCV, subclavian vein; BCV, brachiocephalic vein; SVC, superior vena cava; TS, transversal sinus; SS, sagittal sinus; IJV, internal jugular vein; TVs, thoracic veins; fistula, upper extremity with the arteriovenous fistula

also not forget hypercoagulability in end-stage renal disease and its contribution to the thrombosis of vascular access.^[7]

To conclude, the anaesthesiologists should not only be aware of a possibility that central venous obstruction and reversed blood flow in IJV may be present in patients with an upper extremity haemodialysis shunt, but should even expect it, in particular, in patients with end-stage kidney disease. With central venous obstruction present, the central venous line should be placed using a femoral route, and caution should be exercised to avoid confusion when using large cervical veins as anatomical landmarks for the upper extremity nerve blocks.

Financial support and sponsorship

Nil.

Conflicts of interest

There are no conflicts of interest.

Vicko Gluncic, Ivan K Lukić¹, Lara Bonasera, Kenneth Candido

Department of Anesthesia, Advocate Illinois Masonic Medical Center, 836 W Wellington Ave, Chicago, IL, USA, ¹Bjelovar University of Applied Sciences, Trg Eugena Kvaternika 4, Bjelovar, HR-43000, Croatia

Address for correspondence:

Dr. Vicko Gluncic,
Department of Anesthesia, Advocate Illinois Masonic Medical Center,
836 W Wellington Ave, Chicago - 60657, IL, USA.
E-mail: vicko.gluncic@gmail.com

Submitted: 11-Apr-2020

Revised: 20-Apr-2020

Accepted: 27-May-2020

Published: 01-Oct-2020

REFERENCES

1. Khemka R, Rastogi S, Chakraborty A, Sinha S. Ultrasonographic assessment of altered anatomical relationship between internal jugular vein and common carotid artery with supraglottic airway in children: LMA vs i-gel™. *Indian J Anaesth* 2019;63:114-8.
2. Ko SF, Huang CC, Ng SH, Hsieh MJ, Lee CC, Wan YL, *et al*. Imaging of the brachiocephalic vein. *AJR Am J Roentgenol* 2008;191:897-907.
3. Wu X, Studer W, Erb T, Skarvan K, Seeberger MD. Competence of the internal jugular vein valve is damaged by cannulation and catheterization of the internal jugular veins. *Anesthesiology*

- 2000;93:319-24.
4. Lumsden AB, MacDonald MJ, Isiklar H, Martin LG, Kikeri D, Harker LA, *et al.* Central venous stenosis in the hemodialysis patient: Incidence and efficacy of endovascular treatment. *Cardiovasc Surg* 1997;5:504-9.
 5. Gonsalves CF, Eschelmann DJ, Sullivan KL. Incidence of central vein stenosis and occlusion following upper extremity PICC and port placement. *Cardiovasc Intervent Radiol* 2003;26:123-7.
 6. Otten TR, Stein PD, Kalpesh PC. Thromboembolic disease involving the superior vena cava and brachiocephalic veins. *Chest* 2003;123:809-12.

7. Molino D, De Lucia D, Gaspare De Santo N. Coagulation disorders in uremia. *Semin Nephrol* 2006;26:46-51.

Access this article online	
Quick response code	Website: www.ijaweb.org
	DOI: 10.4103/ija.IJA_378_20

This is an open access journal, and articles are distributed under the terms of the Creative Commons Attribution-NonCommercial-ShareAlike 4.0 License, which allows others to remix, tweak, and build upon the work non-commercially, as long as appropriate credit is given and the new creations are licensed under the identical terms.

How to cite this article: Gluncic V, Lukic IK, Bonasera L, Candido K. Upper extremity arteriovenous dialysis fistula causing arterialized blood flow in internal jugular vein in patients with brachiocephalic vein occlusion. *Indian J Anaesth* 2020;64:915-7.
© 2020 Indian Journal of Anaesthesia | Published by Wolters Kluwer - Medknow