


# Can the patient pinpoint where the ingested fish bone is impacted?

## A single-center, retrospective study

Gyu Man Oh, MD, Kyoungwon Jung, MD\* , Jae Hyun Kim, MD, Sung Eun Kim, MD, Won Moon, MD, Moo In Park, MD, Seun Ja Park, MD

### Abstract

Among the plethora of foreign body impactions, fish bones are common examples that patients may struggle to properly disclose in clinical situations. This study investigated whether patients could pinpoint where the ingested fish bone was lodged. In addition, we investigated the differences between fish bone and other foreign bodies, the usefulness of computed tomography (CT), and the related risk factors for hospitalization. The cases of patients who underwent an endoscopic removal of fish bone between April 2008 and April 2020 were retrospectively reviewed. The clinical outcomes, X-ray scan, CT, and complications of each patient were investigated. A total of 96 patients were included in this study. The mean size of the impacted fish bone was 23.78 mm, and most were found in the upper esophagus ( $n = 38$ ). There was a weak correlation between pain location and the actual lesion location ( $r = 0.419$ ,  $P < .001$ ). Compared to those of other foreign bodies, the location of impacted fish bones was different ( $P < .001$ ), the X-ray detection rate of fish bones was lower ( $P < .001$ ), and the complication incidence was higher ( $P = .030$ ). CT (95.89%) showed higher sensitivity than X-ray scanning (11.24%) ( $P < .001$ ). Foreign body size ( $P = .004$ ) and door-to-endoscopy time ( $P = .029$ ) were related to admission. Patients only managed to point out the approximate location of the ingested fish bone. CT detected fish bones well, but scans should include at least the entire esophagus instead of solely the area where pain is felt. Fish bone impaction has different clinical characteristics from other foreign bodies. Endoscopic removal without delay can reduce the admission rates.

**Abbreviation:** CT = computed tomography.

**Keywords:** bone and bones, endoscopic surgical procedure, esophageal perforation, fishes, foreign bodies

## 1. Introduction

Foreign body impaction is a common condition that prompts many people to visit the emergency room. Epidemiologically, this complication causes more than 100,000 individuals to visit hospitals each year in the United States.<sup>[1]</sup> The incidence rate is higher in children aged between 6 months and 3 years and in adults with a history of mental illness, stroke, and alcohol dependence.<sup>[2]</sup> In many cases, foreign bodies are found in the esophagus,<sup>[3]</sup> which include bolus food, fish bones, and pill packages.<sup>[4]</sup>

Among these kinds of foreign bodies, fish bones are particularly difficult to adequately disclose in clinical settings. In the case of other common foreign bodies such as coins or pill packages confined in the esophagus, patients are able to clearly express that the foreign body is caught within their neck area. However, most patients may be unsure about whether or not they have impacted fish bones in their esophagus, especially when they simply swallow ones hidden in their food. This accidental event can bring about ambiguous complaints that confuse physicians. Lodged fish bones in the larynx can

easily be detected and removed using plain radiography and laryngoscopy. However, if the fish bones are not visible on the laryngoscope, computed tomography (CT) and esophagogastroduodenoscopy should be considered. Also, there are still no established standard diagnostic tools or guidelines for treatment.<sup>[5,6]</sup>

This study aimed to determine the differences of size, location, complications and hospitalization rates between impacted fish bones and other foreign bodies. In addition, this study investigated whether the location of the lesion that the patient complained of was same as the accurate location of impaction. The usefulness of CT for diagnosis was also compared to that of plain radiography.

## 2. Materials and Methods

### 2.1. Patients

This study investigated the medical records of patients in whom foreign bodies had been removed from April 2008 to April 2020.

The authors have no funding and conflicts of interest to disclose.

The data underlying this article will be shared on reasonable request to the corresponding author.

Department of Internal Medicine, Kosin University College of Medicine, Busan, Korea.

\*Correspondence: Kyoungwon Jung, Department of Internal Medicine, Kosin University College of Medicine, 262 Gamcheon-ro, Seo-gu, Busan 49267, Korea (e-mail: forjkw@gmail.com).

Copyright © 2022 the Author(s). Published by Wolters Kluwer Health, Inc.

This is an open-access article distributed under the terms of the Creative Commons Attribution-Non Commercial License 4.0 (CCBY-NC), where it is permissible to download, share, remix, transform, and buildup the work provided it is properly cited. The work cannot be used commercially without permission from the journal.

How to cite this article: Oh GM, Jung K, Kim JH, Kim SE, Moon W, Park MI, Park SJ. Can the patient pinpoint where the ingested fish bone is impacted? A single-center, retrospective study. *Medicine*. 2022;101:30(e29399).

Received: 8 November 2021 / Received in final form: 13 February 2022 / Accepted: 14 April 2022

<http://dx.doi.org/10.1097/MD.00000000000029399>

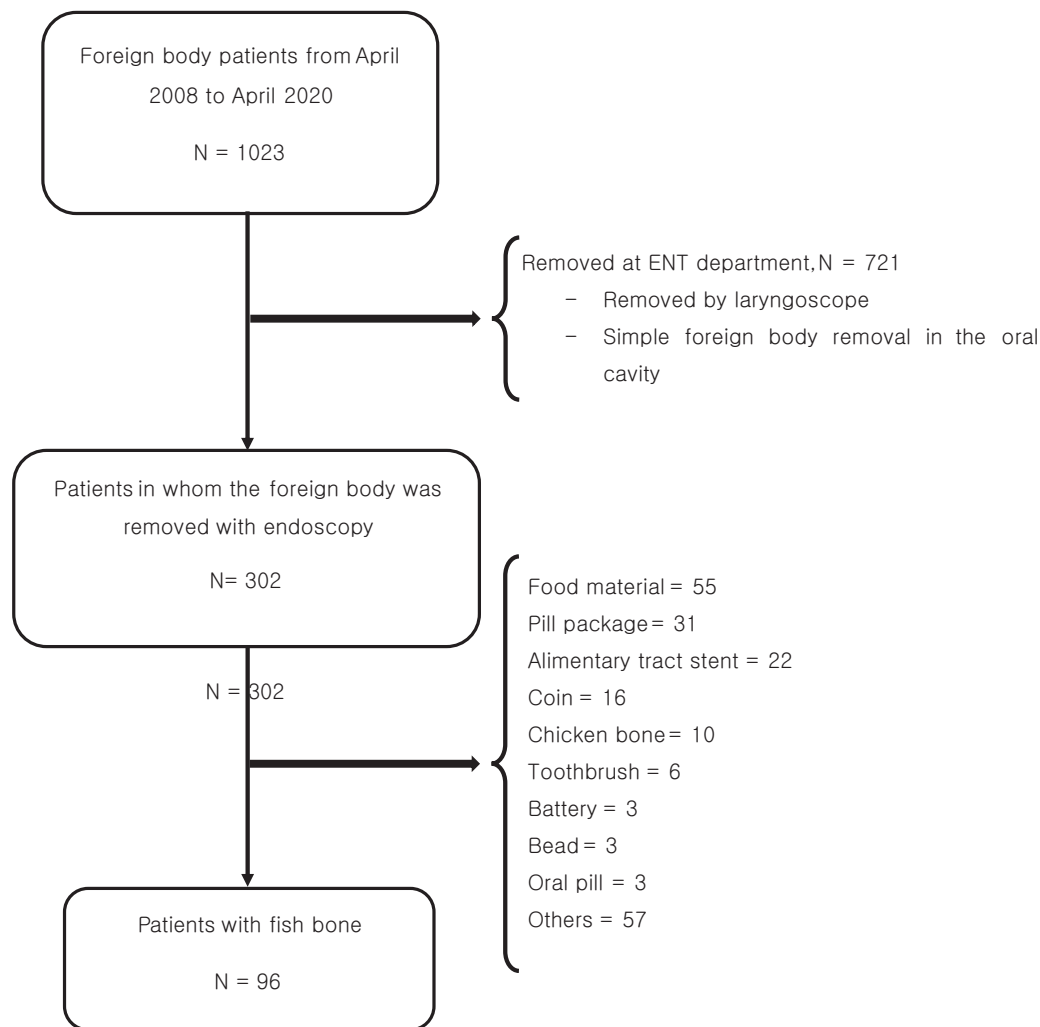


Figure 1. Patient selection diagram.

Among them, patients who had ingested a fish bone and underwent endoscopic removal were selected. Pregnant women who could not undergo radiologic examinations were excluded. This study was performed after obtaining approval from the Institutional Review Board of Kosin University Gospel Hospital (2021-04-014).

## 2.2. Data collection and clinical setting

The age, sex, residence, medical history, and surgical history of the patients included in the study were examined. The time between the foreign body impaction and the visit to the hospital, the time between the visit to the hospital and the performance of the endoscopy (door-to-endoscopy time), and the total time of both were investigated. Furthermore, the duration of the endoscopic removal procedure was noted. The location where the patient complained of pain and the actual location of the lesion were compared, and the size of the foreign body was measured. The related complications that arose from the foreign bodies, hospitalization rates, and hospitalization periods were also checked.

The location of the lesion was classified under the pyriform sinus, cervical esophagus (from the lower end of pharynx to the suprasternal notch; 15–20 cm from the incisors), upper esophagus (from the suprasternal notch to the level of the tracheal bifurcation; 20–25 cm), middle esophagus (from the tracheal bifurcation to the gastroesophageal junction; 25–30 cm), lower

esophagus (from the tracheal bifurcation to the gastroesophageal junction; 30–40 cm), stomach, or duodenum.

Moreover, the sensitivity of the two diagnostic tests was calculated to determine whether X-ray and CT scans were taken. CT scans were acquired with a multidetector CT system reconstructed with 2-mm slice thickness and pitch 1.2 before and after the contrast medium injection. The CT images fully involved the upper gastrointestinal area.

Esophagogastroduodenoscopes (GIF-Q260, GIF-H260, GIF-H290, Olympus Tokyo, Japan) were utilized for diagnosis and removal. Endoscopic devices such as biopsy forceps, graspers, retrieval baskets, polypectomy snares, and endoscopic transparent caps were also used to extract the foreign bodies. All examinations were performed as non-sleep tests, and no local pharyngeal anesthesia.

## 2.3. Statistical analyses

In this study, statistical analysis was used for 1) comparing the difference between fish bones and other foreign bodies, 2) comparing the sensitivity of X-ray and CT scans in the detection of fish bones, 3) investigating the association between the area where the patient complained of pain and the actual location of impaction, and 4) identifying the risk factors for hospitalization.

Student's t-test was used for the continuous variables, and the chi-square test was used for the categorical variables to

**Table 1**  
**Patients' characteristics and clinical results.**

Variables (n = 96)	
Age, yr, mean ± SD (range)	55.10 ± 15.5 (3–84)
Sex, n (%)	
Male	73 (76.04)
Female	23 (33.96)
Comorbidities, n	
Hypertension	21
Diabetes	6
Stroke	6
Atrial fibrillation	3
Colon cancer	3
Schizophrenia	2
Angina	2
COPD	1
Lye stricture	1
Liver cirrhosis	1
Esophageal cancer	1
Stomach cancer	1
Surgical history of alimentary tract, n	
Esophagus	1
Stomach	1
Chief complaints, n	
Neck pain	71
Chest pain	8
Epigastric pain	11
Odynophagia	4
Hematemesis	1
Vomiting	1
Time taken to endoscopy, hour	
mean ± SD (range)	17.02 ± 27.95 (0.25–196)
0–1	37
1–4	20
4–8	10
8–12	6
12–24	13
24–48	3
>48	7
Location of foreign body, n	
Pyriform sinus	11
Cervical esophagus	27
Upper esophagus	38
Middle esophagus	11
Lower esophagus	9
Stomach	0
Size of foreign body, mm	
mean ± SD (range)	23.78 ± 9.26 (4–50)
Complications, n	
Esophageal mucosal break	37
Esophageal ulcer	9
Esophageal bleeding	6
Esophageal perforation	2
None	46

confirm the difference between the two groups. Meanwhile, the Spearman correlation analysis was used to investigate the correlation between the two groups. Multivariate logistic regression analysis was also performed to identify the risk factors. Statistical significance was determined based on the 95% confidence level ( $P < .05$ ). All statistical analyses were performed using the IBM SPSS ver. 20.0 (IBM Co., Armonk, NY).

### 3. Results

#### 3.1. Patient characteristics

A total of 1023 patients were subjected to foreign body removal between April 2008 and April 2020. Among these, 721 patients underwent laryngoscopic foreign body removal. The other 302 patients underwent endoscopic foreign body removal, and

among them, 96 patients had impacted fish bones (Fig. 1). The characteristics and clinical results of the 96 patients are shown in Table 1. The mean age was 55.10 years, and the number of men was greater than that of women (73 vs 23). There were 21 patients with hypertension, six patients with diabetes, six patients with stroke, and one patient each with lye stricture, esophageal cancer, and stomach cancer. Most endoscopies were performed within an hour of a hospital visit (door-to-endoscopy time). The mean time from the foreign body impaction to the endoscopy (the time from the foreign body impaction to the hospital visit plus door-to-endoscopy time) was 14.22 hours. The most frequent site of impaction was the upper esophagus ( $n = 38$ ), and there were 27 cases in the cervical esophagus. None of the fish bones were found in the stomach. The mean size of the fish bone was 23.78 mm. Forty-six patients did not have any complications, but 37 had mucosal breaks in the esophagus. In addition, nine patients had ulcers, and two patients had esophageal perforations.

#### 3.2. Fish bone vs. other foreign bodies

A comparison of the clinical results between fish bones and other foreign bodies is shown in Table 2. Other foreign bodies were larger than the fish bones (23.78 vs. 37.16). The location of the impacted fish bone was frequently in the upper esophagus ( $n = 38$ , 39.58%), but other foreign bodies were common in the upper esophagus ( $n = 53$ , 25.73%) and stomach ( $n = 58$ , 28.16%) ( $P < .001$ ). The time from the foreign body impaction to the hospital visit was short for those with an impacted fish bone, and the door-to-endoscopy time was similar. However, none of these were statistically significant ( $P = .693$  and  $P = .143$ , respectively). The duration of the removal procedure was longer in the non-fish bone group (8.66 vs 17.23%,  $P < .001$ ). The X-ray scan detection rate was higher in the non-fish bone group (11.24% vs 37.23%,  $P < .001$ ), but both groups had a high detection rate in CT scans (95.89% vs 87.23%,  $P = .068$ ). The complication incidence was higher in the fish bone group ( $P = .030$ ). There was no significant difference in hospitalization rates between the two groups (57.29% vs 55.34%,  $P = .748$ ).

#### 3.3. The accuracy of patient's complaint site and the comparison of sensitivity between CT and X-ray

The correlation coefficient was 0.419 ( $P < .001$ ) when comparing the actual location of the lesion and reported area of pain (Table 3). The graph in Figure 2 shows how the exact location of the lesion and the patient's pain point differ. When comparing the sensitivity of CT and X-ray scanning (Table 4), CT exhibited a higher sensitivity than X-ray scanning (11.24% vs 95.89%,  $P < .001$ ).

#### 3.4. The factors linked to hospitalization

The logistic regression analysis (Table 5) revealed that fish bone size and door-to-endoscopy time ( $P = .004$ ,  $P = .029$ ) were factors related to hospitalization. However, there was no relationship found with the location of the fish bone ( $P = .119$ ), the total time taken to the endoscopy ( $P = .202$ ), the duration of the removal procedure ( $P = .701$ ), and other arising complications ( $P = .704$ ).

### 4. Discussion and Conclusions

This retrospective study investigated patients who had removed an impacted fish bone located in the esophagus through esophagogastroduodenoscopy within the last 12 years in a single center. Ninety-six patients (73 men, 23 women) were included, and

**Table 2**  
**Comparison of fish bone with other foreign bodies.**

N = 302		Fish bone (N = 96)	Foreign bodies except fish bone (N = 206)	P-value
Sex, n (%)	Male	73 (76.04)	141 (68.44)	.013
	Female	23 (33.96)	65 (31.56)	
Age, years, mean ± SD (range)	55.10 ± 15.5 (3–84)	52.94 ± 23.72 (0–88)	.443	.001
Foreign body size, mm, mean ± SD (range)		23.78 ± 9.26 (4–50)	37.16 ± 38.48 (3–200)	
Location of impaction, n				
	Pyriform sinus	11	8	
	Cervical esophagus	27	33	
	Upper esophagus	38	53	
	Mid esophagus	11	16	
	Lower esophagus	9	33	
	Stomach	0	58	
	Duodenum	0	5	
Time to visit hospital, hour, mean ± SD *		14.36 ± 33.50	25.12 ± 59.25	.128
Door-to-endoscopy time, hour, mean ± SD †		4.59 ± 3.57	4.32 ± 5.27	.693
Total time to endoscopy, hour, mean ± SD ‡		17.02 ± 27.95	27.02 ± 59.27	.143
Procedure time, minutes, mean ± SD (range)		8.66 ± 7.98	17.23 ± 21.46	
Foreign body detection via X-ray scan, n (%)		Yes	10	70
	No	79	118	
	Not applicable	7	18	
Foreign body detection via computed tomography, n (%)		Yes	82	.068
	No	3	12	
	Not applicable	23	112	
Complication		None	127	.030
	Mucosal break	37	56	
	bleeding	6	7	
	Ulceration	9	15	
	Perforation	2	1	
Admission, n (%)		55 (57.29)	114 (55.34)	.748
Hospitalization days, mean ± SD (range)		7.42 ± 7.56	8.67 ± 8.52	.404

\*Time to visit the hospital = time taken to visit the hospital after foreign body impaction.

†Door-to-endoscopy time = time to wait for the endoscopy procedure in the hospital.

‡Total time to endoscopy = 'time to visit hospital' plus 'door-to-endoscopy time'.

SD = standard deviation.

**Table 3**  
**The location of pain and impaction in fish bone foreign body and the correlation between these.**

	The location of pain (N = 83)	The location of lesion (N = 96)	
Neck	71	Pyriform sinus 11 Cervical esophagus 27	$r = 0.419^*P < .001$
Chest	4	Upper esophagus 38 Middle esophagus 11	
Epigastric area	8	Lower esophagus 9	
Abdomen	0	Stomach 0	

\*r: coefficient of correlation, Spearman's rank correlation coefficient.

the mean age was 55.10 years. The comorbidities of the patients were stroke (n = 6, 6.25%) and schizophrenia (n = 2, 2.08%). Stroke was observed in 1.71% of patients and schizophrenia in approximately 0.6% of the general population of Korea.<sup>[7,8]</sup> Several cases of stroke and schizophrenia were observed among the analyzed cases, and this is aligned with previous studies that concluded that foreign body impaction is more common in patients with a history of stroke or mental illness.<sup>[6]</sup> Furthermore, patients with cancer had a high incidence rate of foreign body impaction due to intestinal narrowing or previous surgery. In this study, one patient had esophageal cancer, and another patient had stomach cancer. Both patients underwent surgery beforehand and had no remaining lesions at the time of impaction. Surgery altered their gut anatomy and bowel movement, resulting in foreign body impaction.

The ingested fish bone was easily caught in the upper esophagus (n = 38, 39.58%) and the cervical esophagus (n = 27, 28.13%) in this study. In other foreign bodies aside from fish

bones, the stomach was the most frequent site of impaction (n = 58, 28.16%), and the upper esophagus (n = 53, 25.73%), cervical esophagus (n = 33, 16.02%), and lower esophagus (n = 33, 16.02%) had a high rate of impaction as well. It seems that the foreign bodies are usually caught in the upper and lower esophagus due to the physiologic narrowing of the esophagus. However, foreign bodies were noted not only in these two areas in the present study. This is because the diameter of the esophagus is less than 1 cm,<sup>[9]</sup> and the mean size of the impacted fish bone was 23.78 mm. The impaction of foreign body may be more common in the esophageal physiologic narrowing, but it can also end up lodged in other areas. Other foreign bodies, excluding fish bones, are commonly found in the stomach due to the gastric emptying time.

Other foreign bodies were larger than fish bones and took more time to remove. This is because large objects, such as toothbrushes and alimentary tract stents, were included. The difference in the impaction site between the two groups was due to the linear or angular shape of the fish bone, so the fish bones could not pass further and remained stuck in the upper esophagus. Additionally, more complications due to fish bones can be attributed to the foreign body's sharpness, resulting in the scratching of the esophageal mucosa. Nevertheless, there was no difference in the hospitalization rates and duration.

The X-ray detection rate was significantly lower in the fish bones ( $P < .001$ ). They had variable radio-opacity and were often radiolucent compared to other foreign bodies.<sup>[10,11]</sup> In the detection rate of CT, there were no differences in sensitivity. However, in other foreign body group, the number of patients who did not undergo CT examination was larger than those who did.

There was a weak correlation between the location of the lesion and the area where the patient complained of pain

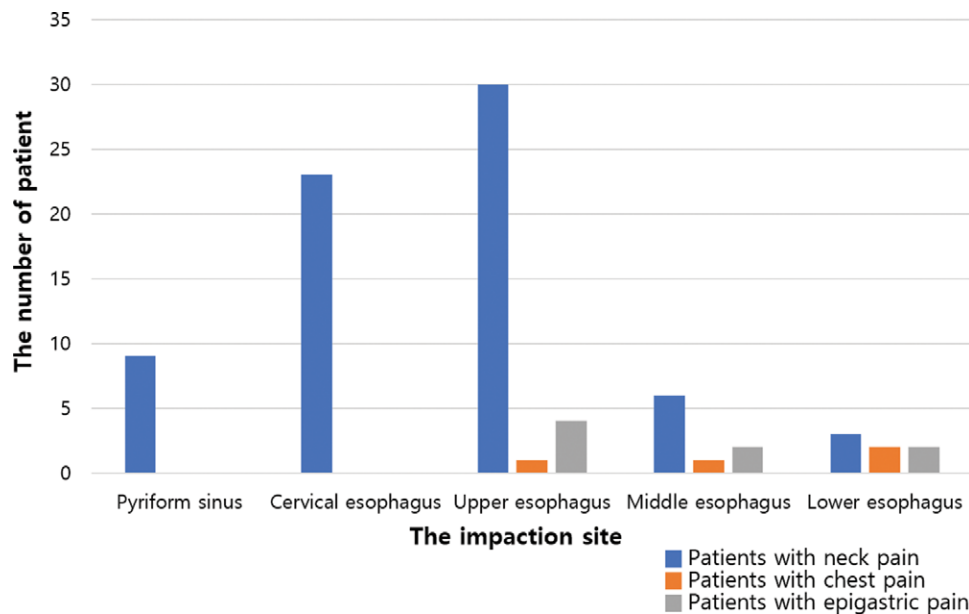


Figure 2. The location of pain and impaction in fish bone foreign body and the correlation between these.

**Table 4**  
Comparison of sensitivity between CT and X-ray scans.

N = 96	X-ray	CT	P-value
Sensitivity (%)	11.24	95.89	
Present	10	70	
Absent	79	3	
Not tested	7	23	

(Fig. 2). For example, in most cases of neck pain, fish bones could be found in the upper esophagus. However, the fish bones were actually in the middle esophagus in six cases, and in three cases, the fish bone could only be noticed once the endoscope entered the lower esophagus. Almost all of the patients grasped the entire neck or chest with their palms rather than pinching the exact point of pain. This resulted in a weak correlation ( $r = 0.419, P < .001$ ). The fact that the patients failed to clearly describe the location of the fish bone illustrates how the fish bone may not easily be found with an endoscope. Therefore, the clinician performing the endoscopy must re-check the entire pyriform sinus and the esophagus, even if there is no fish bone at the site where the patient initially complains of pain.

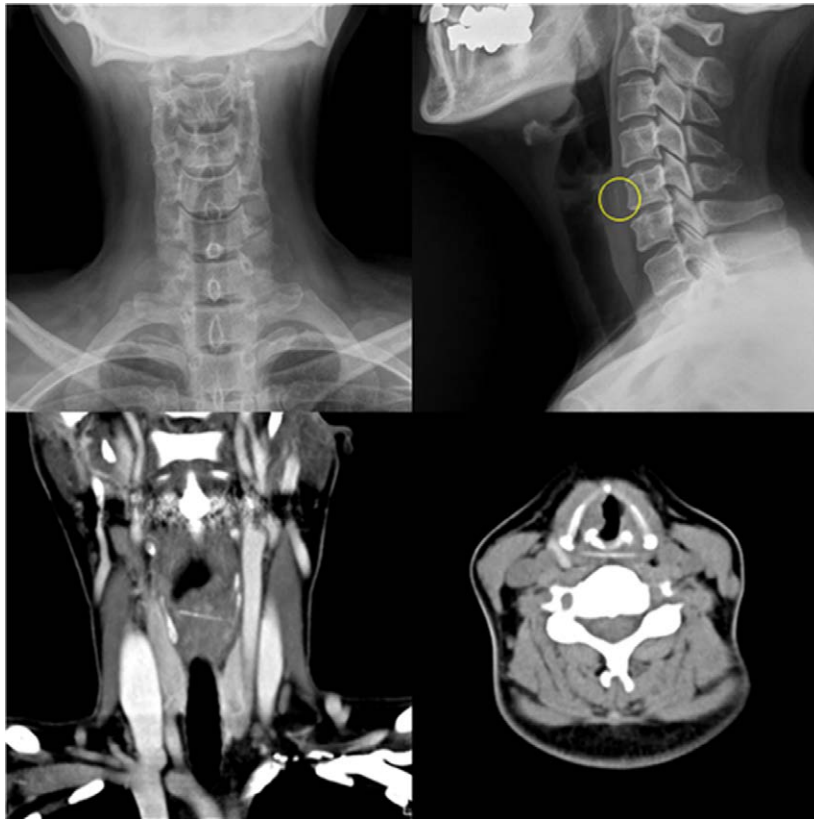
In the comparison of X-ray and CT images, there was a distinct difference in sensitivity. Radiologic imaging is needed to identify the fish bones. X-ray and CT scans have been mainly used so far, and further debate is warranted regarding which is better between the two in terms of practical aspects such as waiting time for examination, cost, and so on. In 1994, even though CT was uncommon, there was a study that recommended not to take X-ray images because it delayed endoscopic removal.<sup>[12]</sup> In relation, considering the difficulty of availing CT, there was a study in 2018 that suggested a scoring system wherein patients with high scores are recommended to take CT.<sup>[13]</sup> In this study, CT showed higher sensitivity than X-ray, which was the same result found in previous studies.<sup>[14-17]</sup> The reason for the low sensitivity of X-rays is that the fish bones are obscured by normal structures in the neck and chest, such as the sternum, heart, and surrounding blood vessels. All 10 cases of fish bones identified in the X-ray were checked in the lateral view, not the AP view (Fig. 3).<sup>[18]</sup> This is consistent with previous studies that emphasized the role of the lateral X-ray view.<sup>[18]</sup> Given the lateral view

**Table 5**  
Multivariate logistic regression analysis to identify significant independent risk factors for admission.

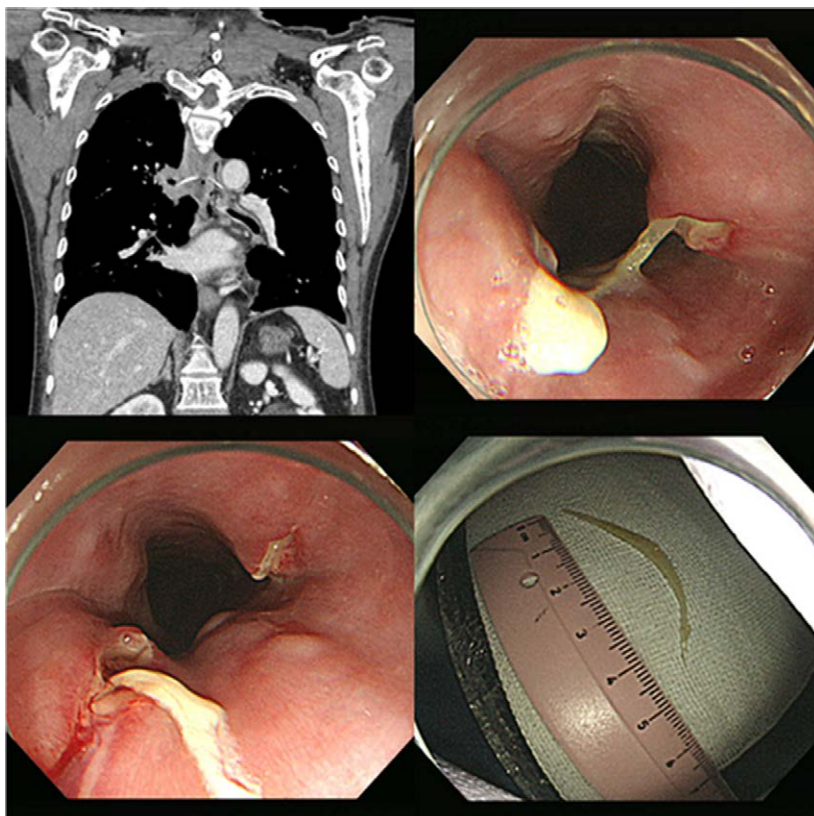
	Odds ratio	95% Confidence interval	P-value
Gender, male	1.248	0.369–4.219	.722
Age	1.017	0.976–1.060	.426
Size of fish bone	1.149	1.046–1.261	.004
Location of fish bone	1.591	0.888–2.852	.119
Total time to endoscopy	1.045	0.977–1.117	.202
Door-to-endoscopy time	1.263	1.024–1.558	.029
Procedure time	0.986	0.915–1.062	.701
Presence of complication	0.663	0.080–5.503	.704

of the radiograph, the fish bone can be detected if it is in the cervical esophagus. However, if it is already in the rib cage, it cannot be found in any view. CT shows much higher sensitivity because it overcomes this shortcoming of X-ray scanning, which can only provide a view of the cross-section.

CT was performed to investigate the location of the ingested fish bone and its possible invasion of the surrounding blood vessels, instead of simply checking its overall presence. The European guideline published in 2016 also strongly recommended that CT should be taken when perforation is suspected due to foreign body impaction.<sup>[19]</sup> In fact, there is a case wherein CT was used to confirm that the fish bone was very close to the aorta (Fig. 4). For this patient, fish bone removal was performed under general anesthesia in the operating room instead of the endoscopy room, and the thoracic surgery team was carefully monitoring the procedure for the case of an aortic rupture. In addition, CT made it possible to determine whether the patient required hospitalization due to a ruptured esophagus (Fig. 5). Nevertheless, CT also has its limitations: it is more time-consuming and costly compared with X-ray scanning. However, CT without contrast media could solve this problem (Fig. 6). Contrast media can be foregone when the patient does not need to check for renal function (serum creatinine, serum blood urea nitrogen), and the cost of the examination could be reduced. In addition, clinicians no longer have to worry about the side effects of contrast media, such as allergic reactions and acute kidney injuries. Even without contrast media, the fish bone could



**Figure 3.** The patient with fish bone in the cervical esophagus. It is noted via computed tomography and X-ray scan in the lateral view, but not in the AP view.



**Figure 4.** The case wherein the fish bone was very close to the aorta. Computed tomography is also useful to check whether the fish bone has invaded the large vessels.

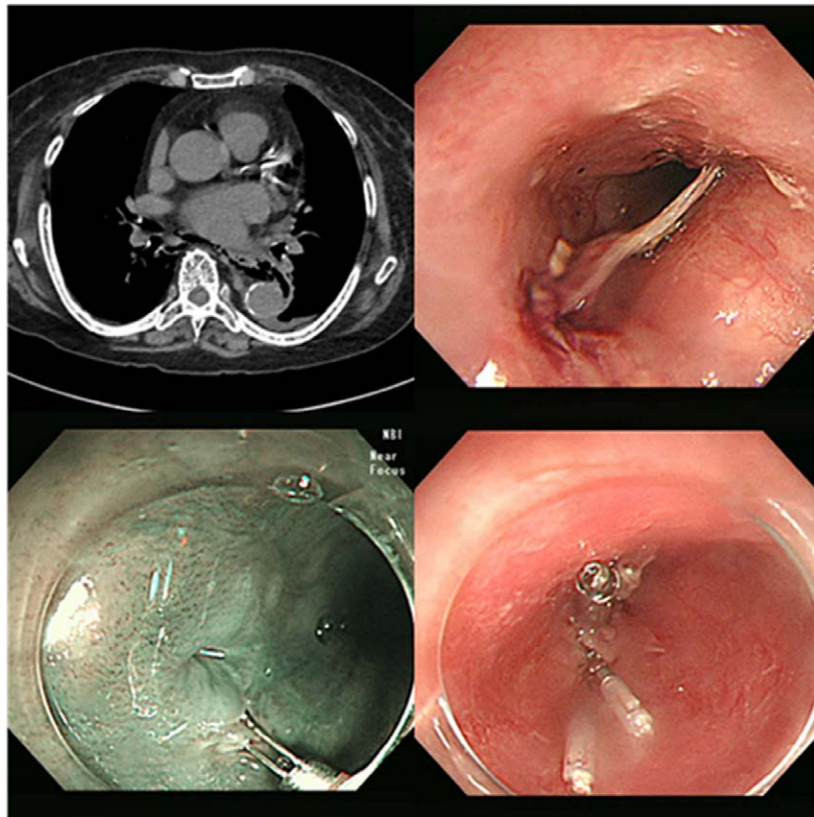


Figure 5. The case of esophageal perforation. It was diagnosed via computed tomography and treated with hemoclip closure.

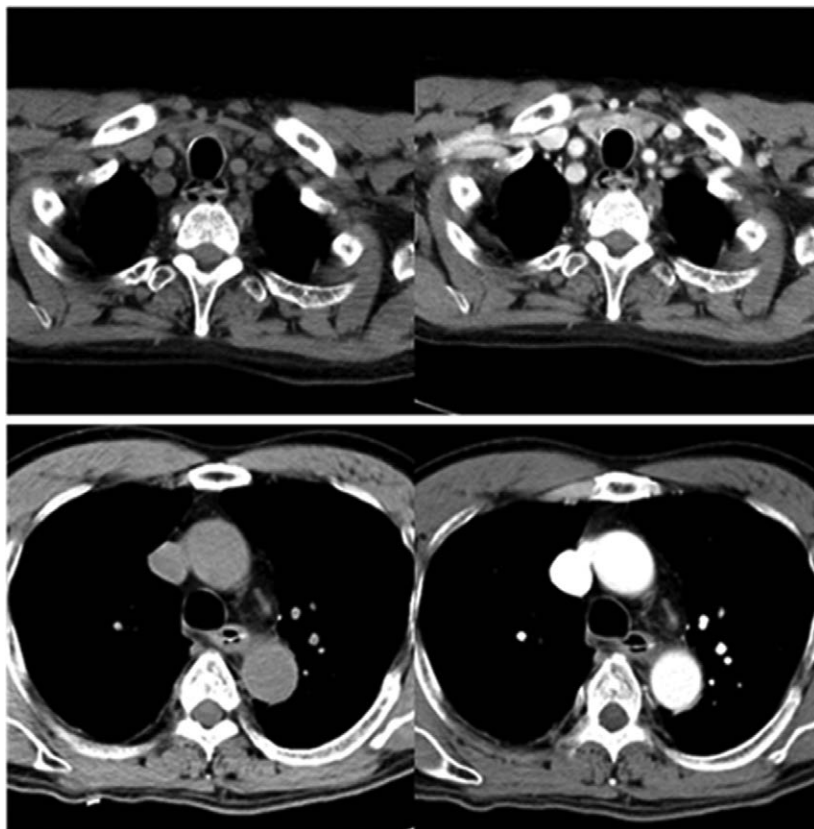


Figure 6. Without contrast media, fish bones can be detected by adjusting the computed tomography windowing.

still be detected by adjusting the CT windowing (Fig. 6). The 70 fish bones in this study were confirmed in both contrast and non-contrast views. As previously mentioned, since the patient cannot clearly explain the exact site of the fish bone, so the CT image should include the entire esophagus from the oral cavity.

According to multivariate logistic regression analysis, the risk of hospitalization increased when the fish bone was large and the door-to-endoscopy time was long. However, additional complications were not significantly related to hospitalization. Previous studies have reported that the incidence of complications increases when the fish bone is removed after a day.<sup>[20,21]</sup> Based on these studies, it is recommended to extract the fish bone within 1 day and remove it as soon as possible when there is a possibility of esophageal perforation. However, in the present study, the door-to-endoscopy time, not the entire time from the impaction to the removal, was related to hospitalization. This is in the same vein as the guidelines recommending endoscopic removal as early as possible, preferably within 2 hours, if sharp objects like fish bone are swallowed.<sup>[19]</sup> The shorter the door-to-endoscopy time, the lower the hospitalization rate. Although the two variables (door-to-endoscopy time and the entire time from the impaction to the removal) are not completely independent, they have very different statistical meanings. It can be speculated that because patients feel pain and visit the hospital only after tissue damage has been inflicted by the fish bone, what really matters are considering when the pain first occurred and prompted them to seek medical attention, rather than when the foreign body impaction happened.

The strength of this study is that it analyzed the long-term data of fish bone impaction, which is uncommon for clinicians to specifically delve into. This study has also highlighted the reality that the patient's area of complaint and the actual location of impaction can differ. Moreover, the need to investigate the risk factors for hospitalization was also emphasized. The limitation of this study is its retrospective nature and that it was conducted in a single center. In addition, fish bones may have different characteristics depending on the type of fish and the shape or size of the bones, but the analysis of these aspects seems insufficient.<sup>[22,23]</sup>

In conclusion, fish bones revealed a higher risk of complications than other foreign bodies, but the endoscopic procedure time, hospitalization rate, and hospitalization period were not significantly longer. X-ray images must be taken with a lateral view, and their detection rate is very low. Compared to X-ray scanning, CT was more helpful in confirming the accurate location of the impacted fish bone and checking for esophageal perforation or vascular invasion. The relationship between the location where the patient complained of pain and the actual impaction was weak. Therefore, CT scan have to cover a wider range, and it is necessary to carefully search through a wide range during endoscopy in clinical situations.

### Author contributions

All authors approved the final version of the manuscript and agreed to its submission.

Conceptualization: Gyu Man Oh, Kyoungwon Jung

Data curation: Jae Hyun Kim, Kyoungwon Jung, Moo In Park

Methodology: Gyu Man Oh, Seun Ja Park

Supervision: Kyoungwon Jung, Seun Ja Park

Visualization: Sung Eun Kim, Won Moon

Writing – original draft: Gyu Man Oh

Writing – review & editing: Jae Hyun Kim, Kyoungwon Jung, Moo In Park, Seun Ja Park, Sung Eun Kim, Won Moon

### References

- [1] Wylie R. Foreign bodies in the gastrointestinal tract. *Curr Opin Pediatr* 2006;18:563–4.
- [2] Blaho KE, Merigian KS, Winbery SL, Park LJ, Cockrell M. Foreign body ingestions in the emergency department: case reports and review of treatment. *J Emerg Med* 1998;16:21–6.
- [3] Li ZS, Sun ZX, Zou DW, Xu GM, Wu RP, Liao Z. Endoscopic management of foreign bodies in the upper-GI tract: experience with 1088 cases in China. *Gastrointest Endosc* 2006;64:485–92.
- [4] Wu WT, Chiu CT, Kuo CJ, et al. Endoscopic management of suspected esophageal foreign body in adults. *Dis Esophagus* 2011;24:131–7.
- [5] Ma J, Kang DK, Bae JI, Park KJ, Sun JS. Value of MDCT in diagnosis and management of esophageal sharp or pointed foreign bodies according to level of esophagus. *AJR Am J Roentgenol* 2013;201:W707–711.
- [6] Webb WA. Management of foreign bodies of the upper gastrointestinal tract: update. *Gastrointest Endosc* 1995;41:39–51.
- [7] Kim JY, Kang K, Kang J, et al. Executive summary of stroke statistics in Korea 2018: a report from the epidemiology research council of the Korean stroke society. *J Stroke* 2019;21:42–59.
- [8] Cho SJ, Kim J, Kang YJ, et al. Annual prevalence and incidence of schizophrenia and similar psychotic disorders in the republic of Korea: a national health insurance data-based study. *Psychiatry Investig* 2020;17:61–70.
- [9] Marini T, Desai A, Kaproth-Joslin K, Wandtke J, Hobbs SK. Imaging of the oesophagus: beyond cancer. *Insights Imaging* 2017;8:365–76.
- [10] AlBathi AK, Shaaban SS, Alshadadi F, et al. Radio-opacity of the bones of commonly consumed fish from the red sea. *Cureus* 2019;11:e6473.
- [11] Irfan M, Ahmad Helmy AK, Wan Shah Jihan WD. Radio-opacity of commonly consumed bony fish in Kelantan, Malaysia. *Med J Malaysia* 2012;67:491–3.
- [12] Sundgren PC, Burnett A, Maly PV. Value of radiography in the management of possible fishbone ingestion. *Ann Otol Rhinol Laryngol* 1994;103(8 Pt 1):628–31.
- [13] Jahshan F, Sela E, Layous E, et al. Clinical criteria for CT scan evaluation of upper digestive tract fishbone. *Laryngoscope* 2018;128:2467–72.
- [14] Qureshi TA, Awan MS, Hussain M, Wasif M. Effectiveness of plain X-ray in detection of fish and chicken bone foreign body in upper aerodigestive tract. *J Pak Med Assoc* 2017;67:544–7.
- [15] Ritchie T, Harvey M. The utility of plain radiography in assessment of upper aerodigestive tract fishbone impaction: an evaluation of 22 New Zealand fish species. *N Z Med J* 2010;123:32–7.
- [16] Woo SH, Kim KH. Proposal for methods of diagnosis of fish bone foreign body in the Esophagus. *Laryngoscope* 2015;125:2472–5.
- [17] Akazawa Y, Watanabe S, Nobukiyo S, et al. The management of possible fishbone ingestion. *Auris Nasus Larynx* 2004;31:413–6.
- [18] Karnwal A, Ho EC, Hall A, Molony N. Lateral soft tissue neck X-rays: are they useful in management of upper aero-digestive tract foreign bodies? *J Laryngol Otol* 2008;122:845–7.
- [19] Birk M, Bauerfeind P, Deprez PH, et al. Removal of foreign bodies in the upper gastrointestinal tract in adults: European Society of Gastrointestinal Endoscopy (ESGE) Clinical Guideline. *Endoscopy* 2016;48:489–96.
- [20] Geng C, Li X, Luo R, Cai L, Lei X, Wang C. Endoscopic management of foreign bodies in the upper gastrointestinal tract: a retrospective study of 1294 cases. *Scand J Gastroenterol* 2017;52:1286–91.
- [21] Hong KH, Kim YJ, Kim JH, Chun SW, Kim HM, Cho JH. Risk factors for complications associated with upper gastrointestinal foreign bodies. *World J Gastroenterol* 2015;21:8125–31.
- [22] Ruan WS, Li YN, Feng MX, Lu YQ. Retrospective observational analysis of esophageal foreign bodies: a novel characterization based on shape. *Sci Rep* 2020;10:4273.
- [23] Kim HU, Song HJ. Clinical characteristics of an esophageal fish bone foreign body from *Chromis notata*. *J Korean Med Sci* 2012;27:1208–14.