

## Neurological manifestation of colonic adenocarcinoma

Terence T. Sio,<sup>1</sup> Mercedes Paredes,<sup>2</sup> Uzair Chaudhary<sup>3</sup>

<sup>1</sup>Department of Radiation Oncology, Mayo Clinic, Rochester, MN; <sup>2</sup>Department of Neurology, UC San Francisco, San Francisco, CA; <sup>3</sup>Department of Hematology and Oncology, UCSF-Fresno, Fresno, CA, USA

### Abstract

Paraneoplastic neurologic disorders are extremely rare in cancer patients and are most commonly associated with certain tumors, such as ovarian cancer, small cell lung cancer, and breast cancer. We report here a paraneoplastic neurological syndrome in a 53-year-old man with colonic adenocarcinoma with a solitary liver metastasis. His paraneoplastic syndrome was successfully treated by methylprednisolone and primary oncologic therapies including neoadjuvant chemotherapy and definitive surgery. This is also the first documented case of simultaneous manifestation of a sensory neuropathy and limbic encephalitis with colon cancer.

### Introduction

Paraneoplastic syndromes are disorders caused by the presence of tumor in the body, an autoimmune response to the tumor when they express neuronal proteins or by immunologic disturbances caused by the tumor.<sup>1</sup> These disorders sometimes predate the tumor and can be the initial manifestation of malignancy. Any benign or invasive cancer can cause paraneoplastic syndromes, including neurologic syndromes. Multiple myeloma and tumors of the lung, breast, kidney and ovary are most commonly implicated. The classical presentations are the syndromes that have been clearly associated with cancer. These include cerebellar degeneration, sensory neuropathy, opsoclonus-myoclonus, and limbic encephalitis.<sup>2,3</sup> Colorectal cancer rarely presents with neurological paraneoplastic disorder; the few known cases have involved vasculitis and sensory neuropathy.<sup>4,5</sup> We report an unusual neurological presentation of a paraneoplastic syndrome, manifesting as an encephalomyelitis and sensory neuropathy associated with colonic adenocarcinoma.

### Case Report

In January 2010, a 53-year-old man with hypertension and migraine headache presented to his local hospital with visual disturbances and pain with eye movements. He first noted a burning sensation in his eyes, which quickly turned into *blotchy vision* where images appeared less intense. He developed generalized headaches with hypersomnolence. Two weeks after symptom onset, he experienced severe urinary retention requiring hospitalization and catheterization. However, three days after discharge, he developed numbness from his mid-back down to his feet, along with saddle anesthesia. During this time, his family also noted that he was more confused and had worsening gait instability.

He was re-admitted for further work-up. An initial lumbar puncture showed a pleocytosis of 138 white blood cells (9% neutrophils, 30% lymphocytes, 8% monocytes, and 56% other mononuclear cells). Magnetic resonance imaging (MRI) scans of the brain and total spine (both with contrast) were normal. He was started on antibiotics for presumed meningitis. During this time, the patient had extensive infectious and inflammatory work-up which were unremarkable, including cerebrospinal fluid (CSF) coccidioides and cryptococcal antigens, serum lyme antibody, West Nile virus and HIV antibodies, erythrocyte sedimentation rate, C-reactive protein, antinuclear antibody and antineutrophil cytoplasmic antibodies (ANCA) levels, and Sjogren's antibodies.

He was then transferred to the neurology service at our institution in March 2010. On admission his MRI scans showed new leptomeningeal enhancement of the intramedullary cervical spine, cauda equina, and multiple cranial nerves which appeared evolving (Figure 1). At this time, his bilateral leg weakness and numbness worsened, and he required a foley catheter due to severe urinary retention. As part of diagnostic work-up, a computed tomography scan of the chest, abdomen and pelvis was performed, which unexpectedly revealed a cecal mass and a possible hepatic metastasis. This mass was subsequently biopsied with colonoscopy and pathologically confirmed to be colonic adenocarcinoma. The rest of his work-up was also finalized at this time: paraneoplastic markers from his serum and cerebrospinal fluid including N-methyl-D-aspartate receptors were normal; testing of two separate viral and atypical bacterial infectious panels performed by the California Department of Public Health also revealed no evidence of infection. He had cytological analysis and flow cytometry performed on his CSF at three separate occasions during this hospitalization.

Folinic acid, fluorouracil and oxaliplatin

Correspondence: Terence T. Sio, Department of Radiation Oncology, Mayo Clinic, 200 First Street SW, Rochester, Minnesota 55905, USA. Tel. +1.507.2669795 - Fax: +1.507.2840079. E-mail: sio.terence@mayo.edu

Key words: colon cancer, paraneoplastic syndrome, peripheral neuropathy, ataxia, mania.

Conflict of interests: the authors report no potential conflict of interests.

Received for publication: 8 October 2011.  
Revision received: 14 May 2012.  
Accepted for publication: 29 May 2012.

This work is licensed under a Creative Commons Attribution NonCommercial 3.0 License (CC BY-NC 3.0).

©Copyright T.T. Sio et al., 2012  
Licensee PAGEPress, Italy  
Rare Tumors 2012; 4:e32  
doi:10.4081/rt.2012.e32

(FOLFOX) chemotherapy was initiated. Because his neurological symptoms were felt to be paraneoplastic sequelae of his cancer, he was also empirically started on daily methylprednisolone intravenously (three days total). At his discharge, his leg strength improved and he was walking with minimal assistance. He still required catheterization but could do so by himself at home. He was to have follow-up with a local oncologist to continue his therapy and to monitor the hepatic lesion: ultrasound and MRI of the liver could not differentiate between a metastatic *versus* cystic lesion. Additionally, this hepatic lesion was not easily accessible to percutaneous biopsy. There was much discussion between the hepatology, oncology, surgical, and neurology services. The decision was ultimately made to not immediately remove the cecal mass or hepatic lesion. He continued with additional cycles of FOLFOX chemotherapy, but without any steroids, as an outpatient.

Two months later he presented to his local emergency department, with increasing confusion and a return of tingling and numbness in his legs. Over days he developed increasingly impulsive behaviors and activities, such as buying unnecessary expensive farming equipment, while chopping trees for hours so he could, in his own words, *build a larger house for my family*. On examination, he was agitated with tangential and pressured speech, and again with remarkable bilateral leg weakness. An infectious work-up was negative and a prolonged electroencephalogram was normal.

His altered mental status, along with progressive lower extremity weakness and numbness, was thought to be a return of his paraneoplastic syndrome. He was started on high-

dose prednisone, which brought only temporary relief. Over 10 days he could not be completely weaned off the steroids without re-demonstrating neuropsychiatric symptoms. A multidisciplinary decision was made to treat the hepatic lesion and do a larger colonic resection, as these areas were likely the neoplastic trigger and origin for his symptoms.

The patient underwent a right-sided hemicolectomy with segment III hepatic resection. Pathology confirmed that the hepatic lesion represented metastatic disease from colon cancer. Post-operatively, patient recovered well with marked improvement of his mental status and symptoms, and was successfully discharged home. At neurology follow-up two months later, his saddle anesthesia and leg weakness had fully resolved. He still had agitation and poor sleep which were controlled well by olanzapine (10 mg three times per day) and clonazepam (1 mg daily). Otherwise his neurological exam was within normal limits; his compulsive actions and thoughts had stopped. He continued to remain on a stable dose of oral prednisone (50 mg daily), without any new signs of further paraneoplastic or carcinomatous syndromes at his last follow-up six months later. He received more cycles of adjuvant FOLFOX chemotherapy in the interim as recommended by his medical oncologist.

## Discussion and Conclusions

Out of 115,081 cancer patients, a 10-year Mayo Clinic retrospective study found only 58 patients (0.05%) suffering from a paraneoplastic neurological syndrome, of which five patients had colon cancer.<sup>6</sup> Presentations included peripheral neuropathy and a cerebellar syndrome. However, to the authors' knowledge, this is the first documented case of simultaneous manifestation of a sensory neuropathy and limbic encephalitis in colon cancer.

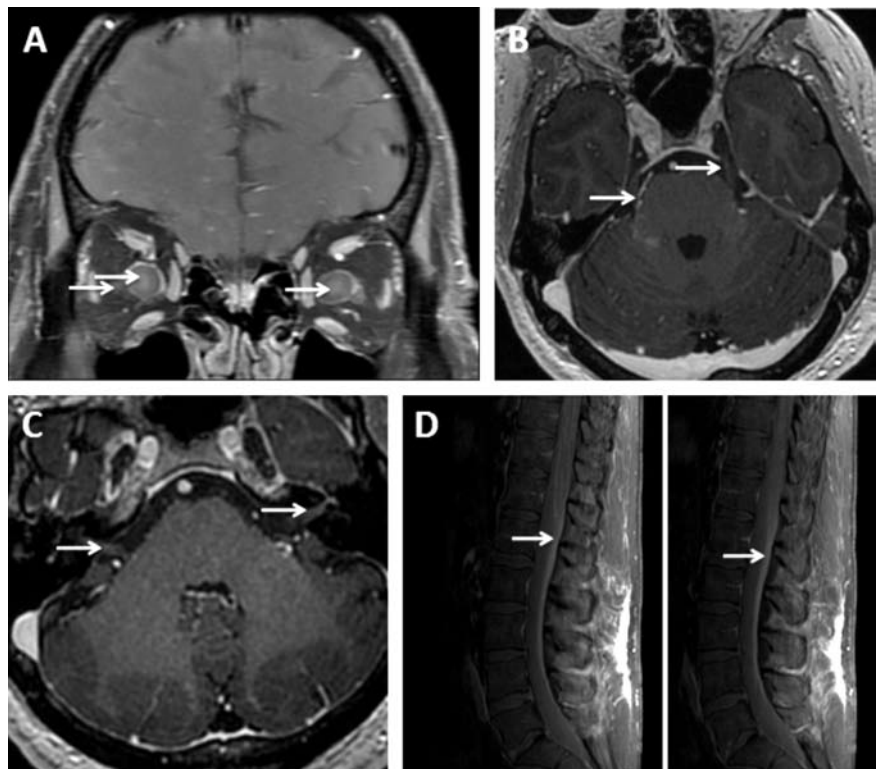
Tsakamoto reported one of the first cases regarding paraneoplastic neurological disorders in colon cancer.<sup>7</sup> In a 55-year-old woman with only a microscopic adenocarcinoma of the colonic polyp, full-blown paraneoplastic cerebellar degeneration and limbic encephalitis ensued. Interestingly, removing the tumor by polypectomy resolved her seizures, but cerebellar damage was permanent. A non-specific anti-neuronal nuclear antibody and its antigen were identified.

Another case report described an unusual example of *P*-ANCA-positive vasculitis in a colon cancer patient, who simultaneously developed vasculitis and impressive neurologic symptoms.<sup>3</sup> The patient developed asthenia and peripheral polyneuropathy, which resolved 4 months later following successful resection and chemotherapy. The authors suggested that

malignant disease could trigger host production of ANCA-associated antibodies, which in turn may give rise to neurologic and vasculitic symptoms. Similar to our case, cerebellar ataxia and myoclonus have been reported as paraneoplastic diseases caused by colon cancer;<sup>2</sup> however, their patient lacked the psychiatric manifestation of the paraneoplastic syndrome, which was present in our case. A Turkish group reported a patient with subacute sensory neuropathy as a preceding sign of colonic cancer recurrence.<sup>8</sup> In another case, sensorimotor neuropathy and axonopathy were found in a patient with sigmoid cancer.<sup>4</sup> The patient's neurologic symptoms resolved upon removal of the sigmoid colon, suggesting a strong paraneoplastic origin similar to our case.

For our patient, we were not able to identify an associated autoantibody in either serum or cerebrospinal fluid. Certainly, we were suspicious of a carcinomatous process, however, extensive work-up including three lumbar punctures with cytology did not reveal malignancy in the central nervous system. Craniospinal carcinomatosis would unlikely respond to non-intrathecal chemotherapy and

surgery, but our patient being symptom-free after such intervention suggested that his clinical neurologic phenomenon was indeed paraneoplastic in nature. Guidelines for diagnosing a paraneoplastic neurological syndrome make an important point that often in the setting of a classical syndrome,<sup>9</sup> the presence of onco-neuronal antibodies is not required. This patient fulfilled the criteria of the symptoms of limbic encephalitis, a classic presentation, with symptoms occurring within five years of identifying a tumor. The clinical improvement and quick resolution of his symptoms after steroids, chemotherapy, and colonic surgery with hepatic metastasectomy were also highly supportive. These point to the fact that there remain unidentified autoantibodies, particularly with regards to neurological presentations - there is a growing number of immune and cellular responses against neuronal receptors which are now increasingly being recognized in patients who were previously thought to be auto-antibody negative.<sup>10,11</sup> Along those lines, the European Federation of Neurological Societies recommend that even if no antibodies are found, patients with such a suggestive



**Figure 1.** Diffuse leptomenigeal disease within the brain and spine as paraneoplastic syndrome caused by colon cancer. These images are the magnetic resonance imaging brain post-gadolinium T1 images. There is abnormal leptomenigeal enhancement along the optic nerve sheaths (A), bilateral third and fifth (B), and seventh and eighth (C) cranial nerves. There is also leptomenigeal disease within the spine (D), including abnormal linear pial enhancement along the conus medullaris and diffuse abnormal linear enhancement of the cauda equina.

presentation and a deteriorating neurological condition should still undergo a basic oncological screen, including a total-body fludeoxyglucose-positron emission tomography.<sup>12</sup> The clinical suspicion must be moderate to high for pursuing such an extensive work-up, but could identify a potentially treatable condition as presented in this report.

## References

1. Dalmau J, Gultekin SH, Voltz R, et al. Ma1, a novel neuron- and testis-specific protein, is recognized by the serum of patients with paraneoplastic neurological disorders. *Brain* 1999;122:27-39.
2. Garcia-Barragan N, Plaza JF, de Luis P, et al. Cerebellar syndrome and myoclonus in a patient with adenocarcinoma of the colon. *Rev Neurol* 1999;28:401-2.
3. Diez-Porres L, Rios-Blanco JJ, Robles-Marhuenda, et al. ANCA-associated vasculitis as paraneoplastic syndrome with colon cancer: a case report. *Lupus* 2005;14:632-4.
4. Pantalone D, Muscas GC, Tings T. Peripheral paraneoplastic neuropathy, an uncommon clinical onset of sigmoid cancer. Case report and review of the literature. *Tumori* 2002;88:347-9.
5. Anderson NE, Barber PA. Limbic encephalitis - a review. *J Clin Neurosci* 2008;15:961-71.
6. Rubin DI, Kimmel DW, Cascino TL. Outcome of peroneal neuropathies in patients with systemic malignant disease. *Cancer* 1998;83:1602-6.
7. Tsukamoto T, Mochizuki R, Mochizuki H, et al. Paraneoplastic cerebellar degeneration and limbic encephalitis in a patient with adenocarcinoma of the colon. *J Neurol, Neurosurg Psychiatry* 1993;56:713-6.
8. Kiylioglu N, Meydan N, Barutca S, et al. Sub-acute sensory neuronopathy as a preceding sign of recurrence in colon carcinoma. *Int J Gastrointest Cancer* 2003;34:135-7.
9. Graus F, Delattre JY, Antoine JC, et al. Recommended diagnostic criteria for paraneoplastic neurological syndromes. *J Neurol Neurosurg Psychiatry* 2004;75:1135-40.
10. Dalmau J, Gleichman AJ, Hughes EG, et al. Anti-NMDA receptor encephalitis: case series and analysis of the effects of antibodies. *Lancet Neurol* 2008;7:1091-8.
11. Bataller L, Galiano R, Garcia-Escrig M, et al. Reversible paraneoplastic limbic encephalitis associated with antibodies to the AMPA receptor. *Neurology* 2010;74:265-7.
12. Titulaer MJ, Sofiattib R, Dalmau J, et al. Screening for tumours in paraneoplastic syndromes: report of an EFNS task force. *Eu J Neurol* 2011;18:19-27.