

Nimotuzumab with intensity-modulated radiation therapy in unresectable and platinum-ineligible locally advanced head-and-neck cancer

K. Satish Srinivas, Raja Sundaram¹, C. V. Divyambika², Sameer Chaudhari³

Abstract

Background: Outcomes with conventional treatment are poor in patients with squamous cell carcinoma of head and neck (SCCHN). Treatment options are further limited for patients ineligible to receive platinum-based chemotherapy due to various factors such as geriatric age, comorbidity, and organ dysfunctions. The present study retrospectively evaluated the effectiveness of nimotuzumab when added to radiation therapy in unresectable, locally advanced SCCHN patients who were ineligible for platinum-based chemotherapy. **Materials and Methods:** The medical records of 21 patients with unresectable, locally advanced head-and-neck cancer and histologically confirmed squamous cell carcinoma who were ineligible for platinum-based chemotherapy treated with nimotuzumab and intensity-modulated radiation therapy (IMRT) from 2012 to 2017 were retrospectively analyzed. The tumor response rate and overall survival (OS) were analyzed. Patients were assessed for toxicity and adverse events (AEs) as per CTCAE version 4. Statistical analysis was performed using SPSS software. **Results:** The median number of doses of nimotuzumab received was 6, and median dose of radiotherapy was 60 Gy. The tumor response rate was calculated at 24 weeks after the completion of radiotherapy and was as follows: 76.2% (16) of patients showed complete response, 9.5% (2) of patients showed partial response, 4.8% (1) of patients showed stable disease, and 9.5% (2) of patients showed progression of disease. Median OS was 21 months, whereas 1-year survival rate was 63.7%. No Grade 3 or Grade 4 AEs were observed. **Conclusion:** Nimotuzumab with IMRT has achieved promising clinical outcomes in unresectable locally advanced SCCHN patients who are ineligible for platinum-based chemotherapy, without accumulation of toxicity.

Key words: Advanced, antibodies, carcinoma, head-and-neck neoplasms, inoperable, monoclonal, nimotuzumab, overall survival, platinum ineligible, squamous cell, therapy

Introduction

Head-and-neck squamous cell cancers (HNSCCs) are one of the most prevalent cancers worldwide, with more than five lakh patients diagnosed annually.^[1] The use of tobacco and Epstein-Barr virus infection are the common causes of these cancers in the Asian population, in comparison to cigarette smoking and alcohol consumption in the Western population.^[2-4] In India, there is an increasing burden of HNSCC, and a majority of patients present with advanced disease.^[4-6] Radical radiotherapy alone is used as a treatment modality in early cancers of the head and neck, whereas cisplatin, in combination with radiotherapy, is the recommended treatment for unresectable and locally advanced stages of the disease.^[7,8] However, a significant fraction of locally advanced cases of HNSCC patients due to various factors such as elderly age, poor performance status, significant comorbidities, renal dysfunction, otologic disorders, and hypersensitivity to platinum drugs are ineligible for platinum-based chemotherapy regimen and are offered radiotherapy alone.^[9] This necessitates the need to explore novel treatment strategies. Squamous cell cancers of head and neck usually express epidermal growth factor receptor (EGFR), the overexpression of which correlates with radiation resistance, poor treatment response, increased rate of metastasis, and hence poor survival.^[10] Thus, EGFR-based targeted therapies have gained attention to improve treatment outcomes. Nimotuzumab (BIOMab EGFR[®]) is a humanized monoclonal antibody (MAb) which binds to the extracellular domain of the EGFR with intermediate affinity and high specificity, which leads to blockade of downstream signal transduction pathways, resulting in antitumor effects.^[11] It also acts as a radiosensitizer and exerts dual benefits.^[8,11] In comparison to other anti-EGFR MAbs, nimotuzumab has few side effects.^[8,12] The BEST trial demonstrated that the addition of nimotuzumab to

chemo-radiotherapy (CRT) or Radiotherapy (RT) resulted in better tumor response and long-term survival benefit in inoperable, locally advanced HNSCC.^[8] Similarly, Rodríguez *et al.* demonstrated the safety and clinical benefits of concurrent nimotuzumab with radiotherapy in locoregionally advanced patients unfit for chemoradiation.^[13] The evidence on the beneficial outcomes achieved by combining nimotuzumab with radiation in unresectable and platinum-ineligible patients is limited in India and needs to be explored. Therefore, the purpose of the present study was to retrospectively analyze the safety and therapeutic benefits of concurrent nimotuzumab with radiotherapy in unresectable, advanced, nonmetastatic patients with squamous cell cancers of head and neck (locoregionally advanced HNSCC [LAHNSCC]) who were ineligible for conventional chemoradiation.

Materials and Methods

In the present study, we retrospectively reviewed the medical records of nonmetastatic LAHNSCC patients who received nimotuzumab with radiation therapy (RT) between 2012 and 2017 at the oncology department of a tertiary care teaching hospital in Chennai (India). Inclusion criteria for this retrospective study were as follows: (1) age 18 years and above, (2) tumor Stage III–IVb, (3) squamous histology, (4) Eastern Cooperative Oncology Group (ECOG) performance score ≤ 3 , (5) unfit for surgery, (6) ineligible for chemotherapy (especially platinum based), and (7) treated with injection nimotuzumab 200 mg IV weekly as infusion and concurrent intensity-modulated radiation therapy (IMRT) with total dose between 60 and 70 Gy. Exclusion criteria included nonsquamous histology and recurrent cancers with a history of prior chemoradiation and/or immunotherapy.

Data regarding patients treated between 2012 and 2017 complying with the above-mentioned inclusion criteria were

Access this article online

Quick Response Code:



Website: www.sajc.org

DOI: 10.4103/sajc.sajc_29_19

Department of Radiation Oncology, Sri Ramachandra Medical College, Sri Ramachandra Institute of Higher Education and Research (DU),¹Department of Radiation Oncology, Global Institute of Oncology, Glen Eagles Global Health City,²Department of Oral Medicine and Radiology, Faculty of Dental Sciences, Sri Ramachandra Institute of Higher Education and Research (DU), Chennai, Tamil Nadu,³Medical Advisor, Biocon Ltd., Bengaluru, Karnataka, India
Correspondence to: Dr. Sameer Chaudhari,
 E-mail: docsameerchaudhari@gmail.com

This is an open access journal, and articles are distributed under the terms of the Creative Commons Attribution-NonCommercial-ShareAlike 4.0 License, which allows others to remix, tweak, and build upon the work non-commercially, as long as appropriate credit is given and the new creations are licensed under the identical terms.

For reprints contact: reprints@medknow.com

How to cite this article: Srinivas KS, Sundaram R, Divyambika CV, Chaudhari S. Nimotuzumab with intensity-modulated radiation therapy in unresectable and platinum-ineligible locally advanced head-and-neck cancer. *South Asian J Cancer* 2020;9:43-6.

extracted from the medical records and analyzed. Data of 21 patients with unresectable, LAHNSCC who were ineligible for platinum-based chemotherapy were included in the final analysis.

Evaluating parameters

At 24 weeks posttreatment, the tumor response rate was calculated using the Response Evaluation Criteria in Solid Tumors (RECIST version 1.1) criteria. The tumor response rate assessed included complete response (CR), partial response (PR), progression of disease, and Stable disease (SD) based on computed tomography/magnetic resonance imaging findings. The objective response rate (ORR) was calculated. Adverse events (AEs) were assessed and graded by the National Cancer Institute's Common Toxicity Criteria version 4.

Statistical analysis

Statistical analysis was performed using SPSS software version 22 (IBM Corp., New York, USA). Median overall survival (OS) along with 95% confidence interval, mean, and the standard error was estimated by the Kaplan–Meier method. The log-rank test was used for the comparison of survival distribution, and the association between the variables was estimated by Chi-square test and Fisher's exact probability test.

Results

A total of 21 patients of LAHNSCC were analyzed. The median age of the patients was 55 years (range: 28–72), with 17 males (81%) and 4 females (19%). The number of patients aged 65 years and less were 13 (61.9%) and those aged >65 years were 8 (38.1%). The most common anatomical site of the tumor was oral cavity (51%) followed by the larynx and hypopharynx. Most patients had good performance status (ECOG-1). Stage IV was the common stage. The median radiation dose received was 60 Gy, along with a median number of six weekly doses of nimotuzumab. The baseline characteristics of unresectable, platinum-ineligible LA-squamous cell carcinoma of head-and-neck (SCCHN) patients are summarized in Table 1.

Tumor response analysis

At 6 months posttreatment, 76.2% ($n = 16$) of patients showed CR, 9.5% ($n = 2$) of patients showed PR, 4.8% ($n = 1$) of patients had static disease (SD), whereas 9.5% ($n = 2$) of patients progressed on treatment. The ORR (CR + PR) achieved was 85.7% [Table 2].

Survival analysis

In this retrospective analysis, we observed that the 1-year survival rate was 63.7%, and the median OS was 21 months [Figure 1].

Subgroup analysis of overall survival with various variables

On further subgroup analysis, we observed that the difference in the mean/median OS with respect to age (>65 years), gender, ECOG status, and tumor stage was not found statistically significant [Table 3].

Safety and toxicity analysis

The side effects encountered during the treatment were leukocytosis, vomiting, and mucositis, and their details are summarized in Table 4. Nimotuzumab was observed to be safe, and no added toxicity was reported.

Discussion

The findings of our retrospective analysis indicate that nimotuzumab with IMRT resulted in improved therapeutic

Table 1: Baseline characteristics of unresectable and platinum ineligible locoregionally advanced head-and-neck squamous cell carcinoma patients

Characteristics	Value (%)
Total patients (n)	21
Age (years)	
Mean±SD	55.4±13.9
Median (range)	55 (28-72)
Age group (years)	
<65	13 (61.9)
≥65	8 (38.1)
Gender	
Male	17 (81)
Female	4 (19)
Performance status	
ECOG - 1	14 (66.7)
ECOG - 2	7 (33.3)
Anatomical sites	
Larynx	4 (19)
Hypopharynx	3 (14.3)
Nasal cavity	2 (9.5)
Oral cavity	10 (47.6)
Oropharynx	2 (9.5)
Tumour stage	
III	7 (33.3)
IVA	10 (47.6)
IVB	4 (19)
T stage	
T2	4 (19)
T3	7 (33.3)
T4	10 (47.6)
M stage	
N1	4 (19)
N2	13 (61.9)
N3	4 (19)
Treatment (Gy)	
Median doses of nimotuzumab received	6
Median dose of radiotherapy received	60

ECOG=Eastern Cooperative Oncology Group, SD=Standard deviation

Table 2: Tumor response at 24 weeks posttreatment

Tumour response at 24 weeks	Total patients=21 Number of patients (%)
CR	16 (72.2)
PR	2 (9.5)
SD	1 (4.8)
PD	2 (9.5)
ORR (CR + PR)	18 (85.7)

CR=Complete response, PR=Partial response, SD=Stable disease, PD=Progressive disease, ORR=Objective response rate

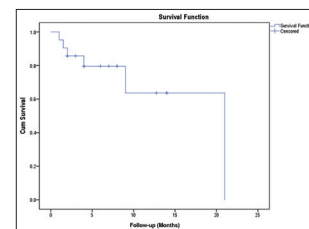


Figure 1: Kaplan–Meier estimates of overall survival in locoregionally advanced squamous cell carcinoma of head and neck treated with nimotuzumab and intensity-modulated radiation therapy

outcomes and better survival benefits in nonmetastatic LAHNSCC patients ineligible for conventional chemoradiation.

Table 3: Subgroup analysis of overall survival with various factors

Parameter	n (%)	Median overall survival (95% CI) in months	P
Patients	21 (100)	21.0 (NR)	
Age			
≤65	13 (61.9)	NR	0.529
>65	8 (38.1)	21	
Gender			
Male	17 (81)	21 (NR)	0.94
Female	4 (19)	9 (NR)	
Tumor stage			
III	7 (33.3)	21 (NR)	0.272
IVA	10 (47.6)	9 (1.8-16.4)	
IVB	4 (19)	8 (NR)	
Performance status			
ECOG - 1	14 (66.7)	21 (NR)	0.49
ECOG - 2	7 (33.3)	21 (NR)	
T stage			
T2	4 (19)	21 (NR)	0.29
T3	7 (33.3)	NR	
T4	10 (47.6)	9 (NR)	
N stage			
N1	4 (19)	21 (NR)	0.045
N2	13 (61.9)	NR	
N3	4 (19)	4 (0-9.2)	

NR=Denotes not reached, ECOG=Eastern Cooperative Oncology Group, CI=Confidence interval

Table 4: Common adverse events encountered during the treatment

Adverse events	Grade 1	Grade 2	Total (%)
Anemia	2	2	4 (9.3)
Neutropenia	3	1	4 (9.3)
Mucositis	4	3	7 (16.3)
Diarrhea	2	1	3 (7.0)
Dysphagia	2	2	4 (9.3)

The MACHNC meta-analysis revealed superior 5-year OS benefit with concurrent CRT (CCRT) only, and cisplatin-based CCRT is the recommended treatment for patients with unresectable, LAHNSCC.^[14] However, platinum-based CCRT is toxic, impacting the quality of life in the survivors, especially with the inherent late toxic effects. Apart from toxicity drawbacks, a large fraction of patients are ineligible for platinum-based chemotherapy regimen due to impaired performance status, reduced nutritional status, geriatric age, and significant comorbidities such as renal dysfunction, otologic disorders, and hypersensitivity to platinum-based therapy. Radiotherapy remains the only treatment option for such platinum-ineligible patients.^[9] The management of unresectable and platinum-ineligible locally advanced SCCHN is a clinical challenge despite the advances in treatment options and therefore, new strategies is the need of the hour for successful management of such tumors.

EGFR is overexpressed in the majority of head-and-neck cancers. The overexpression of the EGFR levels is very much related to tumor growth, proliferation, invasion, metastasis, apoptosis, and poor prognosis. Inhibiting EGFR pathway inhibits the proliferation of tumor cells, differentiation, cancer angiogenesis and promotes better treatment outcome of chemoradiation.^[15] Therefore, anti-EGFR-targeted treatment is considered as a potential addition to the standard treatment

regimens. Nimotuzumab (BIOMAb EGFR) is a new humanized anti-EGFR MAb with proven antitumor activity and has relatively better safety profile than other anti-EGFR MABs.^[8,11,15] It is also known to block the PI3K/AKT pathway and inhibit the activation of DNA-PKcs, thereby improving radiation sensitivity.^[16] In our retrospective analysis, we found that addition of nimotuzumab to IMRT improved tumor response and survival rates in locally advanced SCCHN unfit for surgery and chemotherapy with cisplatin. A study conducted as multicenter trial among Indian population showed that concurrent chemoradiation with cisplatin and BIOMAb given together resulted in a 64% reduction in death risk. While the 5-year OS was 39% in the nimotuzumab + RT group, it was 26% in the RT group. Furthermore, the median follow-up of 65.7 months did not reveal any long-term drug-related toxicity in the study arm. The trial demonstrated that addition of nimotuzumab to CRT or radiotherapy (RT) improved locoregional control and better treatment outcome in unresectable, locally advanced SCCHN.^[8] Similarly, Rodríguez *et al.*, in a controlled, double-blind, randomized clinical trial, assessed the efficacy of nimotuzumab in combination with radiotherapy in 106 advanced SCCHN patients. The trial documented significant CR rate in patients treated with nimotuzumab plus RT (59.5%) as compared to RT plus placebo (34.2%), and the drug was well tolerated in combination with radiotherapy.^[13] Similarly, Talapatra *et al.*, in a prospective trial, evaluated the efficacy and safety of nimotuzumab and IMRT in locally advanced SCCHN patients considered unfit for cisplatin chemotherapy, where the addition of nimotuzumab was found to be safe and efficacious in locally advanced SCCHN patients with 72% of complete locoregional response.^[17] The current study of employing nimotuzumab during IMRT resulted in improved tumor response rate and beneficial survival outcome, where >75% of patients showed CR, the findings of which were similar to those of the previous studies.^[8,13] Nimotuzumab was found to be a safe drug with no added toxicity in the present study. The common AEs observed in our study during the treatment were of Grade 1/2 which included leukocytosis and mucositis, which is similar to previously documented studies.^[8,13] No typical anti-EGFR-related toxicity such as severe rash or hypomagnesemia or infusion reaction was observed. Nimotuzumab binds to cells expressing high EGFR levels in a bivalent manner which is more stable. In normal tissues where EGFR levels are low, it binds in a monovalent manner which is less stable and has minimal effect on normal tissues, thereby providing a better safety profile unlike other anti-EGFR antibodies.^[8,18] To summarize, our study validates the use of nimotuzumab with IMRT as a viable therapeutic option to improve tumor response and survival in inoperable and platinum-ineligible LAHNSCC patients, although robust multicentric, randomized controlled clinical trials with larger sample size are needed to validate these results. The main limitation of the study was that it was a retrospective study. The sample size was small with single-arm assessment.

Conclusion

Nimotuzumab during IMRT will help in bringing a promising treatment response, with no additional toxicity in unresectable LAHNSCC patients ineligible for conventional chemoradiation.

Financial support and sponsorship

Nil.

Conflicts of interest

There are no conflicts of interest.

References

- Jemal A, Bray F, Center MM, Ferlay J, Ward E, Forman D, *et al.* Global cancer statistics. *CA Cancer J Clin* 2011;61:69-90.
- Graham S, Dayal H, Rohrer T, Swanson M, Sultz H, Shedd D, *et al.* Dentition, diet, tobacco, and alcohol in the epidemiology of oral cancer. *J Natl Cancer Inst* 1977;59:1611-8.
- Joshi P, Dutta S, Chaturvedi P, Nair S. Head and neck cancers in developing countries. *Rambam Maimonides Med J* 2014;5:e0009.
- Parikh P, Patil V, Agarwal JP, Chaturvedi P, Vaidya A, Rathod S, *et al.* Guidelines for treatment of recurrent or metastatic head and neck cancer. *Indian J Cancer* 2014;51:89-94.
- Dayal PK, Mani NJ, Bhargava K. Prevalence of oral cancer and precancerous lesions in 'pan'/'supari' chewers. *Indian J Public Health* 1978;22:234-45.
- Tuljapurkar V, Dhar H, Mishra A, Chakraborti S, Chaturvedi P, Pai PS, *et al.* The Indian scenario of head and neck oncology – Challenging the dogmas. *South Asian J Cancer* 2016;5:105-10.
- Vermorken JB, Specenier P. Optimal treatment for recurrent/metastatic head and neck cancer. *Ann Oncol* 2010;21 Suppl 7:vii252-61.
- Reddy BK, Lokesh V, Vidyasagar MS, Shenoy K, Babu KG, Shenoy A, *et al.* Nimotuzumab provides survival benefit to patients with inoperable advanced squamous cell carcinoma of the head and neck: A randomized, open-label, phase IIb, 5-year study in Indian patients. *Oral Oncol* 2014;50:498-505.
- Ahn MJ, D'Cruz A, Vermorken JB, Chen JP, Chitapanarux I, Dang HQ, *et al.* Clinical recommendations for defining platinum unsuitable head and neck cancer patient populations on chemoradiotherapy: A literature review. *Oral Oncol* 2016;53:10-6.
- Agulnik M. New approaches to EGFR inhibition for locally advanced or metastatic squamous cell carcinoma of the head and neck (SCCHN). *Med Oncol* 2012;29:2481-91.
- Perez R, Moreno E, Garrido G, Crombet T. EGFR-targeting as a biological therapy: Understanding nimotuzumab's clinical effects. *Cancers (Basel)* 2011;3:2014-31.
- Ramakrishnan MS, Eswaraiyah A, Crombet T, Piedra P, Saurez G, Iyer H, *et al.* Nimotuzumab, a promising therapeutic monoclonal for treatment of tumors of epithelial origin. *MAbs* 2009;1:41-8.
- Rodríguez MO, Rivero TC, del Castillo Bahi R, Muchuli CR, Bilbao MA, Vinageras EN, *et al.* Nimotuzumab plus radiotherapy for unresectable squamous-cell carcinoma of the head and neck. *Cancer Biol Ther* 2010;9:343-9.
- Pignon JP, le Maître A, Maillard E, Bourhis J; MACH-NC Collaborative Group. Meta-analysis of chemotherapy in head and neck cancer (MACH-NC): An update on 93 randomised trials and 17,346 patients. *Radiother Oncol* 2009;92:4-14.
- Wykosky J, Fenton T, Furnari F, Cavenee WK. Therapeutic targeting of epidermal growth factor receptor in human cancer: Successes and limitations. *Chin J Cancer* 2011;30:5-12.
- Qu YY, Hu SL, Xu XY, Wang RZ, Yu HY, Xu JY, *et al.* Nimotuzumab enhances the radiosensitivity of cancer cells *in vitro* by inhibiting radiation-induced DNA damage repair. *PLoS One* 2013;8:e70727.
- Talapatra K, Deshpande M, Goyle S, Majumder D, Badhwar S, Mistry R. Nimotuzumab and intensity modulated radiation therapy (IMRT) in the concurrent setting of locally advanced head and neck cancers: Early results of a prospective trial in India. *Int J Radiat Oncol Biol Phys* 2016;96:E359.
- Garrido G, Tikhomirov IA, Rabasa A, Yang E, Gracia E, Iznaga N, *et al.* Bivalent binding by intermediate affinity of nimotuzumab: A contribution to explain antibody clinical profile. *Cancer Biol Ther* 2011;11:373-82.