

# Factors determining recurrence of fluid collections following migration of intended long term transmural stents in patients with walled off pancreatic necrosis and disconnected pancreatic duct syndrome

Surinder Singh Rana<sup>1</sup>, Deepak Kumar Bhasin<sup>1</sup>, Ravi Sharma<sup>1</sup>, Rajesh Gupta<sup>2</sup>

<sup>1</sup>Departments of Gastroenterology and <sup>2</sup>Surgery, Post Graduate Institute of Medical Education and Research, Chandigarh, India

## ABSTRACT

**Background and Objectives:** Long-term indwelling transmural stents in patients with walled off pancreatic necrosis (WOPN) and disconnected pancreatic duct syndrome (DPDS) decreases risk of recurrence of pancreatic fluid collection (PFC). However, stents can spontaneously migrate causing recurrence of PFC in some patients whereas some patients may have asymptomatic migration of stents. We aim to retrospectively evaluate profile of patients with recurrent PFC following migration of transmural stents in patients with WOPN and DPDS and compare it with patients who had asymptomatic migration of stents. **Patients and Methods:** Records of consecutive patients who underwent endoscopic transmural drainage of WOPN over last 4 years were analyzed and patients with DPDS identified. Results: Thirty-five patients (29 M; mean age  $37.0 \pm 7.6$  years) were followed-up for mean of  $28.2 \pm 14.0$  months (range: 6–50 months). Eight patients (22.8%) had spontaneous migration of stents. It led to recurrence of PFC in three patients, whereas in five patients it was asymptomatic. The patients with recurrent PFC had early stent migration (2, 4, and 5 months respectively) whereas patients with asymptomatic migration had their stents migrating  $>6$  months of resolution. Patients with recurrent PFC had duct disruption in pancreatic head (100% vs. 20%), and low frequency of diabetes (nil vs. 40%), steatorrhea (nil vs. 20%) as well as pancreatic atrophy (nil vs. 80%). **Conclusion:** Early migration of stents, ductal disruption in pancreatic head as well as absence of diabetes, steatorrhea, and pancreatic atrophy seem to increase risk of recurrent PFC following migration of transmural stents in patients with DPDS.

**Key words:** Acute pancreatitis, computed tomography, endoscopic ultrasound, stent

## INTRODUCTION

Acute necrotizing pancreatitis (ANP) often results in disruption of the main pancreatic duct (PD) and complete PD disruption with a considerable amount

of viable pancreatic parenchyma upstream to the disruption lead on to disconnected pancreatic duct syndrome (DPDS).<sup>[1-4]</sup> The initial management of walled off pancreatic necrosis (WOPN) associated with DPDS is endoscopic transmural drainage with or without endoscopic ultrasound (EUS) guidance and the initial outcome of WOPN and DPDS following endoscopic transmural drainage is excellent, but there is increased frequency of recurrence of pancreatic fluid collections (PFCs) after the removal of transmural stents because of the underlying uncorrected physiological abnormality.<sup>[5]</sup>

### Access this article online

#### Quick Response Code:



#### Website:

www.eusjournal.com

#### DOI:

10.4103/2303-9027.162999

### Address for correspondence

Dr. Surinder Singh Rana, E-mail: drsurinderrana@yahoo.co.in

Received: 2014-06-23; Accepted: 2014-07-21

To reduce this higher frequency of recurrence in patients with DPDS, it has been suggested that transmural stents should be left in for a longer time. Studies have shown that placing transmural stents for longer duration is associated with lower frequency of PFC recurrence.<sup>[3,6,7]</sup> The proposed mechanism for this lower rate of recurrence is that the transmural stents may keep the fistula between the PFC and the digestive tract patent, thereby preventing recurrence.<sup>[2,3,6,7]</sup> The major concerns of leaving transmural stents for long duration is a risk of stent occlusion with consequent infectious complications and fracture of plastic stents. However, fortunately none of these complications have been described in the literature.

Although, long term transmural stents have been shown to be safe in the majority of patients, stent migration occurs in a significant proportion of patients and this increases the risk of PFC recurrence.<sup>[2,3]</sup> There are few reports of intestinal obstruction caused by migrated stents also.<sup>[6]</sup> Moreover, many patients with spontaneous migration of stents do not have a recurrence of PFC.<sup>[2,3,6,7]</sup> This subset of patients who do not have a recurrence of PFC following migration of stents could benefit from scheduled removal of stents. Therefore, it is important to identify the factors that could identify patients at both high, as well as low risk of recurrence of PFC following removal of transmural stents. This would help in better management of these patients as stents could be removed in patients with low risk of recurrence whereas patients with high risk of recurrence would require close monitoring.

In this retrospective study, we compared the clinical and investigational profile of patients who developed recurrent PFC following migration of transmural stents in patients with WOPN and DPDS with that of patients who had asymptomatic migration of stents.

## PATIENTS AND METHODS

A retrospective analysis of the collected data of the patients who underwent EUS-guided transmural drainage of symptomatic WOPN over last 4 years to identify patients with WOPN and DPDS was done. The details of the endoscopic procedure have been described by us in previously published reports.<sup>[3,4]</sup> An informed consent was obtained from all the patients prior to procedure, and the study protocol had been approved by the Institutional Ethics Committee.

Endoscopic ultrasound-guided drainage was performed using a linear scanning echo endoscope EG 3870 UTK (Pentax Inc, Tokyo, Japan) or GF-UCT 180 (Olympus Corp., Tokyo, Japan). Following the successful resolution of WOPN, an endoscopic retrograde cholangiopancreatography (ERCP) was performed to document pancreatic duct disruption and identify patients with DPDS. In these patients, 1-3 7 Fr/10 Fr double-pigtail stents, 5 cm in length, were left indefinitely in the resolved collection.

### *Follow-up*

The patients with DPDS and indefinite indwelling transmural stents were advised 3 monthly clinical follow-up in our clinic and were asked to report immediately if they noticed the passage of the plastic stents in the stool. The patients not reporting to the clinic were contacted telephonically three monthly for any symptoms or hospitalization. The patients reporting with history of the passage of stents in the stools underwent abdominal skiagram to confirm the passage of the stents. If no stents were observed on abdominal X-ray, contrast enhanced computed tomography (CECT) of the abdomen was performed to detect recurrence of PFC, if any. Furthermore, patients underwent abdominal X-ray every 6 months to confirm the presence of transmural stents. The patients also underwent measurements of fasting blood sugar as well as glycosylated hemoglobin levels every 6 months or when the patients reported symptoms of hyperglycemia. Patients reporting with new symptoms like abdominal pain, fever or jaundice underwent CECT to confirm the presence of transmural stents as well as to detect recurrence of PFCs. The patients with recurrence of PFCs underwent further investigations such as magnetic resonance cholangiopancreatography, EUS, and ERCP for appropriate management. The clinical and investigational profile of patients who developed recurrent PFC following migration of transmural stents was compared with that of patients who had asymptomatic migration of stents.

## RESULTS

Thirty-five patients (29 M; mean age  $37.0 \pm 7.6$  years) with permanent indwelling transmural stents and DPDS were followed-up for a mean of  $28.2 \pm 14.0$  months (range: 6-50 months). The etiology of ANP was alcohol in 24 (68.5%), gall stones in 9 (25.7%) and idiopathic in 2 (5.8%) patients. In all patients two or three, 7 Fr (18 [51.4%] patients) or 10 Fr (17 [48.6%]

patients) 5 cm double pigtail stents were placed. Eight patients (22.8%) had spontaneous migration of all stents (10 Fr in one and 7 Fr in 7 patients). Stent migration led to recurrence of PFC in three patients whereas in five patients it did not cause any symptoms and were detected by passage of stents in stools. The stent migration was confirmed by their absence on abdominal X-ray.

The patients with recurrent PFC had early stent migration (<6 months after of resolution of WOPN; 2, 4, and 5 months respectively) whereas all the patients with asymptomatic migration of transmural stents had their stents migrated after 6 months of resolution of WOPN (mean: 20 ± 8 months) [Figures 1 and 2]. Furthermore, the patients with recurrent PFCs had increased frequency of duct disruption at the pancreatic

head level (100% vs. 20%;  $P = 0.14$ ), and decreased frequency of diabetes mellitus (nil vs. 40%;  $P = 1.0$ ), steatorrhea (nil vs. 20%;  $P = 1.0$ ) as well as atrophy of pancreatic parenchyma on follow-up cross-sectional imaging (nil vs. 80%;  $P = 0.49$ ). The diabetes and steatorrhea developed in these patients before the stents migration was detected. The diabetes developed 4 and 10 months after the successful resolution of WOPN and both patients required insulin for controlling blood sugar.

One of the patients with recurrent PFC required surgery whereas the other two were managed conservatively. The patients with asymptomatic migration of transmural stents are asymptomatic over a follow-up period of 6-18 months. No complications of long-term indwelling transmural stents were observed in the cohort of patients with nonmigrated transmural stents.

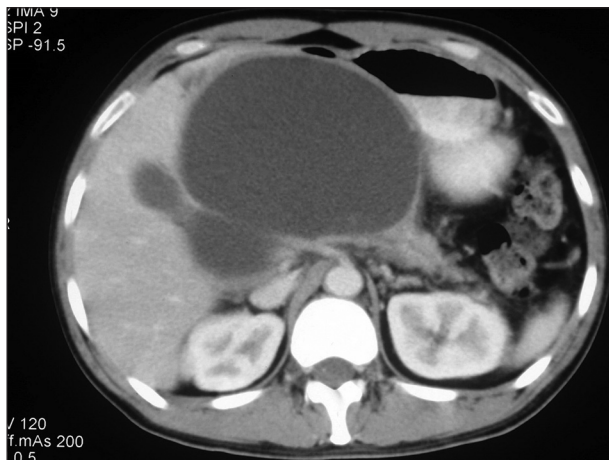


Figure 1a. Large walled off pancreatic necrosis

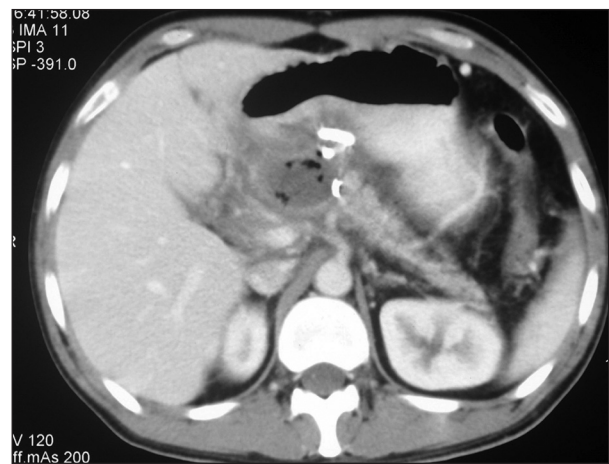


Figure 1b. Follow-up computed tomography after resolution of walled off pancreatic necrosis shows transmural stent in place with a small residual collection. Disconnected tail of pancreas noted

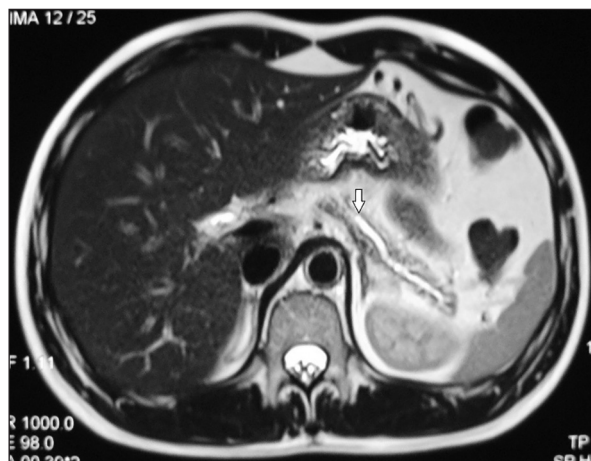

Figure 1c. Patient presented 14 months later with asymptomatic migration of stents. This patient had diabetes with blood sugars controlled on insulin. Magnetic resonance cholangiopancreatography shows dilated main pancreatic duct in the tail (arrow) with disconnection in the pancreatic body

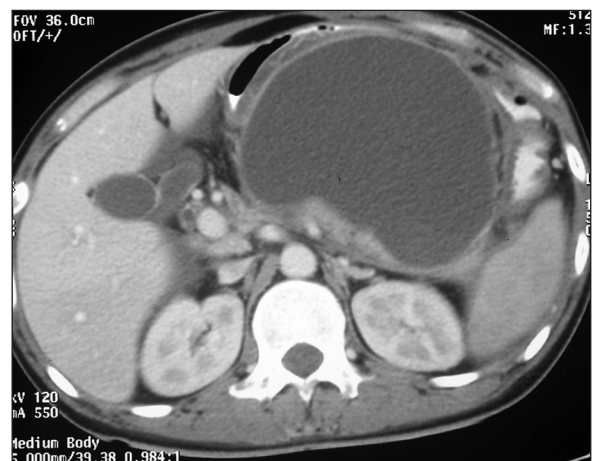
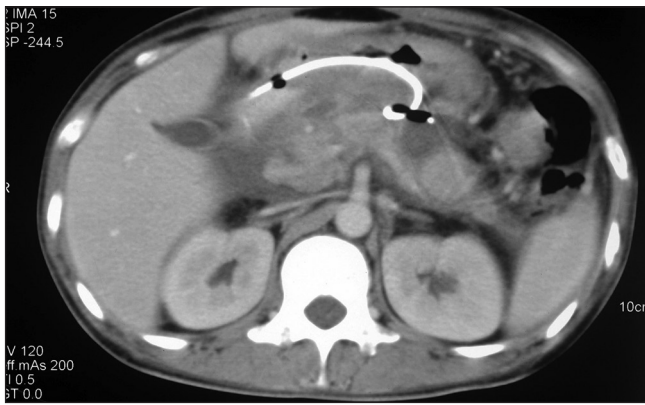


Figure 2a. Large walled off pancreatic necrosis



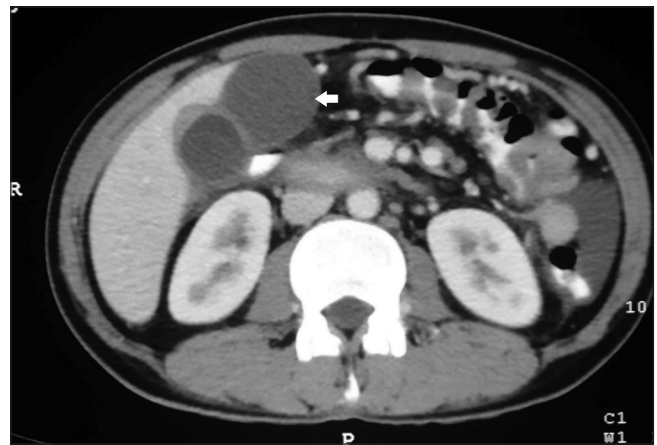
**Figure 2b.** Follow-up computed tomography after resolution of walled off pancreatic necrosis shows transmural stent in place with peri-pancreatic inflammatory changes

## DISCUSSION

Patients with WOPN and DPDS are a therapeutic challenge because of high risk of recurrences of PFC following the removal of transmural stents as the underlying physiological abnormality remains uncorrected. One of the strategies suggested reducing this higher frequency of recurrence in patients with DPDS has been to leave the transmural stents indefinitely. These transmural stents possibly keep the trans enteric fistula between the PFC and the digestive tract patent, thereby preventing recurrence.<sup>[2,3,6,7]</sup> Studies including an earlier published study by us has shown that this strategy of leaving transmural stents indefinitely is safe and effective and prevents recurrence of PFCs.<sup>[2,3,6,7]</sup>

Stent migration occurs in a significant proportion of these patients and some of these patients with migrated stents tend to have PFC recurrence. This has prompted the use of shorter and larger diameter stents that seem to have decreased risk of migration.<sup>[3]</sup> While treating these patients, we observed that all the patients with migrated stents did not have a recurrence of PFC. Therefore, if we are able to identify these patients earlier, the transmural stents can be removed electively, and these patients would not be at risk of potential complications of long-term transmural stents.

In the current study, we found that the PFC recurred in patients who had early stent migration (<6 months after of resolution of WOPN) whereas all the patients with asymptomatic migration of transmural stents had their stents migrated after 6 months of resolution of WOPN. Other studies have also shown that the



**Figure 2c.** Patient presented 5 months later with abdominal pain and computed tomography shows a subhepatic collection (arrow) and no stents are visualized

recurrences following transmural stent removal usually occur during the 1<sup>st</sup> year after treatment.<sup>[7,8]</sup> These observations suggest that leaving transmural stents for a longer time helps in maturation of the fistulous tract and an earlier migration/removal of stents would lead to recurrence of PFC because of the closure of the transenteric fistula.

Furthermore, the patients with recurrent PFCs had increased frequency of duct disruption at the pancreatic head level, and decreased frequency of diabetes mellitus, steatorrhea as well as atrophy of pancreatic parenchyma on follow-up cross-sectional imaging. The diabetes and steatorrhea developed in these patients before the stents migration was detected. Although this difference was not statistically significant, but very small number of patients in each group would have limited the utility of statistical analysis. However, rarity of this condition coupled with limited published experience on this topic makes these findings important.

Our observations suggest that patients who have significant pancreatic necrosis leading on to pancreatic exocrine/endocrine dysfunction are at low risk of PFC recurrence following migration/removal of stents possibly because of decreased pancreatic juice secretion, as a result, of the limited pancreatic reserve. Furthermore, patients having upstream pancreatic ductal disruption (PD disruption in body/tail) had a low risk of PFC recurrence possibly because of the presence of a small amount of viable pancreatic parenchyma upstream to the ductal disruption.

Our findings suggest that that in patients with WOPN and DPDS, who had PD disruption in body/tail, transmural stents *in situ* for >6 months and have developed pancreatic insufficiency, the stents can be removed as these patients have a low risk of PFC recurrence. On the other hand, patients with PD disruption in head/neck of pancreas with no pancreatic insufficiency need to be closely monitored for migration of stents and consequent recurrence of PFCs.

The small sample size with very few patients with recurrent PFCs and retrospective nature are the limitations of the current study. Furthermore, we did not follow-up the patients for the development of parenchymal changes of chronic pancreatitis with sensitive imaging techniques like EUS.

## CONCLUSION

Early migration of transmural stents, ductal disruption in head, as well as absence of diabetes, steatorrhea, and pancreatic atrophy seems to increase the risk of recurrent PFC following migration of transmural stents in patients with DPDS.

## REFERENCES

1. Neoptolemos JP, London NJ, Carr-Locke DL. Assessment of main pancreatic duct integrity by endoscopic retrograde pancreatography in patients with acute pancreatitis. *Br J Surg* 1993;80:94-9.
2. Varadarajulu S, Rana SS, Bhasin DK. Endoscopic therapy for pancreatic duct leaks and disruptions. *Gastrointest Endosc Clin N Am* 2013;23:863-92.
3. Rana SS, Bhasin DK, Rao C, et al. Consequences of long term indwelling transmural stents in patients with walled off pancreatic necrosis & disconnected pancreatic duct syndrome. *Pancreatology* 2013;13:486-90.
4. Rana SS, Bhasin DK, Rao C, et al. Non-fluoroscopic endoscopic ultrasound-guided transmural drainage of symptomatic non-bulging walled-off pancreatic necrosis. *Dig Endosc* 2013;25:47-52.
5. Pelaez-Luna M, Vege SS, Petersen BT, et al. Disconnected pancreatic duct syndrome in severe acute pancreatitis: Clinical and imaging characteristics and outcomes in a cohort of 31 cases. *Gastrointest Endosc* 2008;68:91-7.
6. Varadarajulu S, Wilcox CM. Endoscopic placement of permanent indwelling transmural stents in disconnected pancreatic duct syndrome: Does benefit outweigh the risks? *Gastrointest Endosc* 2011;74:1408-12.
7. Arvanitakis M, Delhaye M, Bali MA, et al. Pancreatic-fluid collections: A randomized controlled trial regarding stent removal after endoscopic transmural drainage. *Gastrointest Endosc* 2007;65:609-19.
8. Bhasin DK, Rana SS. Combining transpapillary pancreatic duct stenting with endoscopic transmural drainage for pancreatic fluid collections: Two heads are better than one! *J Gastroenterol Hepatol* 2010;25:433-4.

**How to cite this article:** Rana SS, Bhasin DK, Sharma R, Gupta R. Factors determining recurrence of fluid collections following migration of intended long term transmural stents in patients with walled off pancreatic necrosis and disconnected pancreatic duct syndrome. *Endosc Ultrasound* 2015;4:208-12.

**Source of Support:** Nil. **Conflicts of Interest:** None declared.