

Access this article online

Quick Response Code:



Website:
www.jehp.net

DOI:
10.4103/jehp.jehp_6_19

Liver and thyroid profile in educating smokeless tobacco users and its role in oral health promotion

Tanya Khaitan, Anjani Kumar Shukla, Prashant Gupta, Shantala R. Naik, Pratik Verma¹, Surender Kumar²

Abstract:

BACKGROUND: Smokeless tobacco (SLT) usage contributes about 40% of the total tobacco used in India. Among the 28 known carcinogens in SLT, tobacco-specific nitrosamines are considered to be the most potent. This has challenged the metabolic condition leading to a rise in the inflammatory status, hepatic injury, and apoptosis of the liver and thyroid tissues. Therefore, the present study was undertaken to evaluate the adverse effects of SLT on the liver and thyroid and establish a correlation between them in Jharkhand population.

MATERIALS AND METHODS: A total of 100 individuals (50 SLT users and 50 healthy individuals) were selected for the study. A complete history was obtained, and clinical examination was done to evaluate any oral mucosal changes. Venous blood samples were taken to analyze the liver function test and thyroid profile.

RESULTS: Significant changes were observed in the liver enzyme levels and thyroid profile in SLT users when compared to healthy controls. All the parameters of liver function test had a positive correlation with the form of SLT, whereas thyroid profile had a negative correlation.

CONCLUSION: This study might be helpful in creating awareness on the hazards of using SLT among the Indian population as a despicable substitute to smoking tobacco. It also acts as a diagnostic tool and warning alarm in chronic tobacco users.

Keywords:

Liver function test, oral mucosa, smokeless tobacco, thyroid profile

Department of Oral
Medicine and Radiology,
¹Orthodontics and
Dentofacial Orthopaedics
and ²Prosthodontics,
Crown and Bridge,
Esthetic Dentistry and
Oral Implantology, Dental
Institute, Rajendra Institute
of Medical Sciences,
Ranchi, Jharkhand, India

Address for correspondence:

Dr. Tanya Khaitan,
Department of Oral
Medicine and Radiology,
Dental Institute,
Rajendra Institute of
Medical Sciences,
Ranchi - 834 009,
Jharkhand, India.
E-mail: tanyakhaitan@
gmail.com

Received: 05-01-2019

Accepted: 02-04-2019

Introduction

The tradition of smokeless tobacco (SLT), such as “chewing tobacco” or “spit tobacco,” is becoming a global menace to human health with each transitory day owing to its numerous deleterious effects.^[1] As per the Global Adult Tobacco Survey, across 16 countries, 3 billion people are using tobacco products in different forms.^[2] The World Health Organization’s Southeast Asia region is domicile to 90% of global SLT users as over 250 million of such users live in this region.^[3] During the first two decades of the

This is an open access journal, and articles are distributed under the terms of the Creative Commons Attribution-NonCommercial-ShareAlike 4.0 License, which allows others to remix, tweak, and build upon the work non-commercially, as long as appropriate credit is given and the new creations are licensed under the identical terms.

For reprints contact: reprints@medknow.com

21st century, India is predicted to experience the fastest rate of rise in deaths attributable to tobacco worldwide. Given a population of over one billion people, this exponential increase in tobacco-related mortality from 1.4% of all deaths in India in 1990 to 13.3% in 2020 will result in tremendous social and economic burden for the country.^[4] The Global Adult Tobacco Survey-2 reports that 28.6% of the population consume tobacco in any form, 10.7% smoke, and 21.4% use SLT.^[5] The prevalence of SLT in India ranges from about 5% in Himachal Pradesh and Goa to nearly 50% in Bihar, Jharkhand, and Chhattisgarh.^[3]

SLT is used in various forms in India such as paan with tobacco, paan masala, khaini,

How to cite this article: Khaitan T, Shukla AK, Gupta P, Naik SR, Verma P, Kumar S. Liver and thyroid profile in educating smokeless tobacco users and its role in oral health promotion. J Edu Health Promot 2019;8:224.

areca nut and slaked lime preparations, kiwam, zarda, mawa, snus, mishri, and gul.^[6,7] The tobacco plus lime mixture is the most common variant of the betel quid frequently known as khaini in the northern part of India. Chewing tobacco is mixed with betel leaves, areca nut, lime, and catechu, available in the Indian market as “gutkha,” and comprises a vast number of toxicants and carcinogens that are also found in cigarette smoke causing a plethora of systemic diseases.^[1,7] These products are used without combustion and eradicate the danger of direct exposure of toxic combustion compounds to the lung and other tissues of the users and people around. However, it may result in other local or systemic health hazards, according to the manner of administration and the content of nicotine and tobacco-specific nitrosamines.^[2]

Considering the above background, the aim and objectives of the present study were to determine the effect of SLT on the liver and thyroid, evaluate the correlation of SLT form with oral mucosal changes, liver function test, and thyroid profile, and describe its role in oral health promotion.

Materials and Methods

The study was initiated after the protocol had been approved by the Institutional Committee of Research Ethics. A total of 100 individuals (50 SLT users and 50 healthy controls) reporting to the Department of Oral Medicine and Radiology, Dental Institute, RIMS, Ranchi, were recruited in the study. The patients enrolled in the study belonged to the age group of 20–85 years. All the individuals were being explained about the study, and written informed consent was obtained.

Healthy individuals with a history of consumption of SLT in any form were selected as cases. Age- and sex-matched healthy individuals with no history of tobacco consumption in any form and no history of any systemic illnesses were selected as controls. Individuals with any systemic illness of the liver and thyroid or any other immunocompromised condition, those under alcohol consumption, and those not willing to participate were excluded from the study.

The armamentarium for the present study consisted of diagnostic instruments, 5-ml syringe, vials containing ethylenediaminetetraacetic acid (EDTA), tourniquet, sterile cotton, and surgical gloves. Five milliliters of venous blood was collected from all patients using routine venipuncture method and stored in vials containing EDTA. Liver function test was being performed using BA400 Biosystem and thyroid profile by serum chemiluminescent microparticle immunoassay

method using I1000/I2000 Architect at the hematology laboratory of the institution.

All the data obtained was noted in a pro forma, especially designed for the study. Comparison of the parameters of the liver function test and thyroid profile in cases and controls was performed using *t*-test and Spearman’s rank correlation coefficient using SPSS version 16.01 software. IBM, Chicago, USA. Significance level was considered at 1% ($P < 0.01$) and 5% ($P < 0.05$).

Results

A total of 100 individuals, 50 SLT users (48 males and 2 females) and 50 healthy controls (46 males and 4 females) with a mean age of 40.2 years and 40.5 years, respectively, were selected for the study. Liver function test and thyroid profile were performed for all individuals.

Among 50 cases, 29 consumed khaini, whereas 21 consumed gutkha. When duration of the habit was being compared, majority of the individuals (23 cases) reported with >10 years, followed by 5–10 years (15 cases) and <5 years (12 cases). The mean average of duration of khaini consumption was 16.14 years with frequency of 10.93 times/day. The mean average of gutkha consumption was 6.24 years with frequency of 6.33 times/day.

The various oral mucosal changes observed were white lesion (17 cases), proliferative/ulcerative growth (17 cases), and mixed red and white lesions (2 cases) [Figure 1]. No mucosal changes were observed in 14 individuals. Burning sensation was noted in 26 cases.

Correlation of liver function test in cases and controls

The mean serum glutamate-pyruvate transaminase (SGPT) level was higher in cases (42.72 U/L) when compared to controls (22.62 U/L), which was statistically significant with $P = 0$ [Graph 1]. The mean serum glutamic-oxaloacetic transaminase (SGOT) level was also seen to be higher in cases (33.35 U/L) when compared to controls (26.06 U/L) with $P < 0.01$ [Graph 2]. The

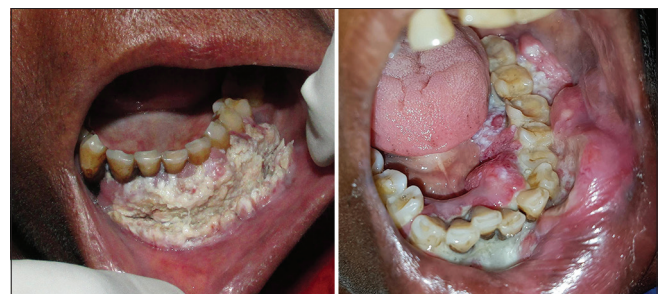

Figure 1: Oral mucosal changes showing white lesion (left) and proliferative/ulcerative growth (right)

mean serum alkaline phosphatase level was significantly higher in cases (124.90 U/L) than in controls (75.20 U/L) with $P = 0$ [Graph 3]. The mean serum albumin and globulin levels did not show much difference in cases and controls and it was statistically nonsignificant ($P = 0.24$ and 0.49 , respectively). The mean serum direct bilirubin (cases – 0.38 mg/dl, controls – 0.24 mg/dl) and indirect bilirubin (cases – 0.54 mg/dl, controls – 0.39 mg/dl) levels were higher in cases and statistically significant with $P < 0.01$ [Graphs 4 and 5].

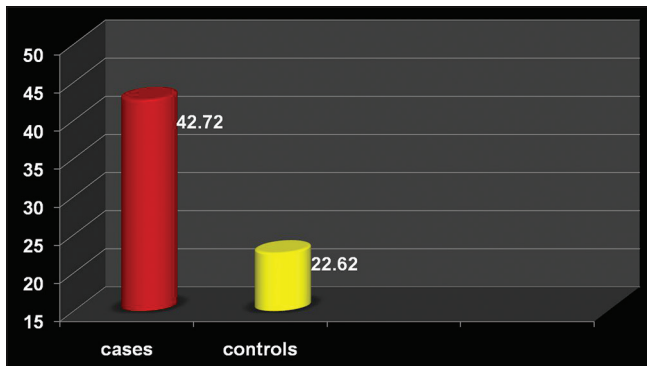
Correlation of thyroid profile in cases and controls

The mean serum T3 level was higher in cases (4.65 ng/ml) when compared to controls (0.91 ng/ml)

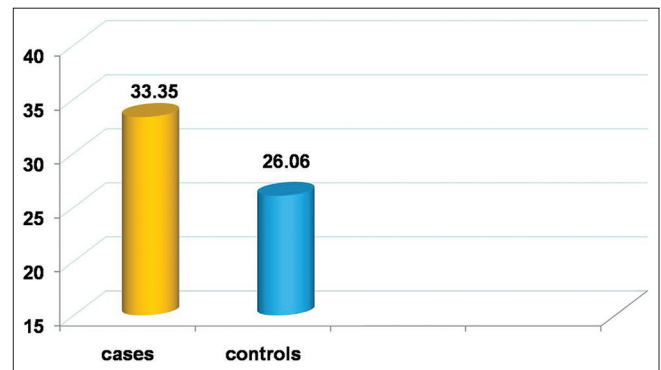
and statistically significant with $P < 0.05$ [Graph 6]. The mean serum T4 level was lower in cases (5.85 $\mu\text{g/dl}$) when compared to controls (7.64 $\mu\text{g/dl}$) with highly significant ($P < 0.01$) [Graph 7]. There was no much considerable difference in the mean serum thyroid-stimulating hormone (TSH) level in cases (2.15 $\mu\text{IU/ml}$) and controls (2.50 $\mu\text{IU/ml}$) which was statistically nonsignificant ($P = 0.47$).

Correlation of form of smokeless tobacco with oral mucosal changes, liver function test, and thyroid profile

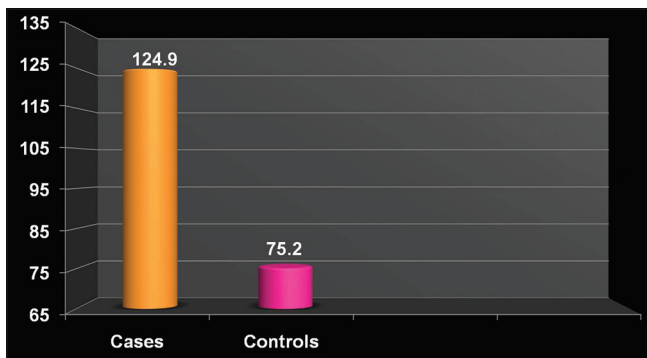
Spearman's correlation coefficient test was performed to correlate the form of SLT and oral mucosal changes and



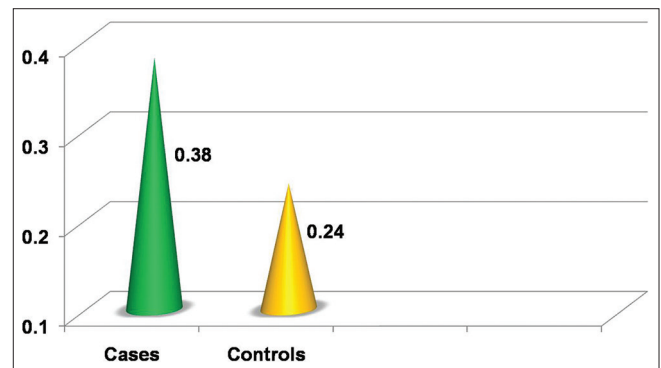
Graph 1: Comparison of serum glutamate-pyruvate transaminase levels in cases and controls



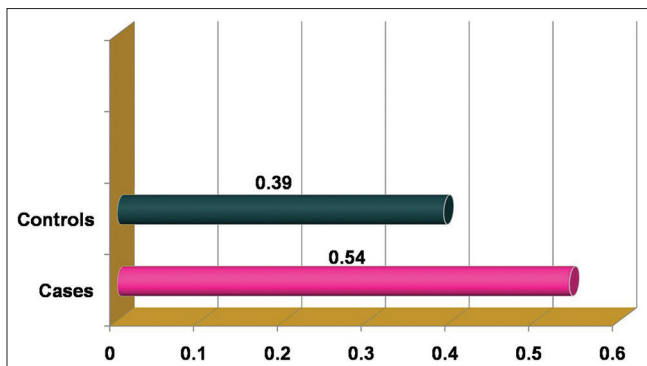
Graph 2: Comparison of serum glutamic-oxaloacetic transaminase levels in cases and controls



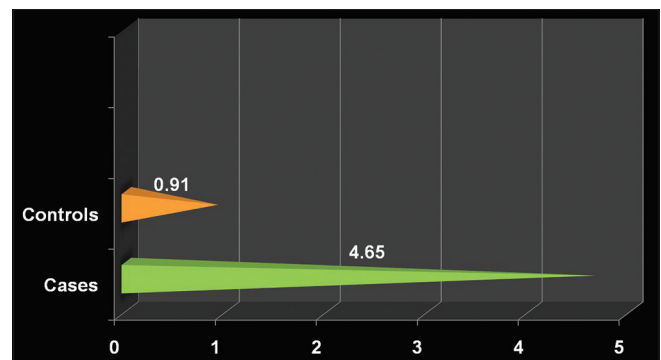
Graph 3: Comparison of serum alkaline phosphatase levels in cases and controls



Graph 4: Comparison of serum direct bilirubin levels in cases and controls



Graph 5: Comparison of serum indirect bilirubin levels in cases and controls



Graph 6: Comparison of serum T3 levels in cases and controls

was found to be statistically significant with $P < 0.01$. This elucidated the fact that more the consumption of khaini and gutkha, more the oral mucosal changes were observed. All the parameters of liver function test had a positive correlation with khaini and gutkha, whereas thyroid profile had a negative correlation and both were statistically not significant [Table 1]. This was suggestive of the fact that both khaini and gutkha had equally adverse systemic effects on the liver and thyroid.

Discussion

The majority of commercially available tobacco products use *Nicotiana tabacum* species. Nicotine is psychoactive ingredient, metabolically inactivated by CYP2A6 to cotinine, further metabolized to pyridine-N-glucuronides, nicotine-N-Gluc, and cotinine-N Gluc in the liver. Nicotine also inhibits antigen-mediated signaling in T-cells and blocks the proliferation and differentiation of lymphocyte and suppression of antibody-forming cells. There is an increased production of pro-inflammatory cytokines (interleukin-1 [IL-1], IL-6, and tumor necrosis factor-alpha) which are involved in hepatocellular injury.^[2]

Tobacco contains >2500 documented chemical constituents, including chemicals applied to tobacco during cultivation, harvesting, and processing. Chewing tobacco contains more than two dozen ingredients

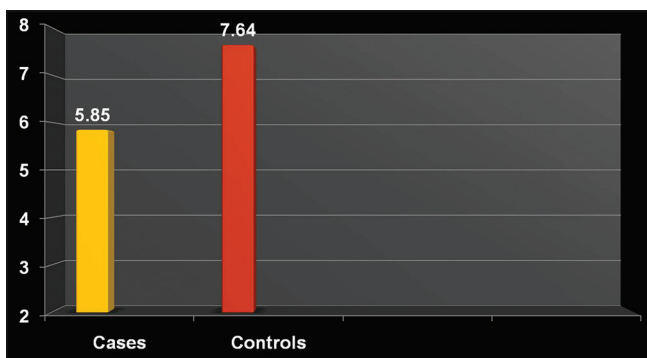
causing cancer, three to four times more nicotine than that delivered by a cigarette, and stays for a longer time in the bloodstream. The rate of absorption may vary among different forms of SLT depending on the pH level of the product, amount of nicotine, and size of the tobacco cutting.^[2,8]

SLT consumption is more prevalent among lower socioeconomic groups in India that includes poor and semi-skilled manual workers and unemployed people with meager education. It is believed that the usage of SLT relieves the work-related stress and has healing properties for curing toothache, headache, and stomach ache which dictates many adults to accede to its usage. Curiosity, peer pressure, offered by friends, and acquaintances contribute to the initiation of its use.^[1] Tobacco use is more common among males when compared with females.^[3,4] Male predominance was seen in the present study.

Habit of chewing or holding of SLT in the oral cavity also allows absorption of nicotine and other carcinogens through the oral mucosa. This could be attributed to injury to the oral epithelium caused by tobacco-related toxic products which in turn increases mucosal permeability and penetration of carcinogens. Orally absorbed nicotine also stays longer in the bloodstream. As an early sign of damage to the oral mucosa, chewers of SLT with or without tobacco often develop clinically visible whitish (leukoplakia) or reddish (erythroplakia) lesions and/or stiffening of the oral mucosa and oral submucous fibrosis which later transforms into malignancy. All these oral mucosal changes were observed in the present study.^[1,7,8]

SLT is hepatotoxic causing mixed type of hepatic injury, which is both cholestatic and hepatocellular, and increases both serum transaminases and alkaline phosphatase. Literature reveals hepatic lipid peroxidation-induced damage to the DNA causing mutation which might later lead to hepatocellular carcinoma in SLT users.^[2,9] Higher serum SGPT, SGOT, alkaline phosphatase, and direct and indirect bilirubin levels were observed in cases when compared to controls in the present study and were statistically significant. Similar increases in liver enzyme levels were also seen in studies conducted by Alwar *et al.* and Ramya and Anuradha.^[2,7] In contrary, no significant changes in liver enzyme levels were seen in a study conducted by Dass *et al.*^[10]

Animal studies have shown that arecoline in acute administration causes an increased release of T3 and T4 and suppression of TSH. In large doses, it activates the hypothalamic-pituitary-adrenal axis, similar to stress response, and in regular use causes hypothyroidism.^[9,11] Higher serum T3 and lower T4 levels were seen in cases



Graph 7: Comparison of serum T4 levels in cases and controls

Table 1: Correlation of form of smokeless tobacco with liver function test and thyroid profile

Parameters	Spearman correlation (rho)	P
SGOT	0.14	0.35
SGPT	0.21	0.15
ALP	0.05	0.74
Direct bilirubin	0.23	0.11
Indirect bilirubin	0.01	0.94
T3	-0.46	0.75
T4	-0.10	0.47
TSH	-0.65	0.66

SGOT=Serum glutamic-oxaloacetic transaminase, SGPT=Serum glutamate-pyruvate transaminase, ALP=Alkaline phosphatase, TSH=Thyroid-stimulating hormone

when compared to controls in the present study. There was no much considerable difference seen in serum TSH levels. Literature shows that no previous studies were done to evaluate the association of SLT with thyroid profile in humans. This was the first attempt undertaken to establish a correlation of SLT with thyroid profile.

Conclusion

Biochemical parameters such as liver function test and thyroid profile can act as a diagnostic tool and alarming signal in chronic SLT users. This present study might also be helpful in creating awareness on the hazards of using SLT among the Indian population as a despicable alternative to tobacco smoke. Evasion of tobacco chewing could avert many cancer deaths. Nicotine replacement therapy along with antioxidants should be prescribed in individuals who are willing to quit SLT and help them in preventing the imminent damage to the liver and possibly other organs in the body. Awareness campaigns carried out among youths regarding the deleterious effect of tobacco may lower the adverse effects.

Providing acknowledgment, ethical moral code.

Acknowledgment

The authors would like to thank Dr. Ritika Jain, MSc. (Economics), PhD (Economics), for her valuable support and guidance in statistical analysis for our original research.

Declaration of patient consent

The authors certify that they have obtained all appropriate patient consent forms. In the form, the patients have given their consent for their images and other clinical information to be reported in the journal. The patients understand that their names and initials will not be

published and due efforts will be made to conceal their identity, but anonymity cannot be guaranteed.

Financial support and sponsorship

Nil.

Conflicts of interest

There are no conflicts of interest.

References

1. Biswas S, Manna K, Das U, Khan A, Pradhan A, Sengupta A, *et al.* Smokeless tobacco consumption impedes metabolic, cellular, apoptotic and systemic stress pattern: A study on government employees in Kolkata, India. *Sci Rep* 2015;5:18284.
2. Alwar V, Ramesh R, Niranjana G, Kala C. Biochemical assessment of liver damage in smokeless tobacco users. *Int J Curr Res Rev* 2013;5:63-9.
3. Sinha DN, Gupta PC, Ray C, Singh PK. Prevalence of smokeless tobacco use among adults in WHO South-East Asia. *Indian J Cancer* 2012;49:342-6.
4. Vikneshan M, Ankola AV, Hiremath A, Hebbal M, Suganya M. Smokeless tobacco and its adverse effects on oral cavity – An overview. *Ann Dent Spec* 2014;2:64-9.
5. Mohan P, Lando HA, Panneer S. Assessment of tobacco consumption and control in India. *Indian J Clin Med* 2018;9:1-8.
6. Vidhubala E, Pisinger C, Basumallik B, Prabhakar DS. The ban on smokeless tobacco products is systematically violated in Chennai, India. *Indian J Cancer* 2016;53:325-30.
7. Ramya M, Anuradha R. Biochemical changes in betel quid chewers and non-chewers of Kakkarai, Thanjavur district of Tamil Nadu. *Asian J Pharm Clin Res* 2015;8:122-4.
8. Muthukrishnan A, Warnakulasuriya S. Oral health consequences of smokeless tobacco use. *Indian J Med Res* 2018;148:35-40.
9. Garg A, Chaturvedi P, Gupta PC. A review of the systemic adverse effects of areca nut or betel nut. *Indian J Med Paediatr Oncol* 2014;35:3-9.
10. Dass BP, Jagannathan P, Sravanakumar P. Changes in hematological and biochemical parameters in smokeless tobacco (ST) chewers in coastal belt of Andhra Pradesh, India. *Eur J Biol Sci* 2013;5:29-33.
11. Balhara YS, Deb KS. Impact of tobacco on thyroid function. *Thyroid Res Pract* 2014;11:6-16.