

Received: 2013.09.10
Accepted: 2013.09.21
Published: 2014.01.07

ISSN 1507-6164
© Am J Case Rep, 2014; 15: 4-6
DOI: 10.12659/AJCR.889769

Pure laparoscopic management of a giant ovarian cyst in an adolescent

Authors' Contribution:
Study Design A
Data Collection B
Statistical Analysis C
Data Interpretation D
Manuscript Preparation E
Literature Search F
Funds Collection G

ABCDEF 1 **Huseyin Kilincaslan**
ABCDEF 2 **Gokhan Cipe**
BCDG 1 **Ibrahim Aydogdu**
EFG 3 **Fatma Sarac**
FG 4 **Huseyin Toprak**
CDG 5 **Engin Ari**

1 Department of Pediatric Surgery, Faculty of Medicine, Bezmialem Vakif University, Istanbul, Turkey
2 Department of General Surgery, Faculty of Medicine, Bezmialem Vakif University, Istanbul, Turkey
3 Department of Pediatric Surgery, Haseki Research and Education Hospital, Istanbul, Turkey
4 Department of Radiology, Faculty of Medicine, Bezmialem Vakif University, Istanbul, Turkey
5 Department of Pediatrics, Faculty of Medicine, Bezmialem Vakif University, Istanbul, Turkey

Corresponding Author: Huseyin Kilincaslan, e-mail: hkilincaslan@gmail.com

Patient: Female, 16
Final Diagnosis: Ovarian cyst
Symptoms: —
Medication: —
Clinical Procedure: Laparoscopic surgery
Specialty: Surgery

Objective: Rare disease

Background: The use of the laparoscopic approach versus open approach for the management of giant ovarian cysts is controversial. Exclusion of malignant conditions has critical importance in the laparoscopic management of these cases. However, in some cases, the possibility of malignancy and the ovarian origin of a cyst cannot be excluded during the preoperative period.

Case Report: Herein we present the case of a 16-year-old girl with a giant ovarian cyst. The abdominal cavity was laparoscopically explored, and no signs suggestive of malignancy were encountered; the ovarian origin of the cyst was confirmed. A Veress needle was inserted percutaneously, and the cyst was drained and laparoscopically excised. No complications were encountered at follow-up visits 3 and 6 months after surgery.

Conclusions: In addition to the well-known advantages of laparoscopic surgery (e.g., decreased postoperative pain, length of hospital stay, and wound infection), perfect cosmetic results are particularly important for young women. The pure laparoscopic management of giant ovarian cysts is safe and feasible.

Key words: pure laparoscopic • giant • ovarian cyst

Full-text PDF: <http://www.amjcaserep.com/download/index/idArt/889769>



947



—



2



13

Background

Ovarian cysts extending to the umbilicus are termed giant ovarian cysts. Giant ovarian cysts are very rarely observed in the pediatric population. Currently, the popularity of laparoscopic techniques is increasing due to their prominent advantages, such as decreasing postoperative pain, length of hospital stay, and wound infection, and improved cosmetic results. However, in the pediatric population, it can be challenging to manage a giant ovarian cyst laparoscopically because of the possibility of cyst rupture due to a restricted operating field [1–3]. Herein, we present our case of a presumptive giant ovarian cyst that we excised laparoscopically with success following confirmation of its benign nature and ovarian origin during preoperative laparoscopy.

Case Report

A 16-year-old female presented to the pediatric emergency unit with complaints of dysmenorrhea, abdominal pain, constipation, and extreme abdominal distension. Abdominal computed tomography demonstrated a smooth cyst surface with a single septation that was predominantly consistent with a benign mass measuring 20×15 cm (Figure 1). However, an ovarian origin of the cyst could not be definitively determined. Laboratory tests showed a serum leukocyte count of 13.800/mm³ (4000–11000), alanine transaminase of 32 unit/L (0–45), aspartate transaminase of 40 unit/L (0–45), C-reactive protein of 2.4 mg/dl (<0.28), sodium of 133 nmol/l (130–140), and chloride of 97 mmol/L. Serum tumor markers were within the normal range [alpha fetoprotein: 0.5 unit/mL (0.5–5.5), beta human chorionic gonadotropin: 0.1 m Unit/ml (<5)]. The clinical findings and radiological examination suggested the presence of a benign cystic mass. Under general anesthesia, a 10-mm trocar was inserted through an umbilical incision using the Hasson technique (Figure 2). Laparoscopic examination confirmed the benign nature of the cyst, which originated from the

left ovary. A Veress needle was then percutaneously inserted through the midline of the infraumbilical region, and the cyst was carefully punctured under direct laparoscopic vision. Four liters of clear intra-cystic fluid were drained. Two 5-mm ports were then inserted in the right subcostal line and right lower quadrant on the midclavicular line. The cyst wall was excised completely using ovary-preserving surgery with an energy device (LigaSure™ 5 mm). It was placed in a preserving bag and brought out of the abdominal cavity through the 10-mm umbilical port incision. The operation lasted 55 minutes. The postoperative recovery period was uneventful, and the patient was discharged on postoperative Day 1. A histopathological examination revealed a serous cystadenoma. No problems were encountered at the follow-up visits 3 and 6 months after surgery.

Discussion

Giant ovarian cysts are very rarely observed and are often benign. Occasionally, they are included in a differential diagnosis with large cysts from other intra-abdominal organs (e.g., gastrointestinal, urological, or lymphatic) [4]. Although ovarian cysts enlarging to immense dimensions are typically of benign nature, excluding any possibility of malignancy during the preoperative period is of utmost importance [5]. A restricted operating field (particularly in children), the probability of malignancy, and tendency of the cyst to rupture are critical considerations in the laparoscopic approach to these cysts [6,7]. To date, the acknowledged management modalities include: the percutaneous drainage of the cyst under ultrasonographic guidance, decompression of the cyst with the aid of minilaparotomy and its excision, and laparoscopic excision of the cyst after its ultrasound-guided drainage [1,7,8]. Drainage of the cyst under ultrasonographic guidance is associated with some complications, the most predominant being the potential leakage of the cyst contents into the abdominal cavity in cases of malignancy. Minilaparotomy, decompression of the cyst, and its excision are alternatives. Nonetheless, the origin of the cyst can be difficult to determine.

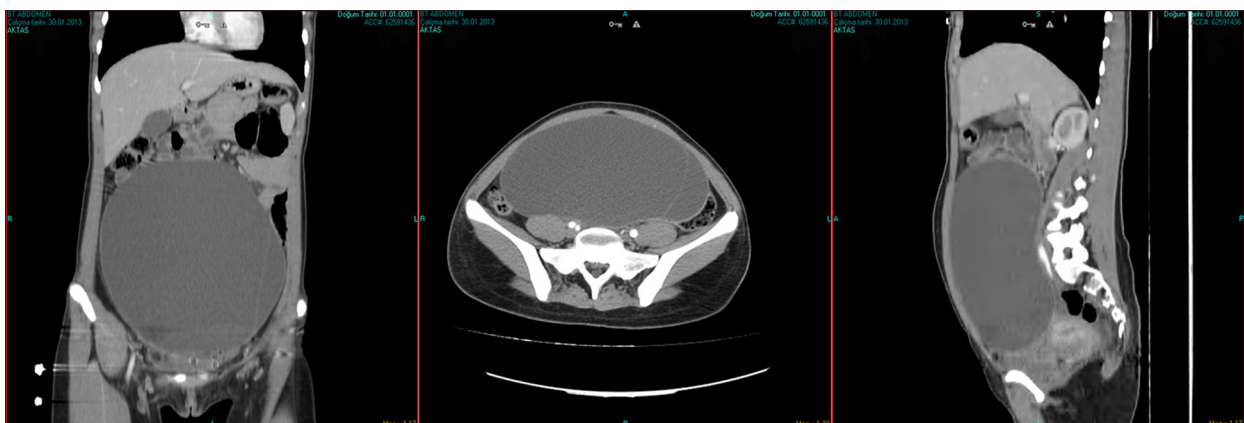


Figure 1. Abdominal computed tomographic images of the giant ovarian cyst.

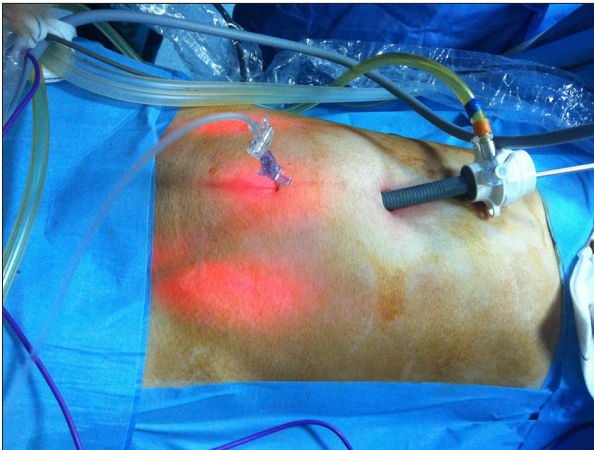


Figure 2. A 10-mm trocar was inserted through the umbilicus using the Hasson technique. The cyst was drained via a Veress needle under full vision.

Diagnostic laparoscopy may be helpful in discriminating between giant ovarian cysts and other intra-abdominal cystic masses when radiological evaluation fails. In this manner, giant cysts originating from organs other than the ovaries are diagnosed, and the surgical process can be better managed. Additionally, the cyst is observed under direct vision and benign and/or malignant findings can be confirmed. In the presence of signs suggesting malignancy (e.g. irregular contours of the cyst and adhesions to adjacent structures), surgeons can convert to open surgery and prevent leakage of cyst contents into the abdominal cavity.

Laparoscopic surgery has been performed during the last 2 decades to treat most abdominal and gynecologic diseases. The advantages of laparoscopic surgery are well studied and include reduced postoperative pain, length of hospital stay, and wound infection, and early return to work [9]. Adhesion

formation following gynecologic operations is an important problem. A laparoscopic approach may reduce postoperative adhesions that may be associated with clinically significant benefits such as improved fertility, reduction in pelvic pain, and improved quality of life [10]. Another advantage of the laparoscopic technique is the perfect cosmetic results, which is important to adolescent girls.

Laparoscopy may be considered the gold standard approach in the management of benign ovarian cysts. However, there is no consensus regarding the size of ovarian cyst that should be considered as a contraindication for laparoscopic surgery. One study results suggest that along with advancing techniques, appropriate patient selection and availability of experts in laparoscopic surgery, it is feasible to remove giant ovarian cyst by laparoscopy [11]. Natural orifice transluminal endoscopic surgery (NOTES) is an innovative procedure in minimally invasive surgery. To date, there are only few cases reported in the literature, performed using pure NOTES. Recently, pure transvaginal and transgastric NOTES were reported in adnexal procedures using laparoscopic rigid instruments [12,13]. However, NOTES procedures are still under investigation for adnexal lesions.

Conclusions

In cases of giant ovarian cysts, pure laparoscopic evaluation and excision is a safe and feasible treatment modality. In addition to their perfect cosmetic results, laparoscopic techniques decrease postoperative adhesion formation, which is associated with minimal infertility risk.

Statement

The authors declare no conflict of interest.

References:

1. Ateş O, Karakaya E, Hakgüder G et al: Laparoscopic excision of a giant ovarian cyst after ultrasound-guided drainage. *J Pediatr Surg*, 2006; 41: E9–11
2. Ma KK, Tsui PZ, Wong WC et al: Laparoscopic management of large ovarian cysts: more than cosmetic considerations. *Hong Kong Med J*, 2004; 10: 139–41
3. Salem AFH: Laparoscopic excision of large ovarian cysts. *J Obstet Gynaecol Res*, 2002; 28: 290–94
4. Vecchio R, Leanza V, Genovese F et al: Conservative laparoscopic treatment of a benign giant ovarian cyst in a young woman. *Laparoendosc Adv Surg Tech A*, 2009; 19: 647–48
5. Ou CS, Liu YH, Zabriskie V, Rowbotham R: Alternate methods for laparoscopic management of adnexal masses greater than 10 cm in diameter. *J Laparoendosc Adv Surg Tech A*, 2001; 11: 125–32
6. Murawski M, Gołębiewski A, Sroka M, Czauderna P: Laparoscopic management of giant ovarian cysts in adolescents. *Wideochir Inne Tech Malo Inwazyjne*, 2012; 7: 111–13
7. Coccia ME, Rizzello F, Bracco GL, Scarselli G: Seven-liter ovarian cyst in an adolescent treated by minimal access surgery: laparoscopy and open cystectomy. *J Pediatr Surg*, 2009; 44: E5–8
8. Cevrioglu AS, Polat C, Fencki V et al: Laparoscopic management following ultrasonographic-guided drainage in a patient with giant paraovarian cyst. *Surg Endosc*, 2004; 18: 346
9. Yuen PM, Yu KM, Yip SK et al: A randomized prospective study of laparoscopy and laparotomy in the management of benign ovarian masses. *Am J Obstet Gynecol*, 1997; 177: 109–14
10. Awonuga AO, Saed GM, Diamond MP: Laparoscopy in gynecologic surgery: adhesion development, prevention, and use of adjunctive therapies. *Clin Obstet Gynecol*, 2009; 52(3): 412–22
11. Alobaid A, Memon A, Alobaid S, Aldakhil L: Laparoscopic management of huge ovarian cysts. *Obstet Gynecol Int*, 2013; 2013: 380854
12. Liu BR, Kong XC, Cui GX et al: Pure transgastric NOTES in an adnexal procedure: the first human case report. *Endoscopy*, 2013; 45(Suppl.2): E290–91
13. Lee CL, Wu KY, Su H et al: Transvaginal natural-orifice transluminal endoscopic surgery (NOTES) in adnexal procedures. *J Minim Invasive Gynecol*, 2012; 19(4): 509–13