



Contents lists available at ScienceDirect

International Journal of Surgery Case Reports

journal homepage: www.casereports.com

Karakousis's abdominoinguinal approach for the treatment of a primary retroperitoneal parasitic leiomyoma with inguinal extension. A case report

Alberto Gomez Portilla^{a,b,*}, Victor Echenagusía^a, Iñaki Cendoya^a, Aintzane Maqueda^a, Eduardo López de Heredia^{a,b}

^a Department of General Surgery and Digestive Diseases, University Hospital of Araba, Vitoria, Spain

^b University of the Basque Country, UPV, Vitoria, Spain

ARTICLE INFO

Article history:

Received 19 October 2017

Received in revised form 2 January 2018

Accepted 4 January 2018

Available online 9 January 2018

Keywords:

Pelvic tumor

Inguinal pelvic tumor

Primary retroperitoneal parasitic leiomyoma (PRPL)

Karakousis's abdominoinguinal approach

ABSTRACT

INTRODUCTION: Primary retroperitoneal parasitic leiomyoma (PRPL) with inguinal extension is a diagnostic-therapeutic challenge due to its uncertain etiopathogenesis and because it has been considered unresectable according to customary surgical techniques in some instances.

The abdominoinguinal incision described by Karakousis in the 1980s allows a safe and radical approach for lower quadrants abdominopelvic tumors.

OBJECTIVES: We present the case of a rare PRPL satisfactorily treated through Karakousis's approach.

PRESENTATION OF CASE: A 35-year-old woman was referred from the Gynecology Service to our Unit. She suffered from a pelvic tumor with left inguinal extension. Initially, it was diagnosed as a retroperitoneal sarcomatous tumor as any digestive and/or gynecological origins of the pelvic tumor were excluded. A radical oncologic excision with permanent neuro-vascular control was undertaken using a left Karakousis's abdominoinguinal approach. The final anatomopathological report was PRPL. The patient was discharged after 8 days. She is disease-free 18 months later.

DISCUSSION: PRPL variant could be related to remnant embryogenic cells of the ducts of Wolf and Müller. Karakousis's approach allowed an en-bloc ilioinguinal removal of the tumor in continuity, with permanent control of the aorto-ileo-femoral axis, the sparing of the neuro-vascular package, and ensured a total abdominal wall restoration.

CONCLUSIONS: PRPL is a rare extrauterine entity probably derived from remnant embryogenic cells. The absence of clinical guidelines recommend an individualized treatment of these patients. Karakousis's abdominoinguinal approach should be present in any surgeon's armamentarium as the resectability-rate of tumors of the lower quadrant of the abdomen increases up to 95%.

© 2018 The Authors. Published by Elsevier Ltd on behalf of IJS Publishing Group Ltd. This is an open access article under the CC BY-NC-ND license (<http://creativecommons.org/licenses/by-nc-nd/4.0/>).

1. Introduction

PRPL is a diagnostic-therapeutic challenge due to its uncertain etiopathogenesis and the difficulties involved in its surgical resolution. It may be considered unresectable according to conventional surgical techniques in some instances.

Low-lying retroperitoneal pelvic tumors with lateral fixation to the side of the lesser pelvis, or protruding behind the inguinal

ligament into the thigh, present challenging difficulties in their exposure and removal. This is because tumors in the distal portion over the external iliac vessels cannot be exposed adequately. Any attempt at removing them by traditional surgical approaches may lead to exsanguinating hemorrhages due to the lack of exposure of the caudal or lateral aspects of the tumors.

The abdominoinguinal incision described by Karakousis in the 1980s [1–3] allows a safe and effective radical approach to tumors in the lower quadrants of the abdomen.

Exposure is provided through the use of a midline infrasuabumbilical incision veering transversely the lower inferior end of the incision toward the site of the tumor, and at the ipsilateral mid-inguinal point it turns again vertically into the femoral triangle. The rectus abdominis is transected off its origin from the crest of the pubis and the inguinal ligament is divided off near the pubic tubercle. Following the division of the inferior epigastric vessels near their origin, the entire lower abdominal wall may be later-

Abbreviations: PRPL, primary retroperitoneal parasitic leiomyoma.

* Corresponding author at: C/Landázuri, 1–6° Izquierda, 01008, Vitoria, Spain.

E-mail addresses: ALBERTO.GOMEZPORTILLA@OSAKIDETZA.EUS

(A. Gomez Portilla), bittor_01@hotmail.com (V. Echenagusía),

IGNACIO.CENDOYAANSOLA@OSAKIDETZA.EUS (I. Cendoya),

AINTZANE.MAQUEDAMERINO@osakidetza.net (A. Maqueda),

eduardmentia@gmail.com (E. López de Heredia).

<https://doi.org/10.1016/j.ijscr.2018.01.003>

2210-2612/© 2018 The Authors. Published by Elsevier Ltd on behalf of IJS Publishing Group Ltd. This is an open access article under the CC BY-NC-ND license (<http://creativecommons.org/licenses/by-nc-nd/4.0/>).

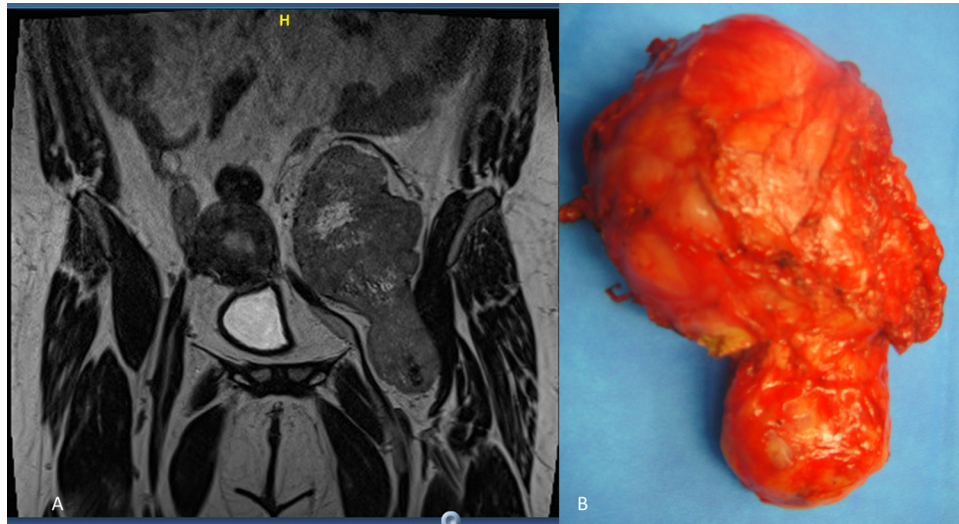


Fig. 1. A) RMN showing a totally independent extraperitoneal giant pelvic tumor mass (16.0 × 9.0 cm) with no connection to any gynecological or digestive organs. The tumor mass extending behind and below the inguinal ligament to the left thigh. B) Surgical correlated specimen.

ally retracted and a full access to the abdomino-pelvic organs is acquired. Mobilization and separation of the bladder and rectosigmoid colon allow for extended exposure to the retroperitoneum. Both the ipsilateral ureter, and the distal external iliac and common femoral vessels are then provided in their entire length. Following the radical removal of the tumor, the inguinal ligament is sutured to Cooper's ligament up to the pubic tubercle.

We present a clinical case of this rare variant of PRPL satisfactorily treated in our Unit through Karakousis's left abdominoinguinal approach. We expose the main hypotheses about its etiopathology. We show the difficulties of its preoperative diagnosis. We discuss the advantages and indications of Karakousis's approach for the treatment of these tumors. Finally, we present some of the principles which may be useful in the removal of this rare PRPL.

This work has been reported in line with the SCARE criteria [4].

2. Presentation of case

A 35-year-old woman, with the diagnosis of a “non-gynecological” retroperitoneal tumor mass, was remitted to our Unit for surgical evaluation from the Department of Obstetrics and Gynecology of our Hospital.

Her pelvic tumor with left inguinal extension had been discovered in the course of the study of metrorrhagia due to the involuntary interruption of her pregnancy. Initially, the digestive and/or gynecological origin of the pelvic tumor was excluded on the RMN, pointing to a retroperitoneal sarcomatous pathology. Her giant pelvic tumor mass (measuring approximately 16.0 × 9.0 cm) was extraperitoneal, totally independent, and with no connection to any gynecological or digestive organs. The mass, oval in shape, was firm and irreducible and extended through the inguinal ligament to the left thigh. At first, the patient underwent a midline infrasuabumbilical incision. After ruling out any intrabdominal metastatic disease, the radical oncologic excision of the pelvic-inguinal mass, was performed using a Karakousis's left abdominoinguinal approach, with an adequate permanent vascular control. This was done prolonging the incision in a transverse manner to the left mid-inguinal point, and then, it continued vertically into the patient's left femoral triangle. The left anterior rectus sheath was completely divided above its origin from the pubic crest, and the inguinal ligament was divided off its insertion to the pubic tubercle. The dissection was continued until the femoral vessels. The entire lower abdominal wall was retracted laterally, and

the rectosigmoid colon medialized. Once the abdominal wall and the viscera were fully retracted using the Thompson^R retractor's blades, the tumor mass was located in the retroperitoneum, utterly independent of uterus and rectum, herniating through the posterior inguinal wall and settling in the subcutaneous region (like a femoral hernia), but no sac was identified. A radical en-bloc oncologic surgical excision with curative intention was undertaken by our team with permanent control of the whole vessels from their aortic bifurcation to the common femoral vessels in continuity (Fig. 1A, B). The definitive anatomopathological report was of PRPL. The patient evolved satisfactorily, and was discharged after 8 days. The patient, who was followed 18 months after surgery, has shown no evidence of recurrence, or any other complications. No incisional hernia has occurred.

3. Discussion

The classification of primary parasitic leiomyomata distinguishes mainly those of uterine origin and those derived from iatrogenic origin, but it does not take into account the rare PRPL variant with its specific prognostic implications [5]. As we alert [6], PRPL need to be included in the differential diagnosis of any women with a pelvic tumor mass.

The origin of PRPL has been postulated to derive from a defect in the migration of the remnant embryogenic cells of the ducts of Wolf and Müller [7].

The main difficulty to treat these huge retroperitoneal pelvic masses is that the best approach is still not well defined. Generally, most authors use a midline abdominal incision. This incision does not allow a good exposure of the caudal portion of the external iliac vessels, as the presence of tumor hinders further visibility. A multidisciplinary team should be involved in order to ensure a radical curative surgery.

Our case shows that, at times, the unusual Karakousis's abdominoinguinal approach [8,9] is needed, especially in pelvic retroperitoneal masses with prolonged extension through the inguinal ring into the thigh. This access guarantees safe resections along the iliac vessels. It provides a continuous access to the whole abdominopelvic cavity and the retroperitoneum, and both iliac and femoral vessels, together in one field, as Karakousis asserts [8,9]. In our patient tumor resection was achieved by a Karakousis's left abdominoinguinal approach. The inguinal transverse extension of the incision and its vertical caudal continuity up to the femoral tri-

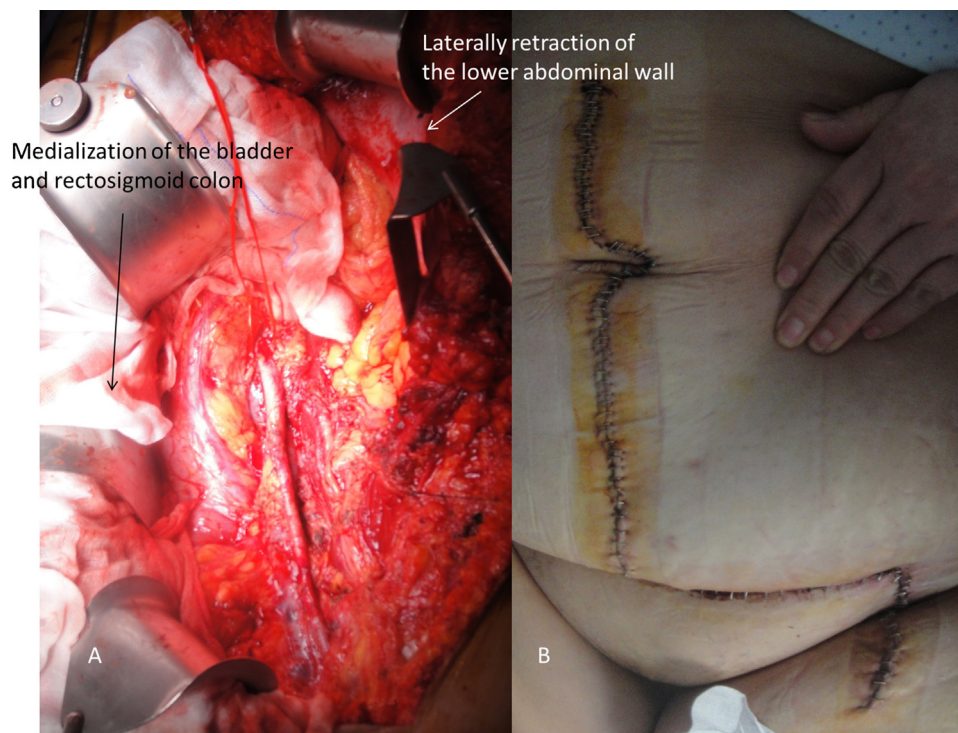


Fig. 2. A) Incontinuity “hands-free” exposure of the abdominal pelvic cavity and retroperitoneum following the oncologic en-bloc surgical removal of the tumor. Laterally retraction of the lower abdominal wall (white arrow), and medialization and separation of the bladder and rectosigmoid colon (black arrow) provided by Thompson[®] retractoris blades. Continuity exposure of the common iliac, external iliac and femoral vessels are shown in their entire length in just one surgical field. B) Final wound incision following a Karakousis's left abdominoinguinal approach.

angle guaranteed the selective vascular control of the aortocavous axis and the ileofemoral vessels. Although the dissection seems to be extensive, it was blood-less as preservation of the vascular vessels was achieved. A partial resection of the psoas muscle was required. The closure of the abdominal wall with reconstruction of the left inguinal ligament allowed a total anatomical restoration. (Fig. 2A, B). The subsequent clinical and radiological control demonstrated the absence of tumor recurrence 18 months later.

4. Conclusions

PRPL is a rare extrauterine entity. The retroperitoneal primary retroperitoneal variant of leiomyoma parasites in the absence of uterine or iatrogenic origin appears to stem from the migration of embryogenic cells. The absence of clinical guidelines and prognostic criteria recommend an individualization in the treatment of these patients.

Any attempt at removing them by traditional surgical techniques appears hazardous due to lack of exposure. Karakousis's procedure allows the correct ilioinguinal dissection and en-bloc removal of the PRPL in continuity. It ensures the safe and complete vascular control of the aorto-ileo-femoral axis, and the sparing preservation of the neuro-vascular package, with no major functional deficits.

Familiarity with the anatomy and technique involved in these surgeries is extremely important as this approach is the only limb salvage procedure that guarantees the radical en-bloc resection of retroperitoneal tumors with pelvic and inguinal extension.

Karakousis's abdominoinguinal incision should be part of the armamentarium of every surgeon willing to accept the responsibility for pelvic advanced malignancies as the rate of resectability of the lower quadrant tumors of the abdomen increases up to 95% in his experience [10].

Conflicts of interest

We wish to confirm that there are no known conflicts of interest associated with this publication.

Funding

There has been no significant financial support for this work that could have influenced its outcome.

Ethical approval

The present study is exempt from ethical approval in our Institution.

Consent

A fully informed written consent has been obtained and signed consent to publish this case report from the patient.

Author contribution

We confirm that the manuscript has been read and approved by all named authors. We further confirm that the order of authors listed in the manuscript has been approved by all of us.

Guarantor

Alberto Gómez Portilla.

References

- [1] C.P. Karakousis, Exposure and reconstruction in the lower portions of the retroperitoneum and abdominal wall, *Arch. Surg.* 117 (1982) 840–844.

- [2] C.P. Karakousis, The abdominoinguinal incision in limb salvage resection of pelvic tumors, *Cancer* 54 (1984) 2543–2548.
- [3] C.P. Karakousis, Technical aspects of resection of pelvic tumors, *J. Surg. Oncol.* 31 (1986) 155–159.
- [4] R.A. Agha, A.J. Fowler, A. Saetta, I. Barai, S. Rajmohan, D.P. Orgil, The SCARE Group, The SCARE statement: consensus-based surgical case report guidelines, *Int. J. Surg.* 34 (2016) 180–186.
- [5] I. Lete, J. González, L. Ugarte, N. Barbadillo, O. Lapuente, J. Álvarez-Sala, Parasitic leiomyomas: a systematic review, *Eur. J. Obstet. Gynecol. Reprod. Biol.* 203 (2016) 250–259.
- [6] A. Gómez Portilla, V. Echenagusia, I. Cendoya, A. Maqueda, Parasitic leiomyomas: a systematic review, *Eur. J. Obstet. Gynecol. Reprod. Biol.* 207 (2016) 233–234.
- [7] N. Fasih, A.K.P. Shanbhogue, D.B. Macdonald, M.A. Frase4r-Hill, D. Papadatos, A.Z. Kielar, et al., Leiomyomas beyond the uterus: unusual locations, rare manifestations, *Radiographics* 28 (2008) 1931–1948.
- [8] C.P. Karakousis, Abdominoinguinal incision in resection of pelvic tumors with lateral fixation, *Am. J. Surg.* 164 (1992) 366–371.
- [9] C.P. Karakousis, The abdominoinguinal incision: the equivalent of thoracoabdominal incision for the lower quadrants of the abdomen, *J. Surg. Oncol.* 69 (1998) 249–257.
- [10] C.P. Karakousis, Refinements of surgical technique in soft tissue sarcomas, *J. Surg. Oncol.* 101 (2010) 730–738.

Open Access

This article is published Open Access at [sciencedirect.com](https://www.sciencedirect.com). It is distributed under the [IJSCR Supplemental terms and conditions](#), which permits unrestricted non commercial use, distribution, and reproduction in any medium, provided the original authors and source are credited.