



OPERATIVE TECHNIQUE

Bone Hook Reduction Technique Combined with Lateral Parapatellar Arthrotomy for Periprosthetic Distal Femoral Fractures Following Total Knee Arthroplasty: A Technical Note

Oog-Jin Shon, MD , Gi Beom Kim, MD , Je Won On, MD

Department of Orthopaedic Surgery, Yeungnam University College of Medicine, Yeungnam University Medical Center, Daegu, Republic of Korea

Objective: To report a bone hook reduction technique combined with lateral parapatellar arthrotomy for periprosthetic distal femoral fractures following total knee arthroplasty (TKA).

Methods: From April 2012 to June 2018, a total of 31 knees who underwent this technique for the treatment of periprosthetic distal femoral fractures following TKA were retrospectively reviewed. Through a lateral parapatellar arthrotomy, the vastus lateralis fascia was dissected from the muscle belly to allow anteromedial mobilization of the muscles. With direct visualization of the posteriorly angulated distal fragment, a bone hook was placed on the anterior flange of the femoral component. The hook was then elevated to correct the posteriorly angulated and shortened distal fragment. The coronal and sagittal alignments of the distal segment with the femoral shaft were confirmed using fluoroscopic images, and internal fixation was performed using an anatomically pre-contoured lateral locked plate. Once the overall length and sagittal plane alignment were restored, the plate was inserted via the previous articular approach. The plate was centered on the femur using anteroposterior and lateral fluoroscopy and then fixed.

Results: A total of 28 patients underwent internal fixation using the bone hook reduction technique combined with lateral parapatellar arthrotomy for the treatment of periprosthetic distal femoral fractures following TKA. The average age at operation was 70.9 years (range, 62–83 years), and the average follow-up period was 17.5 months (range, 12–48.5 months). Fractures were classified as Su type I (13/28 [46.4%]), type II (11/28 [39.3%]), and type III (4/28 [14.3%]). Bone union was confirmed radiographically in all patients.

Conclusion: The bone hook reduction technique is a simple and effective method to reduce the distal fragment in periprosthetic distal femoral fractures following TKA.

Key words: Bone hook; Lateral parapatellar arthrotomy; Periprosthetic distal femoral fracture; Reduction technique; Total knee arthroplasty

Introduction

Periprosthetic fractures following total knee arthroplasty (TKA) mainly occur in the supracondylar area of the distal femur and have an incidence of approximately 0.3%–2.5%^{1–3}. Treatment of periprosthetic distal femoral fractures

following TKA is technically demanding because of poor bone stock, pre-existing components, and bone cement⁴. These may make fracture reduction and fixation difficult and even lead to nonunion or malunion⁵. Particularly, in distally extended femoral fractures, since the gastrocnemius muscle

Address for correspondence Gi Beom Kim, Department of Orthopaedic Surgery, Yeungnam University College of Medicine, Yeungnam University Medical Center, Hyeonchungno 170, Nam-gu, Daegu, 42415, Republic of Korea. Email: donggamgb@hanmail.net

Received 21 November 2021; accepted 18 May 2022



can cause extension of the distal fragment and the hamstrings and quadriceps can cause shortening, maintenance of the reduction can be a problem^{1,6,7}.

To our knowledge, several modalities have been introduced to aid in the reduction of the distal fragment⁶. Intraoperative traction or distal femoral distractor, sterile towel bump or bolster, standard reduction forceps, and Schanz pin joysticks can be used to restore the rotation and sagittal alignment of the distal fragment^{6,8}. However, morbidities associated with previously reported techniques remain a major concern, particularly in osteoporotic geriatric patients. Accordingly, a simple reduction tool that does not require invasive fixation to osteoporotic bone, such as a bone hook, is needed.

Meanwhile, the lateral parapatellar arthrotomy is the longitudinal division of the quadriceps tendon and extending distal along the lateral margin of the patella⁹. It facilitates adequate visualization of articular joint and allows the

surgeon to ensure proper plate position on the lateral side of femur to the proximal side^{10,11}.

Therefore, the objective of this technical note is to: (i) describe a bone hook reduction technique combined with lateral parapatellar arthrotomy for periprosthetic distal femoral fractures following TKA; (ii) evaluate the outcomes of patients who had the technique applied. In this report, this technique was introduced with case illustrations.

Surgical Procedure

Patient Positioning

A patient was placed in a supine position on a radiolucent operating table with neutral rotation. To neutralize the pulling force of the gastrocnemius muscle, a sterile towel bump was placed posterior to the dia-metaphyseal area of the distal femur. Manual traction was applied to prevent shortening (Figure 1(A),(B)).

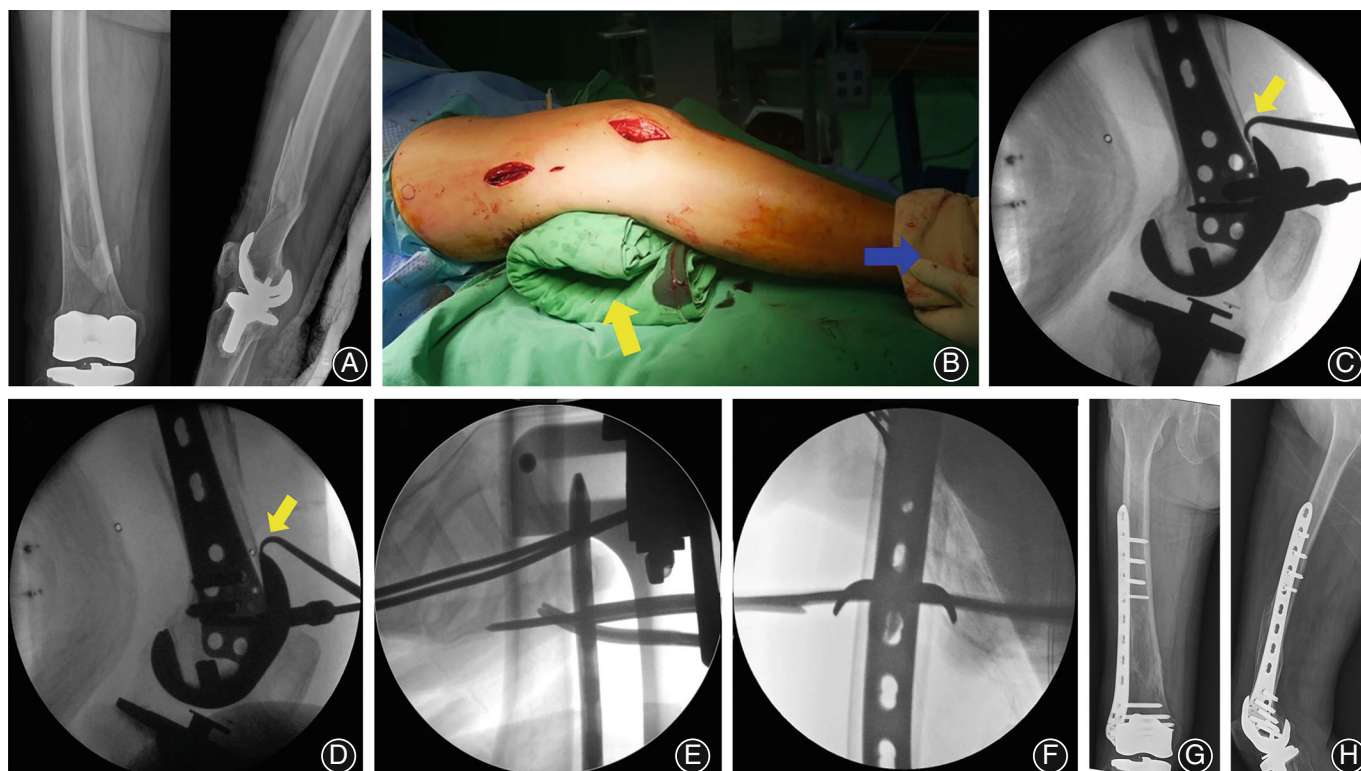


Fig. 1 Case demonstration of a 70-year-old woman with periprosthetic distal femoral fracture following total knee arthroplasty. (A) Distally extended periprosthetic distal fracture of the right femur following total knee arthroplasty (TKA) is identified on anteroposterior and lateral radiographs in a 70-year-old woman. Particularly, the posteriorly angulated distal fragment can be seen in the lateral radiograph. (B) Lateral parapatellar arthrotomy with retrograde minimally invasive locked plate osteosynthesis to the right distal femur is performed. The patient is placed in the supine position with a sterile bump under the ipsilateral distal thigh with neutral rotation. Manual traction is usually applied to prevent shortening. (C, D) A bone hook (red arrow) is placed on the anterior flange of the femoral component. The hook is then elevated to correct the posterior angulation and shortening of the distal fragment. (E, F) Once the overall length and sagittal plane alignment is restored, the plate is inserted via the previous articular approach. The plate is centered on the femur using Kelly forceps under anteroposterior and lateral fluoroscopy. (G, H) Anteroposterior and lateral radiographs at 12 months postoperatively show that the fracture has healed without angulation, and the reduction is well-maintained

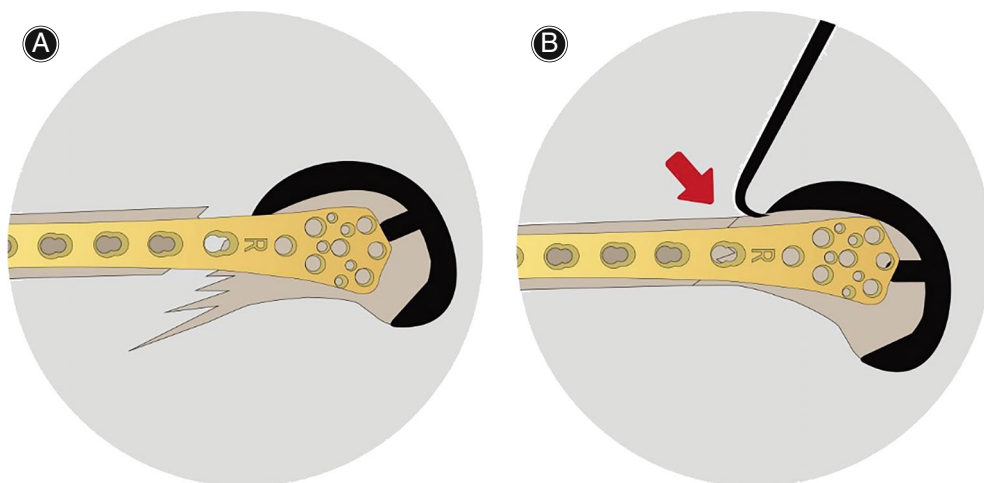


Fig. 2 Technique diagrams. (A) The posteriorly angulated distal femoral fragment can be seen in the lateral view. (B) After a bone hook is applied to the anterior flange of the femoral component, the posterior angulation and shortening of the distal fragment are corrected

Surgical Approach

An approximately 8–10-cm skin incision began proximally at the superolateral corner of the patella and extended distally to the lateral edge of the patellar tendon¹⁰. The skin incision was placed laterally or at midline depending on the discretion of the surgeon¹². Soft tissue dissection was performed to develop the full thickness skin flaps visualizing the underlying lateral patellar retinaculum¹⁰. The lateral patellar retinaculum was exposed through sharp soft tissue dissection, and a retinacular incision was made to gain access to the knee joint¹⁰. The joint capsule was incised with a clean incision, and hemarthrosis in the joint was aspirated. For identification of the anterior flange of the femoral component, a soft tissue retractor such as Army-Navy retractor was placed across the suprapatellar pouch. Finally, a bone hook could be applied to the anterior flange of the femoral component.

Bone Hook Reduction Technique

First, the stability of the femoral component was confirmed intraoperatively before applying a bone hook. When the instability of the component was confirmed, revision TKA or distal femoral replacement was considered. Thereafter, a bone hook was placed on the anterior flange of the femoral component. The hook was elevated to correct posterior angulation and shortening of the distal fragment. In particular, for relatively simple fractures, the bone hook could be applied to the anterior femoral flange with minimal lateral parapatellar arthrotomy (Figure 1(C),(D), and Video S1). The reduction was assessed using anteroposterior and lateral fluoroscopy. Once the overall length and sagittal plane alignment were restored, an anatomical locked plate (LCP[®] distal femur plate; Synthes, Solothurn, Switzerland) was inserted via the previous articular approach. A proximal lateral incision for proximal locked screws was made to facilitate plate application. Centering of the plate on the femur was confirmed using Kelly forceps under anteroposterior and lateral

fluoroscopy (Figure 1(E),(F)), and then the plate was fixed. Diagrams of the technique are shown in Figure 2.

Postoperative Rehabilitation

Active and passive motion was initiated on the first postoperative day, and toe-touch weight-bearing ambulation was started at 3 weeks postoperatively¹³. Patients were permitted to start full weight bearing at 6 weeks postoperatively.

Result

Between April 2012 and June 2018, a total of 31 knees who underwent locked plate fixation using the bone hook reduction technique combined with lateral parapatellar arthrotomy for the treatment of periprosthetic distal femoral fractures following TKA were retrospectively reviewed. All surgeries were conducted by a single senior surgeon, and the minimum follow-up period was 12 months. The average age at operation was 70.9 years (range, 62–83 years), and the average follow-up period was 17.5 months (range, 12–60.5 months). Fractures were classified as Su type I (13/28 [46.4%]), type II (11/28 [39.3%]), and type III (4/28 [14.3%]). The average union time was 6.8 months (range, 3.0–8.0 months). Bone union without any evidence of malunion or implant failure was observed in all patients. The institutional ethics review board approved the study protocol (YUMC 2020-03-080-001).

Discussion

Our novel technique using bone hook combined with lateral parapatellar arthrotomy for periprosthetic distal femoral fractures following total knee arthroplasty has been used successfully and safely for the past 6 years on over 30 patients at our hospital. During the follow-up period, there were no other complications, especially those related to union problems. The above outcomes indicate that preliminary clinical application outcomes for this technology are reliable. First of all, accurate placement of the bone hook tip

to the anterior flange is the most essential step. If the hook is not properly engaged, it may be difficult to obtain a satisfactory reduction, and additional fractures may occur in the bone.

Limitations of Conventional Reduction Tools

Several reduction techniques have been introduced to aid in the reduction of the posteriorly angulated distal femoral fragment. In particular, orthopaedic surgical instruments, including distal femoral distractor, standard reduction forceps, and Schanz pin joysticks, can be utilized to correct the coronal and sagittal alignment of the distal femoral fragment^{6,8}. However, these reduction methods can cause further damage to the bone stock around the anterior flange of the femoral component, which may be a major concern, especially in patients with osteoporosis. The joystick technique not only requires additional fixation, but also risks damaging the posterior neurovascular structures during fixation. This can lead to prolonged surgical time. Moreover, this technique is difficult to perform in patients with cortical comminution or osteoporotic nature. Meanwhile, special instruments, such as coaxial reduction clamps, to minimize soft tissue damage are not readily available¹⁴. Therefore, the reduction technique using a bone hook is easily available, relatively simple, and can be an effective method to minimize iatrogenic damage to the surrounding bone.

Advantages of Lateral Parapatellar Approach

Various surgical approaches can be considered depending on the fracture configuration, experience of the surgeon, and characteristics of the implant itself. Among them, lateral parapatellar arthrotomy is the most popular open approach, which involves the longitudinal division of the quadriceps tendon and distal extension along the lateral margin of the patella¹¹. It facilitates sufficient articular exposure and allows surgeons to position the plate properly on the lateral side of the femur proximally¹⁰. Through this arthrotomy, the stability of the femoral component can be confirmed, and the posteriorly angulated and shortened distal fragment can be corrected easily by placing a bone hook on the anterior flange of the femoral component. Particularly, in a simple fracture, because the extent of arthrotomy can be minimized, this method has an advantage that a hook can be applied without exposing the joint extensively.

Favorable Outcomes of Technique

In the present study, a simple bone hook reduction technique combined with lateral parapatellar arthrotomy for periprosthetic distal femoral fractures was introduced. This technique showed favorable radiographic and clinical outcomes in a total of 31 knees. In particular, there were no union problems such as nonunion or malunion. By applying a bone hook, which is a relatively common orthopaedic instrument, it was possible to easily reduce the distal fragment with minimal damage to the bone stock around the

anterior flange. For the present technique, the stability of the femoral component was the most important prerequisite. As already known, in case of mal-positioned or loose components, revision TKA or distal femoral replacement should be considered¹⁵⁻¹⁹.

Technique Limitations

Although this technique is a simple and useful method for the reduction of the distal femoral fragments, it has some limitations depending on the type of fracture. As with other reduction tools, it may not be easy to use for fractures with severe metaphyseal comminution, and it is difficult to expect effective reduction of segmental fractures. Therefore, this technique would be suitable for relatively simple fracture patterns, as demonstrated in this study.

Conclusions

Bone hook reduction technique combined with lateral parapatellar arthrotomy is a simple and effective method to achieve the reduction of the distal fragment in periprosthetic distal femoral fractures following TKA. Although the outcomes of the clinical experiment are promising, their efficacy still needs to be evaluated by including more cases, which can be verified in future clinical practice.

Authors' Contributions

The following authors have made substantial contributions to the following: (1) the conception and design of the study were contributed to by Oog-Jin Shon, provision of study materials or patients was contributed to by Gi Beom Kim, acquisition of data was contributed to by Gi Beom Kim, analysis and interpretation of data were contributed to by Gi Beom Kim and Oog-Jin Shon. (2) Drafting the article was contributed to by Gi Beom Kim, (3) final approval of the version to be submitted was contributed to by Gi Beom Kim and Oog-Jin Shon. All authors read and approved the final manuscript.

Declaration of Interest

The authors declare that they have no competing interests.

Funding

This research was supported by the 2021 Yeungnam University Research Grant.

Acknowledgements

None.

Supporting Information

Additional Supporting Information may be found in the online version of this article on the publisher's web-site:

Video S1

References

1. Dennis DA. Periprosthetic fractures following total knee arthroplasty. *J Bone Joint Surg Am.* 2001;83:120–30.
2. Rorabeck CH, Taylor JW. Periprosthetic fractures of the femur complicating total knee arthroplasty. *Orthop Clin North Am.* 1999;30:265–77.
3. Mak Y-F, Lee Q-J, Chang W-YE, Wong Y-C. Intraoperative femoral condyle fracture in primary total knee arthroplasty—a case-control study in Asian population. *Knee Surg Relat Res.* 2020;32:1–9.
4. Chen F, Mont MA, Bachner RS. Management of ipsilateral supracondylar femur fractures following total knee arthroplasty. *J Arthroplasty.* 1994;9:521–6.
5. Engh G. Periprosthetic fractures adjacent to total knee implants: treatment and clinical results. *Instr Course Lect.* 1998;47:437–48.
6. Kregor PJ, Stannard JA, Zlowodzki M, Cole PA. Treatment of distal femur fractures using the less invasive stabilization system: surgical experience and early clinical results in 103 fractures. *J Orthop Trauma.* 2004;18:509–20.
7. Althausen PL, Lee MA, Finkemeier CG, Meehan JP, Rodrigo JJ. Operative stabilization of supracondylar femur fractures above total knee arthroplasty: a comparison of four treatment methods. *J Arthroplasty.* 2003;18:834–9.
8. Gangavalli AK, Nwachuku CO. Management of distal femur fractures in adults. *Orthop Clin North Am.* 2016;47:85–96.
9. Pires RE, Kfuri M. Setting yourself up for success: locked plating in periprosthetic fractures about total knee arthroplasty. *J Orthop Trauma.* 2019;33:S25–8.
10. Beltran MJ, Blair JA, Huh J, Kirby JM, Hsu JR, Consortium STR. Articular exposure with the swashbuckler versus a “Mini-swashbuckler” approach. *Injury.* 2013;44:189–93.
11. Beltran MJ, Gary JL, Collinge CA. Management of distal femur fractures with modern plates and nails: state of the art. *J Orthop Trauma.* 2015;29:165–72.
12. Crist BD, Lee MA. *Distal Femur Fractures: Open Reduction and Internal Fixation, Master Techniques in Orthopaedic Surgery: Fractures.* 3rd ed. Philadelphia, PA: Lippincott Williams and Wilkins; 2012. p. 425–48.
13. Quinn J, Jones P, Randle R. A reliable surgical approach to revision total knee arthroplasty. *Clin Orthop Surg.* 2020;14:215–9.
14. Pape H-C, Tarkin IS. Intraoperative reduction techniques for difficult femoral fractures. *J Orthop Trauma.* 2009;23:S6–S11.
15. Bettin CC, Weinlein JC, Toy PC, Heck RK. Distal femoral replacement for acute distal femoral fractures in elderly patients. *J Orthop Trauma.* 2016;30:503–9.
16. Kim K-I, Egol KA, Hozack WJ, Parvizi J. Periprosthetic fractures after total knee arthroplasties. *Clin Orthop Relat Res.* 2006;446:167–75.
17. Rorabeck CH, Taylor JW. Classification of periprosthetic fractures complicating total knee arthroplasty. *Orthop Clin North Am.* 1999;30:209–14.
18. Quinn J, Jones P, Randle R. Clinical outcomes following revision total knee arthroplasty: minimum 2-Year follow-up. *Clin Orthop Surg.* 2020;14:69–75.
19. Park S-H, Jung K-H, Chang S-W, Jang S-M, Park K-B. Trends in knee surgery research in the official journal of the Korean knee society during the period 1999–2018: a bibliometric review. *Knee Surg Relat Res.* 2020;32:1–7.