

[Case report]



## Plastic bronchitis associated with influenza B virus infection : A case report

Jun Shirota, Masatoki Sato, Yasushi Saito, Yuichiro Asano, Yoichi Tomita, Masahiro Watanabe,  
Kazuhide Suyama, Yukihiko Kawasaki and Mitsuaki Hosoya

*Department of Pediatrics, Fukushima Medical University*

(Received May 26, 2021, accepted February 9, 2022)

### Abstract

Plastic bronchitis (PB) is a severe acute respiratory disease that develops as a result of the formation of branching mucus plugs in the bronchial tree. PB is known as a complication of influenza A virus infection, but some cases have been associated with influenza B virus infections. This patient was a 3-year-old boy with no history of allergic disease who developed PB requiring ventilator management after influenza B virus infection. He was hospitalized and managed with ventilator support because of acute respiratory failure. Influenza B virus infection was diagnosed via rapid antigen test and real-time reverse-transcription polymerase chain reaction (RT-PCR). A bronchoscopy performed after a chest X-ray and computed tomography confirmed the presence of extensive atelectasis in the right lung field and mucus plugs in the right bronchus. The patient's respiratory condition improved rapidly after removal of the plugs. Quantitative real-time RT-PCR performed with nasal and aspirated sputum samples obtained at hospitalization revealed a higher viral RNA load in the upper rather than in the lower respiratory tract. Viral replication in the lower respiratory was not found to be a major contributor toward mucus plug formation. The finding of increased serum IgE in the absence of a history of allergic disease suggests that an allergic reaction contributed to the formation of mucus plugs.

**Key words :** influenza B virus, children, plastic bronchitis

### Introduction

Plastic bronchitis (PB) is a severe, possibly life-threatening acute respiratory condition caused by formation of branching mucus plugs in the bronchi and sudden respiratory distress resulting from airway obstruction<sup>1)</sup>. Therefore, prompt diagnosis of PB and removal of the mucus plugs is required. PB occurs secondary to respiratory infections, especially influenza A/H1N1 pdm09 virus infection, but few cases have been reported following influenza B virus infection<sup>2-6)</sup>. This patient was a 3-year-old boy with no history of allergic disease who developed PB requiring ventilator support after influenza B virus infection.

### Case report

A 3-year-old boy with no underlying disease, including allergic illnesses such as bronchial asthma, suddenly experienced dyspnea after 3 days of cough and mild fever. He was transferred to our hospital for further treatment after visiting a nearby pediatric clinic. He presented with a body temperature of 37.9°C, pulse of 157 beats/min, respiratory rate of 50-70 breaths/min, blood pressure of 141/89 mmHg, and an SpO<sub>2</sub> of 80%-90% on room air. He was alert. The breath sounds in the right lung field were very weak, and signs of respiratory distress (i.e., upper sternal, epigastric, intercostal retraction, nasal alar breathing, and tachypnea) were evident. The patient's arterial blood gas analysis (Table 1)

Corresponding author : Jun Shirota, MD E-mail : [jshirota@fmu.ac.jp](mailto:jshirota@fmu.ac.jp)

©2022 The Fukushima Society of Medical Science. This article is licensed under a Creative Commons [Attribution-NonCommercial-ShareAlike 4.0 International] license.  
<https://creativecommons.org/licenses/by-nc-sa/4.0/>

was consistent with respiratory failure. The results of the peripheral blood counts, biochemical tests, and bacterial cultures are shown in Table 1. Influenza virus B was detected using an influenza virus rapid antigen-detection test and real-time reverse-transcription polymerase chain reaction (RT-PCR)<sup>7</sup>. The rapid antigen test for influenza A, RS virus, human metapneumovirus, and *Mycoplasma pneumoniae* were negative. He had received influenza vaccination twice in this season. A chest X-ray showed loss of permeability in the right lung field with a shift to the right side of the trachea (Figure 1a). Chest computed tomography (CT) images showed extensive atelectasis in the right middle and

lower lobes (Figure 2a, b). The patient was admitted to the pediatric intensive care unit, intubated, placed on ventilator support, and given intravenous peramivir (10 mg/kg/day), ceftriaxone (120 mg/kg/day), methylprednisolone, magnesium sulfate, and isoproterenol (Figure 3). PB was suspected because of the extensive atelectasis on chest CT images, and because bronchoscopy revealed a large amount of viscous plaque in the right middle and lower lobe bronchi. The patient's respiratory status improved significantly following plaque removal via intratracheal aspiration and pulmonary physiotherapy (Figure 4). A chest X-ray after removal of the mucus plugs also showed improvement of the

Table 1. Results of blood tests and cultures at hospitalization

Blood count			Blood chemistry			Arterial blood gas analysis <sup>a</sup>			Cultures	
WBC	12,100	/ $\mu$ L	AST	30	IU/L	pH	7.176		Sputum	Negative
<i>Neu</i>	87	%	ALT	13	IU/L	pCO <sub>2</sub>	74.4	Torr	Blood	Negative
<i>Lym</i>	7	%	LDH	201	IU/L	pO <sub>2</sub>	103	Torr		
<i>Mo</i>	4	%	CK	500	IU/L	HCO <sub>3</sub> <sup>-</sup>	27.5	mmol/L		
<i>Eo</i>	1	%	Na	136	mEq/L	BE	-1.2	mmol/L		
<i>Ba</i>	0	%	K	4.7	mEq/L					
RBC	434 $\times$ 10 <sup>4</sup>	/ $\mu$ L	Cl	102	mEq/L					
Hb	11.7	g/dL	BUN	11	mg/dL					
Ht	34.6	%	Crea	0.21	mg/dL					
Plt	31.6 $\times$ 10 <sup>4</sup>	/ $\mu$ L	CRP	2.21	mg/dL					
			PCT	0.09	ng/mL					
			IgG	488	mg/dL					

<sup>a</sup> Arterial blood gas was analyzed under a fraction of inspired oxygen of 0.6.

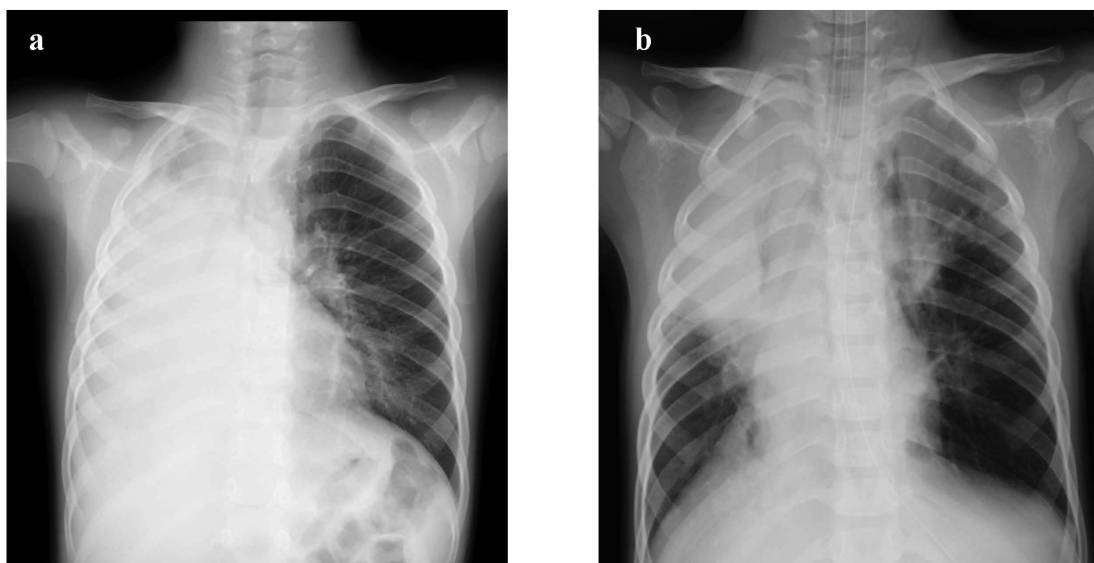


Fig. 1. Chest X-ray images.

Chest X-ray images at hospitalization (a) showed a decrease in permeability of the entire right lung field that improved after the removal of mucus plugs (b).

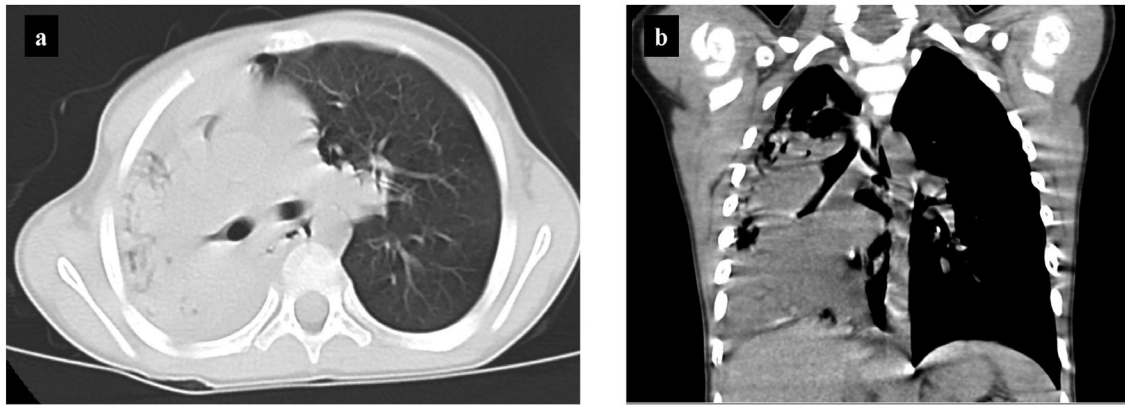


Fig. 2. Chest CT images at hospitalization. Chest CT (a) an axial image and (b) a coronal section image at hospitalization showed atelectasis of the right middle and lower lung lobes. CT, computed tomography.

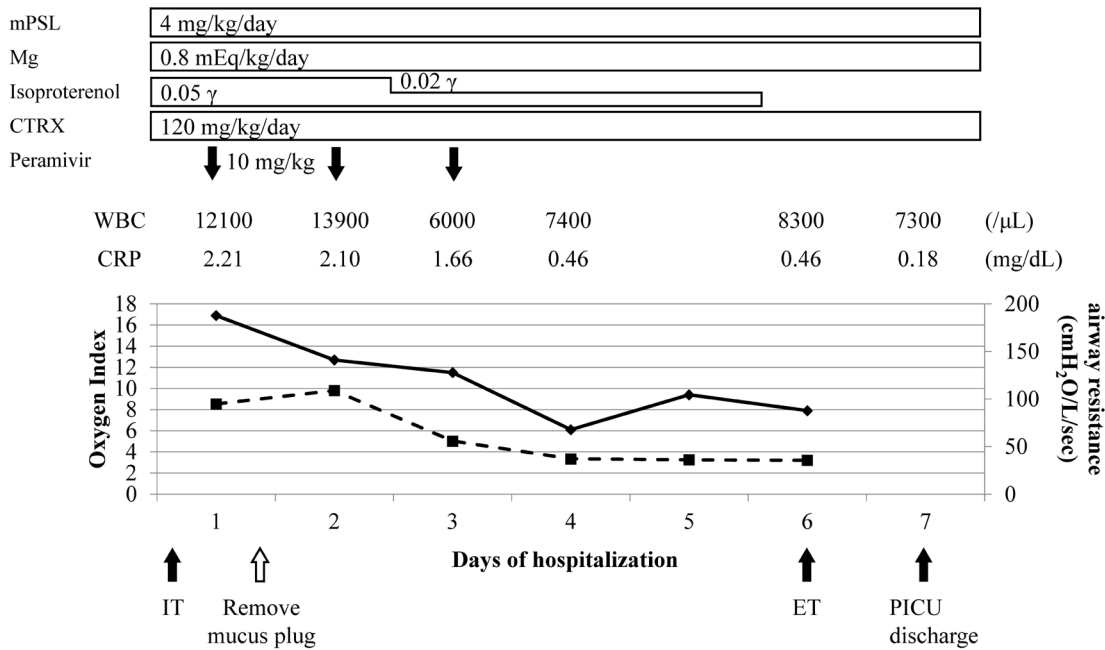


Fig. 3. Clinical course from days 1 to 7 of hospitalization in the pediatric intensive care unit. After the removal of mucus plugs by bronchoscopy and initiation of general management, the patient’s respiratory status, oxygen index (solid lines), and airway resistance (broken lines) rapidly improved. He was extubated on day 6 and transferred to the general ward on day 7. mPSL, methylprednisolone ; Mg, magnesium sulfate ; CTRX, ceftriaxone ; WBC, white blood cell ; CRP, C-reactive protein ; IT, intubation ; ET, extubation ; PICU, pediatric intensive care unit.

findings of the right middle and lower lung fields (Figure 1b). The ventilator was removed on day 6 of hospitalization following improvement in the oxygen index and airway resistance (Figure 3). The patient was discharged on the 11<sup>th</sup> day after admission. The viral RNA load upon hospitalization was  $2.45 \times 10^6$  copies/mL in the nasal aspiration sample and  $1.07 \times 10^4$  copies/mL in the aspirated sputum

sample. Serum IgE was 14,854 IU/mL at discharge (Table 2) and 3,955 IU/mL 10 months later.

### Discussion

The patient was a 3-year-old boy with no underlying illness who developed PB. PB is known to occur secondary to respiratory infections and is more




Fig. 4. Removed mucus plugs. The removed mucus plug had a dendritic branched structure (arrows and circles) that resembled the shape of a bronchus.

Table 2. Serum IgE level at discharge

Total IgE (UA/mL)	14,854
Specific IgE (UA/mL)	
Japanese cedar	18.60
Ragweed	1.37
Japanese white birch	0.56
Orchard grass	0.52
Japanese mugwort	0.40
Japanese alder	0.40
Mold mite	1.35
Dog	0.41
Moth	0.38

likely in children with allergic predispositions (i.e., bronchial asthma) or congenital heart disease<sup>8,9</sup>. A previous report found that among 42 patients with PB less than 18 years old, 31% had a history of allergic illnesses including bronchial asthma, 40% had a history of heart disease, and the remaining 29% had no underlying disease<sup>1</sup>. Bronchial mucus plugs are classified as either type 1 or type 2 depending on the cause and pathology<sup>10</sup>. Type 1 mucus plugs are in-

flammatory, composed mainly of fibrin and inflammatory cells, such as neutrophils and eosinophils. It often occurs in patients with bronchial diseases such as asthma. Type 2 mucus plugs are acellular, composed mainly of mucin, and occur in patients after surgery for congenital heart disease. The mucus plugs removed from our patient were not for pathological evaluation, but his medical history without heart disease and the occurrence of PB after influenza B virus infection suggested that the mucus plugs were type 1.

Type 1 mucus plugs have often been found in PB cases following influenza A/H1N1 pdm09 virus infection. Because the influenza A/H1N1 pdm09 virus has a high affinity for both human- and avian-type receptors that are highly expressed in both the upper and lower respiratory tracts, the virus can directly cause inflammation in both these areas<sup>11,12</sup>. We previously reported a case of severe acute respiratory distress syndrome caused by the influenza A/H1N1 pdm09 virus, which had a greater viral RNA load in the lower than in the upper respiratory tract<sup>13</sup>. Both seasonal influenza A/H1N1 and A/H3N2 virus infections have also been reported to increase IgE production and airway responsiveness, as well as enhance antigen-induced airway inflammation and hyperresponsiveness<sup>14,15</sup>. Thus, the influenza A/H1N1 pdm09 virus may both directly and indirectly contribute to the formation of type 1 mucus plugs in PB. On the other hand, the influenza B virus binds mainly to human-type receptors expressed on the epithelial cells of the upper respiratory tract. Thus, influenza B is not likely to grow in the lower respiratory tract and directly cause inflammation. In our patient, the influenza B viral RNA load in the lower respiratory tract ( $1.07 \times 10^4$  copies/mL) was approximately one hundredth of that in the upper respiratory tract ( $2.45 \times 10^6$  copies/mL); this was even almost the same as that observed in the upper respiratory tract 7 days after onset<sup>7</sup>, suggesting that viral infectivity is likely to be low. A previous report by Sanerkin *et al.* demonstrated the presence of eosinophils and fibrin in the submucosal layer of the bronchi in PB following infection. They proposed that allergic inflammation produces secretions in the trachea and leads to the formation of bronchial casts<sup>16</sup>. In general, an elevation of eosinophil count in the peripheral blood is often observed in patients with bronchial asthma, but this was not seen in our patient at hospitalization. This could be attributed to the patient's dexamethasone therapy for 2 days before hospitalization. In our patient, a clinically significant allergic reaction involving IgE

transiently induced by influenza B virus infection, rather than direct viral inflammation, in the lower respiratory tract may have played an important role in the development of PB with type 1 mucus plugs. Because our patient had no allergic symptoms so far, the presence of an allergic background was uncertain. However, throughout the patient's clinical course, he had high serum IgE levels (14,854 IU/mL) in the acute phase and a subsequent marked decline to 3,955 IU/mL 10 months after discharge. These findings suggest a potential allergic background as an etiology. An increase in IgE production due to influenza B has not been reported, and thus the increased IgE production in this case may have been due to a potential allergic background alongside the infection. Although this patient has had no symptoms of allergic disease after discharge, he should be carefully observed for IgE-mediated allergic reactions associated with recurrent influenza B virus infections. In conclusion, this case of PB occurred in a 3-year-old boy who developed acute respiratory failure after influenza B virus infection. The mucus plugs in the lower respiratory tract most likely resulted from an allergic reaction rather than as a direct result of influenza B virus infection. We obtained informed consent from the patient's parents to publish this report, and confirmed that ethics committee review and approval was not required.

### Acknowledgment

**Funding :** This research did not receive any specific grant from funding agencies in the public, commercial, or not-for-profit sectors.

**Declarations of interest :** None

**Providing language help :** The authors would like to thank Enago ([www.enago.jp](http://www.enago.jp)) for the English language review.

### References

1. Brogan TV, Finn LS, Pyskaty DJ Jr, Redding GJ, Ricker D, Inglis A, *et al.* Plastic bronchitis in children : a case series and review of the medical literature. *Pediatr Pulmonol*, **34** : 482-487, 2002. <https://doi.org/10.1002/ppul.10179>
2. Terano C, Miura M, Fukuzawa R, Saito Y, Arai H, Sasaki M, *et al.* Three children with plastic bronchitis associated with 2009 H1N1 influenza virus infection. *Pediatr Infect Dis J*, **30** : 80-82, 2011. <https://doi.org/10.1097/INF0b013e3181f10fff>
3. Deng J, Zheng Y, Li C, Ma Z, Wang H, Rubin BK. Plastic bronchitis in three children associated with 2009 influenza A(H1N1) virus infection. *Chest*, **138** : 1486-1488, 2010. <https://doi.org/10.1378/chest.10-0548>
4. Uda K, Shoji K, Koyama-Wakai C, Furuichi M, Iwase N, Fujisaki S, *et al.* Clinical characteristics of influenza virus-induced lower respiratory infection during the 2015 to 2016 season. *J Infect Chemother*, **24** : 407-413, 2018. <https://doi.org/10.1016/j.jiac.2018.01.002>
5. Kirito Y, Matsubayashi T, Ohsugi K. Plastic bronchitis : Three cases caused by influenza B virus Yamagata lineage. *Pediatr Int*, **61** : 421-423, 2019. <https://doi.org/10.1111/ped.13799>
6. Zhang J, Kang X. Plastic bronchitis associated with influenza virus infection in children : a report on 14 cases. *Int J Pediatr Otorhinolaryngol*, **79** : 481-486, 2015. <https://doi.org/10.1016/j.ijporl.2015.01.002>
7. Sato M, Honzumi K, Sato T, Hashimoto K, Watanabe M, Miyazaki K, *et al.* Sequential influenza B viral load and susceptibility in children treated with oseltamivir and zanamivir. *Pediatr Infect Dis J*, **33** : e168-172, 2014. <https://doi.org/10.1097/INF.0000000000000266>
8. Bowen A, Oudjhane K, Odagiri K, Liston SL, Cumming WA, Oh KS. Plastic bronchitis : large, branching, mucoid bronchial casts in children. *AJR Am J Roentgenol*, **144** : 371-375, 1985. <https://www.ajronline.org/doi/10.2214/ajr.144.2.371>
9. Li Y, Williams RJ, Dombrowski ND, Watters K, Daly KP, Irace AL, *et al.* Current evaluation and management of plastic bronchitis in the pediatric population. *Int J Pediatr Otorhinolaryngol*, **130** : 109799, 2020. <https://doi.org/10.1016/j.ijporl.2019.109799>
10. Seear M, Hui H, Magee F, Bohn D, Cutz E. Bronchial casts in children : a proposed classification based on nine cases and a review of the literature. *Am J Respir Crit Care Med*, **155** : 364-370, 1997. <https://doi.org/10.1164/ajrccm.155.1.9001337>
11. Liu Y, Childs RA, Matrosovich T, Wharton S, Palma AS, Chai W, *et al.* Altered receptor specificity and cell tropism of D222G hemagglutinin mutants isolated from fatal cases of pandemic A(H1N1) 2009 influenza virus. *J Virol*, **84** : 12069-12074, 2010. <https://doi.org/10.1128/JVI.01639-10>
12. Ibricevic A, Pekosz A, Walter MJ, Newby C, Battaile JT, Brown EG, *et al.* Influenza virus receptor specificity and cell tropism in mouse and human airway epithelial cells. *J Virol*, **80** : 7469-7480, 2006. <https://doi.org/10.1128/JVI.02677-05>
13. Suyama K, Kawasaki Y, Suzuki Y, Ishii K, Sakai N, Sato M, *et al.* Treatment with oseltamivir and prone positioning for a 9-year-old boy with ARDS

- caused by pandemic H1N1 2009 influenza. *Pediatr Int*, **55** : e77-80, 2013. <https://doi.org/10.1111/ped.12055>
14. Suzuki S, Suzuki Y, Yamamoto N, Matsumoto Y, Shirai A, Okubo T. Influenza A virus infection increases IgE production and airway responsiveness in aerosolized antigen-exposed mice. *J Allergy Clin Immunol*, **102** : 732-740, 1998. [https://doi.org/10.1016/S0091-6749\(98\)70012-0](https://doi.org/10.1016/S0091-6749(98)70012-0)
  15. Birmingham JM, Gillespie VL, Srivastava K, Li XM, Busse PJ. Influenza A infection enhances antigen induced airway inflammation and hyperresponsiveness in young but not aged mice. *Clin Exp Allergy*, **44** : 1188-1199, 2014. <https://doi.org/10.1111/cea.12365>
  16. Sanerkin NG, Seal RM, Leopold JG. Plastic bronchitis, mucoid impaction of the bronchi and allergic broncho-pulmonary aspergillosis, and their relationship to bronchial asthma. *Ann Allergy*, **24** : 586-594, 1966.