



Since January 2020 Elsevier has created a COVID-19 resource centre with free information in English and Mandarin on the novel coronavirus COVID-19. The COVID-19 resource centre is hosted on Elsevier Connect, the company's public news and information website.

Elsevier hereby grants permission to make all its COVID-19-related research that is available on the COVID-19 resource centre - including this research content - immediately available in PubMed Central and other publicly funded repositories, such as the WHO COVID database with rights for unrestricted research re-use and analyses in any form or by any means with acknowledgement of the original source. These permissions are granted for free by Elsevier for as long as the COVID-19 resource centre remains active.



Preoperative Chest Computed Tomography Screening for Coronavirus Disease 2019 in Asymptomatic Patients Undergoing Cardiac Surgery

Wiebe G. Knol, MD,^{*,†} Daniel J.F.M. Thuijs, MD,^{*} Arlette E. Odink, MD, PhD,[†] Pál Maurovich-Horvat, MD, PhD,[‡] Pim A. de Jong, MD, PhD,[§] Gabriel P. Krestin, MD, PhD,[†] Ad J.J.C. Bogers, MD, PhD,^{*} and Ricardo P.J. Budde, MD, PhD[†]

Due to the outbreak of Severe Acute Respiratory Syndrome coronavirus (SARS-Cov-2), an efficient COVID-19 screening strategy is required for patients undergoing cardiac surgery. The objective of this prospective observational study was to evaluate the role of preoperative computed tomography (CT) screening for COVID-19 in a population of COVID-19 asymptomatic patients scheduled for cardiac surgery. Between the 29th of March and the 26th of May 2020, patients asymptomatic for COVID-19 underwent a CT-scan the day before surgery, with reverse-transcriptase polymerase-chain reaction (RT-PCR) reserved for abnormal scan results. The primary endpoint was the prevalence of abnormal scans, which was evaluated using the CO-RADS score, a COVID-19 specific grading system. In a secondary analysis, the rate of abnormal scans was compared between the screening cohort and matched historical controls who underwent routine preoperative CT-screening prior to the SARS-Cov-2 outbreak. Of the 109 patients that underwent CT-screening, an abnormal scan result was observed in 7.3% (95% confidence interval: 3.2–14.0%). One patient, with a normal screening CT, was tested positive for COVID-19, with the first positive RT-PCR on the ninth day after surgery. A rate of preoperative CT-scan abnormalities of 8% ($n = 8$) was found in the unexposed historical controls ($P > 0.999$). In asymptomatic patients undergoing cardiac surgery, preoperative screening for COVID-19 using computed tomography will identify pulmonary abnormalities in a small percentage of patients that do not seem to have COVID-19. Depending on the prevalence of COVID-19, this results in an unfavorable positive predictive value of CT screening. Care should be taken when considering CT as a screening tool prior to cardiac surgery.

Semin Thoracic Surg 33:417–424 © 2020 The Author(s). Published by Elsevier Inc. This is an open access article under the CC BY license (<http://creativecommons.org/licenses/by/4.0/>)

Abbreviations: COVID-19, coronavirus disease; CT, computed tomography; RT-PCR, reverse-transcriptase polymerase-chain reaction test; SARS-Cov-2, the novel coronavirus

^{*}Department of Cardiothoracic Surgery, Erasmus University Medical Center, Rotterdam, The Netherlands

[†]Department of Radiology and Nuclear Medicine, Erasmus University Medical Center, Rotterdam, The Netherlands

[‡]Department of Radiology, Medical Imaging Centre, Semmelweis University, Budapest, Hungary

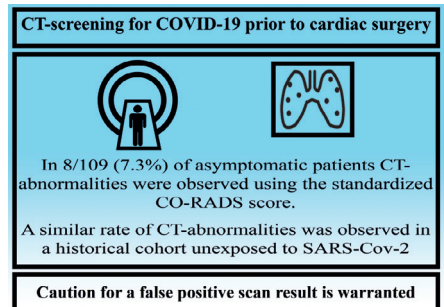
[§]Department of Radiology, University Medical Center Utrecht and Utrecht University, The Netherlands

Funding statement: No funding was received for this work.

Conflict of interest: Nothing to disclose.

IRB approval: Received on May 6th, 2020 (MEC-2020-0362).

Address reprint requests to R.P.J. Budde, MD, PhD, Department of Radiology, Erasmus Medical Center, PO BOX 2040, ND-547, 3000 CA Rotterdam, The Netherlands. E-mail: r.budde@erasmusmc.nl



A visual overview of the main findings of this study.

Central Message

Preoperative computed tomography shows abnormalities comparable to those in COVID-19 in a small percentage of asymptomatic patients undergoing cardiac surgery, hampering its value as a screening tool.

Perspective Statement

An efficient COVID-19 screening strategy is required for patients undergoing cardiac surgery. Because the preoperative CT scan often shows pulmonary abnormalities in patients without COVID-19 symptoms, addition of CT to a screening protocol will likely decrease positive predictive value. Care should be taken when CT as a screening tool for COVID-19 prior to cardiac surgery.

Keywords: Preoperative screening, Computed tomography, COVID-19, Cardiac surgery

INTRODUCTION

In March 2020, the World Health Organization declared the recent outbreak of the novel Severe Acute Respiratory Syndrome coronavirus (SARS-Cov-2) an official pandemic.¹ To meet the sudden increase in the demand for hospital care, much of the regular patient care had to be delayed. The pressure on the health care system caused limited availability of operating room capacity, intensive care beds and hospital staff and prompted a careful approach for patients in need of a surgical intervention. Early experience of surgical procedures in patients with the disease caused by SARS-Cov-2 (COVID-19) suggested that surgical risk is increased, especially as surgical complexity increases.² Cardiac surgery is complex and patients are routinely admitted to the intensive care unit. Furthermore, the risk of using extracorporeal circulation in patients with latent COVID-19 is unknown. To address these concerns preoperative screening for latent COVID-19 was implemented to optimize the utilization of the scarce healthcare resources, prevent the spread of the virus within the hospital and to prevent a possible increase in perioperative complications and mortality. The Erasmus Medical Center Rotterdam adopted a preoperative screening program using computed tomography (CT) first and subsequent RT-PCR in patients with a positive CT-scan suspected of COVID-19. Although several early studies from China reported on the diagnostic accuracy of CT in patients suspected of COVID-19, not much is known on the use of CT in preoperative screening of asymptomatic patients.^{3,4} We evaluated the CT findings of preoperative screening CT for COVID-19 in a population of asymptomatic patients scheduled for cardiac surgery and compared these with CT findings from a recently completed trial with similar inclusion criteria, performed prior to the outbreak.

METHODS

Study Design

Between the 29th of March and the 26th of May 2020, all adult patients scheduled for cardiac surgery in the Erasmus Medical Center underwent preoperative screening for COVID-19 using CT. Patients were asked for symptoms of COVID-19 prior to admission, based on recent exposure to high endemic areas or diseased persons, or presence of one or more of the following symptoms: Congestion or runny nose, sore throat, sneezing, coughing, dyspnea, chills, fever, new loss of taste or smell. Only patients without these symptoms underwent subsequent screening with a CT-scan. Patients that did not undergo the screening CT-scan were excluded from the analysis. Patients were prospectively included in the study and their medical charts were reviewed. Baseline characteristics, CT-scan findings as reported by the radiologist, and perioperative outcomes were extracted from the patient electronic information

system. The EuroScore II was calculated for each patient as a measure of the surgical risk.⁵ Approval was obtained from the local Medical Ethics Committee (MEC-2020-0362) and the patients were asked to sign for informed consent. The study adhered to the STROBE statement for reporting on observational cohort studies.⁶

Computed Tomography Screening

Patients underwent a noncontrast enhanced CT-scan of the chest the day before surgery. Scans were performed on any of the following scanners: SOMATOM Force, Edge Plus or Definition Edge, (all Siemens Healthcare) and the entire lungs were included in the scan range. The clinical reports of the attending radiologist, in most cases a (cardio)thoracic radiologist, were used for the study. All radiologists reporting the scans in our hospital were trained in using the system. In all patients a standardized reporting format was used, based on the recently published CO-RADS score, created by the Dutch radiological society.⁷ This score categorizes each scan as one of 5 CO-RADS grades, with CO-RADS 1 indicating a very low suspicion, CO-RADS 2 low, CO-RADS 3 unsure, CO-RADS 4 high and CO-RADS 5 very high suspicion. The CO-RADS score is based on the conformity of the findings on the scan with the typical radiological findings seen in COVID-19. The score system has been shown to perform well and interobserver agreement ranges from substantial to almost perfect.^{7,8} Clinical findings are not included in the score and CO-RADS 6, which is used clinically for patients with a positive RT-PCR test, was not used in our study. According to the local hospital protocol only patients with a CO-RADS score of 2 (low suspicion) or higher underwent subsequent RT-PCR testing with a nasopharyngeal swab. During the postoperative phase, RT-PCR was performed at the discretion of the clinician. In patients with high clinical suspicion, multiple RT-PCR tests were performed. Apart from the determination of the CO-RADS score, a severity score was calculated for patients with CO-RADS 3–5 using a method that has been validated in a prior outbreak of a severe acute respiratory syndrome coronavirus and has been shown to identify patients with severe COVID-19.^{9,10} A score of 0–5 is assigned per lobe based on the total involvement of that lobe with, e.g., ground glass opacities as 0%, 1–5%, 5–25%, 25–50%, 50–75% or >75%, yielding a maximum severity score of 25 points. For each scan the following radiological pulmonary abnormalities were also systematically scored: Ground glass opacities, pulmonary consolidation, pleural fluid, pericardial fluid, pulmonary infiltrate, or lymphadenopathy.

Endpoints

The primary endpoint was the prevalence of abnormalities on the preoperative scan, defined as a CO-RADS score of 2 or higher. Secondary endpoints were the proportion of patients

with a positive RT-PCR test, change of surgical approach including postponement or cancellation of surgery, postoperative respiratory complications and in-hospital mortality. Any SARS-Cov-2 RT-PCR test that was performed during the hospital admission, either before or after the CT-scan, was considered for the analysis. Change of surgical approach was subcategorized in COVID-19 related and unrelated changes. Changes were regarded as COVID-19 related when they were directly related either to a perceived risk of adverse outcome for the patient itself due to a possible latent COVID-19 infection or to a perceived risk of virus transmission by the patient to others. The decision to change the approach was at the surgeons' discretion. Postoperative respiratory complications were a composite of postoperative pneumonia requiring treatment or postoperative respiratory failure, defined as the need for mechanical ventilator support >72 due to respiratory insufficiency, similar to previous research.¹¹

Matched Historical Control Group

Because the CO-RADS grading system categorizes abnormalities on the scan according to the level of suspicion of COVID-19, abnormal scans can also be caused by other pathologies.⁷ For instance an area of ground glass in the lung may also be due to a non-COVID-19 infection. As a secondary analysis, with the aim to better understand the meaning of the prevalence of abnormal scans in the screening cohort, a historical control group was matched. In a recent randomized controlled trial studying the effect of preoperative CT screening on the risk of stroke in general cardiac surgery, the intervention group also underwent routine chest CT imaging prior to surgery.¹² Patients were enrolled between September 2014 and October 2019 and were therefore not exposed to SARS-Cov-2 as the first positive test in the Netherlands was not before the February 27, 2020. All patients from the intervention arm with an available scan were matched 1:1 to patients in the screening cohort. Exact matching was applied to the type of surgery (aortic valve replacement, coronary artery bypass grafting, mitral valve surgery or other surgery) and the urgency (elective, urgent, emergent or salvage) of the operation. Nearest neighbor matching with a maximum width of 7.5 years was used for age. The CT-scans of the control cohort were re-examined by an experienced cardiothoracic radiologist (R.B.) using the same standard reporting format. The endpoint of this secondary analysis was again the prevalence of abnormalities on the preoperative scan defined by the CO-RADS score.

Statistical Analysis

In the primary analysis, continuous variables were presented as the mean \pm standard deviation or median with the 1st and 3rd interquartile depending on the data distribution. Categorical variables were described as a count with the corresponding percentage. For the primary endpoint a 95% confidence interval was calculated using the Clopper-Pearson method. As the cohorts in the secondary analysis were matched, we compared

the 2 groups accounting for dependent samples. Continuous data were compared using the paired t-test or Wilcoxon signed-rank test depending on the data distribution and categorical data were compared using McNemar's test. All analyses and the matching procedure were performed using SPSS software version 25 (SPSS Inc, Chicago, Illinois).

RESULTS

Study Population

A total of 130 adult patients underwent cardiac surgery during the inclusion period including 110 (85%) that underwent the preoperative CT-scan. A flowchart of the study is shown in [Figure 1](#). Reasons not to undergo the CT-scan were emergency surgery, ($n = 13$, 65%), a CT-scan that was already made for other indications in patients already admitted to the hospital ($n = 6$, 30%) or presence of already known pulmonary abnormalities that would lead to an abnormal scan result ($n = 1$, 5%). RT-PCR tests were done in 13 of these 20 patients, all of which were negative. None of these patients were suspected of COVID-19, neither before nor after surgery. Of the 110 patients that underwent CT-screening, only 1 patient refused consent to use the data. Baseline characteristics of the remaining 109 patients, who comprise the screening cohort of this study, are shown in [Table 1](#). A specification of all types of surgery can be found in Supplementary Table S1.

Endpoints

As is shown in [Table 2](#), CO-RADS 2 or higher was found in 8 (7.3 %) patients (95% confidence interval: 3.2–14.0%). In spite of the local screening protocol, 2 of the 8 patients with abnormal scans were not tested with a RT-PCR, both because of a CO-RADS 2 score with low clinical suspicion of COVID-19. The remaining 6 patients all tested SARS-Cov-2 negative. Sample images of the 5 CO-RADS categories are shown in [Figure 2](#). Additional information on the 8 patients with abnormal scan results is provided in Supplementary table S2. In 9 of 101 patients with a normal screening CT-scan, a RT-PCR test was performed after surgery, for clinical suspicion of COVID-19 during the postoperative course. Of these patients only one tested positive, with the first positive RT-PCR on the ninth day after surgery and tenth day after the CT scan. In one patient, a CO-RADS score could not be given because of known pre-existing bilateral pulmonary abnormalities on a recent CT-scan. Because the severity of these abnormalities was clearly decreased on the screening CT-scan, the scan result was regarded as normal.

The preoperative CT-scan led to a change in the surgical approach in 7% of patients ($n = 8$). Five of these changes were caused by an abnormal result of the CT-scan, against the background of possible adverse outcome of COVID-19 infection. All changes are specified in [Table 3](#) and the specific reasons for change are shown in Supplementary Table S3. Postoperative respiratory complications were observed in 10% ($n = 11$) of

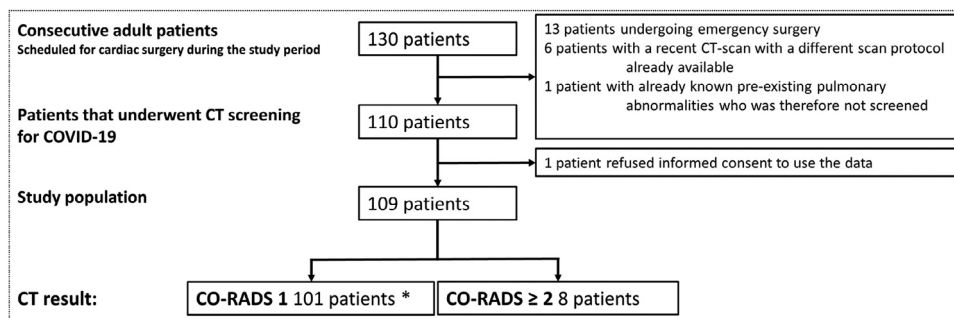


Figure 1. A flowchart of the consecutive patients enrolled in the study. *Including one patient with pre-existing pulmonary abnormalities which were decreased at the time of the screening CT-scan. Although reporting a CO-RADS score was not possible, the scan was regarded as normal. (Color version of figure is available online at <http://www.semthorcardiovascsurg.com>.)

patients, among whom was the patient with the positive RT-PCR. The in-hospital mortality rate was 2% (2 patients), although one patient was still admitted to the hospital at the time of the analysis.

Matched Historical Cohort Analysis

Of the 109 patients in the screening cohort 95 patients were successfully matched. The baseline characteristics of the matched cohort are also shown in Table 1. Of the 95 matched controls 8% ($n = 8$) of the scans were found to be CO-RADS 2

or higher ($P > 0.999$). A specification of the CO-RADS scores is shown in Table 4. Table 5 shows the abnormalities that were found on CT in the entire screening cohort and in the secondary analysis.

DISCUSSION

Preoperative screening for COVID-19 using computed tomography in asymptomatic patients scheduled for cardiac surgery resulted in abnormalities on 7.3 % of the scans. All patients with an abnormal scan were either at very low clinical

Table 1. Baseline Characteristics of the Screening Cohort and the Two Groups in the Matched Cohort

		Screening Cohort $n = 109$	Matched Population		<i>P</i> -value
			Screening cohort $n = 95$	Control cohort $n = 95$	
Age		63.9 ± 11.7	65.7 ± 9.9	66.0 ± 9.4	0.408
Sex	Male	74% (81)	74% (70)	79% (75)	0.511
Hypertension		72% (78)	75% (71)	66% (63)	0.391
Diabetes	Oral	17% (18)	18% (17)	14% (13)	0.302*
	Insulin	13% (14)	14% (13)	10% (9)	
Smoking	Stopped	34% (37)	34% (32)	40% (38)	0.165 [#]
	Current	16% (17)	15% (14)	17% (16)	
COPD		15% (16)	17% (16)	13% (12)	0.556
Prior cardiac surgery		5% (5)	2% (2)	4% (4)	0.688
EuroScore II	Median (IQR)	1.59 (0.96–2.94)	1.46 (0.96–2.57)	1.19 (0.80–2.20)	0.366
Urgency	Elective	75% (82)	78% (74)	78% (74)	
	Urgent	25% (27)	22% (21)	22% (21)	
Type of surgery	AVR	10% (11)	11% (10)	11% (10)	
	CABG	55% (60)	60% (57)	60% (57)	
	AVR+CABG	6% (6)	6% (6)	6% (6)	
	Mitral valve surgery	9% (10)	9% (9)	9% (9)	
	Other [†]	20% (22)	14% (13)	14% (13)	
Radiation dose of CT-scan (DLP in mGy.cm)	Median (IQR)	115 (81–185)	119 (84–186)	46 (35–51)	<0.001

*The *P*-value is based on a binary comparison of the presence of diabetes between the matched groups.

[#]The *P*-value is based on the comparison of presence or absence of a history of smoking between the matched groups.

[†]A specification of all types of surgery can be found in supplementary table S1. AVR, aortic valve replacement; CABG, coronary artery bypass grafting; COPD, chronic obstructive pulmonary disease; DLP, dose length product. Proportions are given as a % (n).

Table 2. Abnormalities on the Preoperative CT-Scan According to the CO-RADS Score in the Screening Cohort

	CO-RADS 1	CO-RADS 2	CO-RADS 3	CO-RADS 4	CO-RADS 5	Total
No RT-PCR done	91	2	0	0	0	93
RT-PCR negative	8	0	4	1	1	14
RT-PCR positive	1	0	0	0	0	1
Total	100	2	4	1	1	108

RT-PCR, reverse-transcriptase polymerase chain reaction test.

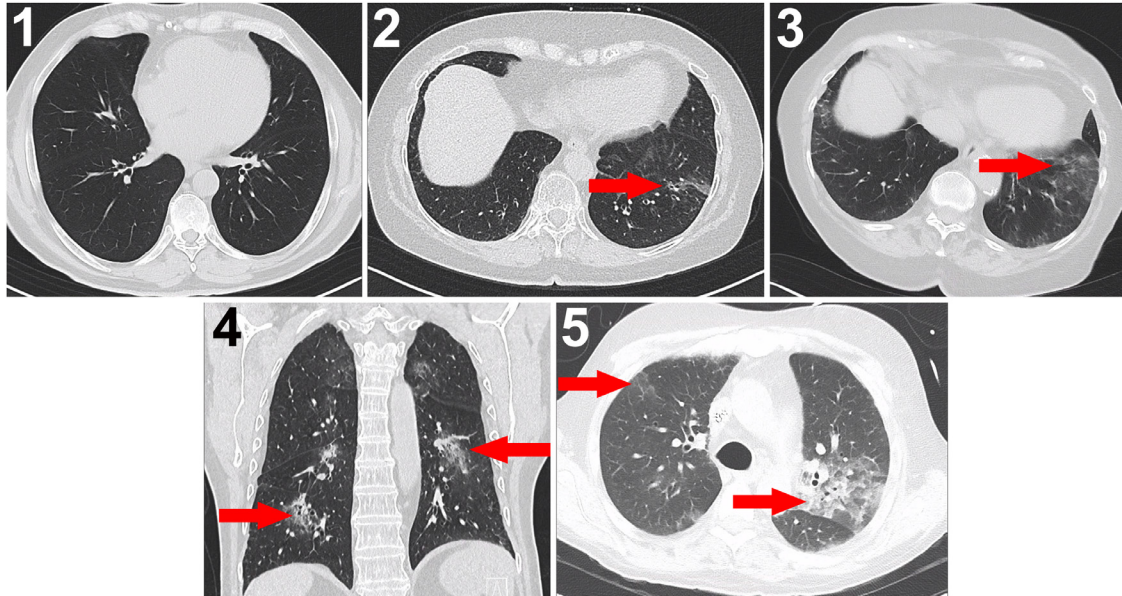


Figure 2. Examples of all 5 CO-RADS categories (1 = very low suspicion, 2 = low, 3 = unsure, 4 = high and 5 = very high suspicion). 1: no abnormalities. 2: thickened bronchial walls and tree-in-bud feature, not typical for COVID-19. 3: Unilateral ground glass lesion in the lower left lobe. 4: bilateral multifocal ground glass opacities, but not in close contact with the visceral pleura. 5: Bilateral ground glass opacities with peripheral distribution. The red arrows indicate the location of the abnormalities. CO-RADS score = a score system developed by the Dutch radiological society (NIVR) categorizing chest CT images based on the likelihood of COVID-19. COVID-19, Corona virus disease 2019.

suspicion for COVID-19 or tested negative with subsequent RT-PCR. One patient without abnormalities on the preoperative scan was tested RT-PCR positive for SARS-Cov-2 9 days

Table 3. Specification of Changes in the Surgical Approach, Subcategorized in COVID-19 Related and Unrelated

		No. of Patients
COVID-19 related changes	Percutaneous approach	2
	Postponement of surgery	1
	Strict isolation precautions	2
COVID-19 unrelated changes	Change to off-pump surgery	1
	Postponement of surgery for suspected malignancy	2
Total changes in approach:		8

after surgery and had a complicated postoperative course. In a secondary analysis, the rate of abnormal scans was comparable between patients from the screening cohort and matched patients from a historical control group that underwent surgery prior to the SARS-Cov-2 outbreak. These main findings are summarized in [Figure 3](#).

During the initial stages of the pandemic, CT-imaging presented as a valuable tool in diagnosing COVID-19. In addition to the more widespread availability of CT as opposed to RT-PCR testing, several early studies showed a high sensitivity of CT in diagnosing COVID-19.^{3,13} A more recent meta-analysis however, demonstrated that, in populations with a low disease prevalence, the positive predictive value of CT can be up to ten times lower than that of RT-PCR, owing to a low specificity of CT.⁴ In this regard, it should be mentioned that this meta-analysis used RT-PCR as the golden standard. This might have caused an underestimation of the diagnostic accuracy of CT, as previous studies found that up to half of the patients that tested RT-PCR negative, but CT positive, were highly suspected of

Table 4. Abnormalities on the Preoperative CT-Scan According to the CO-RADS Score in the Matched Cohort

	CO-RADS 1	CO-RADS 2	CO-RADS 3	CO-RADS 4	CO-RADS 5	Total
Matched screening cohort	86	2	4	1	1	94
Matched control cohort	87	2	6	0	0	95

Table 5. Pulmonary Abnormalities That Were Found in the Screening Cohort and in the Secondary Analysis

		Screening Cohort	Matched Population	
		N = 109	Screening cohort n = 95	Control cohort n = 95
Ground glass opacities	Unilateral	2% (2)	2% (2)	2% (2)
	Bilateral	6% (6)	6% (6)	5% (5)
Consolidation		5% (5)	5% (5)	6% (6)
Infiltrate		7% (8)	8% (8)	2% (2)
Pleural effusion		2% (2)	1% (1)	4% (4)
Pericardial effusion		1% (1)	0	0
Lymphadenopathy		3% (3)	3% (3)	2% (2)
Severity score	(in CO-RADS ≥ 3)	3.5 (1–9.25)	3.5 (1–9.25)	3 (1–4.5)

having COVID-19.³ However, it is unclear what the consequences of these findings are for a situation where CT is used for screening in asymptomatic individuals. The previous studies were all performed in patients with symptoms related to COVID-19. It could be argued that, when compared to an asymptomatic population, symptomatic patients with a negative RT-PCR would be more likely to have pulmonary abnormalities on the CT-scan, for instance due to another type of viral pneumonia. In the aforementioned studies this would be counted as a false-positive CT, thereby decreasing specificity. Previous studies evaluating asymptomatic RT-PCR positive patients showed that CT abnormalities were present in up to 83%.¹⁴ However, this was observed in an area with a high prevalence of COVID-19. The findings of these previous studies cannot simply be extrapolated to the setting of preoperative screening in nonendemic areas.

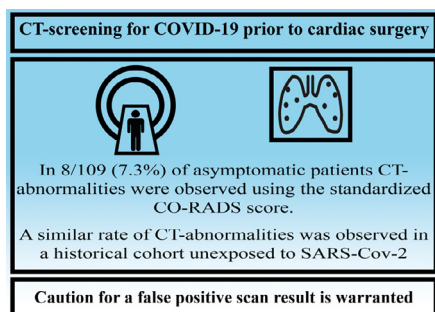


Figure 3. A visual overview of the main findings of this study. CO-RADS score = a score system developed by the Dutch radiological society (NIVR) categorizing chest CT images based on the likelihood of COVID-19. COVID-19, Coronavirus disease 2019, CT, computed tomography, SARS-Cov-2, the novel coronavirus. (Color version of figure is available online at <http://www.semthorcardiovascsurg.com>.)

In our study, the prevalence of COVID-19 was low. Only one patient tested positive for SARS-Cov-2 with RT-PCR. Halfway during our inclusion period, on the April 16, 2020, preliminary results of a prevalence study by the Dutch National Institute for Public Health and the Environment (RIVM) were presented, during a briefing of the Dutch parliament.¹⁵ It was found that in a sample of 4208 blood donors, SARS-Cov-2 specific antibodies were found in 3.2% ($n = 135$). This percentage increased to 5.5% in a second sample of approximately 7000 blood donors tested between the 10th and 20th of May.¹⁶ Given this low prevalence, our study is not able to evaluate the safety of the CT first screening approach. In the patient with a positive RT-PCR, no test was done before the ninth day after surgery and fever developed on the tenth postoperative day. Given the median incubation period of 5 days, it cannot be said whether the patient was infected before or after admission to the hospital.¹⁷

However, our study does have an important clinical implication. Using the CO-RADS grading system, we have observed abnormalities in 7.3% of the patients in the screening cohort. Our secondary matched analysis showed that this is a common finding in patients prior to cardiac surgery. Among these matched patients, some even showed abnormalities that were comparable to the radiological presentation of COVID-19, namely bilateral ground glass opacities.¹⁸ In future preoperative screening approaches in cardiac surgery, these patients should be taken into account as an expected rate of false positive CT-scans.

For a numerical example, assume that the prevalence of latent COVID-19 in asymptomatic individuals would be as high as 10%, with a sensitivity of 80% and theoretical specificity of 100% for the RT-PCR-assay used¹⁹ and a false-positive rate with additional CT-screening of 7.5%, comparable to our results. When screening 100 preoperative patients using RT-

PCR with additional CT, it would be expected that RT-PCR identifies 8 out of 10 patients with latent COVID-19. When adding CT to this screening protocol, the CT might be abnormal in the 2 remaining COVID-19 patients, but most likely CT would also be abnormal in additional 7 or 8 patients without COVID-19. Since all of these CT false positive and CT true positive patients would be asymptomatic and RT-PCR negative, subsequent alteration in patient management would have to be considered in all of them. For nonurgent procedures, postponing surgery is a sensible strategy. In more urgent cases, changing to a less invasive strategy, such as percutaneous treatment, will be considered. This might negatively influence the outcomes of patients with a false-positive CT-scan. Although our example is simplified and speculative, it illustrates the problem in clinical decision making when adding CT to the screening approach of asymptomatic patients prior to cardiac surgery. In this population, our results are in line with the recommendations of the European Society of Radiology, the European Society of Thoracic Imaging and the Fleischner Society not to implement CT screening in asymptomatic patients.^{20,21} If preoperative CT screening is nevertheless considered, for instance in areas with limited availability of RT-PCR testing, the rate of abnormalities found in this study could be used to estimate the potential benefit. This rate should then be weighed against the prevalence of COVID-19.

The decisions to change the surgical approach were taken at a time when the surgeons were not yet familiar with COVID-19 and the diagnostic performance of the various tests. During the larger part of the study period it was assumed that the CT abnormalities were caused by a latent COVID-19 infection with a false negative RT-PCR. This urged the change of approach despite a negative RT-PCR. The higher than expected rate of abnormalities in asymptomatic patient prompted the secondary analysis in the historical cohort, supporting the idea that the asymptomatic patients with abnormalities on the preoperative CT were most likely false positive.

As with all preoperative imaging strategies, radiation exposure is a factor that needs to be weighed carefully against the presumed benefit. Since the historical controls were derived from a study evaluating the use of a low-dose preoperative scan, it was expected that the radiation dose in these controls was lower. Although the scan quality was generally adequate for scoring the CO-RADS system, minor pulmonary abnormalities may have been missed. However, it was not the aim of this study to evaluate a potential dose reduction in the CT-scan protocol for pulmonary imaging.

Limitations

Care has to be taken in the interpretation of our results. First, no systematic RT-PCR tests were performed, the sample size was small and the prevalence of COVID-19 in our cohort was low. Therefore, our results cannot be used to estimate diagnostic accuracy of CT. The protocol deviation in the 2 patients with abnormal screening CT that did not undergo RT-PCR omitted the possibility to rule out latent COVID-19.

Second, the applied statistical methods analyzed the scan results as a binary variable and did not account for the degree of abnormality of the scans. Preferably, the CO-RADS score should be regarded as an ordinal variable with 5 distinct categories. However, our sample size was not sufficient for such an analysis. This is also the reason that we did not compare specific types of pulmonary abnormalities that might be more typical for COVID-19. The sample size also prevented us from evaluating potential risk factors of having pulmonary abnormalities, such as the preoperative degree of heart failure. As this study was conducted in the early stages of the SARS-Cov-2 outbreak, we have not encountered patients with a history of COVID-19 and residual abnormalities have not been accounted for. Due to different scan protocols, the radiologists could not be blinded to the study groups, which introduced a potential source of bias. Finally, we have only studied patients prior to cardiac surgery. These results should not be extrapolated to other surgical populations, as the rate of false-positive findings on CT could be lower in these populations. Also, a different rate of pulmonary abnormalities could be expected in populations with a different distribution of certain types of cardiac surgery.

CONCLUSION

In asymptomatic patients undergoing cardiac surgery, preoperative screening for COVID-19 using computed tomography will identify pulmonary abnormalities in a small percentage of patients that do not seem to have COVID-19. In these patients, management decisions that are taken based on the scan could be unnecessary. When the background prevalence of COVID-19 is low, the positive-predictive value of CT screening will be unfavorable and care should be taken when considering CT as a screening tool prior to cardiac surgery. The rate of abnormal scan findings not associated with COVID-19 should be taken into account when implementing CT screening, even in higher prevalence settings.

SUPPLEMENTARY MATERIAL

Scanning this QR code will take you to the article title page to access supplementary information.



REFERENCES

1. WHODirector-General's opening remarks at the media briefing on COVID19. 2020.
2. Lei S, Jiang F, Su W, et al: Clinical characteristics and outcomes of patients undergoing surgeries during the incubation period of COVID-19 infection. *Eclin Med* 21:100331, 2020
3. Ai T, Yang Z, Hou H, et al: Correlation of chest CT and RT-PCR testing in coronavirus disease 2019 (COVID-19) in China: A report of 1014 cases. *Radiology* 296:E32–E40, 2006

4. Kim H, Hong H, Yoon SH: Diagnostic performance of CT and reverse transcriptase-polymerase chain reaction for coronavirus disease 2019: A meta-analysis. *Radiology* 296:E145–E155, 2020
5. Nashef SA, Roques F, Sharples LD, et al: EuroSCORE II. *Eur J Cardiothorac Surg* 41:734–744, 2012. discussion 744-735
6. von Elm E, Altman DG, Egger M, et al: The Strengthening the Reporting of Observational Studies in Epidemiology (STROBE) statement: Guidelines for reporting observational studies. *Int J Surg* 12:1495–1499, 2014
7. Prokop M, van Everdingen W, van Rees Vellinga T, et al: CO-RADS - A categorical CT assessment scheme for patients with suspected COVID-19: Definition and evaluation. *Radiology* 296:E97–E104, 2020
8. Fujioka T, Takahashi M, Mori M, et al: Evaluation of the usefulness of CO-RADS for chest CT in patients suspected of having COVID-19. *Diagnostics* 10:608, 2020
9. Chang YC, Yu CJ, Chang SC, et al: Pulmonary sequelae in convalescent patients after severe acute respiratory syndrome: evaluation with thin-section CT. *Radiology* 236:1067–1075, 2005
10. Li K, Wu J, Wu F, et al: The clinical and chest CT features associated with severe and critical COVID-19 pneumonia. *Invest Radiol* 55:327–331, 2020
11. Canver CC, Chanda J: Intraoperative and postoperative risk factors for respiratory failure after coronary bypass. *Ann Thorac Surg* 75:853–857, 2003. discussion 857-858
12. den Harder AM, de Heer LM, Maurovich-Horvat P, et al: Ultra low-dose chest CT with iterative reconstructions as an alternative to conventional chest X-ray prior to heart surgery (CRICKET study): Rationale and design of a multicenter randomized trial. *J Cardiovasc Comput Tomogr* 10:242–245, 2016
13. Wang K, Kang S, Tian R, et al: Imaging manifestations and diagnostic value of chest CT of coronavirus disease 2019 (COVID-19) in the Xiaogan area. *Clin Radiol* 75:341–347, 2020
14. Ling Z, Xu X, Gan Q, et al: Asymptomatic SARS-CoV-2 infected patients with persistent negative CT findings. *Eur J Radiol* 126:108956, 2020
15. Technical briefing on Covid-19 of Dutch Parliament by J. van Dissel, chairmen of the National Institute of Public Health and the Environment. 2020.
16. Press release by Sanquin, the Dutch Blood Institute, 3rd of June. 2020.
17. Lauer SA, Grantz KH, Bi Q, et al: The incubation period of coronavirus disease 2019 (COVID-19) from publicly reported confirmed cases: Estimation and application. *Ann Intern Med* 172:577–582, 2020
18. Wu J, Pan J, Teng D, et al: Interpretation of CT signs of 2019 novel coronavirus (COVID-19) pneumonia. *Eur Radiol* 30:5455–5462, 2020
19. van Kasteren PB, van der Veer B, van den Brink S, et al: Comparison of seven commercial RT-PCR diagnostic kits for COVID-19. *J Clin Virol* 128:104412, 2020
20. Revel MP, Parkar AP, Prosch H, et al: COVID-19 patients and the radiology department - Advice from the European Society of Radiology (ESR) and the European Society of Thoracic Imaging (ESTI). *Eur Radiol* 2020
21. Rubin GD, Ryerson CJ, Haramati LB, et al: The role of chest imaging in patient management during the COVID-19 pandemic: A multinational consensus statement from the Fleischner society. *Radiology* 296:172–180, 2020