

RESEARCH

Pituitary metastasis: a rare condition

Aida Javanbakht¹, Massimo D'Apuzzo², Behnam Badie³ and Behrouz Salehian¹¹Department of Diabetes, Endocrinology and Metabolism, Beckman Research Institute of City of Hope, Duarte, California, USA²Department of Pathology, Beckman Research Institute of City of Hope, Duarte, California, USA³Department of Neurosurgery, Beckman Research Institute of City of Hope, Duarte, California, USACorrespondence should be addressed to A Javanbakht: aidajavanbakht@gmail.com

Abstract

Tumor metastasis to the pituitary gland is a rare, not well-documented and life-threatening condition associated with a shortened life span. A better understanding of its clinical manifestations could lead to earlier diagnosis, appropriate therapy and potentially improving quality of life. Therefore, we retrospectively studied the charts of patients with pituitary metastases who were treated at the City of Hope National Medical Center (Duarte, CA) from 1984 to 2018. We reviewed and analyzed tumor origin, primary pituitary clinical manifestation, duration between primary tumor diagnosis and pituitary metastasis, type of treatment and patient survival. A total of 11 patients were identified with a mean age of 59.2 years and median survival following the diagnosis of metastasis of 10 months. Breast cancer and lymphoma were the most common primary origins in these cases, and diabetes insipidus and panhypopituitarism were the most common clinical manifestations of their metastasis. We also compared our results with reports in the literature published between 1957 and 2018. A total 289 patients with pituitary metastasis have been reported in the literature. Breast cancer was the most frequent primary origin of the metastasis, and visual symptoms were the most common primary manifestation. The posterior part of the pituitary is more susceptible than the anterior to metastasis. Pituitary metastasis may occur as a consequence of successful primary tumor treatment prolonging the chance of seeding. Future studies are needed to determine the molecular mechanism of metastasis to the pituitary.

Key Words

- ▶ pituitary metastasis
- ▶ diabetes insipidus
- ▶ panhypopituitarism
- ▶ posterior pituitary

Endocrine Connections
(2018) **7**, 1049–1057

Introduction

Pituitary metastasis (Pit Met) is a rare condition first reported for the by Ludwig Benjamin in 1857 and subsequently by Harvey Cushing in 1913 (1). Detection of Pit Met is difficult, as they are easily missed in imaging studies and patients are frequently asymptomatic. Previous studies have reported that only 7% of Pit Mets are symptomatic (2, 3). There are reports of involvement of the anterior and posterior part of the pituitary gland (3). In contrast to pituitary adenomas, metastatic tumors, when detected, are more likely to be located in the posterior pituitary. This likely accounts for diabetes insipidus (DI) being more common in patients with Pit Met than patients with other pituitary pathology.

The exact reasons underlying the predilection of metastasis for the posterior pituitary is unknown.

Reports of Pit Met have largely been found in autopsies series performed for reasons unrelated to the presence of pituitary pathology (4, 5, 6, 7, 8, 9). In this report, we present a case series of Pit Met from City of Hope National Medical Center, recorded between 1984 and 2018, as well as a review of the relevant literature from 1957 to present.

Materials and methods

Data collection

Chart review was performed on all of the patients diagnosed with pituitary metastasis at City of Hope Hospital from 1984 to 2018. Key words employed in the electronic



record search included 'pituitary', 'metastasis' and 'brain metastasis.' Pituitary adenomas and other primary pituitary tumors (germinoma, chordoma, meningioma, etc.) were excluded. Information abstracted from patient records included tumor origin, primary pituitary clinical presentation, age, sex, type of treatment, presence of other metastases and survival. Also, analysis was made of the duration between primary tumor diagnosis and pituitary metastasis. The study was approved by the Beckman Research Institute of City of Hope Ethics Committee and consent was obtained from all patients.

Literature review

A query of PubMed spanning the years 1957 until 2018 was performed using the key words 'pituitary metastasis' and 'hypophyseal metastasis' and returned 156 manuscripts, 21 of which involved analysis of animals, leaving 135. Four references included in the analysis were identified from the bibliographies of the articles returned via the PubMed search and, excluding any cases from City of Hope left 139 original publications.

Statistical analysis

Results were summarized using descriptive statistics (mean, median and percentages, etc.) by a biostatistician using SPSS 16.0 for Windows.

Results

Case series at City of Hope

We identified a total of 11 patients (6 male) with a mean age of 59.2 years (range: 43–76) excluding one adult patient for whom the age was not recorded. There were no pediatric patients with pituitary metastasis. The most common tumors of origins were breast cancer (2 cases) and lymphoma (2 cases). The most common primary clinical presentations were panhypopituitarism (3 cases) and DI (3 cases). Visual symptoms were also noted in two patients. In keeping with the natural history of these lesions, several patients did not have any pituitary-related clinical manifestations. Four patients underwent transsphenoidal surgery (TSS); four patients with Pit Met were discovered by biopsy and three were identified at autopsy. At the time of analysis, five patients had died (mean time from diagnosis of Pit Met 2.7 months). The median survival after diagnosis of Pit Met was 10 months.

Ten cases had additional known metastases. All case data are presented in [Table 1](#).

Literature review

According to our search, a total of 289 pituitary metastases have been reported from 1957 to 2018. The mean age of patients was 56.6 years, and 52.9% were female. The frequencies of primary sites are summarized in [Fig. 1](#) (10, 11, 12, 13, 14, 15, 16, 17, 18, 19, 20, 21, 22, 23, 24, 25, 26, 27, 28, 29, 30, 31, 32, 33, 34, 35, 36, 37, 38, 39, 40, 41, 42, 43, 44, 45, 46, 47, 48, 49, 50, 51, 52, 53, 54, 55, 56, 57, 58, 59, 60, 61, 62, 63, 64, 65, 66, 67, 68, 69, 70, 71, 72, 73, 74, 75, 76, 77, 78, 79, 80, 81, 82, 83, 84, 85, 86, 87, 88, 89, 90, 91, 92, 93, 94, 95, 96, 97, 98, 99, 100, 101, 102, 103, 104, 105, 106, 107, 108, 109, 110, 111, 112, 113, 114, 115, 116, 117, 118, 119, 120, 121, 122, 123, 124, 125, 126, 127, 128, 129, 130, 131, 132, 133, 134, 135, 136, 137, 138, 139, 140). In addition, the frequencies of primary symptoms are reported in [Table 2](#), visual involvement was the most common. The median survival time after diagnosis of Pit Met was 10 months. A total of 179 (61.9%) Pit Met patients underwent surgery, and 175 (60.5%) of them had radiotherapy.

Discussion

Based on our literature reviewing, breast cancer was the most frequent primary origin of the metastasis, and visual involvement was the most common primary manifestation. The posterior part of the pituitary is more susceptible than the anterior to metastasis.

Between 0.14 and 3.6% of all intracranial metastases are in the pituitary (89, 141). It has been estimated that 1.8% of all surgically resected pituitary masses are metastases (6). The incidence of Pit Met is independent of gender, and most patients were in sixth decades of life. Although diagnostic methods and treatment options for patients with cancers have improved, at the same time the incidence of Pit Met has increased (142). Clinical symptoms due to the metastasis manifest in 2.5–18.2% of patients with Pit Met (142).

Symptoms vary from nonspecific manifestation, such as fatigue and headache, to more specific symptoms of polyuria and polydipsia. The frequent absence or nonspecific nature of Pit Met symptoms makes diagnosis difficult delaying detection of early-stage disease. In our study, 60% of cases exhibited pituitary dysfunction with clinical manifestation. The most common clinical

Table 1 Summary of pituitary metastasis cases at City of Hope Hospital from 1984 to 2018.

Subject	Origin	Age	Sex	Primary pituitary manifestation	Other metastases	Pit Met DX after primary tumor (years)	TX	Survival after Pit Met DX (months)	Alive
Solid organ cancers									
1	Breast (HER2-)	49	F	DI	No	5	TSS	8	Yes
2	Breast (HER2+)	54	F	Panhypopituitarism	Bone	5	Chemo	5	Yes
3	Testicular germ cell tumor	52	M	Panhypothyroidism	Lung	Same time	RT	4	No
4	Lung carcinoma	43	M	DI	Liver, bone	11	TSS	10	Yes
5	Colon adenocarcinoma	61	M	None	Temporal-parietal	1	TSS	3	No
6	Yolk sac	NA	M	NA	Liver	NA	NA	NA	No
7	Papillary thyroid	65	F	None	Intestinal	Same time	No	1	No
Hematologic cancers									
8	Hodgkin lymphoma	65	M	None	Papillary, thyroid, lung	Same time	NA	NA	No
9	Diffuse large B cell lymphoma	72	F	Visual involvement, panhypothyroidism	Hypothalamic	5 months	Chemo	36	Yes
10	Eosinophilic granuloma, dendritic cell tumor	55	M	DI	Bone	Same time	RT	432	Yes
11	Multiple myeloma	76	F	Visual involvement	Thyroid	Same time	TSS and RT	84	Yes

DI, diabetes insipidus; DX, diagnosis; F, female; HER2, human epidermal growth factor receptor 2; M, male; NA, not available; Pit Met, pituitary metastasis; RT, radiation therapy; TSS, transsphenoidal surgery, TX, treatment.

manifestations were DI and panhypopituitarism (27.7% each). In primary pituitary adenoma, 1% of patients present with DI, so it has been suggested that patients presenting with DI undergo evaluation for pituitary metastasis via MRI prior to evaluation of the primary tumor source (143). Based on review of the literature, visual problems are the most common first manifestation of Pit Met (Table 2). The difference between our institutional disease rates vs literature-derived rates might be related to late diagnosis of Pit Met and rapid growth of tumors in patients with end-stage cancer.

Patients with breast cancer had Pit Met 9.3 times more frequently than other types of cancers (144, 145). Consistent with this finding, review of the literature showed that breast cancer was the most common source of Pit Met (Fig. 1). In the City of Hope series contained herein, breast cancer and lymphoma were equally the most common primary metastasis source. It is hypothesized that elevated hormone levels in the pituitary gland, especially prolactin, may attract metastatic cells (85). Recent studies have found that anti-HER-2 treatment can facilitate Pit Met (145, 146, 147). In contrast, one of our patients with HER2-positive breast cancer developed Pit Met before receiving anti-HER2 treatment. Future studies are needed to understand the role of the anti-HER2 treatment in the development of Pit Met.

Review of the literature revealed lung cancer to be the second most common source of Pit Met. The lung cancers, being mostly asymptomatic, were discovered in the late stages of disease. In another study, Pit Mets were the first metastatic manifestation of the primary tumor in 34.5% of cases and lung cancers were the source of Pit Mets in 50% (11). Thyroid cancer is the third most common source of Pit Met. Occasionally, papillary thyroid cancer is diagnosed after finding Pit Mets, while the first symptoms in patients with papillary thyroid cancer may be visual (123).

The frequency of renal cell carcinoma is low worldwide (148, 149), but it is the fourth most common primary site of Pit Met. This raises the question of possible molecular interactions between renal cell carcinoma and Pit Met including pituitary-originating homing signals or specific characteristics of renal cancers that favor pituitary metastasis. Based on data from the literature, the incidence of Pit Met arising from cancers of the cervix, pancreas, nasal membranes or germinomas is low. However, the rarity of Pit Met suggests a random nature to these, rather pituitary signals attracting the cancer.

When tumors do metastasize, the posterior part of the pituitary is more susceptible than the anterior.

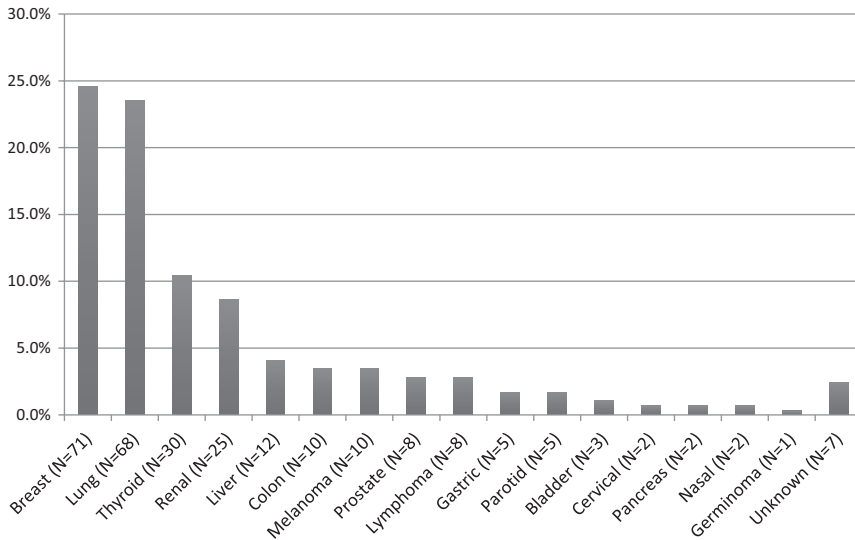


Figure 1 Frequencies of the pituitary metastasis primary sites reported in the literature from 1957 to 2018.

The incidence of metastatic involvement of the anterior pituitary varies from 23.7 to 40% (142). That most Pit Mets locate to the posterior pituitary may be, in part, due to the fact that this region of the gland is supplied by the systemic circulation, whereas the anterior pituitary receives blood via the hypophyseal portal system (149). Another explanation might be the difference in sizes of these areas. The posterior part of the gland is smaller than the anterior, suggesting that the same volume of metastasis in the posterior region will result in symptomatology sooner. Also, involvement and massive destruction of supraoptic and paraventricular nuclei in hypothalamus, where the synthesis of neurohypophysis hormones take place, by the extension of an infiltrating tumor, can cause DI. In addition, tumor infiltrating, the site of tracks convergence originating from hypothalamic nuclei, at the base of hypothalamus at the origin pituitary stalk, causes DI (150, 151, 152).

As there is no standardization to the treatment of Pit Mets, a number of approaches have been employed including surgical resection, radiosurgery, radiotherapy, chemotherapy and hormonotherapy. Surgery is used for confirming the diagnosis and decreasing symptoms. Hypervascularization of the tumor and invasion of the cavernous sinus and other nearby organs make total resection difficult (153). All therapies, including radiation therapy, surgical resection and intrathecal chemotherapy may cause panhypopituitarism. In our literature review, 179 cases had surgery. Regardless of which therapy is selected, experience at City of Hope suggests caution in the use of high-dose steroids prior to biopsy of pituitary masses suspicious for lymphoma. Under these circumstances, steroid use and subsequent tapering of the

same may mask the diagnosis of lymphoma, leading to a negative biopsy, causing early recurrence, and potentially negatively impacting vision.

Patient survival after the diagnosis of Pit Met depends on the presence of other metastases and the subtype of the primary malignancy. Resection alone, with or without radiotherapy, does not change survival rates (154). The median survival rate after surgical removal of the pituitary tumor is 6 months (155, 156). Review of the literature determined the mean survival post-Pit Met diagnosis was 13.6 months. In our case series in City of Hope Hospital, median survival after diagnosis of Pit Met was 10 months. The differences in these data could be secondary to earlier diagnosis and more aggressive treatment of metastasis in the City of Hope group.

The present study has a number of limitations. First, analysis of City of Hope cases was descriptive and retrospective with two cases having incomplete medical records. Second, the size of the clinical cohort was quite small, thus limiting the strength of any conclusions drawn. Third, the data were not balanced by a control cohort. And finally, the study was single center based and could be biased by local unaccounted for factors.

Table 2 Frequencies of primary symptoms of pituitary metastasis reported in the literature from 1957 to 2018.

Primary pituitary symptom	Number of cases	Percentage of cases (%)
Visual involvement	141	48.8
Panhypopituitarism	109	37.7
Diabetes insipidus	111	38.4
Headache	102	35.3

Although the detection and treatment of cancers in general have improved, the incidence of Pit Mets has been increasing. Pit Mets may be the initial presentation of many cancers or may arise during treatment. Physicians should be cautious when a patient presents with extreme fatigue or symptoms suspicious for hypothyroidism or hypoadrenalism. The mechanism of attracting metastatic cells to the pituitary gland is not clear yet. It may be due to the vascular distribution of the pituitary gland, characteristics of the primary tumor or yet to be determined features of the pituitary gland milieu. Determining the molecular characteristics of the tumor and hosting environments will help to elucidate the pathophysiology of this unusual condition.

Declaration of interest

B Salehian: Eisai Inc. Consultant, Speaker Bureau. The other contributing authors declare that they have no conflicts of interest.

Funding

This study did not receive funding from any agency in the public, commercial or not-for-profit sectors.

Author contribution statement

Study conception and design: Aida Javanbakht, Behrouz Salehian. Acquisition of data: Aida Javanbakht, Behrouz Salehian, Massimo D'Apuzzo, Behnam Badie. Analysis and interpretation of data: Aida Javanbakht. Drafting of manuscript: Aida Javanbakht. Critical revision: Behrouz Salehian.

Acknowledgement

The authors thank our colleague Kerin Higa for editing the manuscript.

References

- Chiang MF, Brock M & Patt S. Pituitary metastases. *Neurochirurgia* 1990 **33** 127–131. (<https://doi.org/10.1055/s-2008-1053571>)
- Freda PU, Wardlaw SL, Bruce JN, Post KD & Golland RS. Differential diagnosis in Cushing syndrome. Use of corticotropin-releasing hormone. *Medicine* 1995 **74** 74–82. (<https://doi.org/10.1097/00005792-199503000-00002>)
- Tears RJ & Silverman EM. Clinicopathologic review of 88 cases of carcinoma metastatic to the pituitary gland. *Cancer* 1975 **36** 216–220.
- Beltrami CA & Grandi E. Pituitary metastases. *Rivista di Patologia Clinica e Sperimentale* 1970 **11** 197–211.
- Delarue J, Chomette G, Pinaudeau Y, Brocheriou C & Auriol M. Pituitary metastases. Frequency. Histopathologic Study. *Archives d'Anatomie Pathologique* 1964 **12** 179–182.
- Fassett DR & Couldwell WT. Metastases to the pituitary gland. *Neurosurgical Focus* 2004 **16** E5.
- Metivier AC, Grunenberger F, Schumacher C, Schott R, Jeung MY, Schlienger JL, Pauli G & Quoix E. Pituitary metastases from lung cancer. Five cases. *Revue de Pneumologie Clinique* 2006 **62** 231–236.
- Ntyonga-Pono MP, Thomopoulos P & Luton JP. Pituitary metastases. 3 Cases. *Presse Medicale* 1999 **2** 1567–1571.
- Pozzessere D, Zafarana E, Buccoliero AM, Pratesi C, Fargnoli R, Di Leo A & Di Leo A. Gastric cancer metastatic to the pituitary gland: a case report. *Tumori* 2007 **93** 217–219. (<https://doi.org/10.1177/030089160709300221>)
- Agarwal KK, Sharma P, Singla S, Suman Kc S, Bal C & Kumar R. A rare case of non-small cell lung cancer metastasizing to the pituitary gland: detection with (18)F-FDG PET-CT. *Clinical Nuclear Medicine* 2014 **39** 318–319.
- Al-Aridi R, El Sibai K, Fu P, Khan M, Selman WR & Arafah BM. Clinical and biochemical characteristic features of metastatic cancer to the sella turcica: an analytical review. *Pituitary* 2014 **17** 575–587. (<https://doi.org/10.1007/s11102-013-0542-9>)
- Altay T, Krisht KM & Couldwell WT. Sellar and parasellar metastatic tumors. *International Journal of Surgical Oncology* 2012 **2012** 647256. (<https://doi.org/10.1155/2012/647256>)
- Ariel D, Sung H, Coghlan N, Dodd R, Gibbs IC & Katznelson L. Clinical characteristics and pituitary dysfunction in patients with metastatic cancer to the sella. *Endocrine Practices* 2013 **19** 914–919. (<https://doi.org/10.4158/EP12407.OR>)
- Aung TH, Po YC & Wong WK. Hepatocellular carcinoma with metastasis to the skull base, pituitary gland, sphenoid sinus, and cavernous sinus. *Hong Kong Medical Journal* 2002 **8** 48–51.
- Azambuja E, Piccart MJ & Awada A. Long-term survival in pituitary metastasis from breast cancer. *Breast* 2006 **15** 446–447.
- Barbaro D, Desogus N & Boni G. Pituitary metastasis of thyroid cancer. *Endocrine* 2013 **43** 485–493. (<https://doi.org/10.1007/s12020-012-9806-9>)
- Beckett DJ, Gama R, Wright J & Ferns GA. Renal carcinoma presenting with adrenocortical insufficiency due to a pituitary metastasis. *Annals of Clinical Biochemistry* 1998 **35** 542–544. (<https://doi.org/10.1177/000456329803500410>)
- Belfquih H, Akhaddar A, Elmoustarchid B & Boucetta M. Pituitary metastasis revealed by a chiasma syndrome. *Headache* 2012 **52** 820–821. (<https://doi.org/10.1111/j.1526-4610.2010.01805.x>)
- Bell CD, Kovacs K, Horvath E, Smythe H & Asa S. Papillary carcinoma of thyroid metastatic to the pituitary gland. *Archives of Pathology and Laboratory Medicine* 2001 **125** 935–938. ([https://doi.org/10.1043/0003-9985\(2001\)125<0935:PCOTMT>2.0.CO;2](https://doi.org/10.1043/0003-9985(2001)125<0935:PCOTMT>2.0.CO;2))
- Berney C, Borruat FX & de Tribolet N. Spontaneous visual improvement in pituitary metastasis. *European Journal of Ophthalmology* 2003 **13** 105–107. (<https://doi.org/10.1177/112067210301300120>)
- Bhatoo HS, Dutta V & Kannan N. Pituitary metastasis from medullary carcinoma of thyroid: case report and review of literature. *Journal of Neuro-Oncology* 2008 **89** 63–67. (<https://doi.org/10.1007/s11060-008-9586-5>)
- Bouaziz H, Kaffel N, Charfi N, Fourati M, Abid H & Abid M. Panhypopituitarism revealing metastasis of small-cell lung carcinoma associated with sarcoidosis. *Annales d'Endocrinologie* 2006 **67** 259–264.
- Buonaguidi R, Ferdeghini M, Faggionato F & Tusini G. Intracellular metastasis mimicking a pituitary adenoma. *Surgical Neurology* 1983 **20** 373–378. ([https://doi.org/10.1016/0090-3019\(83\)90005-8](https://doi.org/10.1016/0090-3019(83)90005-8))
- Burkhardt T, Henze M, Kluth LA, Westphal M, Schmidt NO & Flitsch J. Surgical management of pituitary metastases. *Pituitary* 2016 **19** 11–18. (<https://doi.org/10.1007/s11102-015-0676-z>)
- Cavallo LM & Solari D. Multimodality attitude for the treatment of a pituitary metastasis. *World Neurosurgery* 2013 **79** 673–674. (<https://doi.org/10.1016/j.wneu.2013.01.073>)
- Chrisoulidou A, Pazaitou-Panayiotou K, Flaris N, Drimonitis A, Giavroglou I, Ginikopoulou E & Vainas I. Pituitary metastasis of follicular thyroid carcinoma. *Hormone Research* 2004 **61** 190–192. (<https://doi.org/10.1159/000076387>)
- Clavier H, Poiradeau S, Le Gros V & Tourani JM. Pituitary metastasis of a small cell bronchial carcinoma responsible for diabetes

- insipidus and disclosed by corticosteroid therapy. *Revue des Maladies Respiratoires* 1987 **4** 185–186.
- 28 Coppola A, Spera C, Longobardi C & Vitter P. Etiopathogenetic aspects of central diabetes insipidus. Report of a clinical case. *Minerva Medica* 1989 **80** 1119–1124.
 - 29 Couldwell WT, Chandrasoma PT & Weiss MH. Pituitary gland metastasis from adenocarcinoma of the prostate. Case report. *Journal of Neurological Surgery* 1989 **71** 138–140.
 - 30 Cryar AK, Morgan J, Rock JP & Wisgerhof M. Pituitary metastasis: lung cancer presenting as bitemporal hemianopsia with diabetes insipidus and anterior pituitary deficiency. *Henry Ford Hospital Medical Journal* 1987 **35** 185–187.
 - 31 Ding H, Tao GS, Fan H, Zhang TT & Liu J. Gestational trophoblastic neoplasia metastasis to the pituitary: a case report. *Journal of Reproductive Medicine* 2015 **60** 547–552.
 - 32 Djimi H, Ayeboua L, Vally P, Olindo S, Cabre P, Ventura E, Landau M, Richer R & Merle H. Hypophysis metastasis of a hypernephroma tumor revealed by a chiasma syndrome. *Journal Français d'Ophthalmologie* 2003 **26** 976–979.
 - 33 Dogan M, Karakilic E, Oz II, Zorlu F & Akbulut H. Breast cancer with diabetes insipidus. *Experimental Oncology* 2008 **30** 324–326.
 - 34 Dou XL, Zhou N, Mai YL, Guan M, Sun Z, Gao X & Bai CM. Gastric cancer with pituitary metastasis presenting as symptomatic secondary adrenal insufficiency: a case report. *Journal of Digestive Diseases* 2017 **18** 369–372. (<https://doi.org/10.1111/1751-2980.12476>)
 - 35 Eloy P, Evrard AS, Donckier J, Godfraind C, Gustin T, Collet S, Rombaux P & Bertrand B. Metastasis of a small cell carcinoma from undetected origin to the pituitary gland – the otolaryngologist's view. *B-ENT* 2005 **1** 159–163.
 - 36 Ersoy R, Topaloglu O, Aydin C, Dirikoc A & Cakir B. Pituitary metastasis of breast cancer confirmed by fluorine-18 fluorodeoxyglucose positron emission tomography: a case report. *Journal of Endocrinological Investigation* 2007 **30** 532–533. (<https://doi.org/10.1007/BF03346341>)
 - 37 Feghaly J & Astras G. Diagnosis and management of isolated pituitary metastasis from adenocarcinoma of unknown origin presenting as loss of libido. *BMJ Case Reports* 2015 bcr2014208735. (<https://doi.org/10.1136/bcr-2014-208735>)
 - 38 Feletti A, Rossi S, Canal F, Longatti P & Billeci D. Pituitary metastasis of Merkel cell carcinoma. *Journal of Neuro-Oncology* 2010 **97** 295–299. (<https://doi.org/10.1007/s11060-009-0025-z>)
 - 39 Fridley J, Adams G, Rao V, Patel A, Humphries W, Goodman C & Gopinath S. Small cell lung cancer metastasis in the pituitary gland presenting with seizures and headache. *Journal of Clinical Neuroscience* 2011 **18** 420–422. (<https://doi.org/10.1016/j.jocn.2010.05.006>)
 - 40 Fukunaga A, Yazaki T, Shimizu K & Ochiai M. A case of pituitary metastasis in a patient with male breast cancer developing anterior lobe dysfunction successfully treated by using hormone replacement therapy. *No Shinkei Geka* 2014 **42** 629–633.
 - 41 Furuta S, Hatakeyama T, Zenke K & Fukumoto S. Pituitary metastasis from carcinoma of the urinary bladder mimicking pituitary apoplexy. Case report. *Neurologia Medico-Chirurgica* 1999 **39** 165–168.
 - 42 Gil J, Crespo C, Fra J, Ruiz de Temiño Á & Cuéllar L. Panhypopituitarism secondary to pituitary metastasis in a patient with breast cancer. *Semergen* 2016 **42** e4–e6.
 - 43 Goglia U, Ferone D, Sidoti M, Spaziante R, Dadati P, Ravetti JL, Villa G, Bodei L, Paganelli G, Minuto F, *et al.* Treatment of a pituitary metastasis from a neuroendocrine tumour: case report and literature review. *Pituitary* 2008 **11** 93–102. (<https://doi.org/10.1007/s11102-007-0038-6>)
 - 44 Gormally JE, Izard MA, Robinson BG & Boyle FM. Pituitary metastasis from breast cancer presenting as diabetes insipidus. *BMJ Case Reports* 2014 **2014** bcr2014203683. (<https://doi.org/10.1136/bcr-2014-203683>)
 - 45 Goulart CR, Upadhyay S, Ditzel Filho LFS, Beer-Furlan A, Carrau RL, Prevedello LM & Prevedello DM. Newly diagnosed sellar tumors in patients with cancer: a diagnostic challenge and management dilemma. *World Neurosurgery* 2017 **106** 254–265.
 - 46 Granata A, Viola G, Privitera C, Romeo G, Cacciaguerra S, Gaeta M, Sicurezza E & Figuera M. Smoking, polyuria and impaired vision. *Clinical Nephrology* 2007 **67** 49–52. (<https://doi.org/10.5414/CNP67049>)
 - 47 Grossman R, Maimon S, Levite R & Ram Z. Multimodal treatment of hemorrhagic pituitary metastasis as first manifestation of renal cell carcinoma. *World Neurosurgery* 2013 **79** 798.
 - 48 Gulsin GS, Jacobs ML, Gohil S, Thomas A & Levy M. Competing interests in a lung cancer with metastasis to the pituitary gland: syndrome of inappropriate ADH secretion versus diabetes insipidus. *Oxford Medical Case Reports* 2016 **2016** 125–129. (<https://doi.org/10.1093/omcr/omw044>)
 - 49 Gunn GB, Villa RD, Sedler RR, Hardwicke F, Fornari GA & Mark RJ. Nasopharyngeal carcinoma metastasis to the pituitary gland: a case report and literature review. *Journal of Neuro-Oncology* 2004 **68** 87–90. (<https://doi.org/10.1023/B:NEON.0000024750.93572.ce>)
 - 50 Gur C, Lalazar G, Salmon A, Dubiner V & Gross DJ. Metastatic pancreatic neuroendocrine tumor presenting as a pituitary space occupying lesion: a case report. *Pituitary* 2008 **11** 293–297. (<https://doi.org/10.1007/s11102-007-0053-7>)
 - 51 Gurling KJ, Scott GB & Baron DN. Metastases in pituitary tissue removed at hypophysectomy in women with mammary carcinoma. *British Journal of Cancer* 1957 **11** 519–522. (<https://doi.org/10.1038/bjc.1957.63>)
 - 52 Habu M, Tokimura H, Hirano H, Yasuda S, Nagatomo Y, Iwai Y, Kawagishi J, Tatewaki K, Yunoue S, Campos F, *et al.* Pituitary metastases: current practice in Japan. *Journal of Neurological Surgery* 2015 **123** 998–1007.
 - 53 Harzallah L, Migaw H, Harzallah F & Kraiem Ch. Diabetes insipidus and panhypopituitarism revealing pituitary metastasis of small cell lung carcinoma: a case report. *Annales d'Endocrinologie* 2005 **66** 117–120.
 - 54 Hayashi N, Mitsuya Harada H, Watanabe J, Nishimura T & Nakasu Y. Leptomeningeal dissemination in patients with pituitary metastasis from breast cancer. *No Shinkei Geka* 2016 **44** 371–376.
 - 55 Hermet M, Delévaux I, Trouillier S, André M, Chazal J & Aumaitre O. Pituitary metastasis presenting as diabetes insipidus: a report of four cases and literature review. *Revue de Médecine Interne* 2009 **30** 425–429.
 - 56 Hirsch D, Benbassat CA, Drozd T, Okon E & Blum I. Pituitary and bilateral adrenal enlargement: an unusual presentation of hepatocellular carcinoma. *Journal of Endocrinological Investigation* 2005 **28** 454–458. (<https://doi.org/10.1007/BF03347227>)
 - 57 Huang YY, Lin SF, Dunn P, Wai YY, Hsueh C & Tsai JS. Primary pituitary lymphoma presenting as hypophysitis. *Endocrine Journal* 2005 **52** 543–549. (<https://doi.org/10.1507/endocrj.52.543>)
 - 58 Irifune K, Hamada H, Yokoyama A, Kondo K, Kohno N, Hara Y & Hiwada K. A case of central diabetes insipidus caused by metastatic small cell lung cancer. *Nihon Kokyuki Gakkai Zasshi* 2002 **40** 154–159.
 - 59 Ismail E, Issam L & Hamid M. Pituitary metastasis of rhabdomyosarcoma: a case report and review of the literature. *Journal of Medical Case Reports* 2014 **8** 144. (<https://doi.org/10.1186/1752-1947-8-144>)
 - 60 Ithimakin S, Suttinont P & Akewanlop C. Pituitary metastasis from renal cell carcinoma: a case report with literature review. *Journal of the Medical Association of Thailand* 2013 **96** S257–S261.
 - 61 Ito I, Ishida T, Hashimoto T, Arita M, Osawa M, Yokota T & Ishimori T. Hypopituitarism due to pituitary metastasis of lung cancer: case of a 21-year-old man. *Internal Medicine* 2001 **40** 414–417. (<https://doi.org/10.2169/internalmedicine.40.414>)
 - 62 Izumi Y, Masuda T, Nabeshima S, Horimasu Y, Nakashima T, Miyamoto S, Iwamoto H, Fujitaka K, Murakami Y, Hamada H, *et al.* A case of central diabetes insipidus that was caused by pituitary metastasis of lung adenocarcinoma and was controlled by radiation therapy. *Gan to Kagaku Ryoho* 2017 **44** 513–516.

- 63 Carmichael JD. Update on the diagnosis and management of hypophysitis. *Current Opinion in Endocrinology, Diabetes and Obesity* 2012 **19** 314–321. (<https://doi.org/10.1097/MED.0b013e32835430ed>)
- 64 Jung JW, Noh G, Lee TH, Lee YY, Yi KH, Kim CH & Lee JC. Polyuria and polydipsia in a patient with non-small-cell lung cancer. *Clinical Lung Cancer* 2007 **8** 565–567. (<https://doi.org/10.3816/CLC.2007.n.044>)
- 65 Kanayama S, Matsuno A, Nagashima T & Ishida Y2005. Symptomatic pituitary metastasis of malignant thymoma. *Journal of Clinical Neuroscience* **12** 953–956. (<https://doi.org/10.1016/j.jocn.2004.11.020>)
- 66 Kano H, Niranjana A, Kondziolka D, Flickinger JC & Lunsford LD. Stereotactic radiosurgery for pituitary metastases. *Surgical Neurology* 2009 **79** 248–255.
- 67 Karamouzis MV, Melachrinou M, Fratzoglou M, Labropoulou-Karataz Ch & Kalofonos HP. Hepatocellular carcinoma metastasis in the pituitary gland: case report and review of the literature. *Journal of Neuro-Oncology* 2003 **63** 173–177. (<https://doi.org/10.1023/A:1023994604919>)
- 68 Kawamata T, Harashima S, Kubo O & Hori T. Intracellular remote metastasis from adenoid cystic carcinoma of parotid gland. *Case Report in Endocrinology Journal* 2006 **53** 659–663.
- 69 Kawamura J, Tsukamoto K, Yamakawa K, Tazima K & Tochigi H. Diabetes insipidus due to pituitary metastasis from bladder cancer. *Urologia Internationalis* 1991 **46** 217–220. (<https://doi.org/10.1159/000282139>)
- 70 Kruljac I, Cerina V, Pećina HI, Pažanin L, Matić T, Božikov V & Vrkljan M. Pituitary metastasis presenting as ischemic pituitary apoplexy following heparin-induced thrombocytopenia. *Endocrine Pathology* 2012 **23** 264–267. (<https://doi.org/10.1007/s12022-012-9224-9>)
- 71 Kurkjian C, Armor J, Kamble R, Ozer H & Kharfan-Dabaja MA. Symptomatic metastases to the pituitary infundibulum resulting from primary breast cancer. *International Journal of Clinical Oncology* 2005 **10** 191–194. (<https://doi.org/10.1007/s10147-004-0458-5>)
- 72 La Rocca G, Mattogno PP, Pompucci A, Coli A, Rigante M & Mangiola A. An extremely rare case of a single isolated pituitary metastasis from hepatocellular carcinoma. *Journal of Neurosurgical Sciences* 2017 **61** 213–215. (<https://doi.org/10.23736/S0390-5616.16.03252-5>)
- 73 Langrand-Escure J, Vallard A, Suchaud JP, Diao P & Magné N. Atypical presentation of a breast cancer pituitary metastasis. *Revue Médicale de Liege* 2016 **71** 332–335.
- 74 Lau G, Tan SY, Chiang G & Poh WT. Bronchioloalveolar carcinoma with metastasis to the pituitary gland: a case report. *Journal of Clinical Pathology* 1998 **51** 931–934. (<https://doi.org/10.1136/jcp.51.12.931>)
- 75 Leães CG, Silva L, Pereira-Lima JF, Kramer J & Oliveira MdaC. Pituitary metastasis from adenocarcinoma. *Arquivos de Neuro-Psiquiatria* 2011 **69** 845–846. (<https://doi.org/10.1590/S0004-282X2011000600026>)
- 76 Leung GK, Chow W, Tan KC, Fan YW & Lam KS. Metastatic melanoma of the pituitary gland. Case report. *Journal of Neurological Surgery* 2003 **99** 913–915.
- 77 Leys D, Lesoin F, Pasquier F, Salomez E, Ramon P, Lefebvre J & Petit H. Ophthalmologic manifestations and panhypopituitarism in a pituitary metastasis disclosing bronchial cancer. *Revue d'Otoneuro-Ophthalmologie* 1984 **56** 415–424.
- 78 Lim W, Lim D, Chng CL & Lim AY. Thyroid carcinoma with pituitary metastases: 2 case reports and literature review. *Case Reports in Endocrinology* 2015 **2015** 252157. (<https://doi.org/10.1155/2015/252157>)
- 79 Lin CY, Huang W, Chung FT & Chang HK. Prognostic factors in cancer patients with symptomatic pituitary metastasis: a clinical case study. *Anticancer Research* 2015 **35** 983–987.
- 80 Lin EY, Hsieh C, Lin CS, Tsai TH & Chiang YH. Keyhole surgery for isolated pituitary stalk metastatic tumors: a case report and review of the literature. *Minimally Invasive Neurosurgery* 2008 **51** 222–224. (<https://doi.org/10.1055/s-2008-1062742>)
- 81 Losa M, Grasso M, Giugni E, Mortini P, Acerno S & Giovanelli M. Metastatic prostatic adenocarcinoma presenting as a pituitary mass: shrinkage of the lesion and clinical improvement with medical treatment. *Prostate* 1997 **32** 241–245. ([https://doi.org/10.1002/\(SICI\)1097-0045\(19970901\)32:4<241::AID-PROS3>3.0.CO;2-M](https://doi.org/10.1002/(SICI)1097-0045(19970901)32:4<241::AID-PROS3>3.0.CO;2-M))
- 82 Luu ST, Billing K, Crompton JL, Blumbergs P, Lee AW & Chen CS. Clinicopathological correlation in pituitary gland metastasis presenting as anterior visual pathway compression. *Journal of Clinical Neuroscience* 2010 **17** 790–793. (<https://doi.org/10.1016/j.jocn.2009.09.044>)
- 83 Madronio EB & Lantion-Ang FL. The tale of two tumours: an undiagnosed case of papillary thyroid carcinoma. *BMJ Case Reports* 2011 **2011** bcr0820114604. (<https://doi.org/10.1136/bcr.2011.4604>)
- 84 Magalhães JF, Bacchin RP, Costa PS, Alves GM, Fraige Filho F & Stella LC. Breast cancer metastasis to the pituitary gland. *Arquivos Brasileiros de Endocrinologia e Metabologia* 2014 **58** 869–872. (<https://doi.org/10.1590/0004-2730000002950>)
- 85 Mansoor Q, Carey P & Adams W. A rare ophthalmic presentation of pituitary metastases. *BMJ Case Reports* 2012 **2012** bcr1120115145. (<https://doi.org/10.1136/bcr.11.2011.5145>)
- 86 Mao JF, Zhang J, Nie M, Lu SH & Wu XY. Diabetes insipidus as the first symptom caused by lung cancer metastasis to the pituitary glands: clinical presentations, diagnosis, and management. *Journal of Postgraduate Medicine* 2011 **57** 302–306. (<https://doi.org/10.4103/0022-3859.90080>)
- 87 Marmouch H, Arfa S, Mohamed SC, Slim T & Khochali I. An acute adrenal insufficiency revealing pituitary metastases of lung cancer in an elderly patient. *Pan African Medical Journal* 2016 **8** 34.
- 88 Matsuda R, Chiba E, Kawana I, Kihara M, Tomiyama M, Ebira H, Ikegami T & Kitamura H. Central diabetes insipidus caused by pituitary metastasis of lung cancer. *Internal Medicine* **34** 913–918. (<https://doi.org/10.2169/internalmedicine.34.913>)
- 89 McCormick PC, Post K, Kandji AD & Hays AP. Metastatic carcinoma to the pituitary gland. *British Journal of Neurosurgery* 1989 **3** 71–79. (<https://doi.org/10.3109/02688698909001028>)
- 90 McCutcheon IE, Waguespack S, Fuller GN & Couldwell WT. Metastatic melanoma to the pituitary gland. *Canadian Journal of Neurological Sciences* 2007 **34** 322–327. (<https://doi.org/10.1017/S0317167100006752>)
- 91 Mengoli MC, Bertolini F, Maur M, Barbieri F, Longo L, Gasparri P, Tiseo M & Rossi G. ALK-positive adenocarcinoma of the lung expressing neuroendocrine markers and presenting as a 'pituitary adenoma'. *Pathologica* 2017 **109** 408–411.
- 92 Moreno-Perez O, Peiro F, López P, Boix E, Meoro A, Serna-Candel C, Aranda FI & Picó AM. An isolated pituitary metastasis as presentation of a differentiated hepatocellular carcinoma mimicking a nonfunctioning macroadenoma. *Journal of Endocrinological Investigation* 2007 **30** 428–433. (<https://doi.org/10.1007/BF03346322>)
- 93 Nasr C, Mason A, Mayberg M, Staugaitis SM & Asa SL. Acromegaly and somatotroph hyperplasia with adenomatous transformation due to pituitary metastasis of a Growth Hormone-releasing hormone-secreting pulmonary endocrine carcinoma. *Journal of Clinical Endocrinology and Metabolism* 2006 **91** 4776–4780. (<https://doi.org/10.1210/jc.2006-0610>)
- 94 Nosedá A, Louis O, Mockel J & Yernault JC. Diabetes insipidus from metastatic oat cell carcinoma: recovery after brain irradiation. *American Journal of the Medical Sciences* 1985 **289** 27–30. (<https://doi.org/10.1097/00000441-198501000-00005>)
- 95 Ochiai H, Nakano S, Goya T, Wakisaka S & Kinoshita K. Pituitary metastasis of thyroid follicular adenocarcinoma – case report. *Neurologia Medico-Chirurgica* 1992 **32** 851–853.
- 96 Ozturk MA, Eren OO, Sarikaya B, Aslan E & Oyan B. Pituitary metastasis of colon adenocarcinoma: a rare occurrence. *Journal of*

- Gastrointestinal Cancer* 2014 **45** 85–87. (<https://doi.org/10.1007/s12029-013-9554-y>)
- 97 Pallud J, Nataf F, Roujeau T & Roux FX. Intraventricular haemorrhage from a renal cell carcinoma pituitary metastasis. *Acta Neurochirurgica* 2005 **147** 1003–1004.
- 98 Paulus P, Paridaens R, Mockel J, Coffernils M, Dhaens J, Baleriaux D, Rodesch G, Rutsaert J, Depierreux M & Flament-Durand J. Argrophilic breast carcinoma, single metastasis to the pituitary gland. *Bulletin du Cancer* 1990 **77** 377–384.
- 99 Payandeh M, Sadeghi M & Sadeghi E. The complete response to targeted drugs without surgery or radiotherapy: a case of pituitary metastasis from renal cell carcinoma. *Acta Medica Iranica* 2016 **54** 617–619.
- 100 Pelletier J, Coudurier M, Kelkel E, Frappat V & Pernot J. Pituitary metastasis revealing a lung cancer. *Revue des Maladies Respiratoires* 2015 **32** 945–948.
- 101 Piedra MP, Brown P, Carpenter PC & Link MJ. Resolution of diabetes insipidus following gamma knife surgery for a solitary metastasis to the pituitary stalk. Case report. *Journal of Neurological Surgery* 2004 **101** 1053–1056.
- 102 Poursadegh Fard M, Borhani Haghighi A & Bagheri MH. Breast cancer metastasis to pituitary infundibulum. *Iranian Journal of Medical Sciences* 2011 **36** 141–144.
- 103 Prodam F, Pagano L, Belcastro S, Golisano G, Busti A, Samà M, Caputo M, Bellone S, Voci A, Valente G, *et al.* Pituitary metastases from follicular thyroid carcinoma. *Thyroid* 2010 **20** 823–830. (<https://doi.org/10.1089/thy.2009.0256>)
- 104 Prpić M, Fröbe A, Zadavec D, Pažanin L, Jakšić B, Bolanča A & Kusić Z. Initial symptomatic pituitary metastasis in a patient with prostate foamy gland carcinoma: tailoring safe and effective therapy. *Acta Clinica Croatica* 2015 **54** 243–248.
- 105 Quevedo I, Rodriguez Portales JA, Rosenberg H & Mery J. Apoplexy in pituitary metastasis of renal cell carcinoma. Clinical case followed for 7 years. *Revista Médica de Chile* 2000 **128** 1015–1018.
- 106 Rajput R, Bhansali A, Dutta P, Gupta SK, Radotra BD & Bhadada S. Pituitary metastasis masquerading as non-functioning pituitary adenoma in a woman with adenocarcinoma lung. *Pituitary* 2006 **9** 155–157. (<https://doi.org/10.1007/s11102-006-8326-0>)
- 107 Rateau J, Rossazza C, Stecken M & Lapierre F. Pituitary metastasis of a digestive tract cancer. *Revue d'Otoneuro-Ophthalmologie* 1983 **55** 419–422.
- 108 Ratti M, Passalacqua R, Poli R, Betri E, Crispino M, Poli R & Tomasello G. Pituitary gland metastasis from rectal cancer: report of a case and literature review. *Springerplus* 2013 **2** 467. (<https://doi.org/10.1186/2193-1801-2-467>)
- 109 Ravnik J, Smigoc T, Bunc G, Lanisnik B, Ksela U, Ravnik M & Velnar T. Hypophyseal metastases: a report of three cases and literature review. *Neurologia i Neurochirurgia Polska* 2016 **50** 511–516. (<https://doi.org/10.1016/j.pjnns.2016.08.007>)
- 110 Reddy P & Kalemkerian GP. Unusual presentations of lung cancer: case 1. Diabetes insipidus as the initial manifestation of non-small-cell lung cancer. *Journal of Clinical Oncology* 2002 **20** 4597–4598. (<https://doi.org/10.1200/JCO.2002.20.23.4597>)
- 111 Weil RJ. Pituitary metastasis. *Archives of Neurology* 2002 **59** 1962–1963.
- 112 Rozen WM & Mann G. Angiosarcoma arising in an unirradiated breast with subsequent pituitary metastasis. *Clinical Breast Cancer* 2010 **7** 811–813.
- 113 Saeki N, Murai H, Kubota M & Fujimoto N. Oedema along the optic tracts due to pituitary metastasis. *British Journal of Neurosurgery* 2001 **15** 523–526. (<https://doi.org/10.1080/026886901317195482>)
- 114 Salpietro FM, Romano A, Alafaci C & Tomasello F. Pituitary metastasis from uterine cervical carcinoma: a case presenting as diabetes insipidus. *British Journal of Neurosurgery* 2000 **14** 156–159. (<https://doi.org/10.1080/02688690050004651>)
- 115 Sanguinetti CM, Marchesani F, Bichi-Secchi E, Staccioli D, Pela R & Cecarini L. Neurogenic diabetes insipidus: an unusual clinical presentation of small cell lung cancer. *Monaldi Archives for Chest Disease* 1993 **48** 130–133.
- 116 Santarpia L, Gagel R, Sherman SI, Sarlis NJ, Evans DB & Hoff AO. Diabetes insipidus and panhypopituitarism due to intrasellar metastasis from medullary thyroid cancer. *Head and Neck* 2009 **31** 419–423. (<https://doi.org/10.1002/hed.20911>)
- 117 Senetta R, Castellano I, Garbossa D, Sapino A & Cassoni P. Pituitary metastasis of an unknown neuroendocrine breast carcinoma mimicking a pituitary adenoma. *Pathology* 2013 **45** 422–424. (<https://doi.org/10.1097/PAT.0b013e328328360dfd1>)
- 118 Shah N, Cavanagh Y, Shaaban H, Stein B, Shaikh SN, Kaswala DH & Baddoura W. An unusual initial presentation of hepatocellular carcinoma as a sellar mass. *Journal of Natural Science, Biology and Medicine* 2015 **6** 471–474. (<https://doi.org/10.4103/0976-9668.160045>)
- 119 Shimon I, Hadani M, Nass D & Zwas ST. Malignant bronchial carcinoid tumor metastatic to the pituitary in a thyroid carcinoma patient: successful treatment with surgery, radiotherapy and somatostatin analog. *Pituitary* 2004 **7** 51–57. (<https://doi.org/10.1023/B:PITU.0000044627.63261.b4>)
- 120 Simmons JD, Donnellan KA, Harbarger CF, Pitman KT & Griswold R. A rare case of a 1.5 mm papillary microcarcinoma of the thyroid presenting with pituitary metastasis. *Annals of Surgery* 2010 **76** 336–338.
- 121 Sioutos P, Yen V & Arbit E. Pituitary gland metastases. 1996 *Annals of Surgical Oncology* **3** 94–99.
- 122 Siqueira PF, Mathez AL, Pedretti DB & Abucham J. Pituitary metastasis of lung neuroendocrine carcinoma: case report and literature review. *Archives of Endocrinology and Metabolism* 2015 **59** 548–553. (<https://doi.org/10.1590/2359-399700000139>)
- 123 Stojanović M, Pekić S, Doknić M, Miljić D, Cirić S, Diklić A, Tatić S, Joksimović M, Manojlović-Gačić E, Skender-Gazibara M, *et al.* What's in the image? Pituitary metastasis from papillary carcinoma of the thyroid: a case report and a comprehensive review of the literature. *European Thyroid Journal* 2013 **1** 277–284. (<https://doi.org/10.1159/000343910>)
- 124 Takei H, Buckleair L, Goodman JC & Powell SZ. Intraoperative cytologic diagnosis of symptomatic carcinoma (pulmonary small cell carcinoma) metastatic to the pituitary gland: a case report. *Acta Cytologica* 2007 **51** 637–641. (<https://doi.org/10.1159/000325816>)
- 125 Takigawa T, Matsumaru Y, Hayakawa M, Ikeda K & Matsumura A. Transarterial embolization with use of lipiodol and gelatin sponge for active nasal bleeding from hepatocellular carcinoma metastasis in the pituitary gland. *Neurologia Medico-Chirurgica* 2011 **51** 592–595.
- 126 Tamer G, Kartal I & Aral F. Pituitary infiltration by non-Hodgkin's lymphoma: a case report. *Journal of Medical Case Reports* 2009 **24** 9293.
- 127 Tamura T, Kawamura Y, Ikeda K, Seko Y, Fukushima T, Kumada H, Yamada S & Matsumaru Y. Hepatocellular carcinoma metastasis to the brain mimicking primary pituitary tumor around the sella turcica. *Clinical Journal of Gastroenterology* 2013 **6** 319–325. (<https://doi.org/10.1007/s12328-013-0384-z>)
- 128 Tanaka H, Kobayashi A, Bando M, Hosono T, Tsujita A, Yamasawa H, Ohno S, Hironaka M & Sugiyama Y. Case of small cell lung cancer complicated with diabetes insipidus and Cushing syndrome due to ectopic adrenocorticotrophic hormone secretion. *Nihon Kokyuki Gakkai Zasshi* 2007 **45** 793–798.
- 129 Tanaka T, Hiramatsu K, Nosaka T, Saito Y, Naito T, Takahashi K, Ofuji K, Matsuda H, Ohtani M, Nemoto T, *et al.* Pituitary metastasis of hepatocellular carcinoma presenting with panhypopituitarism: a case report. *BMC Cancer* 2015 **15** 863. (<https://doi.org/10.1186/s12885-015-1831-7>)
- 130 Taniguchi H, Inomata M, Abo H, Miyazawa H, Noto H & Izumi S. Central diabetes insipidus caused by pituitary metastasis of lung cancer. *Nihon Kokyuki Gakkai Zasshi* 2004 **42** 1009–1013.
- 131 Lerdlum S, Shuangshoti S, Lerdlum S, Siwanuwatn R & Sunthornyothin S. Colorectal cancer manifesting with metastasis

- to prolactinoma: report of a case involving symptoms mimicking pituitary apoplexy. *Internal Medicine* 2014 **53** 1965–1969. (<https://doi.org/10.2169/internalmedicine.53.2353>)
- 132 Tomoda Y, Kai T, Inata J, Miyazaki K, Murai H, Yamaoka N & Kuraoka T. Central diabetes insipidus caused by pituitary metastasis of lung cancer. *Nihon Kokyuki Gakkai Zasshi* 2005 **43** 751–754.
- 133 Turaka A, Parsons RB & Buyyounouski MK. Radiation therapy for pituitary metastasis: report of four cases. *Tumori* 2012 **98** e1–e6. (<https://doi.org/10.1700/1053.11520>)
- 134 Uryu K, Umakoshi T, Hyakutake T, Willard YI, Yamashita K & Harada H. Hyponatremia caused by pituitary metastasis of lung cancer. *Nihon Kokyuki Gakkai Zasshi* **49** 371–376.
- 135 Uzal MC, Kocak Z, Doganay L, Tokatli F, Caloglu M & Kilincer C. Pituitary metastasis mimicking a macroadenoma from carcinoma of the larynx: a case report. *Tumori* 2001 **87** 451–454. (<https://doi.org/10.1177/030089160108700620>)
- 136 Vianello F, Mazzarotto R, Taccaliti A, Lora O, Basso M, Servodio O, Mian C & Sotti G. Follicular thyroid carcinoma with metastases to the pituitary causing pituitary insufficiency. *Thyroid* 2011 **21** 921–925. (<https://doi.org/10.1089/thy.2010.0335>)
- 137 Wang A, Carberry N, Solli E, Kleinman G & Tandon A. Metastatic mantle cell lymphoma to the pituitary gland: case report and literature review. *Case Reports in Oncology* 2016 **9** 25–32. (<https://doi.org/10.1159/000443682>)
- 138 Wendel C, Campitiello M, Plastino F, Eid N, Hennequin L, Quélin P & Longo R. Pituitary metastasis from renal cell carcinoma: description of a case report. *American Journal of Case Reports* 2017 **18** 7–11. (<https://doi.org/10.12659/AJCR.901032>)
- 139 Yang L, Yu SY & Hu GY. Pituitary metastasis from a renal cell carcinoma progressed after sorafenib treatment. *Chinese Journal of Cancer* 2013 **32** 353–356. (<https://doi.org/10.5732/cjc.012.10184>)
- 140 Yilmaz H, Kaya M, Can M, Ozbek M & Keyik B. Metastatic prostate adenocarcinoma presenting central diabetes insipidus. *Case Reports in Medicine* 2012 **2012** 452149. (<https://doi.org/10.1155/2012/452149>)
- 141 Nomizu T, Kanno M, Watanabe T, Watanabe F, Suzuki S, Tsuchiya A, Yamaki Y, Takeda Y, Ohuchi N, Saito T, *et al.* A case of breast cancer metastatic to the pituitary gland. *Breast Cancer* 1996 **29** 71–74.
- 142 Komninos J, Vlassopoulou V, Protopapa D, Korfiatis S, Kontogeorgos G, Sakas DE & Thalassinou NC. Tumors metastatic to the pituitary gland: case report and literature review. *Journal of Clinical Endocrinology and Metabolism* 2004 **89** 574–580. (<https://doi.org/10.1210/jc.2003-030395>)
- 143 Morita A, Meyer F & Laws ER Jr 1998 Symptomatic pituitary metastases. *Journal of Neurological Surgery* **89** 69–73.
- 144 He W, Chen F, Dalm B, Kirby PA & Greenlee JD. Metastatic involvement of the pituitary gland: a systematic review with pooled individual patient data analysis. *Pituitary* 2015 **18** 159–168. (<https://doi.org/10.1007/s11102-014-0552-2>)
- 145 Park Y, Kim H, Kim EH, Suh CO & Lee S. Effective treatment of solitary pituitary metastasis with panhypopituitarism in HER2-positive breast cancer by lapatinib. *Cancer Research and Treatment* 2016 **48** 403–408. (<https://doi.org/10.4143/crt.2014.165>)
- 146 Kam J, Kam J, Mann GB, Phillips C, Wentworth JM, King J & Lindeman GJ. Solitary metastasis from HER2-positive breast cancer. *Asia Pacific Journal of Clinical Oncology* 2017 **13** E181–E184.
- 147 Peppas M, Papaxoinis G, Xiros N, Raptis SA, Economopoulos T & Haakis D. Panhypopituitarism due to metastases to the hypothalamus and the pituitary resulting from primary breast cancer: a case report and review of the literature. *Clinical Breast Cancer* 2009 **9** E4–E7. (<https://doi.org/10.3816/CBC.2009.n.047>)
- 148 Gopan T, Toms S, Prayson RA, Suh JH, Hamrahian AH & Weil RJ. Symptomatic pituitary metastases from renal cell carcinoma. *Pituitary* 2007 **10** 251–259. (<https://doi.org/10.1007/s11102-007-0047-5>)
- 149 Kramer CK, Ferreira N, Silveiro SP, Gross JL, Dora JM & Azevedo MJ. Pituitary gland metastasis from renal cell carcinoma presented as a non functioning macroadenoma. *Arquivos Brasileiros de Endocrinologia e Metabologia* 2010 **54** 498–501. (<https://doi.org/10.1590/S0004-27302010000500011>)
- 150 Czernichow P, Garel C & Léger J. Thickened pituitary stalk on magnetic resonance imaging in children with central diabetes insipidus. *Hormone Research* 2000 **53** 61–64. (<https://doi.org/10.1159/000023536>)
- 151 Fujisawa I, Uokawa K, Horii N, Murakami N, Azuma N, Furutokato S, Yamashita K, Nakao S, Kageyama N & Kageyama N. Bright pituitary stalk on MR T1-weighted image: damming up phenomenon of the neurosecretory granules. *Endocrine Journal* 2002 **49** 165–173. (<https://doi.org/10.1507/endocrj.49.165>)
- 152 Fujisawa I. Magnetic resonance imaging of the hypothalamic-neurohypophyseal system. *Journal of Neuroendocrinology* 2004 **16** 297–302. (<https://doi.org/10.1111/j.0953-8194.2004.01183.x>)
- 153 Zoli M, Mazzatenta D, Faustini-Fustini M, Pasquini E & Frank G. Pituitary metastases: role of surgery. *World Neurosurgery* 2013 **79** 327–330. (<https://doi.org/10.1016/j.wneu.2012.03.018>)
- 154 Novák V, Hrabálek L, Hampel M, Hoza J, Fryšák Z & Vaverka M. Metastatic pituitary disorders. *Klinická Onkologie* 2017 **30** 273–281.
- 155 Chen CW, Chen CY, Lee HS & Su YH. Pituitary metastasis from bronchogenic adenocarcinoma. *Journal of Medical Sciences* 2005 **25** 253–256.
- 156 Gilard V, Alexandru C, Proust F, Derrey S, Hannequin P & Langlois O. Pituitary metastasis: is there still a place for neurosurgical treatment? *Journal of Neuro-Oncology* 2016 **126** 219–224. (<https://doi.org/10.1007/s11060-015-1967-y>)

Received in final form 16 August 2018

Accepted 20 August 2018

Accepted Preprint published online 23 August 2018