



Arthroscopic-Assisted Pectoralis Minor Transfer for Irreparable Anterosuperior Massive Rotator Cuff Tear

Kotaro Yamakado, M.D., Ph.D.

Abstract: An irreparable anterosuperior massive rotator cuff tear with an irreparable subscapularis tear is not common; however, once symptomatic, it would become a challenging situation. Tendon transfer is a choice and the pectoralis major is a commonly selected graft source. However, there are theoretical concerns over its use: high invasiveness and low reproducibility, different force vector from the subscapularis, unsuitability for the arthroscopic modification, and difficulty in conversion to the reverse shoulder arthroplasty due to adhesions and scar formation in the anterior shoulder. Recently, open pectoralis minor transfer has been advocated as an alternative reconstruction option. We describe an arthroscopic-assisted technique of pectoralis minor transfer for irreparable anterosuperior massive rotator cuff tear.

An irreparable anterosuperior massive rotator cuff tear with an irreparable subscapularis tear is not common.¹ However, once symptomatic, it would become a challenging situation. Treatment options depend on the symptoms, patient age, and presence of glenohumeral osteoarthritis. Tendon transfer is a choice and the pectoralis major is a commonly selected graft source.¹⁻⁴ However, the reported outcomes of pectoralis major transfer are varied.¹⁻⁴ Most favorable results could be expected with isolated subscapularis tears. On the other hand, anticipated outcome is less optimal in the setting of massive rotator cuff tears. The transfer is more likely to fail in cases of irreparable supraspinatus or infraspinatus tears. Failed transfers may be revised with the use of the reverse shoulder prosthesis. However, resultant adhesions on the anterior or anteroinferior part of the shoulder are problems for implantation.⁵ From biomechanical and anatomical viewpoints, the pectoralis major muscle originates

anterior to the chest wall and the subscapularis runs behind the chest wall. Thus, the transferred course of the pectoralis major is different from the force vector of the subscapularis. Some researchers have proposed a subcoracoid transfer route for simulating the natural pull of the subscapularis.⁶⁻¹⁰ However, loss of power transduction at the conjoined tendon pulley is inevitable.

Pectoralis minor had been reported as a graft source for the serratus anterior palsy, acromioclavicular reconstruction, glenohumeral instability, and irreparable subscapularis sporadically.¹¹⁻¹⁵ Recently, Paladini et al.¹⁵ reported on the technical feasibility, safety, and promising outcomes of an open pectoralis minor transfer in patients with a Lafosse¹⁶ type 3 irreparable subscapularis tear. They concluded that subcoracoid transfer of the pectoralis minor is an effective procedure, as the thin pectoralis minor muscle passes easily under the coracoid and the force vector produced by this transfer improves shoulder function and provides pain relief.

We describe an arthroscopic modification of the pectoralis minor transfer for irreparable anterosuperior massive rotator cuff tears (Fig 1, Video 1) with Lafosse type 3 and 4 irreparable subscapularis tears, and investigate a short-term clinical result. We hypothesized that the arthroscopic-assisted pectoralis minor transfer would result in improved shoulder function in patients with irreparable anterosuperior massive rotator cuff tears.

Technique

Arthroscopic-assisted pectoralis minor transfer is indicated if: (1) patients had pain with irreparable subscapularis and supraspinatus tears with or without infraspinatus tears after an unsuccessful minimum

From the Department of Orthopaedics, Fukui General Hospital, Fukui, Japan.

The author reports that he has no conflicts of interest in the authorship and publication of this article. Full ICMJE author disclosure forms are available for this article online, as [supplementary material](#).

Received June 30, 2017; accepted August 11, 2017.

Address correspondence to Kotaro Yamakado, M.D., Ph.D., Department of Orthopaedics, Fukui General Hospital, 58-16-1 Egami, Fukui 9108561, Japan. E-mail: yamakadok@gmail.com

© 2017 by the Arthroscopy Association of North America. Published by Elsevier. This is an open access article under the CC BY-NC-ND license (<http://creativecommons.org/licenses/by-nc-nd/4.0/>).

2212-6287/17814

<https://doi.org/10.1016/j.eats.2017.08.070>

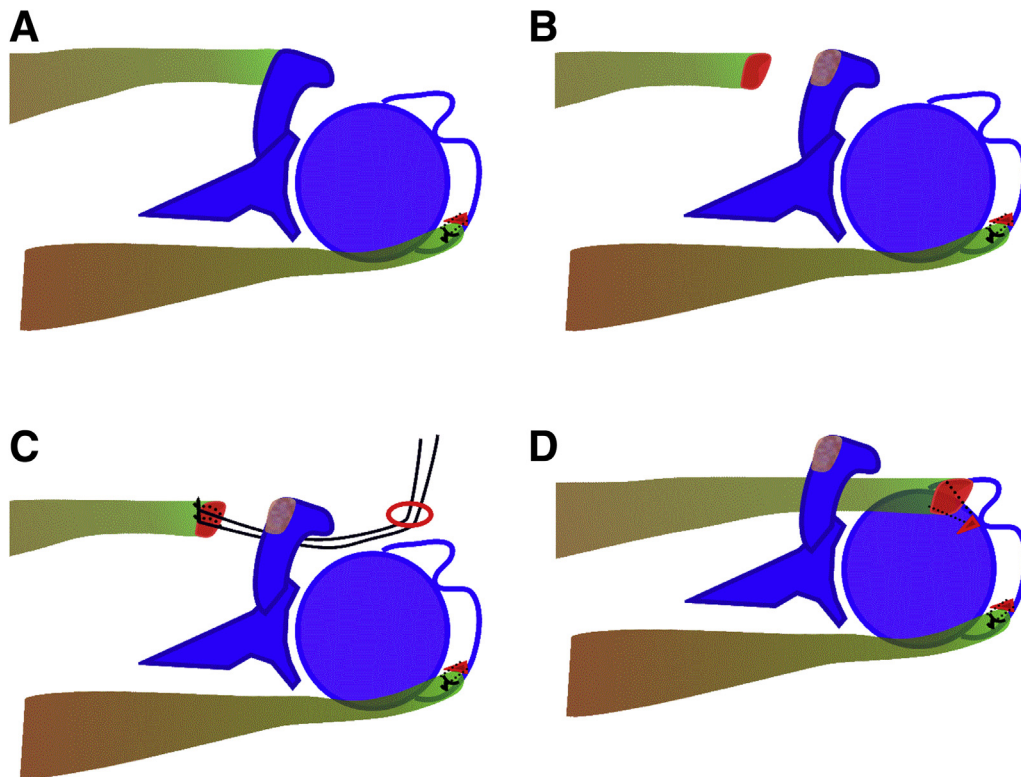


Fig 1. Key surgical steps. (A) Before the tendon transfer, the posterior torn cuff is repaired (partially repaired). To reduce tension of the repair construct, the footprint of the cuff is medialized. (B) Using a narrow bone chisel, the pectoralis minor tendon is released with a flake of bone tip from the medial side of the coracoid. (C) Leading sutures are passed around the tendon-bone junction in the simple stitch configuration and tied. The leading sutures are retrieved from the space behind the coracoid process to the anterolateral portal. (D) The pectoralis minor tendon graft is fixed to the lesser tuberosity using a knotless anchor.

3 months of conservative treatment (consisting of anti-inflammatory medications, physical therapy, and activity modification), (2) the supraspinatus tendon retracted medial to the glenoid on the magnetic resonance imaging coronal view and could not be fixed to the greater tuberosity without marked tension during the operation, (3) the torn subscapularis retracted medially and could not be fixed to the lesser tuberosity without marked tension after the arthroscopic mobilization, and (4) they suffered a recurrent tear after the initial subscapularis repair. Contraindications are: (1) an irreparable subscapularis tear with humeral head subluxation anteriorly or superiorly (Lafosse¹⁶ type 5 cases),

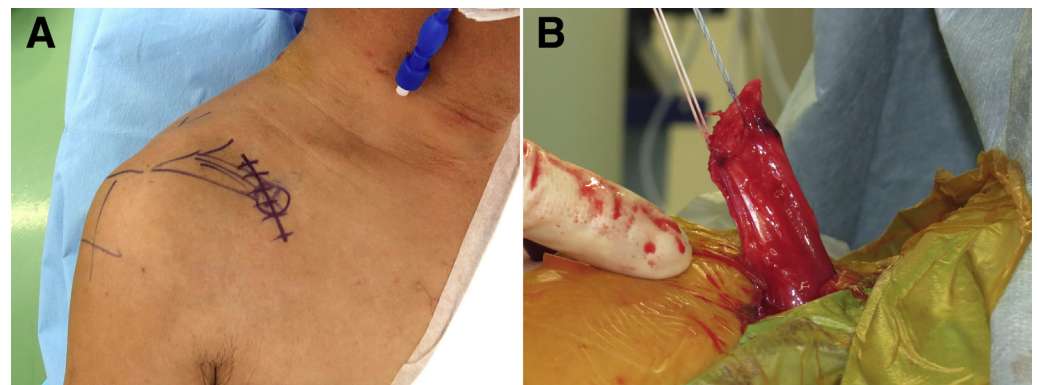
(2) advanced osteoarthritis with superior migration of the humeral head (stage 4 or 5 in the Hamada classification¹⁷), (3) a severe contracture of the shoulder joint with a passive flexion/abduction less than 70°, (4) a permanent axillary nerve palsy, (5) severe deltoid dysfunction, and (6) patients with instability.

Surgical Technique

Positioning and Partial Repair of the Cuff

The patient is placed in the beach chair position with the arm held in flexion and 1 to 3 kg of longitudinal traction in accordance with the patient's body weight

Fig 2. The operative shoulder (right) is widely draped, allowing for free access medial to the coracoid process. (A) A 3- to 4-cm skin incision is made over the coracoid process. (B) The pectoralis minor tendon is harvested with a flake of bone tip. Leading sutures are passed around the tendon-bone junction in the simple stitch configuration and tied.



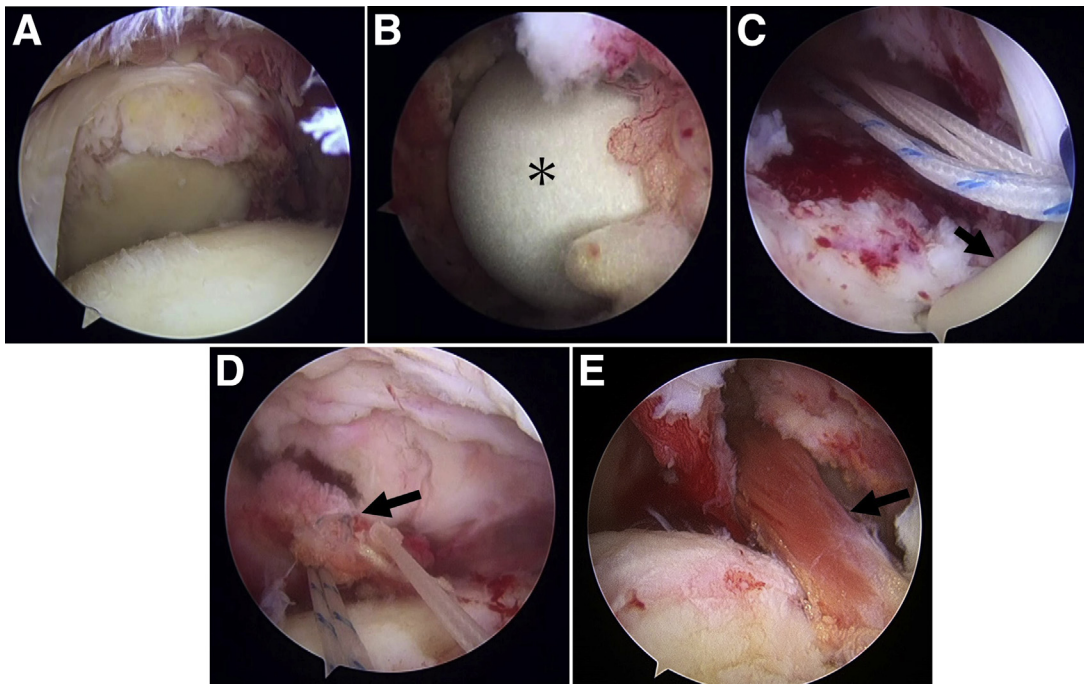


Fig 3. The right shoulder viewing from the lateral portal. The patient is placed in the beach chair position. (A) Right shoulder, viewing from the lateral portal. (B) The intra-articular finger sign. The surgeon's finger is inserted from the incision behind the coracoid process to develop the passage pathway. If the passage pathway of the tendon is well prepared, the groove of the fingertip could be visualized well arthroscopically from the joint. *The surgeon's fingertip. (C) Leading sutures are set to the knotless anchor and pulled from the anterolateral portal. Arrow, a knotless anchor placed at the bicipital groove. (D). The leading edge of the pectoralis minor tendon. Leading sutures are tied around the tendon-bone junction. Arrow, the end of the transferred pectoralis minor graft. (E) The transferred pectoralis minor tendon fixed to the lesser tuberosity. Arrow, muscle belly of the transferred pectoralis minor.

(Figs 1-4, Video 1, Tables 1 and 2). The shoulder is widely draped, allowing for free access medial to the coracoid process. The superficial anatomy of the shoulder is identified, and the skin is marked to outline the clavicle, acromion, scapular spine, coracoid process, and lateral border of the scapula (Fig 2). Routine arthroscopy portals are used (posterior, lateral, anterior, and anterolateral), and diagnostic arthroscopy using a 30° arthroscope is initiated with the use of a standard posterior portal. The viewing portal is subsequently changed to a lateral portal (midway between the anterolateral and posterolateral acromial corners) (Fig 3A).

Step 1: Mobility of the torn subscapularis is examined using a suture retriever from the anterosuperior working portal.

Step 2: If the long head of the biceps is present, tenotomy or tenodesis of the long head of the biceps is recommended before tendon repair. When tenodesis is performed, our preference is for subpectoral mini-open tenodesis using a spike washer.

Step 3: Then, the subscapularis is fixed using a suture anchor placed medially in the footprint to reduce tension. In the case of a retracted subscapularis tear with low mobility, repair is not attempted. If the robust

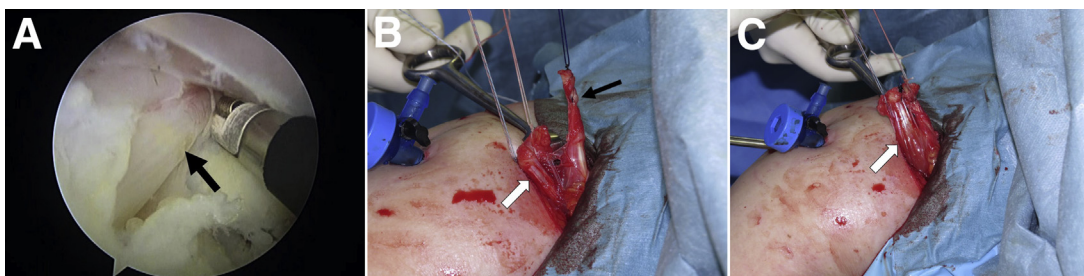

Fig 4. A case with an ectopic insertion of the pectoralis minor in the right shoulder. (A) An ectopic insertion to the supraspinatus (→). (B) The aberrant tendon slip (←) and main part of the pectoralis minor (⇄). (C) The aberrant tendon slip is tied to the released bone tip of the main tendon part using the strong suture (⇄). The composite of the main part and fixed-aberrant tendon is secured to the lesser tuberosity as a unit.

Table 1. Key Steps in Arthroscopic-Assisted Pectoralis Minor Transfer

1. Evaluation and partial repair of the posterior rotator cuff (supraspinatus and/or infraspinatus)
2. Tendon harvesting from the anterior mini-incision to protect the neurovascular structures behind the coracoid process
3. Coracoidplasty and finger dissection behind the coracoid area (the “intra-articular finger sign”) to assure the space where the tendon would pass
4. Careful fixation of the leading sutures using a knotless anchor to the bicipital groove

tendon is well secured with low tension, the pectoralis minor tendon transfer is not indicated.

Step 4: Mobility of the torn posterior rotator cuff is assessed and the torn supraspinatus (and infraspinatus, if it is torn) is repaired. In the case of a retracted supraspinatus tear beyond the glenoid rim with low mobility, repair is not attempted.

Preparation of the Tendon Passage Route and Harvesting the Pectoralis Minor

Coracoplasty is performed to assure the space where the tendon would pass. Two to three millimeters of bone from the backside of the coracoid is removed with the burr. The inferior surface of the coracoid from the neck to the tip is skeletonized with an arthroscopic cautery device (VAPR; DePuy Synthes, Warsaw, IN). Then, arthroscopy is suspended and mini-open tendon preparation is performed (Video 1). A 3- to 4-cm skin incision is made over the coracoid process and the deltopectoral interval is developed (Fig 2A). The coracoid process is exposed from its tip to the insertion of the coracoclavicular ligaments at the base of the coracoid, and the pectoralis minor tendon insertion on the medial side of the coracoid is visualized. Using a 4-mm bone chisel, the pectoralis minor tendon is released with a flake of bone tip from the medial side of the coracoid (Figs 1B and 2B). At this step, the chisel is tapped on the anterior cortex 3 mm lateral to the medial margin from proximal to distal on the coracoid process where the pectoralis minor is inserted. Then, the chisel is inserted into the created slit and levered up to complete the osteotomy. Once the pectoralis minor tendon is released with a small bone tip, 2 to 3 strong sutures (Hi-Fi suture; ConMed Linvatec, Largo, FL) are passed around the tendon-bone junction in the simple stitch configuration and tied. By pulling sutures, the tendon is mobilized. If sufficient mobility is not obtained, the most inferior slip of the tendon is released, which is tensioned and acted as a check rein. Then, the surgeon’s middle finger is inserted from the incision behind the coracoid process (Fig 3B). Arthroscopy is resumed, and viewing from the lateral portal, the backside of the coracoid is dissected using the surgeon’s finger. If the passage pathway of the tendon is well prepared, the glove of the fingertip could be

visualized well arthroscopically from the joint. It is called the “intra-articular finger sign.”

Arthroscopic Fixation of the Pectoralis Minor Tendon

A prebent malleable slot-shaped cannula (Malleable Retractor; DePuy Mitek, Raynham, MA) is bent to a J-shape to fit around the coracoid process from the incision and is inserted into the glenohumeral joint while sliding the cannula on the backside of the coracoid to protect the brachial plexus and neurovascular structures during graft introduction. This step is also monitored by arthroscopy. A silicone Penrose drain is inserted from the incision sliding on the slot cannula and is advanced into the joint space behind the coracoid. Then, the drain is retrieved with a suture retriever to the anterolateral working portal. Leading sutures are tied to the Penrose drain, and the graft is dragged into the joint by pulling the drain from the anterolateral portal. The leading suture is set into the Versalok anchor (Depuy Synthes), and the anchor is inserted to the bicipital groove (if present) or anterolateral part of the humeral head if the groove is not present, especially in chronic cases (Figs 1D and 2C-E). The leading sutures are tied to each other on the anchor after suture crimping. If the bone is not strong, the suture tails are not cut, and are set into the second Versalok anchor, which is secured laterally, 1 cm away from the first anchor (the “series circuit” configuration) for backup.

The Situation With an Ectopic Insertion of the Pectoralis Minor Tendon

In a few cases, the pectoralis minor tendon has an ectopic insertion where an abnormal tendon part runs over the coracoid and is inserted to the supraspinatus or coracohumeral ligament¹⁸⁻²³ (Fig 4). The prevalence of this ectopic insertion has been reported in 10% to 16% cases.¹⁸⁻²³ In this particular subgroup, the majority of

Table 2. Pearls and Pitfalls of Arthroscopic-Assisted Pectoralis Minor Transfer

Pearls	Pitfalls
Do not complete the osteotomy of the coracoid with the sharp instruments. Lever up the chisel that is tapped into the slot created on the anterior cortex	Neurovascular injury behind the coracoid process
Coracoplasty and soft-tissue dissection using the surgeon’s finger behind the coracoid process facilitates the graft passage	Less mobility of the harvested pectoralis minor tendon
Use of a prebent malleable slot-shaped cannula to protect neurovascular structures posteromedial to the coracoid process during the graft passage	Aberrant anatomy of the pectoralis minor tendon

Table 3. Advantages and Disadvantages of Arthroscopic-Assisted Pectoralis Minor Transfer

Advantages	Disadvantages
Minimum invasive arthroscopic-assisted approach	Small muscle volume compared with the pectoralis major
Bone-to-bone healing and preserving the tendon-bone junction	Technically demanding procedure requiring advanced shoulder arthroscopic and open skills
More similar force vector of the subscapularis compared with the pectoralis major	No proven long-term clinical outcome studies

the pectoralis tendon is inserted to the medial margin of the coracoid. The aberrant tendon slip is released arthroscopically from its insertion and secured to the released bone tip using the strong suture (No. 2 Hi-Fi suture). The composite of the main part and fixed-aberrant tendon is secured to the lesser tuberosity as a unit.

Postoperative Care

Patients were immobilized with an abduction pillow for 6 weeks (SlingShot 3; Breg, Carlsbad, CA). Passive shoulder range-of-motion exercise was started postoperatively. Strengthening exercises were started at 12 weeks postoperatively.

Discussion

To convert a painful irreparable cuff tear into a biomechanically stable shoulder, a tendon transfer functions in 3 ways²⁴: (1) by rebalancing the force couples on the axial, coronal, and sagittal planes; (2) by soft tissue interposition between the acromion/coracoid and humeral head (the “spacer effect”); and (3) by recreating a stable fulcrum by lowering the humeral head (the “tenodesis effect”). Transferred pectoralis minor was expected to have a spacer effect, and to act as a depressor and counterpart of the posterior cuff muscles (infraspinatus and teres minor).

The advantages of using the pectoralis minor tendon over the pectoralis major tendon were less donor site morbidity, biomechanical superiority, and arthroscopic feasibility (Table 3). First, although the pectoralis minor tendon was frequently released during a Latarjet procedure during the instability surgery, complications related to release were not reported.^{25,26} Second, the line of pull of the pectoralis minor was more similar to that of the subscapularis compared with the pectoralis major. Harvesting with a flake of bone at the tendon insertion on the coracoid preserved the bone-tendon junction and allowed bone-to-bone healing. Finally, harvesting the pectoralis major tendon requires a large incision, and dissection along the deltopectoral interval precludes arthroscopic modification; however, a pectoralis minor tendon transfer could be attained as shown in this study. A theoretical concern of using the pectoralis minor muscle

was the small muscle volume. However, Gausden et al.²⁷ simulated anterosuperior rotator cuff tears and found that the superior half of the subscapularis significantly altered shoulder biomechanics and led to increased anterosuperior and superior glenohumeral translation, demonstrating that the superior part is more important than the inferior part. The course of the pectoralis minor tendon transfer simulated that of the superior part of the subscapularis and may have attained sufficient substitution of the function of the subscapularis.

Arthroscopic-assisted pectoralis minor tendon transfer can lead to significant improvements in overall shoulder pain and function, and appears to be an attractive choice in the treatment of young patients with limited reconstruction options.

References

1. Axe JM. Tendon transfers for irreparable rotator cuff tears: An update. *EFORT Open Rev* 2016;1:18-24.
2. Nelson GN, Namdari S, Galatz L, Keener JD. Pectoralis major tendon transfer for irreparable subscapularis tears. *J Shoulder Elbow Surg* 2014;23:909-918.
3. Shin JJ, Saccomanno MF, Cole BJ, Romeo AA, Nicholson GP, Verma NN. Pectoralis major transfer for treatment of irreparable subscapularis tear: A systematic review. *Knee Surg Sports Traumatol Arthrosc* 2016;24:1951-1960.
4. Moroder P, Schulz E, Mitterer M, Plachel F, Resch H, Lederer S. Long-term outcome after pectoralis major transfer for irreparable anterosuperior rotator cuff tears. *J Bone Joint Surg Am* 2017;99:239-245.
5. Ortmaier R, Plachel F, Lederer S, et al. Reverse shoulder arthroplasty after failed pectoralis major tendon transfer with a minimum follow-up of 5 years. A case series. *J Orthop Sci* 2016;21:591-595.
6. Galatz LM, Connor PM, Calfee RP, Hsu JC, Yamaguchi K. Pectoralis major transfer for anterior-superior subluxation in massive rotator cuff insufficiency. *J Shoulder Elbow Surg* 2003;12:1-5.
7. Gavriilidis I, Kircher J, Magosch P, Lichtenberg S, Habermeyer P. Pectoralis major transfer for the treatment of irreparable anterosuperior rotator cuff tears. *Int Orthop* 2010;34:689-694.
8. Hackl W, Wambacher M, Kralinger F, Smekal V. Pectoralis major transfer in the treatment of chronic subscapularis insufficiency. *Oper Orthop Traumatol* 2007;19:433-441 [in German].
9. Lanz U, Fullick R, Bongiorno V, Saintmard B, Campens C, Lafosse L. Arthroscopic repair of large subscapularis tendon tears: 2- to 4-year clinical and radiographic outcomes. *Arthroscopy* 2013;29:1471-1478.
10. Resch H, Povacz P, Ritter E, Matschi W. Transfer of the pectoralis major muscle for the treatment of irreparable rupture of the subscapularis tendon. *J Bone Joint Surg Am* 2000;82:372-382.
11. Chaves JP. Pectoralis minor transplant for paralysis of the serratus anterior. *J Bone Joint Surg Br* 1951;33:228-230.
12. Dickson JA, O'Dell HW. A phylogenetic study of recurrent anterior dislocation of the shoulder joint. *Surg Gynecol Obstet* 1952;95:357-365.

13. Wirth MA, Rockwood CA Jr. Operative treatment of irreparable rupture of the subscapularis. *J Bone Joint Surg Am* 1997;79:722-731.
14. Moinfar AR, Murthi AM. Anatomy of the pectoralis minor tendon and its use in acromioclavicular joint reconstruction. *J Shoulder Elbow Surg* 2007;16:339-346.
15. Paladini P, Campi F, Merolla G, Pellegrini A, Porcellini G. Pectoralis minor tendon transfer for irreparable anterosuperior cuff tears. *J Shoulder Elbow Surg* 2013;22:e1-e5.
16. Lafosse L, Jost B, Reiland Y, Audebert S, Toussaint B, Gobezie R. Structural integrity and clinical outcomes after arthroscopic repair of isolated subscapularis tears. *J Bone Joint Surg Am* 2007;89:1184-1193.
17. Hamada K, Fukuda H, Mikasa M, Kobayashi Y. Roentgenographic findings in massive rotator cuff tears. A long term observation. *Clin Orthop Relat Res* 1990;254:92-96.
18. Weinstabl R, Hertz H, Firbas W. Connection of the ligamentum coracoglenoidale with the muscular pectoralis minor. *Acta Anat (Basel)* 1986;125:126-131 [in German].
19. Homsy C, Rodrigues MB, Silva JJ, Stump X, Morvan G. Anomalous insertion of the pectoralis minor muscle: Ultrasound findings. *J Radiol* 2003;84:1007-1011 [in French].
20. Moineau G, Cikes A, Trojani C, Boileau P. Ectopic insertion of the pectoralis minor: Implication in the arthroscopic treatment of shoulder stiffness. *Knee Surg Sports Traumatol Arthrosc* 2008;16:869-871.
21. Low SC, Tan SC. Ectopic insertion of the pectoralis minor muscle with tendinosis as a cause of shoulder pain and clicking. *Clin Radiol* 2010;65:254-256.
22. Yoo JC, Lim TK, Koh KH, Park WH. Arthroscopic perspective of the tendinous insertion of the pectoralis minor and correlation with MRI: A case report. *J Shoulder Elbow Surg* 2010;19:e19-e23.
23. Dwivedi AK, Airan N, Das AR. An unusual variation of pectoralis minor muscle and its clinical significance. *Int J Biomed Res* 2016;7:613-618.
24. Yamakado K. Clinical and radiographic outcomes with assessment of the learning curve in arthroscopically-assisted latissimus dorsi tendon transfer for irreparable posterosuperior rotator cuff tears. *Arthroscopy* 2018;34:1151-1155.
25. Rollick NC, Ono Y, Kurji HM, et al. Long-term outcomes of the Bankart and Latarjet repairs: A systematic review. *Open Access J Sports Med* 2017;8:97-105.
26. Gartsman GM, Waggenspack WN Jr, O'Connor DP, Elkousy HA, Edwards TB. Immediate and early complications of the open Latarjet procedure: A retrospective review of a large consecutive case series. *J Shoulder Elbow Surg* 2017;26:68-72.
27. Gausden EB, McCarthy MM, Kontaxis A, Corpus KT, Gulotta LV, Kelly AM. Subscapularis tendon loading during activities of daily living. *J Shoulder Elbow Surg* 2017;26:331-336.