


RESEARCH ARTICLE

Open Access



# Mid-term results of a new femoral prosthesis using Ti-Nb-Sn alloy with low Young's modulus

Daisuke Chiba<sup>1</sup>, Norikazu Yamada<sup>2</sup>, Yu Mori<sup>1\*</sup> , Masamizu Oyama<sup>2</sup>, Susumu Ohtsu<sup>3</sup>, Yoshiyuki Kuwahara<sup>1</sup>, Kazuyoshi Baba<sup>1</sup>, Hidetatsu Tanaka<sup>2</sup>, Toshimi Aizawa<sup>1</sup>, Shuji Hanada<sup>4</sup> and Eiji Itoi<sup>1</sup>

## Abstract

**Background:** This study was performed to investigate the mid-term results of Ti-Nb-Sn (TNS) alloy stem with a low Young's modulus.

**Methods:** This study was a multicenter prospective cohort study. A total of 40 primary total hip arthroplasties performed between April 2016 and September 2017 was enrolled in this study. With the unique functional gradient properties by heating treatment, the strength of the proximal portion was enhanced, while the distal portion maintained a low Young's modulus. The surgeries were performed through the posterolateral approach using the TNS alloy stems. Radiographs were taken from immediately after surgeries until 3 years, and stress shielding and subsidence of the stems were evaluated. The incidences of the stem breakage were also assessed. Clinical assessments were performed using Japanese Orthopaedic Association (JOA) and Japanese Orthopaedic Association Hip Disease Evaluation Questionnaire (JHEQ) scores.

**Results:** Among the 40 enrolled patients, 36 patients were female and 4 were male. At 3 years after surgery, there were no radiologic signs of loosening, subsidence, or breakage of the stem. Stress shielding was observed in 26 hips (65%). Of 26 hips, 16 hips (40%) were grade 1 and 10 hips (25%) were grade 2. There was no advanced stress shielding. The JOA and JHEQ scores significantly improved compared with the preoperative scores.

**Conclusion:** The current study using a new TNS alloy femoral stem showed good clinical outcomes at 3-year follow-up. Radiologically, there was no loosening or subsidence of the stem. The mild stress shielding was observed in 65% of patients.

**Trial registration:** Current Controlled Trials [ISRCTN21241251](https://www.clinicaltrials.gov/ct2/show/study?term=ISRCTN21241251).

The date of registration was October 26, 2021.

Retrospectively registered.

**Keywords:** Total hip Arthroplasty, Low Young's modulus, Stress shielding, Ti-Nb-Sn alloy;  $\beta$  type titanium alloy

## Background

The good long-term results of total hip arthroplasty (THA) have been reported in patients with hip osteoarthritis. Previous long term follow-up studies demonstrated that the improvements of hip pain, functions and quality of life were achieved by THA [1, 2]. Furthermore, the long-term results of cementless femoral stem have demonstrated favorable results in clinical and radiological assessments, same as cemented femoral stem.

\*Correspondence: [yu-mori@med.tohoku.ac.jp](mailto:yu-mori@med.tohoku.ac.jp)

<sup>1</sup> Department of Orthopaedic Surgery, Tohoku University Graduate School of Medicine, 1-1 Seiryō-machi, Aoba-ku, Sendai, Miyagi 980-8574, Japan

Full list of author information is available at the end of the article



Therefore, THA with cementless stem has prevailed worldwide [3–7].

However, there are still several issues to be solved in THA with cementless stem. One of the major problems is the stress shielding due to inadequate load-stress distribution. Stress shielding refers to the bone atrophy and loss of bone density as results of load stress being removed from the bone by the femoral stem [8, 9]. The bone atrophy and loss of bone mineral density by the stress shielding increase the risk of periprosthetic fracture [10, 11]. As the number of THA performed in elderly patients with osteoporosis has been increasing, the prevention of periprosthetic fracture is a very important issue. The etiology of stress shielding is considered multifactorial such as surface texture, geometry, and stiffness of the stem [12]. Currently, femoral stems are made with Ti-6Al-4V alloy with a Young's modulus of 110 GPa and a tensile strength to 860 MPa. Ti-6Al-4V alloy has a good biocompatibility and resistance to corrosion. In contrast, the Young's modulus of the human cortical bone ranges between 10 GPa and 30 GPa [13]. This mismatch of elasticities between the femoral stem and the cortical bone is considered one of the major causes of stress shielding.

To solve the mismatch of elasticity between the stem and the bone, the Robert Mathys (RM) isoelastic stem was developed as a low elastic stem to avoid stress shielding [14–16]. However, the results of isoelastic RM stem were demonstrated to be unacceptably poor. The deficiency of primary fixation was believed to be the main reason for the high failure rate [17]. In contrast, Hanada et al. developed a new  $\beta$  type titanium alloy, Ti-33.6% Nb-4% Sn (TNS) alloy with the Young's modulus as low as 40 GPa. Not only the low Young's modulus, but also the modifiability of material properties by heat are the great assets of the TNS alloy. The researchers developed a new cementless stem of TNS alloy with the functional gradient properties of Young's modulus and strength by heating treatment [18]. Furthermore, the safety and biocompatibility were demonstrated in the previous studies [18, 19]. TNS alloy stem with high strength in the proximal part and low Young's modulus in the distal part are considered ideal for the prevention of fatigue failure and stress shielding.

The authors hypothesized that a TNS alloy stem with functional gradient properties of Young's modulus and strength could prevent the stress-shielding problem and improve the postoperative outcome of cementless THA. The purpose of this study was to investigate the mid-term results of TNS alloy stem.

## Methods

### Patients

The study was a multicenter, open-label, single-arm clinical trial. The approval of Clinical Research Ethics Committee of Tohoku University Hospital was obtained before the initiation of this study (Approval number: #201506–1). From April 2016 to September 2017, a total of 425 total hip arthroplasties were performed at our institutions, and 40 primary total hip arthroplasties using the TNS alloy stem were performed. These 40 patients were enrolled in this study. The inclusion criteria for this study were patients over 20 years of age who had a pre-operative diagnosis of osteoarthritis, avascular necrosis, or rheumatoid arthritis, and consent to participate in the study. Patients who did not wish to participate in the clinical study did not undergo total hip arthroplasties with TNS alloy stems. The exclusion criteria were previous operation (total hip arthroplasty, osteotomy, tenotomy around hip joint), bilateral hip disorder, rheumatoid arthritis of Charnley category C (multiple joint disease or other disease limiting mobility) [20], past history of deep venous thrombosis or pulmonary embolism, metal allergy, severe obesity (Body Mass Index  $> 35.0 \text{ kg/m}^2$ ), severe diabetes mellitus, and infection around hip joint. The surgical cases with TNS femoral stems were selected based on the choices and consent of patients who met the inclusion criteria. In our institutes, total hip arthroplasties with antero-lateral supine hip approach using short-designed stems were mainly performed. There were few cases operated with posterolateral hip approach using conventional metaphyseal filling type stems of Ti-6Al-4V alloy in the study period. Therefore, the control cases were not able to be established in this study.

### Characteristics of a new TNS alloy stem

TNS alloy is a new material with a low Young's modulus of 40 GPa [18]. TNS alloy has characteristics that the Young's modulus and strength can be modified by heating treatment and a low thermal conductivity. The fabrication of the TNS alloy stem and the changes of Young's modulus and tensile strength of the TNS alloy stem with heat treatment have been described in previous studies in detail, and the TNS alloy stem used in this study was fabricated according to the method reported in a previous study [18, 21, 22]. As briefly described, when stem neck was heated locally, it made the temperature gradation, high temperature in the proximal and low temperature in the distal portions of the stem. Thereby local heat treatment at stem neck at 673 K for 5 h increased its Young's modulus and strength in proximal part resulted in a gradual decrease in the Young's modulus from the proximal

to the distal end. The authors made a high-performance stem from the TNS alloy with high strength in the proximal part and low Young’s modulus in the distal part of the stem. Figure 1A shows the appearance of the TNS alloy stem. The TNS alloy stem is cementless tapered proximal fixation stem. According to the classification of Khanuja [23], it is classified as double wedge metaphyseal filling stem. Over the proximal one third of the stem, there is a circumferential rough surface by sandblasting. The surface of distal two third is polished. Vickers hardness has been reported to be correlated with Young’s modulus [24]. Figure 1B shows the temperature gradient and Vickers hardness measurements after 5 h of heat treatment at stem neck at 673K. The white circles show the actual measured values at each site, where the temperature change of the TNS alloy stem due to heat treatment was measured from proximal to distal. Color mapping of the stem is shown for Vickers hardness distribution. The black circles show the measured Vickers hardness values reflecting the change in Young’s modulus after heat treatment at each site. The neck part of the TNS alloy stem had sufficient strength of more than 250 hardness of Vickers (HV). In contrast, the temperature was 344K in the distal part of TNS alloy stem due to the gradient function property. There was no increase in Vickers hardness in the distal portion of the TNS alloy stem than the neck where the temperature was kept below 500K. The

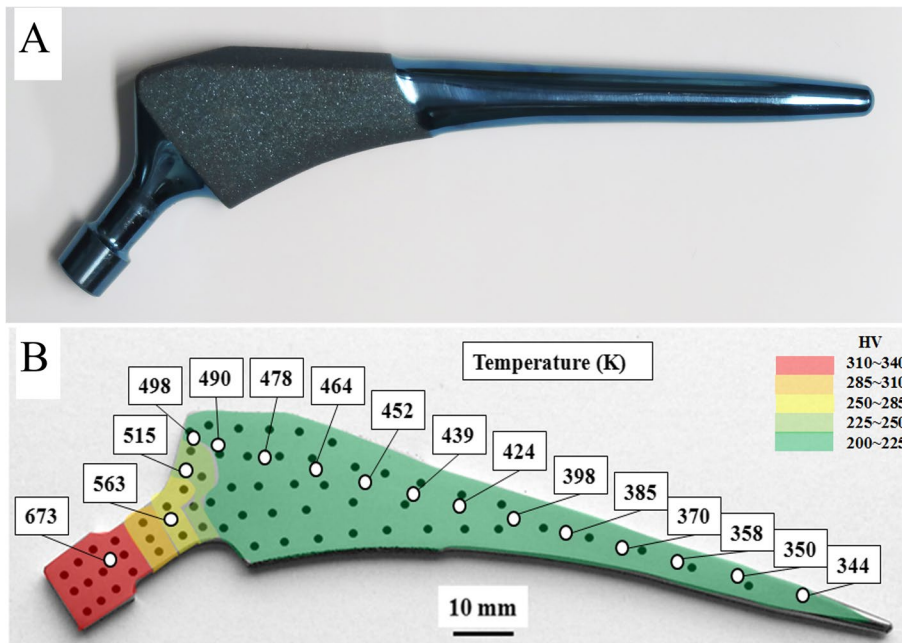
TNS alloy stem was manufactured and provided by Mizuho Co. Tokyo, Japan. The cost of the clinical trials was covered by Mizuho Co. Tokyo, Japan.

**Surgery and rehabilitation**

All surgeries were performed at three institutions by 6 orthopaedic surgeons through the posterolateral hip approach. The femur was scraped with a hand-powered reamer and a broach. The TNS alloy stem was inserted with the press-fit technique. As acetabular component, ARC HA cup (Mizuho Co., Tokyo, Japan) was used in all patients. All the patients were allowed to begin full weight bearing with use of an assistive device on the first postoperative day.

**Radiographical evaluation**

Anteroposterior radiographs of bilateral hips and lateral radiographs of affected hip with calibration measure were taken before the surgery, immediately after the surgery, at 3 weeks, 6 weeks, 3 months, 6 months, 1 year, and 3 years postoperatively. The incidences of stress shielding were assessed with radiographs at 3 years using the classification of Engh [25]. Stem subsidence was defined as the inferior migration of the stem by more than 2mm from the initial postoperative radiograph. Stem subsidence was evaluated at every time point. Also, the stem breakage was assessed on radiographs at every follow-up.



**Fig. 1** A Photograph of TNS alloy stem. B Schematic model of the low thermal conductivity and Vickers hardness of TNS alloys. The white circles show the actual measured values at each site, where the temperature (K) of the TNS alloy stem due to heat treatment. Color mapping of the stem is shown for Vickers hardness (HV) distribution. The black circles show the measured Vickers hardness at each site. HV: Hardness of Vickers

Radiological assessment of stress shielding, subsidence, and breakage of the stem was performed by two independent orthopaedic surgeons.

### Clinical assessment

The Japanese Orthopaedic Association (JOA) hip scores were used to assess the clinical outcomes before the surgery, 6 weeks, 3 months, 6 months, and 1 year postoperatively. The JOA hip score is a 100-point scale that comprises the subcategories of pain (Pain: 40 points), range of motion (ROM: 20 points), ability to walk (Gait: 20 points) and activities of daily living (ADL: 20 points) [26]. To assess the patient-reported outcome measures, the Japanese Orthopaedic Association Hip Disease Evaluation Questionnaire (JHEQ) was used before the surgery, 3 months, 6 months, and 1 year postoperatively. The JHEQ consists of pain (28 points), movement (28 points) and mental (28 points) subscales, with 84 points being the best outcome [27].

### Statistical analysis

All results were expressed as the mean  $\pm$  standard deviation. For the evaluation of the differences between the preoperative and postoperative JOA hip scores and JHEQ scores, Bonferroni correction and Mann-Whitney U test were applied to evaluate statistical differences using a data analysis software (JMP 15, SAS Institute Japan, Tokyo, Japan). If number of the null hypothesis was  $k$  in the multiple comparisons, level of significance  $\alpha$  was adjusted at  $\alpha / k$  for each comparison by Bonferroni correction. A value of  $p < 0.05 / k$  was considered statistically significant. Kappa coefficients for reproducibility of scores between examiners for grading of Engh's classification were calculated using SPSS version 21 (IBM, Armonk, NY, USA) to assess the reliability of the measurements.

## Results

### Patients characteristics

Among the 40 patients enrolled, 36 patients were female and 4 were male. The average age at operation was  $64.2 \pm 10.7$  years. The mean follow-up period for these patients after the surgery was  $3.7 \pm 0.8$  years. The mean weights of female and male patients at surgery were  $56.5 \pm 10.2$  kg and  $73.4 \pm 5.6$  kg, respectively. The mean heights of female and male patients were  $151.6 \pm 7.2$  cm and  $172.5 \pm 8.1$  cm, respectively. The mean body mass index was  $24.6 \pm 4.1$  kg/m<sup>2</sup>. In terms of diagnosis, 35 patients were osteoarthritis and the rest 5 patients were avascular necrosis. Patients with rheumatoid arthritis were not included (Table 1).

**Table 1** Demographics of the Patients

Variable	
Number of patients (hips)	40
Gender Female: Male, n (%)	36 (90%): 4 (10%)
Mean age at surgery (years)	$64.2 \pm 10.7$
Mean follow-up period (years)	$3.7 \pm 0.8$
Pre-operative diagnosis, n (%)	
Osteoarthritis	35 (87.5)
Avascular necrosis	5 (12.5)
Body Mass Index (Kg/m <sup>2</sup> )	$24.6 \pm 4.1$

Results are the mean with a standard deviation in parenthesis

### Radiological evaluation

At every time point, there were no radiographical signs of loosening, subsidence and breakage of the stem. At 3 years after surgery, stress shielding was observed in 26 hips (65%). Of these 26 hips, 16 hips (40%) were grade 1 and 10 hips (25%) were grade 2 according to Engh's classification. Severe stress shielding in grade 3 or 4 was not observed (Table 2). Kappa coefficient for reproducibility of scores between examiners for grading of Engh's classification was 0.75. The radiographs of the representative case without stress shielding were demonstrated in Fig. 2.

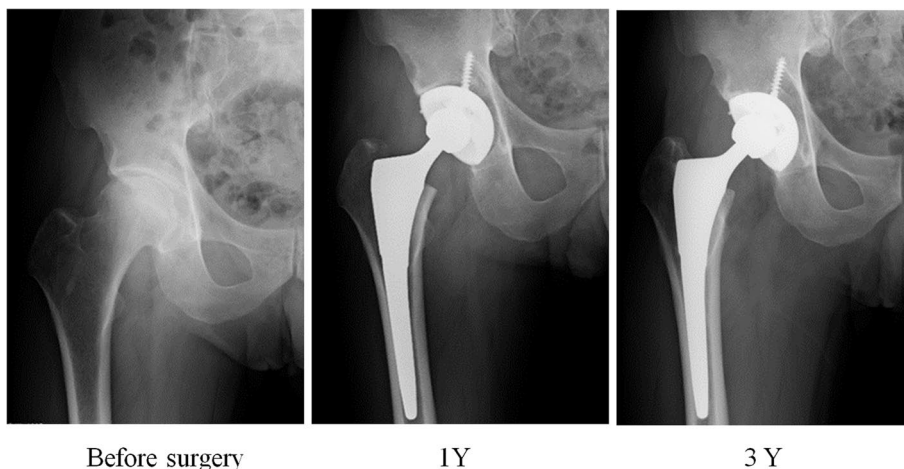
### Clinical evaluation

The JOA scores were  $47.4 \pm 9.6$  points before surgery, which improved to  $73.3 \pm 9.2$  points at 6 weeks,  $78.5 \pm 9.9$  points at 3 months,  $82.3 \pm 8.4$  points at 6 months and  $84.9 \pm 8.6$  points at 1 year. Compared with the preoperative JOA scores, the postoperative scores improved significantly at 6 weeks, 3 months, 6 months, and 1 year ( $p < 0.0001$ ,  $p < 0.0001$ ,  $p < 0.0001$ ,  $p < 0.0001$ , respectively) (Fig. 3). The preoperative JHEQ scores were  $18.1 \pm 9.5$  points, which improved to  $51.8 \pm 13.5$  points at 3 months,  $56.9 \pm 14.3$  points at 6 months,  $57.5 \pm 11.7$  points at 1 year after surgery. Compared with the preoperative JHEQ scores, the postoperative scores improved significantly at 3 months, 6 months, and 1 year ( $p < 0.0001$ ,  $p < 0.0001$ ,  $p < 0.0001$ , respectively) (Fig. 4). No adverse event including allergic reaction was observed. There were no periprosthetic infection, dislocation, or revision surgery.

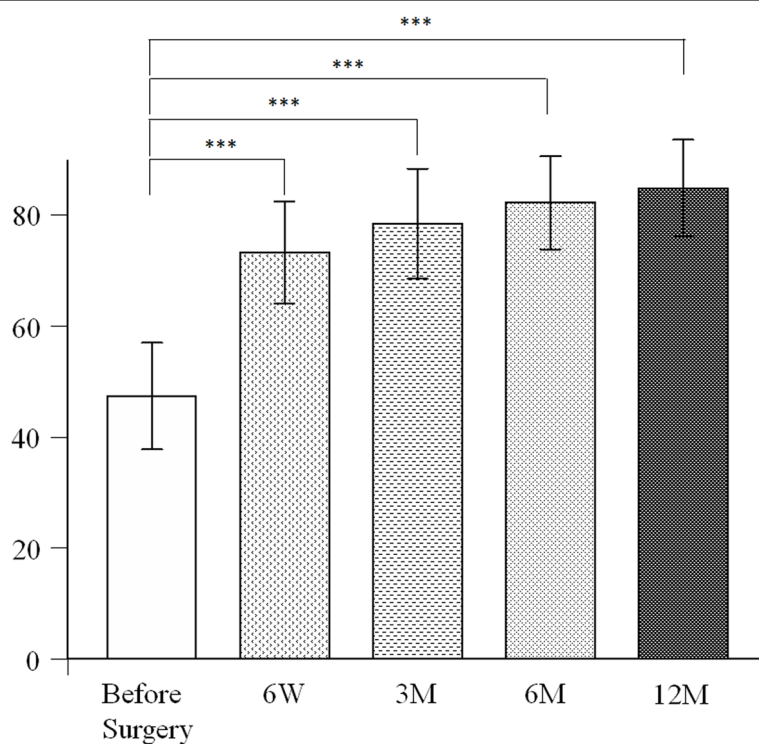
**Table 2** Stress shielding according to the Engh's classification at 3-year follow-up

Engh's classification	Number of patients (Hips)	Ratio (%)
None	14	35
Grade 1	10	25
Grade 2	16	40
Grade 3	0	0
Grade 4	0	0





**Fig. 2** Radiographs of the representative case without stress shielding. **A** Before surgery. **B** 1 year after surgery. **C** 3 year after surgery

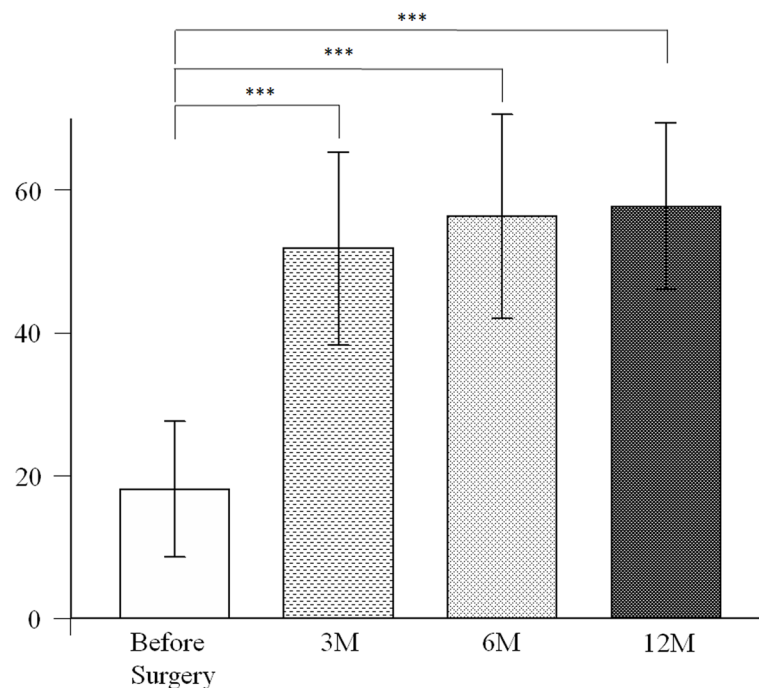


**Fig. 3** Comparison of Japanese Orthopaedic Association Hip Scores before surgery, and 6 weeks, 3 months, 6 months, and 1 year after surgery. \*\*\* $P < 0.00025$  by Mann-Whitney U test with post-hoc by Bonferroni correction for 4 comparisons

**Discussion**

The current study showed good clinical outcomes at 3years using this new TNS alloy femoral stem. Radiological results also showed good fixation in all

cases without loosening and subsidence of the stem. There were no complications such as the breakage and corrosion of the stem, and no safety issues were encountered.



**Fig. 4** Comparison of Japanese Orthopaedic Association Hip Disease Evaluation Questionnaire before surgery, and 3 months, 6 months, and 1 year after surgery. \*\*\* $P < 0.00055$  by Mann-Whitney U test with post-hoc by Bonferroni correction for 3 comparisons

The incidence of stress shielding at 3 years was 65% in this study. The grade of stress shielding was mild, up to grade 2, and there was no occurrence of advanced stress shielding. In contrast, previous studies using the same design type of stems demonstrated that the incidence of stress shielding was much higher (87.4–100%), and the grade of stress-shielding was more advanced [28–30]. In the previous study of load-stress analysis of TNS alloy stem using finite element methods showed that TNS alloy stem increased the load-stress in the cortical bone and might solve the load-stress imbalance between the cortical bone and prosthesis stems [21]. In the present study, the Kappa coefficient in the assessment of stress shielding was good. Previous study reported that the reproducibility of the evaluation of stress shielding was moderate among the cases with mild stress shielding compared [31]. There were no cases with advanced stress shielding in the present study, therefore it was reasonable the Kappa coefficient was resulted in not excellent, but good value.

The clinical scores of TNS alloy stem at 3 years in this study was significantly improved compared with the clinical scores at baseline. Previous clinical studies using the conventional titanium alloy (Ti-6Al-4V) stem demonstrated excellent results in the improvements of clinical scores [3–7]. We were not surprised to know that the mid-term results were comparable between the new TNS

alloy stem and the conventional Ti-6Al-4V alloy stem in terms of clinical score improvement. However, in the long-term postoperative course, the TNS alloy stem may suppress the occurrence of stress-shielding and bone atrophy, which may contribute to a better clinical outcome in the long-term. Furthermore, considering these potential advantages, the TNS alloy stem may contribute to extend the durability of THA prosthesis and reduce the risk of revisional surgery.

The TNS alloy has a gradient functional property that allows us to change the modulus and strength by heat treatment, and this technology was applied for the stem used in this study. With the low thermal conductivity of TNS alloys, it is speculated that this functional gradient property could be applied to short designed stems used in anterior lateral supine hip approaches. In addition, the low Young's modulus of TNS alloys may also be useful in other orthopaedic implants. Although locking plates with Ti-6Al-4V alloy for fracture treatment are widely used, the previous reports described that their excessive stiffness might inhibit an adequate micro-motion for fracture healing and obstruct bone healing [32, 33]. In the previous studies using mice and rabbits tibial fracture models, the TNS alloy promoted bone healing and improved bone strength after healing compared to the Ti-6Al-4V alloy [34, 35]. Similarly, experiments in mice showed that TNS alloy intramedullary

nails promoted bone healing better than stainless steel intramedullary nails [36]. In these studies, it was speculated that the TNS alloy adjusted the load-stress during bone healing and provided appropriate micromotion to the fracture site. The effect of TNS alloy on the adjustment of load-stress to promote bone healing seems to be consistent with the stress shielding prevention observed in this study. We believed that the TNS alloy is a promising material for orthopaedic implants.

To improve the biocompatibility of TNS alloy, the previous studies indicated the effect of anodic oxidation with acetic acid and sulfuric acid which demonstrated improved osseointegration with hydroxyapatite formation in experimental models [37–41]. In contrast, anodic oxidation of TNS alloy with sodium tartrate indicated photocatalytic activity with ultraviolet light irradiation [41]. Therefore, anodic oxide of TNS alloy prepared in sodium tartrate electrolyte may have the antibacterial effect using photocatalytic activity with ultraviolet light irradiation to prevent surgical site infection. Furthermore, the anodized TNS alloy prepared in sodium tartrate electrolyte had improved wear resistance while maintaining its elastic modulus [42, 43]. This seems to be another advantage of TNS alloy.

The present study had several limitations. First, there was no control in this study. The comparison between control cases and cases with TNS alloy femoral stems was not performed in this study because there were few cases operated using Ti-6Al-4V alloy femoral stems with similar design in the study period. Ideally, a cementless femoral stem made of Ti-6Al-4V alloy with the same shape should be used as a control. Second, the number of participants was small, and there was no process for minimizing selection bias in the selection of cases with TNS alloy femoral stem. Third, the follow-up period was short. Future studies are needed to clarify the usefulness of femoral stem of the TNS alloy in a larger cohort study with a long-term follow-up.

## Conclusion

The current study using a new TNS alloy femoral stem showed good clinical outcomes at 3-year follow-up. Radiologically, there was no loosening or subsidence of the stem. The mild stress shielding was observed in 65% of patients. No safety issues occurred during the study period. TNS alloys may be useful as a material for femoral stem.

## Abbreviations

HV: Hardness of Vickers; JOA: Japanese Orthopaedic Association; JHEQ: Japanese orthopaedic association Hip disease Evaluation Questionnaire; THA: Total Hip Arthroplasty; TNS: Ti-Nb-Sn; RM: Robert Mathys.

## Authors' contributions

DC, NY, MO, SO, YK, KB and HT mainly collected the clinical data. DC, YM, EI, SH and TA interpreted the data through discussion. All the authors participated in manuscript writing and editing. All authors approved the final version of the manuscript.

## Funding

The study was funded by Mizuho Co and Japan Hip Joint Foundation. The funders had no role in data collection and interpretation, or the decision to submit the work for publication.

## Availability of data and materials

All data generated or analyzed during this study are included in this published article.

## Declarations

### Ethics approval and consent to participate

This study was approved by Clinical Research Ethics Committee of Tohoku University Hospital. Approval number: #201506–1. Written informed consent was obtained from all patients in accordance with the Declaration of Helsinki before participating in this study.

### Consent for publication

Not applicable.

### Competing interests

The authors declare that they have no conflict of interest.

### Author details

<sup>1</sup>Department of Orthopaedic Surgery, Tohoku University Graduate School of Medicine, 1-1 Seiryomachi, Aoba-ku, Sendai, Miyagi 980-8574, Japan.

<sup>2</sup>Department of Orthopaedic Surgery, Sendai Red Cross Hospital, 2-43-3 Yagiyamahoncho, Taihaku-ku, Sendai, Miyagi 982-8501, Japan. <sup>3</sup>Department of Orthopaedic Surgery, Osaki Citizen Hospital, 3-8-1 Furukawahonami, Osaki, Miyagi 989-6183, Japan. <sup>4</sup>Institute for Materials Research, Tohoku University, 2-1-1 Katahira, Aoba-ku, Miyagi 980-8577, Japan.

Received: 19 May 2021 Accepted: 17 November 2021

Published online: 26 November 2021

## References

- Callaghan JJ, Bracha P, Liu SS, Piyaworakhun S, Goetz DD, Johnston RC. Survivorship of a Charnley total hip arthroplasty. A concise follow-up, at a minimum of thirty-five years, of previous reports. *J Bone Joint Surg Am.* 2009;91(11):2617–21. Epub 2009/11/04. PubMed PMID: 19884436. <https://doi.org/10.2106/JBJS.H.01201>.
- Klapach AS, Callaghan JJ, Goetz DD, Olejniczak JP, Johnston RC. Charnley total hip arthroplasty with use of improved cementing techniques - A minimum twenty-year follow-up study. *J Bone Joint Surg Am.* 2001;83a(12):1840–8. <https://doi.org/10.2106/00004623-200112000-00012> PubMed PMID: WOS:000172724400012.
- Bourne RB, Rorabeck CH, Patterson JJ, Guerin J. Tapered titanium cementless total hip replacements - A 10- to 13-year followup study. *Clin Orthop Relat R.* 2001;(393):112–20 PubMed PMID: WOS:000172493400014.
- Capello WN, D'Antonio JA, Jaffe WL, Geesink RG, Manley MT, Feinberg JR. Hydroxyapatite-coated femoral components: 15-year minimum followup. *Clin Orthop Relat Res.* 2006;(453):75–80. <https://doi.org/10.1097/01.blo.0000246534.44629.b2> Epub 2006/10/04. PubMed PMID: 17016216.
- Engh CA Jr, Mohan V, Nagowski JP, Sychterz Terefenko CJ, Engh CA Sr. Influence of stem size on clinical outcome of primary total hip arthroplasty with cementless extensively porous-coated femoral components. *J Arthroplast.* 2009;24(4):554–9. PubMed PMID: 18534449. Epub 2008/06/07. <https://doi.org/10.1016/j.arth.2008.02.002>.
- Kim YH. Long-term results of the cementless porous-coated anatomic total hip prosthesis. *J Bone Joint Surg-Bri.* 2005;87b(5):623–7. <https://doi.org/10.1302/0301-620x.87b5.15554> PubMed PMID: WOS:000229195600005.

7. Albrektsson T, Branemark PI, Hansson HA, Lindstrom J. Osseointegrated titanium implants. Requirements for ensuring a long-lasting, direct bone-to-implant anchorage in man. *Acta Orthop Scand*. 1981;52(2):155–70. PubMed PMID: 7246093. Epub 1981/01/01. <https://doi.org/10.3109/17453678108991776>.
8. Huiskes R. The various stress patterns of press-fit, ingrown, and cemented femoral stems. *Clin Orthop Relat Res*. 1990;261:27–38 Epub 1990/12/01. PubMed PMID: 2245558.
9. Van Rietbergen B, Huiskes R, Weinans H, Sumner DR, Turner TM, Galante JO. ESb research award 1992. The mechanism of bone remodeling and resorption around press-fitted THA stems. *J Biomech*. 1993;26(4–5):369–82. PubMed PMID: 8478342. Epub 1993/04/01. [https://doi.org/10.1016/0021-9290\(93\)90001-u](https://doi.org/10.1016/0021-9290(93)90001-u).
10. Engh CA Jr, Young AM, Engh CA Sr, Hopper RH Jr. Clinical consequences of stress shielding after porous-coated total hip arthroplasty. *Clin Orthop Relat Res*. 2003;417:157–63. <https://doi.org/10.1097/01.blo.0000096825.67494.e3> Epub 2003/12/04. PubMed PMID: 14646713.
11. Lindahl H. Epidemiology of periprosthetic femur fracture around a total hip arthroplasty. *Injury*. 2007;38(6):651–4. PubMed PMID: 17477925. Epub 2007/05/05. <https://doi.org/10.1016/j.injury.2007.02.048>.
12. Nakashima Y, Sato T, Yamamoto T, Motomura G, Ohishi M, Hamai S, et al. Results at a minimum of 10 years of follow-up for AMS and PerFix HA-coated cementless total hip arthroplasty: impact of cross-linked polyethylene on implant longevity. *J Orthop Sci*. 2013;18(6):962–8. PubMed PMID: 23963589. Epub 2013/08/22. <https://doi.org/10.1007/s00776-013-0456-4>.
13. Rho JY, Ashman RB, Turner CH. Young's Modulus of trabecular and cortical bone material - ultrasonic and microtensile measurements. *J Biomech*. 1993;26(2):111–9. [https://doi.org/10.1016/0021-9290\(93\)90042-D](https://doi.org/10.1016/0021-9290(93)90042-D) PubMed PMID: WOS:A1993KJ75500003.
14. Morscher E, Mathys R. Total isoelectric hip prosthesis implanted without cement. Initial results. *Acta Orthop Belg*. 1974;40(5–6):639–47 Epub 1974/01/01. PubMed PMID: 4469728.
15. Morscher E, Mathys R. First experiences with a cementless isoelectric total hip prosthesis. *Z Orthop Ihre Grenzgeb*. 1975;113(4):745–9 Epub 1975/08/01. PubMed PMID: 1210626.
16. Bombelli R, Mathys R. Cementless Isoelectric Rm Total Hip-Prosthesis. *J Roy Soc Med*. 1982;75(8):588–97 PubMed PMID: WOS:A1982PA37800005.
17. Trebbe R, Milosev I, Kovac S, Mikek M, Pisot V. Poor results from the isoelectric total hip replacement: 14-17-year follow-up of 149 cementless prostheses. *Acta Orthop*. 2005;76(2):169–76. Epub 2005/08/16. PubMed PMID: 16097540. <https://doi.org/10.1080/00016470510030535>.
18. Hanada S, Masahashi N, Jung TK, Yamada N, Yamako G, Itoi E. Fabrication of a high-performance hip prosthetic stem using beta Ti-33.6Nb-4Sn. *J Mech Behav Biomed Mater*. 2014;(30):140–9. <https://doi.org/10.1016/j.jmbbm.2013.11.002> PubMed PMID: 24291735. Epub 2013/12/03.
19. Miura K, Yamada N, Hanada S, Jung TK, Itoi E. The bone tissue compatibility of a new Ti-Nb-Sn alloy with a low Young's modulus. *Acta Biomater*. 2011;7(5):2320–6. Epub 2011/02/15. PubMed PMID: 21316491. <https://doi.org/10.1016/j.actbio.2011.02.008>.
20. Charnley J. The long-term results of low-friction arthroplasty of the hip performed as a primary intervention. *J Bone Joint Surg Br*. 1972;54(1):61–76 Epub 1972/02/01. PubMed PMID: 5011747.
21. Yamako G, Janssen D, Hanada S, Anijs T, Ochiai K, Totoribe K, et al. Improving stress shielding following total hip arthroplasty by using a femoral stem made of beta type Ti-33.6Nb-4Sn with a Young's modulus gradation. *J Biomech*. 2017;63:135–43. Epub 2017/09/09. PubMed PMID: 28882332. <https://doi.org/10.1016/j.jbiomech.2017.08.017>.
22. Yamako G, Chosa E, Totoribe K, Hanada S, Masahashi N, Yamada N, et al. In-vitro biomechanical evaluation of stress shielding and initial stability of a low-modulus hip stem made of beta type Ti-33.6Nb-4Sn alloy. *Med Eng Phys*. 2014;36(12):1665–71. Epub 2014/10/06. PubMed PMID: 25282098. <https://doi.org/10.1016/j.medengphy.2014.09.002>.
23. Khanuja HS, Vakili JJ, Goddard MS, Mont MA. Cementless femoral fixation in total hip arthroplasty. *J Bone Joint Surg Am*. 2011;93(5):500–9. Epub 2011/03/04. PubMed PMID: 21368083. <https://doi.org/10.2106/JBJS.J.00774>.
24. Ni JE, Case ED, Sakamoto JS, Rangasamy E, Wolfenstine JB. Room temperature elastic moduli and Vickers hardness of hot-pressed LLZO cubic garnet. *J Mater Sci*. 2012;47(23):7978–85 PubMed PMID: WOS:000308726500003.
25. Engh CA, Bobyn JD, Glassman AH. Porous-coated hip replacement. The factors governing bone ingrowth, stress shielding, and clinical results. *J Bone Joint Surg Br*. 1987;69(1):45–55 Epub 1987/01/01. PubMed PMID: 3818732.
26. S I. The Japanese orthopaedic association: evaluation chart of hip joint functions. *J Jpn Orthop Assoc*. 1995;69:864–7.
27. Matsumoto T, Kaneuji A, Hiejima Y, Sugiyama H, Akiyama H, Atsumi T, et al. Japanese Orthopaedic Association Hip Disease Evaluation Questionnaire (JHEQ): a patient-based evaluation tool for hip-joint disease. The Subcommittee on Hip Disease Evaluation of the Clinical Outcome Committee of the Japanese Orthopaedic Association. *J Orthop Sci*. 2012;17(1):25–38. <https://doi.org/10.1007/s00776-011-0166-8> Epub 2011/11/03 PubMed PMID: 22045450; PubMed Central PMCID: PMCPCMC3265722.
28. Shishido T, Tateiwa T, Takahashi Y, Masaoka T, Ishida T, Yamamoto K. Effect of stem alignment on long-term outcomes of total hip arthroplasty with cementless Bi-Metric femoral components. *J Orthop*. 2018;15(1):134–7. <https://doi.org/10.1016/j.jor.2018.01.008> Epub 2018/04/17. PubMed PMID: 29657457; PubMed Central PMCID: PMCPCMC5895888.
29. Nishino T, Mishima H, Kawamura H, Shimizu Y, Miyakawa S, Ochiai N. Follow-up results of 10-12 years after total hip arthroplasty using cementless tapered stem – frequency of severe stress shielding with synergy stem in Japanese patients. *J Arthroplast*. 2013;28(10):1736–40. Epub 2013/04/02. PubMed PMID: 23540537. <https://doi.org/10.1016/j.arth.2013.02.027>.
30. Ateschrang A, Weise K, Weller S, Stockle U, de Zwart P, Ochs BG. Long-term results using the straight tapered femoral cementless hip stem in total hip arthroplasty: a minimum of twenty-year follow-up. *J Arthroplast*. 2014;29(8):1559–65. Epub 2014/03/25. PubMed PMID: 24656056. <https://doi.org/10.1016/j.arth.2014.02.015>.
31. Engh CA Jr, McAuley JP, Sychterz CJ, Sacco ME, Engh CA Sr. The accuracy and reproducibility of radiographic assessment of stress-shielding. A postmortem analysis. *J Bone Joint Surg Am*. 2000;82(10):1414–20. Epub 2000/11/01. PubMed PMID: 11057469. <https://doi.org/10.2106/0004623-200010000-00007>.
32. Molster A, Gjerdet NR, Raugstad TS, Kholo A, Bang G. Effect of instability on experimental fracture-healing. *Acta Orthop Scand*. 1982;53(4):521–6. <https://doi.org/10.3109/17453678208992251> PubMed PMID: WOS:A1982PC25500003.
33. Henderson CE, Kuhl LL, Fitzpatrick DC, Marsh JL. Locking plates for distal femur fractures: is there a problem with fracture healing? *J Orthop Trauma*. 2011;25:S8–S14. <https://doi.org/10.1097/BOT.0b013e3182070127> PubMed PMID: WOS:000297573600003.
34. Fujisawa H, Mori Y, Kogure A, Tanaka H, Kamimura M, Masahashi N, et al. Effects of intramedullary nails composed of a new beta-type Ti-Nb-Sn alloy with low Young's modulus on fracture healing in mouse tibiae. *J Biomed Mater Res B*. 2018;106(8):2841–8. <https://doi.org/10.1002/jbm.b.34064> PubMed PMID: WOS:000448178200011.
35. Kogure A, Mori Y, Tanaka H, Kamimura M, Masahashi N, Hanada S, et al. Effects of elastic intramedullary nails composed of low Young's modulus Ti-Nb-Sn alloy on healing of tibial osteotomies in rabbits. *J Biomed Mater Res B*. 2019;107(3):700–7. <https://doi.org/10.1002/jbm.b.34163> PubMed PMID: WOS:000461683400023.
36. Mori Y, Fujisawa H, Kamimura M, Kogure A, Tanaka H, Mori N, et al. Acceleration of fracture healing in mouse tibiae using intramedullary nails composed of  $\beta$ -type TiNbSn alloy with low Young's Modulus. *Tohoku J Exp Med*. 2021;255(2):135–42. <https://doi.org/10.1620/tjem.255.135>.
37. Masahashi N, Mori Y, Tanaka H, Kogure A, Inoue H, Ohmura K, et al. Study of bioactivity on a TiNbSn alloy surface. *Thin Solid Films*. 2017;639:22–8. <https://doi.org/10.1016/j.tsf.2017.08.023> PubMed PMID: WOS:000412787200004.
38. Tanaka H, Mori Y, Noro A, Kogure A, Kamimura M, Yamada N, et al. Apatite formation and biocompatibility of a low young's modulus ti-nb-sn alloy treated with anodic oxidation and hot water. *Plos One*. 2016;11(2):e0150081. <https://doi.org/10.1371/journal.pone.0150081> Epub 2016/02/26. PubMed PMID: 26914329; PubMed Central PMCID: PMCPCMC4767882.
39. Kunii T, Mori Y, Tanaka H, Kogure A, Kamimura M, Mori N, et al. Improved Osseointegration of a TiNbSn Alloy with a Low Young's Modulus Treated with Anodic Oxidation. *Sci Rep-Uk*. 2019;9. <https://doi.org/10.1038/s41598-019-50581-7> ARTN 13985. PubMed PMID: WOS:000488222500037.



40. Masahashi N, Mori Y, Tanaka H, Kogure A, Inoue H, Ohmura K, et al. Bioactive TiNbSn alloy prepared by anodization in sulfuric acid electrolytes. *Mat Sci Eng C-Mater*. 2019;98:753–63. <https://doi.org/10.1016/j.msec.2019.01.033> PubMed PMID: WOS:000461526800076.
41. Masahashi N, Mori Y, Kurishima H, Inoue H, Mokudai T, Semboshi S, et al. Photoactivity of an anodized biocompatible TiNbSn alloy prepared in sodium tartrate/hydrogen peroxide aqueous solution. *Appl Surf Sci*. 2021;543. <https://doi.org/10.1016/j.apsusc.2020.148829> ARTN 148829. PubMed PMID: WOS:000613947400002.
42. Hatakeyama M, Masahashi N, Michiyama Y, Inoue H, Hanada S. Wear resistance of surface-modified TiNbSn alloy. *J Mater Sci*. 2021;56(25):14333–47. <https://doi.org/10.1007/s10853-021-06213-5>.
43. Hatakeyama M, Masahashi N, Michiyama Y, Inoue H, Hanada S. Mechanical properties of anodized TiNbSn alloy for biomedical applications. *Mater Sci Eng A*. 2021;825. <https://doi.org/10.1016/j.msea.2021.141898>.

### Publisher's Note

Springer Nature remains neutral with regard to jurisdictional claims in published maps and institutional affiliations.

Ready to submit your research? Choose BMC and benefit from:

- fast, convenient online submission
- thorough peer review by experienced researchers in your field
- rapid publication on acceptance
- support for research data, including large and complex data types
- gold Open Access which fosters wider collaboration and increased citations
- maximum visibility for your research: over 100M website views per year

At BMC, research is always in progress.

Learn more [biomedcentral.com/submissions](https://biomedcentral.com/submissions)

