

# Challenging surgical treatment of giant retroperitoneal liposarcoma: A case report

XIAOYI WEI<sup>1\*</sup>, YUJIE QIN<sup>2\*</sup>, SONG OUYANG<sup>3</sup>, JUN QIAN<sup>4</sup>, SONG TU<sup>1,4</sup> and JIAXI YAO<sup>1,4</sup>

Departments of <sup>1</sup>Urology and <sup>2</sup>Endoscopy Center, Hexi University Affiliated Zhangye People's Hospital, Zhangye, Gansu 734000; <sup>3</sup>Department of Urology, First Affiliated Hospital, School of Medicine, Shihezi University, Shihezi, Xinjiang 830000; <sup>4</sup>Institute of Urology, Hexi University, Zhangye, Gansu 734000, P.R. China

Received May 17, 2022; Accepted June 30, 2022

DOI: 10.3892/ol.2022.13434

**Abstract.** Liposarcoma is a rare malignant tumor type and surgical resection is the gold standard treatment. The present study reported on the case of a 51-year-old woman who presented with a mass in the left upper abdomen. Computed tomography revealed a 32-cm giant retroperitoneal liposarcoma. Complete tumor resection was performed without the removal of other organs. Postoperative pathological examination indicated retroperitoneal well-differentiated liposarcoma and immunohistochemistry revealed S-100(-), MDM2(+), vimentin(+), CDK4(+), p16(+) and STAT6(+) results. The patient recovered well after the surgery. Complete tumor resection during the first surgery is key to cure liposarcoma. The present case report will be helpful for clinical oncologists to fully understand giant retroperitoneal liposarcoma and treat it accordingly.

## Introduction

The most common subtypes of soft-tissue sarcomas are liposarcoma, leiomyosarcoma, malignant fibrous histiocytoma and fibrosarcoma (1,2). Liposarcoma is a rare malignancy that originates from the adipose tissue and accounts for <1% of all malignancies (3,4). It may occur anywhere in the adipose tissue. The World Health Organization classifies it histologically into well-differentiated, myxoid/round cell, pleomorphic and dedifferentiated subtypes (5,6). The incidence of liposarcoma has gradually increased and the disease is more common in middle-aged and older individuals (7). Most liposarcomas grow slowly and the huge space in the retroperitoneum and

abdominal cavity provides sufficient space for their growth. Giant liposarcomas eventually surround large blood vessels and vital organs (8,9). Retroperitoneal liposarcoma is usually asymptomatic until it is large enough to compress the surrounding organs, and there is no evidence that chemotherapy or radiotherapy improves survival (10,11). The present study reports a case of giant retroperitoneal liposarcoma. Giant liposarcoma is rare but is occasionally reported in developing countries, where the tumor grows irregularly, and there are no conventional surgical methods and techniques to manage these large retroperitoneal malignancies. The present study reported a case of a 6-kg giant retroperitoneal liposarcoma measuring 32x30 cm.

## Case report

The patient was a 51-year-old female with a body mass index of 17.58 kg/m<sup>2</sup>. The patient observed a mass in the upper left abdomen for 3 days, and visited Hexi University Affiliated Zhangye People's Hospital (Zhangye, China) in March 2022 for treatment. Computed tomography (CT) revealed a giant retroperitoneal liposarcoma measuring 32 cm in size (Fig. 1). After a multidisciplinary team discussion, surgical treatment was decided and preoperative preparations were performed. Open surgery was performed under general anesthesia. During the surgery, the tumor was found to be located in the retroperitoneum, the small intestine had been pushed to the upper left corner of the abdomen and the tumor extended from the gastrocolic ligament to the deep pelvic cavity. The texture of the tumor in the left upper corner was hard (the patient went to the hospital after palpating that mass) and the other parts of the tumor were soft like fat. The left ureter that was pushed by the tumor and had deviated to the right was repositioned during the procedure (Fig. 2). The abdominal cavity was closed after no other injury was found on exploration. The patient returned to the ward without being sent to the intensive care unit. Postoperative pathological examination indicated retroperitoneal well-differentiated liposarcoma, while immunohistochemistry, performed as previously described (12), revealed S-100(-) (cat. no. Kit-0007), MDM-2(+) (cat. no. MAB-0074), vimentin(+) (cat. no. MAB-0735), CDK4(+) (cat. no. RMA-0771), p16(+) (cat. no. MAB-0673) and STAT6(+) (cat. no. RMA-0845) (all Fuzhou Maixin

---

*Correspondence to:* Dr Jiaxi Yao or Dr Song Tu, Department of Urology, Hexi University Affiliated Zhangye People's Hospital, 67 Xihuan Road, Ganzhou, Zhangye, Gansu 734000, P.R. China  
E-mail: 1611210057@fudan.edu.cn  
E-mail: zytusong@126.com

\*Contributed equally

*Key words:* liposarcoma, case report, surgery

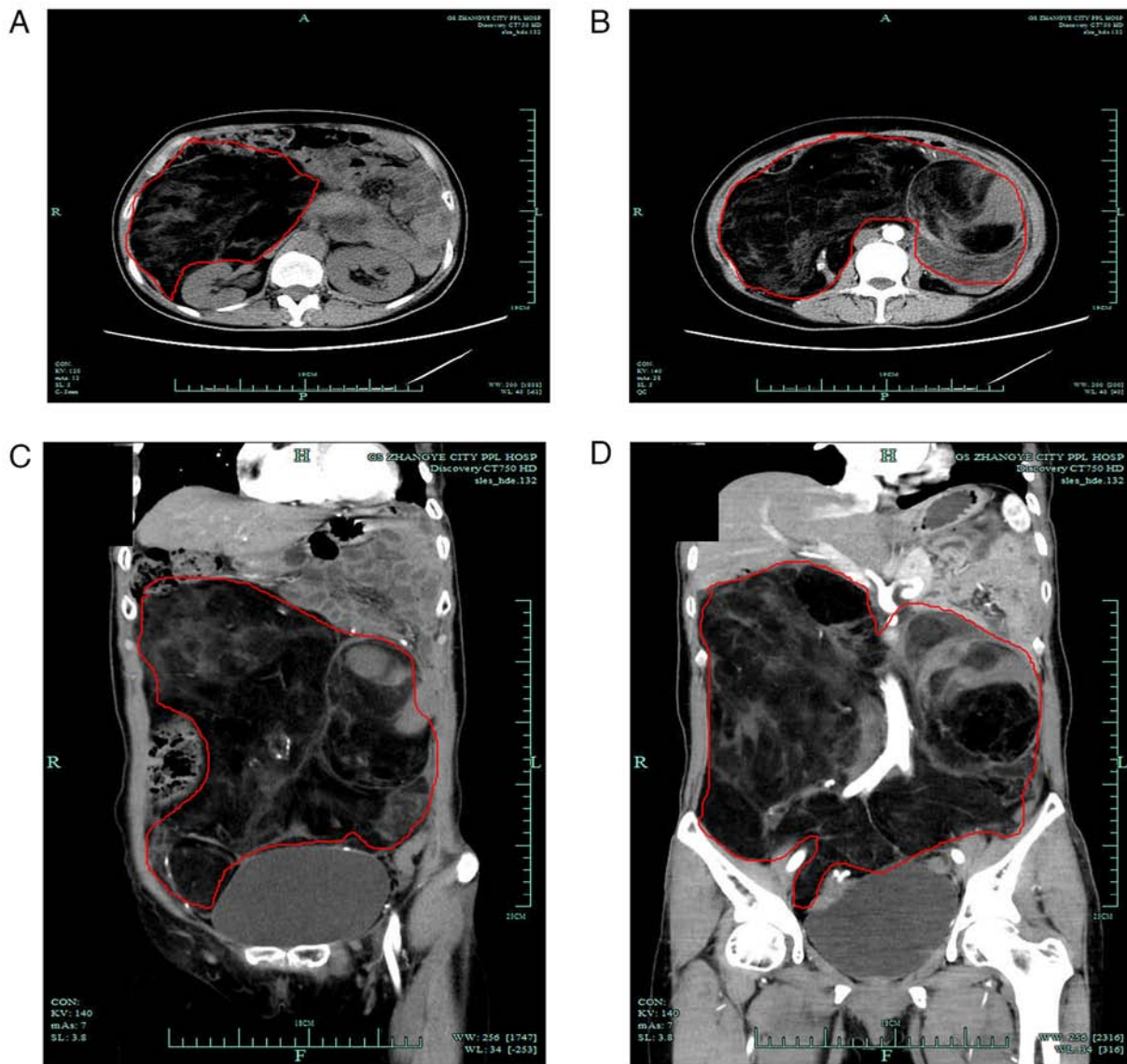


Figure 1. Preoperative CT images. (A) Cross section of giant liposarcoma. (B) Contrast-enhanced CT of giant liposarcoma. (C) Contrast-enhanced CT of giant liposarcoma in the sagittal view. (D) Contrast-enhanced CT of giant liposarcoma in the coronal view. CT, computed tomography.

Biotech Co., Ltd.) results (Fig. 3). The patient had occasional diarrhea in the early stage, and during the follow-up, has been recovering well without any adverse events or obvious discomfort. The patient and the patient's family were satisfied with the recovery and the patient is still being followed up.

## Discussion

Retroperitoneal liposarcoma is a rare mesenchymal tumor type that usually occurs in individuals aged 40-60 years (12,13). Retroperitoneal liposarcoma may grow very large prior to the onset of clinical symptoms, as the latent space of the retroperitoneum and abdominal cavity is large and loose. In case there are no bony borders, retroperitoneal liposarcomas grow recklessly. However, retroperitoneal liposarcomas with a diameter of >30 cm are rare. Most cases are discovered incidentally due to tumor compression symptoms, such as abdominal distension, indigestion and dyspnea. In the present case, the patient experienced an abdominal mass 3 days

prior to visiting the hospital for treatment, indicating that the disease was insidious. Patients generally have no obvious symptoms, particularly when the tumor size is small. Due to its low morbidity and special anatomical location, the tumor is bulky and deep, making resection difficult. Complete surgical removal of the tumor may be highly challenging, while the majority of surgeons lack experience in handling such large tumors. Complete tumor resection during surgery is key to treating this disease; otherwise, it easily relapses, and surgery is the only cure after recurrence. Notably, performing surgery bears great difficulty and a residual tumor increases the risk of relapse. In the present case, the left ureter was compressed and deviated to the far right. Therefore, during the operation, the large blood vessels and tumor tissue were carefully and accurately identified, particularly the iliac blood vessels and intestinal blood vessels, and the ureter was protected because giant tumors disorganize the normal anatomical relationship; the relationship between the abdominal cavity and the retroperitoneum complex, the incision margin is not easy to

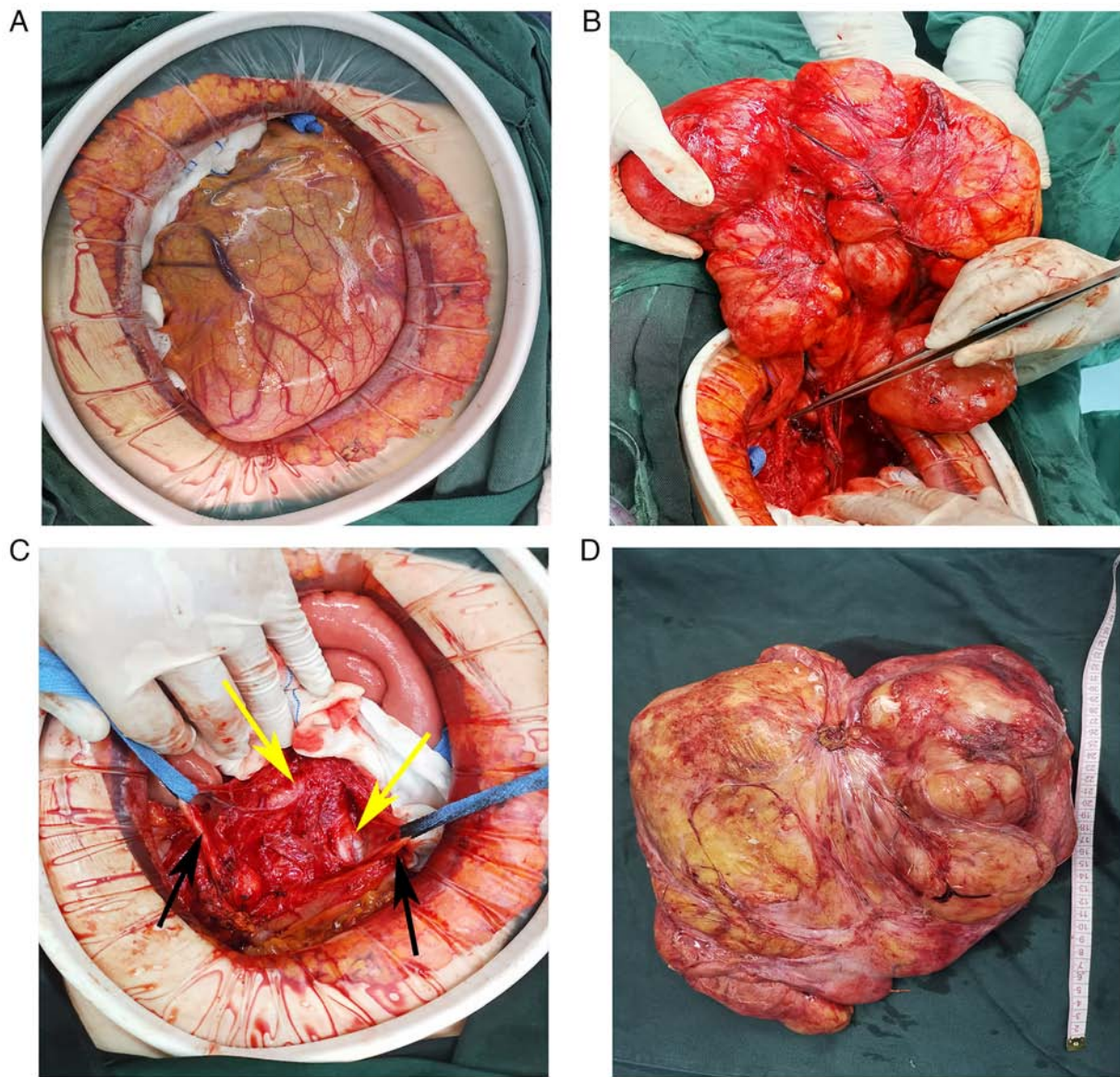


Figure 2. Intraoperative images. (A) Opening the abdominal cavity to expose the tumor. (B) Intraoperative tumor base abutment. (C) Exposure of the iliac vessels (yellow arrows) and ureter (black arrows). (D) Tumor excision specimen (scale bar in cm).

identify and the surrounding blood vessels and ureters require to be protected.

CT is the most commonly used imaging test for diagnosis and preoperative evaluation (14). There is no clear evidence in the literature to support the need for histological biopsy of suspected retroperitoneal tumors because, with or without biopsy, such large tumors require surgical resection, which is the only curative option. Liposarcoma is histologically subdivided into well-differentiated, myxoid/round cell, pleomorphic and dedifferentiated subtypes (15). The 5-year survival rate of patients with well-differentiated retroperitoneal liposarcoma is ~90%. The postoperative pathological examination of the patient of the present study indicated well-differentiated liposarcoma and the patient's prognosis was expected to be favorable after complete resection, while dedifferentiated, myxoid and pleomorphic liposarcoma have an annual survival rate lower than that of well-differentiated liposarcoma (15,16).

Studies have indicated that radiotherapy reduces the risk of local recurrence; however, the supporting data are limited. The

STRASS study suggested that preoperative radiotherapy and surgery did not prolong the recurrence-free survival of patients compared with surgery alone but aggravated the adverse reactions in patients. Therefore, preoperative radiotherapy should not be considered a standard treatment for retroperitoneal sarcoma (17). The role of chemotherapy in retroperitoneal liposarcoma remains controversial, as no studies have demonstrated a significant improvement in survival (18). The main factors affecting patients' prognosis are tumor grade and degree of surgical resection. Radical resection should be performed, and if necessary, the tumor should be removed together with the surrounding organs, such as the kidney, to ensure the completeness of tumor resection. Incomplete piecemeal resection may lead to a significant reduction in patient prognosis and should be avoided intraoperatively.

In conclusion, retroperitoneal liposarcoma is an atypical, rare and aggressively growing tumor. CT may be reliably used for diagnosis and complete resection is the gold standard treatment. A tumor diameter of >30 cm should not be considered a



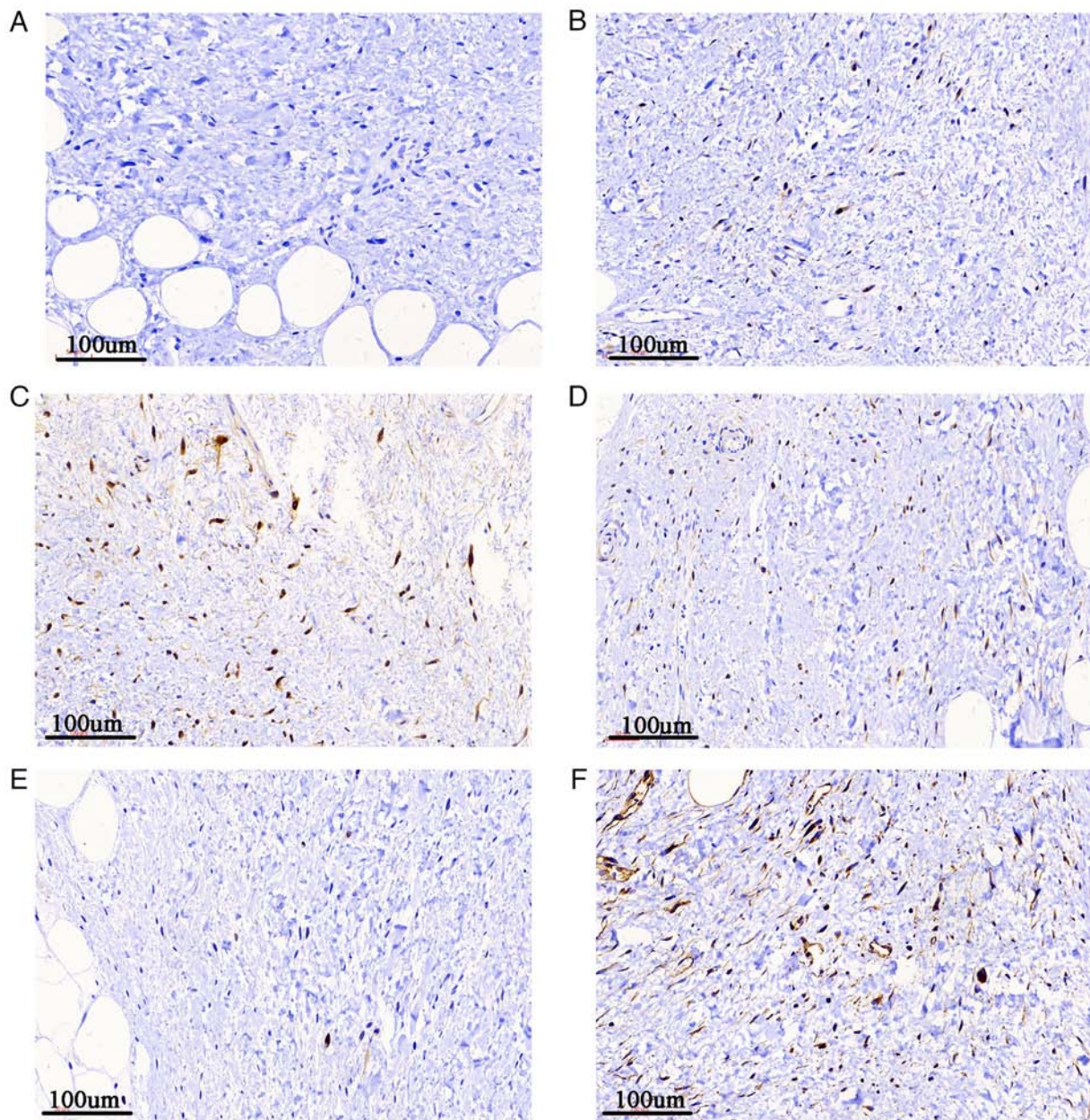


Figure 3. Immunohistochemical analysis of giant liposarcoma tissues. (A) S-100-negative, (B) CDK4-positive, (C) p16-positive, (D) STAT6-positive, (E) MDM2-positive and (F) vimentin-positive brown staining (original magnification, x200).

contraindication for surgical resection; however, treating this disease with radiotherapy or chemotherapy remains controversial. In the present study, surgical resection of a large tumor was successful without postoperative complications and the patient was satisfied with the treatment outcomes. However, the long-term effects of the treatment require to be further evaluated.

#### Acknowledgements

Not applicable.

#### Funding

This study was funded by the Gansu Province Science and Technology Planning Project (grant no. 20JR10RG310).

#### Availability of data and materials

The data sets used and/or analyzed during the current study are available from the corresponding author on reasonable request.

#### Authors' contributions

XYW and YJQ contributed substantially to the conceptualization of the study. XYW performed the surgery, YJQ obtained the medical images, and they both contributed to the drafting of the manuscript and critical revisions for intellectual content. SOY and JQ contributed substantially to the conceptualization and design of the study. ST and JXY assisted in the completion of the surgery, collected clinical information and assisted with drafting the manuscript. XYW, YJQ, ST and JXY approved

the final version of the manuscript for publication. ST and JXY confirm the authenticity of all the raw data. All authors read and approved the final manuscript.

### Ethics approval and consent to participate

The study was conducted according to the guidelines of the Declaration of Helsinki and approved by the Ethics Committee of Hexi University Affiliated Zhangye People's Hospital (Zhangye, China). Written informed consent was obtained from the patient.

### Patient consent for publication

Written informed consent was obtained for publication of the patient's data and images in this case report.

### Competing interests

The authors declare that they have no competing interests.

### References

1. Siegel RL, Miller KD, Fuchs HE and Jemal A: Cancer statistics, 2021. *CA Cancer J Clin* 71: 7-33, 2021.
2. Ray-Coquard I, Serre D, Reichardt P, Martin-Broto J and Bauer S: Options for treating different soft tissue sarcoma subtypes. *Future Oncol* 14: 25-49, 2018.
3. Thway K: Well-differentiated liposarcoma and dedifferentiated liposarcoma: An updated review. *Semin Diagn Pathol* 36: 112-121, 2019.
4. Mansfield SA, Pollock RE and Grignol VP: Surgery for abdominal well-differentiated liposarcoma. *Curr Treat Options Oncol* 19: 1, 2018.
5. Kallen ME and Hornick JL: The 2020 WHO classification: What's new in soft tissue tumor pathology? *Am J Surg Pathol* 45: e1-e23, 2021.
6. Improta L, Tzanis D, Bouhadiba T, Abdelhafidh K and Bonvalot S: Overview of primary adult retroperitoneal tumours. *Eur J Surg Oncol* 46: 1573-1579, 2020.
7. Bock S, Hoffmann DG, Jiang Y, Chen H and Il'yasova D: Increasing incidence of liposarcoma: A population-based study of National surveillance databases, 2001-2016. *Int J Environ Res Public Health* 17: 2710, 2020.
8. Herrera-Almarío G, Cabrera LF, Londono-Schimmer EE and Pedraza M: Giant retroperitoneal liposarcoma surgical management. *Ann R Coll Surg Engl* 104: e54-e56, 2022.
9. Qiao Z, Zhan R, Pang Y and Wu J: Giant retroperitoneal dedifferentiated liposarcoma in an old man. *Asian J Surg* 44: 1076-1078, 2021.
10. Wu YX, Liu JY, Liu JJ, Yan P, Tang B, Cui YH, Zhao YL, Shi Y, Hao YX, Yu PW and Qian F: A retrospective, single-center cohort study on 65 patients with primary retroperitoneal liposarcoma. *Oncol Lett* 15: 1799-1810, 2018.
11. Lee ATJ, Thway K, Huang PH and Jones RL: Clinical and molecular spectrum of liposarcoma. *J Clin Oncol* 36: 151-159, 2018.
12. Yao JX, Chen X, Zhu YJ, Wang H, Hu XY and Guo JM: Prognostic value of vimentin is associated with immunosuppression in metastatic renal cell carcinoma. *Front Oncol* 10: 1181, 2020.
13. Cheung KT, Mitchell C and Wong E: Retroperitoneal liposarcoma in a nonagenarian. *Autops Case Rep* 11: e2020224, 2020.
14. Wang Q, Juan YH, Li Y, Xie JJ, Liu H, Huang H, Liu Z, Zheng J, Saboo US, Saboo SS and Liang C: Multidetector computed tomography features in differentiating exophytic renal angiomyolipoma from retroperitoneal liposarcoma: A Strobe-compliant observational study. *Medicine (Baltimore)* 94: e1521, 2015.
15. Mascarenhas MRM, Mutti LA, Paiva JMG, Enokihara MMSES, Rosa IP and Enokihara MY: Giant atypical lipoma. *An Bras Dermatol* 92: 546-549, 2017.
16. Haddox CL and Riedel RF: Recent advances in the understanding and management of liposarcoma. *Fac Rev* 10: 1, 2021.
17. Bonvalot S, Gronchi A, Le Pechoux C, Swallow CJ, Strauss D, Meeus P, van Coevorden F, Stoldt S, Stoeckle E, Rutkowski P, *et al*: Preoperative radiotherapy plus surgery versus surgery alone for patients with primary retroperitoneal sarcoma (EORTC-62092: STRASS): A multicentre, open-label, randomised, phase 3 trial. *Lancet Oncol* 21: 1366-1377, 2020.
18. Crago AM and Dickson MA: Liposarcoma: Multimodality management and future targeted therapies. *Surg Oncol Clin N Am* 25: 761-773, 2016.



This work is licensed under a Creative Commons Attribution-NonCommercial-NoDerivatives 4.0 International (CC BY-NC-ND 4.0) License.