

Totally implantable venous access system (TIVAS) Complicated by Tracheo-Venous Fistula

Samer Khaled, M.D., Vladimir Gotlieb, M.D., and Arunbai Patel, M.D.

Citation: Khaled S, Gotlieb V, Patel A. Totally implantable venous access system (TIVAS): An Unusual Complication. *Radiology Case Reports*. [Online] 2009;4:266.

Copyright: © 2009 The Authors. This is an open-access article distributed under the terms of the Creative Commons Attribution-NonCommercial-NoDerivs 2.5 License, which permits reproduction and distribution, provided the original work is properly cited. Commercial use and derivative works are not permitted.

Abbreviations: CT, computed tomography; TIVAS, totally implantable venous access system

Samer Khaled, M.D. (Email: samerkm@yahoo.com), Vladimir Gotlieb, M.D. (Email: vzgotlib@yahoo.com), and Arunbai Patel, M.D., are in the Division Of Hematology and Oncology, The Brooklyn Hospital Center, Brooklyn, NY, United States of America.

Published: March 10, 2009

DOI: 10.2484/rcr.v4i1.266

Abstract

Totally implantable venous access system (TIVAS) are widely used for various indications including chemotherapy infusion. The use of TIVAS is associated with number of complications that can occur as early as the time of insertion or can take place months later. We report a case of a 64 year old female with recurrent osteosarcoma of the mandible. She had a port-a-catheter placed for chemotherapy infusion. The patient developed fistula between the Innominate Vein and the trachea, which found to be secondary to a spontaneous migration of the tip of the catheter. To our knowledge this is the first case of this kind to be reported. This complication, although very rare, can be life threatening, and should be considered when there is a malfunction of the TIVAS.

Introduction

Totally implanted venous access devices are widely used for chemotherapy delivery especially when the patient has poor venous access. Catheter placement associated with number of complications, including pneumothorax 3.4%, catheter fracture and embolization 1.5%, venous thrombosis 1.5%, pocket infection 0.3%, port-related bacteremia 2.4%, and sepsis. These complications are higher in patients suffering from hematological disorders, up to 15% [1, 2]. Fistulas and spontaneous migration of TIVAS have been reported as rare cases [3,6,7]. We present a patient with catheter induced fistula between the Innominate vein and the trachea, which we believed was secondary to spontaneous migration. To our knowledge this is the first case of this kind in the literature.

Case Report

A 64-year-old woman was diagnosed with osteosarcoma of the right mandible and treated with surgical resection. Eight months later, she presented to the emergency room with pain to the right side

of the face along with an enlarging mass. A biopsy of the mass revealed recurrent osteosarcoma and was deemed inoperable.

A port system (LifePort®, silicone Fr.12) was placed and the patient received multiple cycles of chemotherapy. She then received radiation therapy in concurrence with chemotherapy which resulted in partial response.

Nine months later the patient returned to the emergency room with poor oral intake. She had normal vital signs. Apart of asymmetry of the face, the rest of the physical exam was unremarkable. The port site had no signs of infection or inflammation.

During the hospital stay she had bouts of cough and choking sensation whenever the catheter was flushed. She also complained of “salty taste” in her mouth after the port was flushed with normal saline. We suspected malfunction of the catheter and did x-rays of the chest. It showed a malposition of the catheter. [Fig. 1], CT scan of chest confirmed that the tip was in the trachea [Fig. 2]. A fistula was subsequently confirmed on venogram. [Fig. 3]

A comparison of the chest x-ray taken before the fistula was repaired and the chest x-ray taken after insertion of the catheter revealed migration of the tip. [Fig. 4]. Since there was no surgical intervention during that period of time; we believe that this happened spontaneously. This migration led to a pressure necrosis and in turn a fistula formation between the trachea and the Innominate Vein.

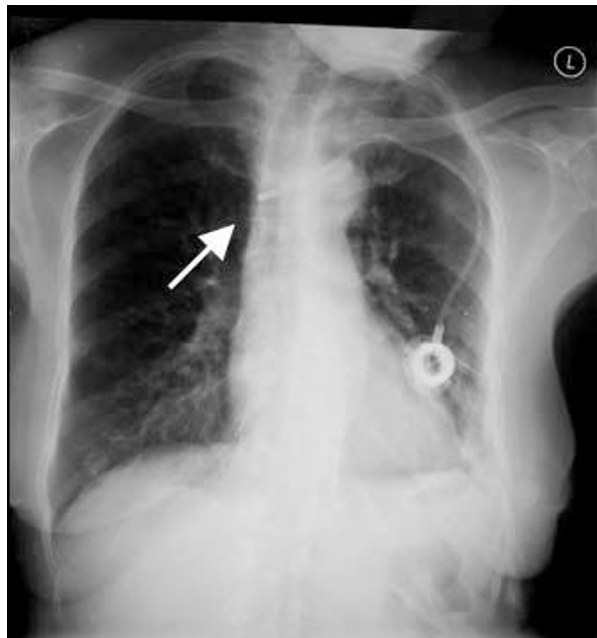


Figure 1. 64-year-old woman with implanted venous access device. Chest radiograph shows malpositioning of the catheter tip.

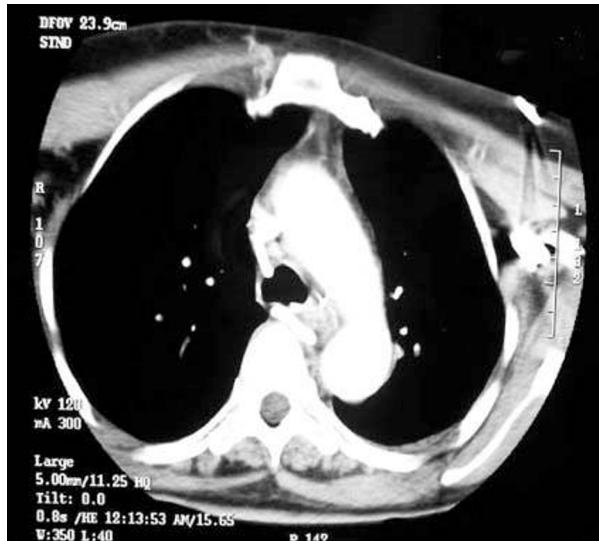


Figure 2. 64-year-old woman with implanted venous access device. Chest CT shows the catheter tip in the trachea.

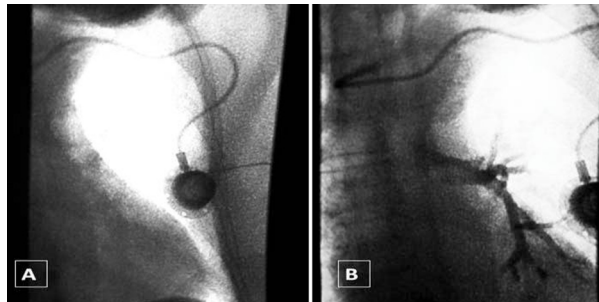


Figure 3. 64-year-old woman with implanted venous access device. Venogram shows the presence of a fistula between the vein and the trachea. **A**, Before contrast injection; **B**, After contrast injection.

She underwent exploratory surgery where the catheter was reported to have emerged from the innominate vein through the anterior wall of the trachea. The port system was removed surgically, to evaluate for erosion by tumor. In addition, controlled removal of the catheter was essential for fistula repair and to prevent air embolism. Subsequently fistula repair was performed. Post-operative course was uneventful.

The fistula found between the innominate vein and the trachea is an extremely rare place due to the anatomical presence of innominate artery between the trachea and the vein. For that reason we tried to investigate the mechanism of this fistula especially that the catheter was made of silicone, a relatively softer catheter than the more rigid polyurethane catheter. When we compared the lateral view of the most recent chest x-rays and the ones done after placement of the catheter, we found that the tip of the catheter was migrating in a perpendicular angle to the coronal plan [Fig. 4]. A very unique way of migration, and this presumably led to a pressure necrosis by the catheter tip which in turn led to the fistula formation.

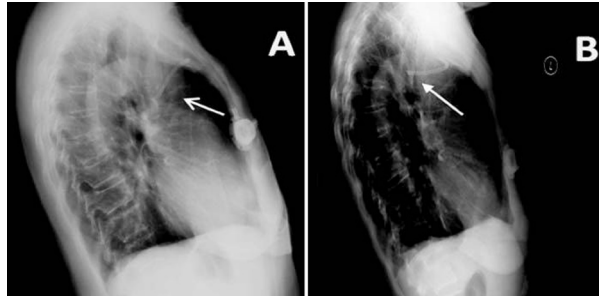


Figure 4. 64-year-old woman with implanted venous access device. **A**, Lateral chest radiograph after initial catheter placement; **B**, Lateral chest radiograph 8 months later shows that the tip of the catheter has migrated.

Discussion

Spontaneous migration, the late complication of totally implanted venous catheter devices after satisfactory initial placement, has been reported in very few cases. It also, has been associated with a number of complications; including neck pain, shoulder pain, ear pain, infection, venous thrombosis and neurological complications [4,5, and 6]. Some authors hypothesize that spontaneous retraction of the indwelling catheter is a result of the action of the underlying pectoralis muscle on the reservoir, or a "jetting effect" during flushing [7]. The catheter in many of the reported cases migrated toward the internal jugular vein [5, 8, and 9], which might be explained by this theory. However, in our case the migration happened in a different plan.

This complication can lead to devastating consequences, if not recognized early and managed appropriately. This report should raise an alert of these or similar complications, especially with the increase use of TIVAS to give chemotherapy. We suggest that it may be useful to perform chest x-ray in two views before using the catheter.

References

1. Biffi R, de Braud F, Orsi F, Pozzi S, Mauri S, Goldhirsch A, Nole F, Andreoni B. Totally implantable central venous access ports for long-term chemotherapy. A prospective study analyzing complications and costs of 333 devices with a minimum follow-up of 180 days. *Ann Oncol.* 1998 Jul; 9(7):767-73. [[PubMed](#)]
2. Sharpe PC, Morris TC. Complications associated with central venous catheters in hematology unit. *Ulster Med J.* 1994 Oct. 63(2):144-50. [[PubMed](#)]
3. Wong C, Joshi N, Nachimuthu S, Vaka G, Bakoss J. Cough in a patient with an infusion port. *Chest.* 2001 Sep;120(3):1031-3. [[PubMed](#)]
4. Poorter RL, Lauw FN, Bemelman WA, Bakker PJ, Taat CW, Veenhof CH. Complications of an implantable venous access device (Port-a-Cath) during intermittent continuous infusion of chemotherapy. *Eur J Cancer.* 1996 Dec, 32A (13):2262-6. [[PubMed](#)]
5. Wu PY, Yeh YC, Huang CH, Lau HP, Yeh HM. Spontaneous migration of a Port-a-Cath catheter into ipsilateral jugular vein in two patients with severe cough. *Ann Vasc Surg.* 2005 Sep, 19(5):734-6. [[PubMed](#)]

6. Bruninx G, Matte JC, VanWilder F, Delcour C. Catheter migration of a Port-a-cath system. *Cardiovasc Intervet Radiol*. 1996 Nov-Dec, 19(6):435-7. [[PubMed](#)]
 7. Meranze SG, Burke DR, Feurer ID, Mullen JL. Spontaneous retraction of indwelling catheters: previously unreported complications. *JPEN J Parenter Enteral Nutr*. 1988 May-Jun, 12(3):310-2. [[PubMed](#)]
 8. Collin GR, Ahmadinejad AS, Misse E. Spontaneous migration of subcutaneous central venous catheters. *Am Surg*. 1997 Apr, 63(4):322-6. [[PubMed](#)]
 9. Rasuli P, Hammond DI, Peterkin IR. Spontaneous intrajugular migration of long-term central venous access catheters. *Radiology*. 1992 Mar, 182(3):822-4. [[PubMed](#)]
-

This work is licensed under a [Creative Commons Attribution-NonCommercial-NoDerivs 2.5 License](#).