


# Progress of Tumor Growth and Metastasis After Inoculation of B16FO Melanoma Cells in Kidney of Female Nude Mice Is Inhibited by a Novel Nutrient Mixture

Integrative Cancer Therapies  
Volume 18: 1–8  
© The Author(s) 2019  
Article reuse guidelines:  
sagepub.com/journals-permissions  
DOI: 10.1177/1534735419832365  
journals.sagepub.com/home/ict  


M. Waheed Roomi, PhD<sup>1</sup>, Bilwa Bhanap, MD<sup>1</sup>, Aleksandra Niedzwiecki, PhD<sup>1</sup>, and Matthias Rath, MD<sup>1</sup>

## Abstract

**Background:** Tumor metastasis is a major cause for most cancer-related deaths. Melanoma is a serious cancer that metastasizes to other areas of the body, including the lungs, liver, brain, bones, or lymph nodes. Currently used cancer therapies are ineffective with a high degree of toxicity and patient mortality. Thus, any successful treatment for melanoma must target metastasis. **Methods:** We studied the effect of a novel nutrient mixture (NM) containing ascorbic acid, lysine, proline, green tea extract, quercetin, and others, on the inhibition of melanoma growth and metastasis after inoculation of B16FO melanoma cells into the left kidney of female nude mice. Female athymic mice ( $n = 10$ ) 8 to 10 weeks of age, were inoculated superficially in the left kidney with  $5 \times 10^5$  B16FO melanoma cells in 100  $\mu$ L of media. The right kidney was left untreated. After inoculation, the mice were randomly divided into 2 groups. The control group ( $n = 5$ ) was fed a regular rodent chow diet, and the test group was given the same diet supplemented with 0.5% NM. The animals in control and the test groups were sacrificed 2 weeks later. Each animal's abdominal cavity was opened, and the kidneys, lungs, liver, and spleen were excised and examined for tumor growth and metastasis. **Results:** The kidneys in the control group weighed 25% to 30% more than those in the NM group due to colonization of B16FO melanoma cells. No metastasis to the liver or spleen was observed in either of the groups. However, severe lung metastasis was observed in the control group and mild to moderate metastasis was observed in the NM group. **Conclusion:** These results show that the NM is effective in mitigating the growth of tumors in the kidney and metastases to the lung.

## Keywords

melanoma, B16FO, nutrient mixture, metastasis, tumor growth, female nude mice

Submitted August 30, 2018; revised January 22, 2019; accepted January 25, 2019

## Introduction

Melanoma is a serious cancer and its diagnosis rates have been rising for the past 30 years. Melanoma causes the majority of skin cancer-related deaths due to metastasis to other areas of the body such as the lymph nodes, lungs, liver, brain, or bones. Although often curable in its early stages, metastatic malignant melanoma is an extremely aggressive cancer with no current viable treatment.<sup>1</sup> According to the American Cancer Society's estimates for 2018, approximately 96 480 new melanoma cases will be diagnosed, and melanoma may cause approximately 7230 fatalities in the United States.<sup>2</sup> The estimated 5-year survival rate for early

stage melanoma is about 98%; however, the survival rate falls to 62% as the disease progresses to the lymph nodes, and to 18% when the disease metastasizes to distant organs.<sup>3</sup>

Metastatic malignant melanoma cells, specifically B16FO, have been successfully used for experimental metastasis to study the effectiveness of anticancer agents,

---

<sup>1</sup>Dr. Rath Research Institute, Santa Clara, CA, USA

### Corresponding Author:

Aleksandra Niedzwiecki, Oncology Division, Dr Rath Research Institute, 1260 Memorex Drive, Santa Clara, CA 95050, USA.  
Email: author@drrath.com



since melanoma cells are extremely aggressive and rapidly metastasize to secondary areas of the body such as the lymph nodes, lungs, liver, brain, or bones.<sup>4</sup> Hart and Fidler<sup>4</sup> studied the role of organ selectivity in the determination of metastatic patterns of B16FO melanoma cells and concluded that the outcome of metastasis was dependent on the tumor cell properties and host factors, thus supporting the “seed and soil” hypothesis to explain the nonrandom pattern of cancer metastasis. For example, although the circulatory mode of metastasis leads to the dissemination of a number of malignant cells, it cannot fully explain the patterns of distribution of numerous tumors, such as the infrequent metastatic development in the organs including the spleen, or skeletal muscle with its highly developed vasculature. Zeidman and Busso<sup>5</sup> reported in their study that tumor cells from different tumors interacted differently with the capillary bed of a given organ. Sugarbaker<sup>6</sup> found that tumor cell suspensions from different types of tumors injected into the same site in rats established different patterns of metastases. Experimental data have indicated that B16FO melanoma cells preferentially metastasize to specific organs, such as the lungs and liver.<sup>7,8</sup>

Since 90% of cancer deaths occur secondary to metastasis, any successful anticancer treatment must target the metastatic stage of cancer development. Critical events in tumor cell invasion include cell attachment, proteolytic degradation of the extracellular matrix (ECM), and migration through the disrupted matrix.<sup>9</sup> The high risk of metastasis makes melanoma difficult to treat and accounts for approximately 90% of deaths due to metastasized cancers. The metastatic cancer responds poorly to the common methods of cancer treatment such chemotherapy and radiation, or other treatments. Therefore, a successful treatment for cancer has become a challenge for oncologists. Rath and Pauling<sup>10</sup> proposed that the most effective and universal approach to controlling cancer is ensuring optimal synthesis and integrity of collagen, which is dependent on essential nutrients, such as vitamin C and lysine.

We selected naturally occurring nutrients such as lysine, proline, ascorbic acid, green tea extract, and quercetin to target cancer development. We then developed a nutrient mixture (NM) that has exhibited synergistic anticancer activity both in vivo and in vitro in a number of cancer cell lines through the inhibition of cancer cell growth, matrix metalloproteinases (MMPs) secretion, invasion and metastasis, and angiogenesis.<sup>11</sup>

In a previous study, we demonstrated that NM was effective in inhibiting the pulmonary metastasis of B16FO melanoma cells injected into the tail vein of C57BL/6 mice, especially when the NM was delivered intravenously or intraperitoneally.<sup>7</sup> We also demonstrated the effectiveness of dietary supplementation with NM to prevent experimental hepatic metastasis by studying its effects on the intrasplenic

injection of B16FO melanoma cells into athymic nude mice.<sup>12</sup> In this study, our main objective was to determine the effects of NM supplementation on the development of tumors and metastasis to other organs after orthotopic inoculation of B16FO melanoma cells in mice.

## Materials and Methods

### *Cancer Cell Line and Culture*

Murine B16FO melanoma cells obtained from ATCC (American Type Culture Collection, Rockville, MD, USA) were maintained in Dulbecco's modified Eagle's medium (DMEM) supplemented with 10% fetal bovine serum, 100 U/mL penicillin, and 100 µg/mL streptomycin. The media and sera used were obtained from ATCC, while the antibiotics (penicillin and streptomycin) were purchased from Gibco-BRL (Long Island, NY, USA).

### *Animals*

Female nude mice, approximately 8 to 10 weeks of age, were purchased from Simonsen Laboratories (Gilroy, CA, USA). The mice were kept in micro-isolator cages under pathogen-free conditions on a 12-hour light/dark schedule for 1 week. The animals were cared for in accordance with institutional guidelines for the care and use of experimental animals.

### *Animal Diet and the Composition of Nutrient Mixture*

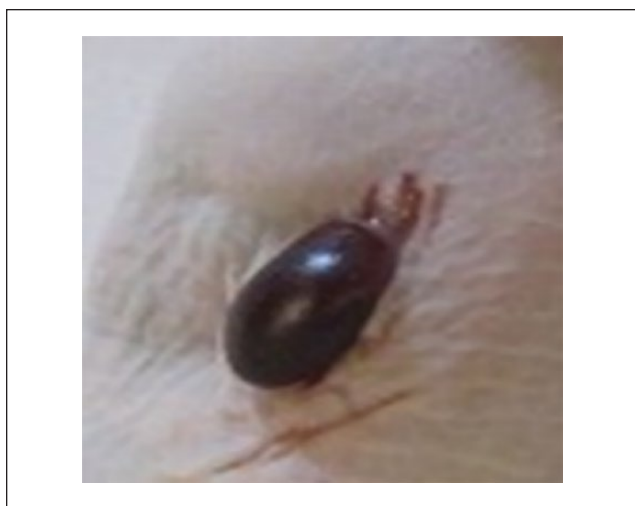
The regular rodent diet was obtained from Purina Mills (Gray Summit, MO, USA). The 0.5% NM supplemented diet mix was milled and pressed by Purina Mills LLC, and generated by Vitatech (Tustin, CA, USA). The 0.5% NM diet was composed of the ratio indicated in Table 1.

### *Experimental Design*

After housing for one week female athymic mice ( $n = 10$ ), 8-10 weeks of age, were anesthetized by inhalation utilizing isofluorane USP (Abbott Laboratories, Chicago, IL, USA). As shown in Figure 1, the back overlying the kidney was sterilized and a skin incision of 1 cm was made to expose the kidney. Mice were inoculated superficially in the left kidney with  $5 \times 10^5$  B16FO melanoma cells in 100 µl of PBS, while the right kidney was left untreated. The skin was sutured and clamped. After inoculation, the mice were randomly divided into 2 groups. The control group ( $n = 5$ ) was fed regular Purina rodent chow diet, while the mice in the 0.5% NM group ( $n = 5$ ) were fed the same diet but supplemented with 0.5% NM. During the study the mice consumed, on the average, 4 g of their respective diets per day.

**Table 1.** Nutrient Composition of Nutrient Mixture (NM).

Components of NM	Weight (mg)
Vitamin C (as ascorbic acid, Mg and Ca ascorbate and ascorbyl palmitate)	700 $\mu$ M
L-Lysine	1000
L-Proline	750
L-Arginine	500
N-Acetyl cysteine	200
Standardized green tea extract EGCG (epigallocatechin gallate) (80% polyphenol)	1000
Selenium	30
Copper	2
Manganese	1
Quercetin dihydrate	50

**Figure 1.** Left kidney exposed. Inoculation of B16FO cells in the exposed kidney in female nude mouse.

Thus, the supplemented mice received ~20 mg of 0.5% NM per day.

Two weeks later the mice were sacrificed, the abdominal cavity of each animal was opened and the kidneys, liver, spleen and hearts were excised from each animal and examined. Growth of B16FO melanoma colonies in kidney was evaluated by visualizing sectioned tissue and the vital organs were examined for metastasis. All procedures were performed according to humane and customary care and use of experimental animals and conducted under protocols approved by the Internal Animal Care and Use Committee (IACUC).

### Histopathology

The kidney samples were fixed in 10% buffered formalin, embedded in paraffin and cut into 4- to 5- $\mu$ m sections. The sections were deparaffinized through xylene and graduated

alcohol series to water and stained with hematoxylin and eosin for microscopic evaluation by IDEXX Reference Laboratories.

## Results

### Mean Initial and Final Weights of the Animals

The body weight of the mice in both the groups did not differ significantly. Before the experiment, the animals in the control group weighed  $30.2 \pm 1.02$  g at the time of inoculation, and  $30.6 \pm 1.0$  g at the time of sacrifice after the experiment. Similarly, the animals in the NM group weighed  $30.06 \pm 0.9$  g before the experiment and  $28.08 \pm 0.81$  g after the experiment (Figure 2).

### Tumor Morphology

The abdominal cavity of each mouse was opened and the kidneys, lungs, liver, spleen, and heart were excised. The metastasis to other vital organs, such as the liver, spleen and the lungs, were visually examined. The mice in the control group showed significant tumor development in the left kidney by B16FO melanoma cells compared with the 0.5% NM group. The weight of the left kidney in the control group ( $0.67 \pm 0.05$  g) was about 25% to 30% higher than the kidney in the NM treated mice ( $0.50 \pm 0.02$  g),  $P < .001$  (Figure 3).

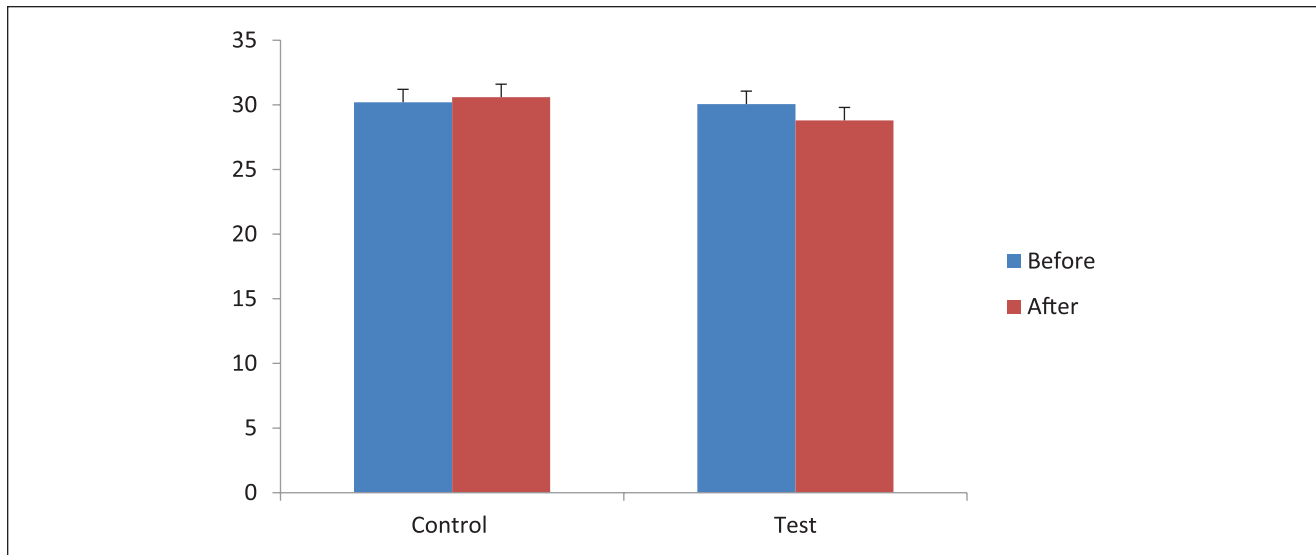
### Metastasis in Vital Organs

There was no metastasis was seen to the liver, the heart, and the spleen in either of the groups. Extensive lung metastasis was observed in all mice in the control group; however, only mild metastatic foci were seen in the 0.5% NM group (Figure 4A and B, respectively).

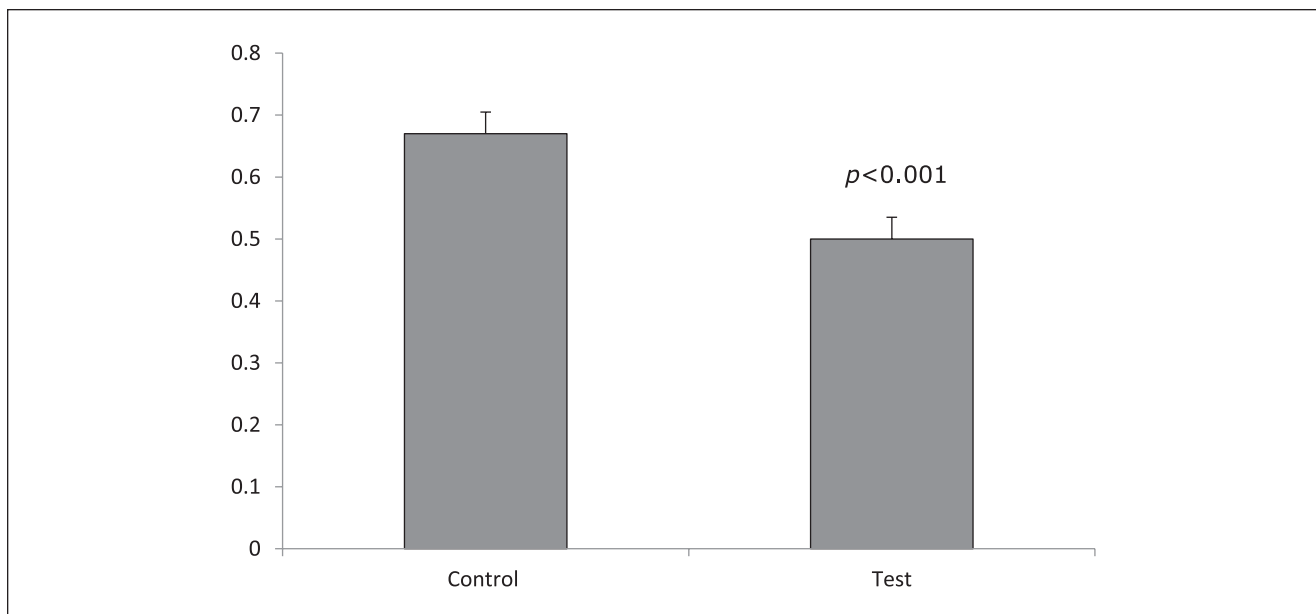
### Tumor Histopathology

Cross sections of the left kidney from the control group showed multiple large pigmented melanoma growth occupying approximately 60% of the kidney and significant destruction of the kidney tissue. The NM group showed similar histology as that of control group; however, the changes were less severe and approximately 25% of the kidney was seen to be affected by melanoma, as seen in Figure 5A and B.

Histological examination of the tumor in the control group showed large areas of necrosis involving a majority of the left kidney. Extensive growth of B16FO melanoma cells was seen in the cortico-medullary area and attached to the renal capsule. They consisted of nests and sheaths of irregularly round cells with prominent nuclei and presence of pigment consistent with melanoma. The details of the



**Figure 2.** Comparison of body weight of the animals in grams.



**Figure 3.** Comparison of the weight of kidneys (in grams) in the control and the test group of mice ( $P < .001$ ).

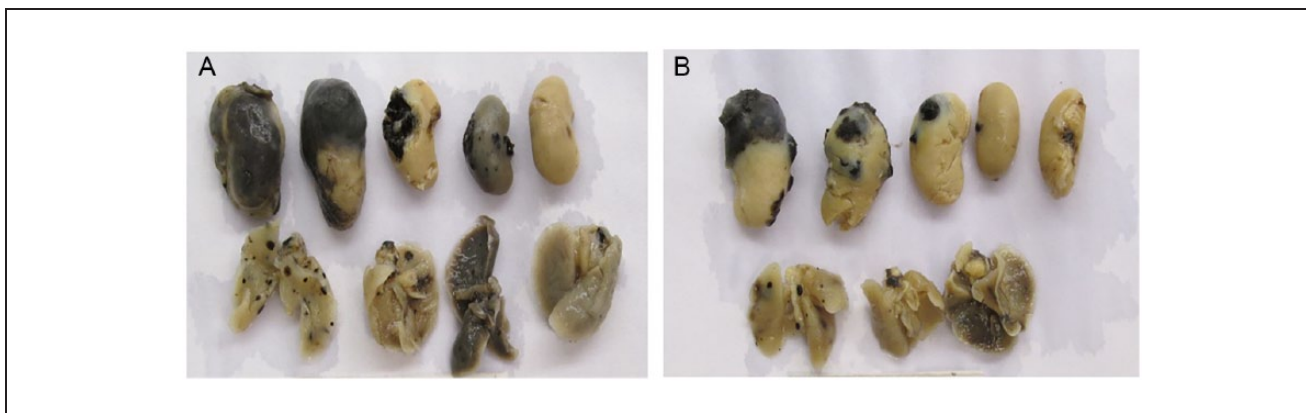
extent of metastasis of melanoma cells can be clearly seen at different magnifications as shown in Figure 6A-D.

The morphology of the tumors in the NM group was similar to that of the control group, but with smaller areas of necrosis, as seen in Figure 6E-H.

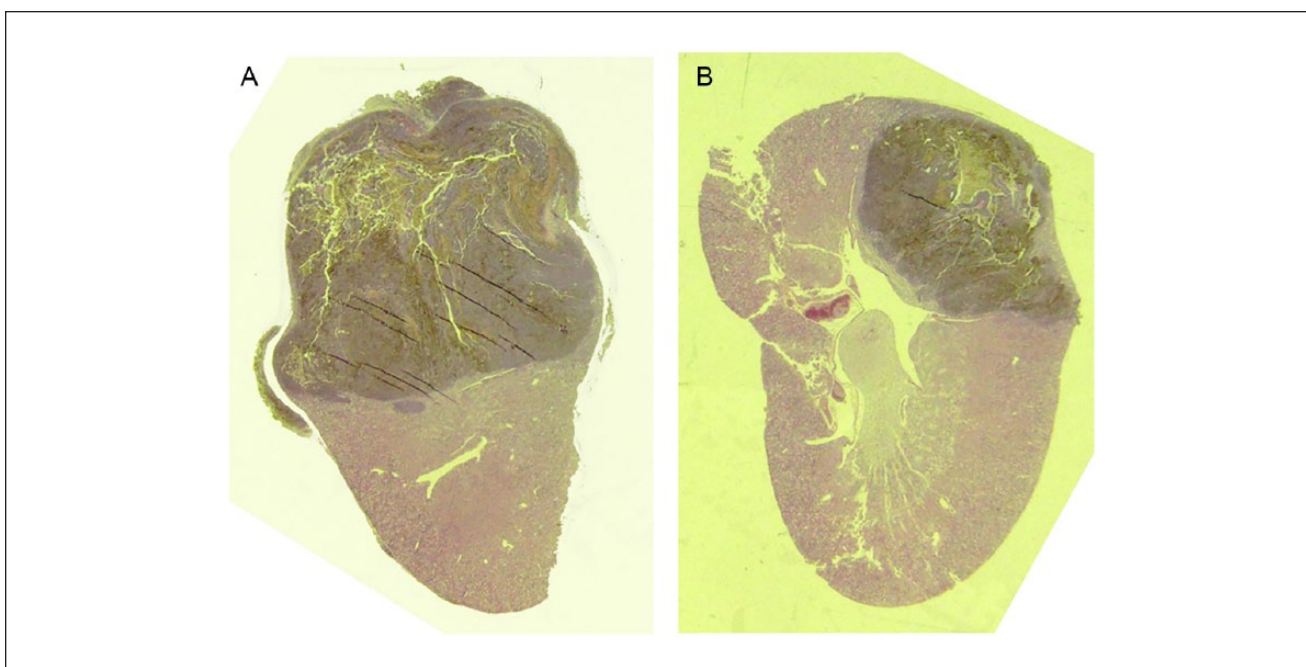
## Discussion

Tumor metastasis is a major reason for treatment failure in cancer patients. There is currently no effective treatment to

block metastasis and any further studies in this area, especially those using nontoxic approaches, would dramatically improve patient prognosis. Metastatic malignant melanoma is an extremely aggressive cancer with no current viable therapy. The aim of this study was to investigate the effect of an NM on B16FO melanoma growth and metastasis from inoculation in left kidney of nude mice, representing the vascular dissemination of melanoma. In our study, supplementation with the NM suppressed B16FO melanoma cell growth in the left kidney and its metastasis to the lungs.



**Figure 4.** Visual comparison of metastatic areas in vital organs (kidney, lungs, spleen) after B16FO inoculation in nude mice. (A) Organs from control group. (B) Organs from nutrient mixture (NM) group.



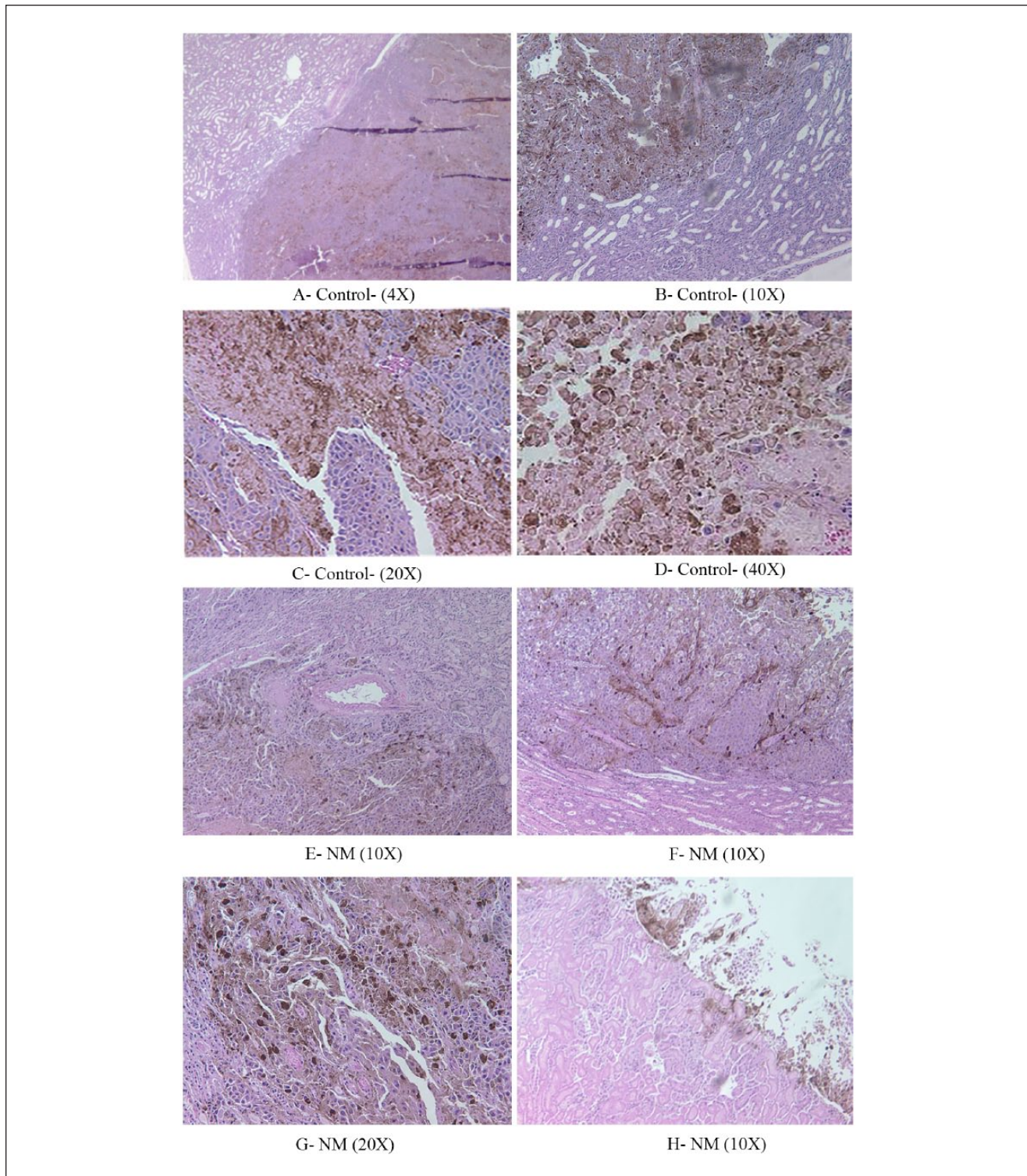
**Figure 5.** Colonization and tumor formation of B16FO cells as seen in the kidney of female nude mice. (A) Cross section of kidney in control group. (B) Cross section of kidney in nutrient mixture (NM) group.

The results of this study demonstrated a significant decrease in the tumor growth in the left kidney and inhibition of metastatic potential in the test group supplemented with NM. All the animals receiving the control diet exhibited extensive metastasis to the lungs, in contrast with mild to moderate metastases in the mice receiving the NM 0.5% diet. No metastases to the liver, heart, and spleen were observed in either of the groups. NM inhibited metastasis to the lungs compared to control mice. Notably, the melanoma cells invaded and developed tumors in the left kidney and metastasized to the lungs from the left kidney (the injection

site of B16FO melanoma cells) but did not metastasize to the right kidney, which was left untreated.

High consumption of fruits and vegetables have been reported to be associated with prevention, inhibition, and reversal of cancers.<sup>13,14</sup> We have developed strategies to inhibit cancer development and its metastasis by targeting common mechanisms used by the cancer cells to invade and migrate throughout the body.<sup>12</sup>

The NM formulation was based on addressing critical physiological targets in cancer progression and metastasis. Adequate supplies of ascorbic acid, lysine, and proline are



**Figure 6.** Tumor histopathology in kidney after B16FO cells inoculation of female nude mice in (A-D) control group (A, 4 $\times$ ; B, 10 $\times$ ; C, 20 $\times$ ; D, 40 $\times$ ) and (E-H) nutrient mixture (NM) group (E, 10 $\times$ ; F, 10 $\times$ ; G, 20 $\times$ ; H, 10 $\times$ ).

essential to ensuring optimal structure of the ECM and, lysine supports ECM stability as a natural inhibitor of plasmin-induced proteolysis.<sup>10</sup> The anticancer effects of

quercetin include induction of cell cycle arrest and apoptosis.<sup>15</sup> In our other studies, we have shown that the addition of quercetin significantly increased the anticancer

efficacy of green tea extract and reduced mammary tumors in Wistar rats.<sup>16</sup>

In our previous in vitro studies we have shown that NM significantly inhibited secretion of the matrix metalloproteinases (MMP-2 and MMP-9) and Matrigel invasion by melanoma and other cancer cells.<sup>17</sup> We also demonstrated significant inhibition of cell proliferation and induction of apoptosis of B16FO melanoma cells at 500 µg/mL NM, suggesting that inhibition of tumor growth was due to the multi targeted action of NM.<sup>18</sup>

Our in vivo studies we have shown that intravenous injection of melanoma cells into C57BL/6 mice resulted in pulmonary metastasis, providing an excellent model to assess test agents on metastasis.<sup>7</sup> In another of our studies with intrasplenic injection of B16FO melanoma cells in mice supplemented with NM, our results showed greater reduced tumor growth in the spleen than in the control group. The NM group also showed drastically reduced metastasis to the liver.<sup>12</sup> Moreover, we have observed that subcutaneous injection of B16FO melanoma cells into C57BL/6 mice induced intraperitoneal growth and ascites.<sup>19</sup>

Additionally, we have also demonstrated that the supplementation with dietary NM significantly suppressed murine B16FO melanoma tumor growth in immune-impaired (athymic) mice.<sup>20</sup> These findings correlate with our other in vivo findings that exposure of melanoma cells for 18 hours to NM before injecting them into mice completely prevented the formation of metastatic lung tumor modules.<sup>7</sup>

In general, any cancer metastases to the kidneys are rather rare. However, while metastases of malignant melanoma to the kidneys were not evident clinically, they were detected at autopsy and present in a form of multiple cortical nodules, not as a renal mass. There have been seven cases reported of secondary renal melanoma with renal cell carcinoma as its origin, and cases of renal melanoma of unknown origin.<sup>21-25</sup> In addition, the clinical case of melanoma present as a renal mass was reported by Tasdemir et al<sup>26</sup> in 2011. The case of a primary renal malignant melanoma mass was also reported.<sup>27</sup> The origins of such tumors are rather obscure because the kidneys do not have melanocytes, therefore they may originate from migrating precursor cells from other organs.

Although melanomas rarely metastasize to atypical locations, Trout et al<sup>28</sup> reported that 14% of patients had atypical locations of melanoma metastases as seen on computed tomography scans. They reported that autopsies and pathological reports indicate that kidney metastases could be present in 35% to 48% of the cases.<sup>28</sup>

Currently the early-stage melanoma 5-year survival rate is more than 98%; however, this rate drastically decreases to 18% with the metastasized melanoma. Although several factors contribute to the prognosis and survival of a patient, nonavailability of a safe and successful method for treatment of metastatic cancer is a major roadblock in progress. In our

in vivo studies, we examined the safety of NM and found that the NM neither had any adverse effects on vital organs (heart, liver, and kidneys) nor did it affect the associated functional serum enzymes.<sup>29</sup> This indicates that this NM mixture is safe to use even at these high doses, which far exceed the normal equivalent dosage of a single nutrient.

In conclusion, the results of the present study have shown that the nutrient mixture was effective in significantly reducing B16FO melanoma cell tumor growth in the left kidney and metastasis to the lungs in female nude mice. These findings, together with our earlier results, indicate the anticancer potential of NM.

### Acknowledgments

We thank Ms. Catherine Flowers for her assistance in proofreading this article.

### Declaration of Conflicting Interests

The author(s) declared no potential conflicts of interest with respect to the research, authorship, and/or publication of this article.

### Funding

The author(s) disclosed receipt of the following financial support for the research, authorship, and/or publication of this article: The research study was funded by Dr Rath Health Foundation (Santa Clara, CA), a nonprofit organization.

### References

1. Fidler IJ. Critical factors in the biology of human cancer metastasis: twenty-eighth GHA. Clowers Memorial Award Lecture. *Cancer Res.* 1990;50:6130-6138.
2. American Cancer Society. Key statistics for melanoma skin cancer. <https://www.cancer.org/cancer/melanoma-skin-cancer/about/key-statistics.html>. Accessed February 4, 2019.
3. American Cancer Society. *Cancer Facts and Figures 2017*. Atlanta, GA: American Cancer Society; 2017.
4. Hart IR, Fidler IJ. Role of organ selectivity in the determination of metastatic patterns of B16 melanoma. *Cancer Res.* 1980;40:2281-2287.
5. Zeidman I, Busso JM. Transpulmonary passage of tumor cell emboli. *Cancer Res.* 1952;12:731-733.
6. Sugarbaker ED. The organ selectivity of experimentally induced metastases in rats. *Cancer.* 1952;5:606-612.
7. Roomi MW, Roomi N, Ivanov V, Kalinovsky T, Niedzwiecki A, Rath M. Inhibition of pulmonary metastasis of melanoma B16FO cells in C57BL/6 mice by a nutrient mixture consisting of ascorbic acid, lysine, proline, arginine, and green tea extract. *Exp Lung Res.* 2006;32:517-530.
8. Gheorghesu D, Dehelean C, Cristea M, Muntean D. Development of the B16 murine melanoma model. *Ann Rom Soc Cell Biol.* 2011;16:148-152.
9. De Vita VT, Hellman S, Rosenberg SA. *Cancer: Principles and Practice of Oncology*. 5th ed. Philadelphia, PA: Lippincott-Raven; 1997:135-152.

10. Rath M, Pauling L. Plasmin-induced proteolysis and the role of apoprotein(a), lysine and synthetic analogs. *Orthomol Med.* 1992;7:17-23.
11. Niedzwiecki A, Roomi MW, Kalinovsky T, Rath M. Micronutrient synergy—a new tool in effective control of metastasis and other key mechanisms of cancer. *Cancer Metastasis Rev.* 2010;29:529-542.
12. Roomi MW, Kalinovsky T, Roomi NW, Monterrey J, Rath M, Niedzwiecki A. A nutrient mixture suppresses hepatic metastasis in athymic nude mice injected with murine B16FO melanoma cells. *Biofactors.* 2008;33:181-189.
13. Aldercreutz H. Western diet and Western diseases: some hormonal and biochemical mechanisms and associations. *Scand J Clin Lab Invest Suppl.* 1990;201:3-23.
14. Miller AB, Diet and cancer. A review. *Acta Oncol.* 1990;29:87-95.
15. Gibellini L, Pinti M, Nasi M, et al. Quercetin and cancer chemoprevention. *Evid Based Complement Alternat Med.* 2011;2011:591356.
16. Kale A, Gawande S, Kotwal S, et al. A combination of green tea extract, specific nutrient mixture and quercetin: an effective intervention treatment for the regression of *N*-methyl-*N*-nitrosourea (MNU)-induced mammary tumors in Wistar rats. *Oncol Lett.* 2010;1:313-317.
17. Roomi MW, Monterrey JC, Kalinovsky T, Rath M, Niedzwiecki A. Inhibition of invasion and MMPs by a nutrient mixture in human cancer cell lines: a correlation study. *Exp Oncol.* 2010;32:243-248.
18. Roomi MW, Kalinovsky T, Niedzwiecki A, Rath M. Anticancer effects of a micronutrient mixture on melanoma: modulation of metastasis and other critical parameters. In: Tanaka Y, ed. *Breakthroughs in Melanoma Research.* London, England: InTechOpen; 2011.
19. Roomi MW, Kalinovsky T, Roomi NW, Monterrey J, Rath M, Niedzwiecki A. Suppression of growth and hepatic metastasis of murine B16FO melanoma cells by a novel nutrient mixture. *Oncol Rep.* 2008;20:809-817.
20. Cha J, Roomi MW, Ivanov V, Kalinovsky T, Niedzwiecki A, Rath M. Ascorbate supplementation inhibits growth and metastasis of B16FO melanoma and 4T1 breast cancer cells in vitamin C-deficient mice. *Int J Oncol.* 2013;42:55-64.
21. Fujimoto H, Chitose K, Tobisu K, Yamazaki N, Sakamoto M, Kakizoe T. Solitary renal melanoma? A case with long survival after initial treatment. *J Urol.* 1995;153:1887-1889.
22. Frasier BL, Wachs BH, Watson LR, Tomasulo JP. Malignant melanoma of the renal pelvis presenting as a primary tumor. *J Urol.* 1988;140:812-814.
23. Tajima K, Saito K, Umeda Y, Murata T, Satani H. Malignant melanoma of the kidney presenting as a primary tumor. *Int J Urol.* 1997;4:94-96.
24. Shimko MS, Jacobs SC, Phelan MW. Renal metastasis of malignant melanoma with unknown primary. *Urology.* 2007;69:384.e9-e10.
25. Perdonà S, Di Trolio R, Di Lorenzo G, Autorino R. A case of renal melanoma metastasis: description of clinico-pathological features. *Arch Ital Urol Androl.* 2007;79:161-163.
26. Tasdemir C, Turkmen Samdanci E, Dogan M, Elmali C, Yasar Sargin S. Primer malignant melanoma of kidney: a case report. *Eur Rev Med Pharmacol Sci.* 2011;15:971-972.
27. Liapis G, Sarlanis H, Poulaki E, Stravodimos K, Riccioni O, Lazaris AC. Primary malignant melanoma of renal pelvis with extensive clear cell change. *Cureus.* 2016;8:e583. doi:10.7759/cureus.583
28. Trout AT, Rabinowitz RS, Platt JF, Elsayes KM. Melanoma metastases in the abdomen and pelvis: frequency and patterns of spread. *World J Radiol.* 2013;5:25-32.
29. Roomi MW, Ivanov V, Netke SP, Niedzwiecki A, Rath M. Serum markers of the liver, heart, and kidney and lipid profile and histopathology in ODS rats treated with nutrient synergy. *J Am Coll Nutr.* 2003;22:477.