

The scope of the dermoscope

One of the questions which usually comes up whenever dermoscopy is discussed in workshops in India, among those new to the concept, is something along the lines of “I have a good magnifying lens with inbuilt LED lights...why do I need a dermoscope?”

The dermoscope is not just a glorified hand lens with lighting. When we look at a skin lesion with a magnifying loupe with lighting, most of the light is scattered due to the reflective property of the stratum corneum. There are two ways to overcome this problem so as to allow more light to pass through the stratum corneum, enabling us to look deeper into the skin to visualize the pigment and vascular patterns among other things [Figure 1a]. One is by using a fluid medium as an interface and a transparent glass contact plate [Figure 1b] and the other is by using a cross polarized light [Figure 1c]. Most newer dermoscopes come with an option of polarized light allowing both contact and noncontact dermoscopy.

HISTORY

Various terms have been used to describe the process of dermoscopy, namely, dermatoscopy, surface microscopy, incident light microscopy, and epiluminescence light microscopy. The term “dermoscopy,” which is the most accepted now, was first suggested by Friedman *et al.*^[1]

Skin surface microscopy for pigmented lesions was initially described in the first half of the 20th century based on earlier work done on colposcopy for visualization of the cervical region.^[2] A couple of decades later, the use of oil-immersion fluid as an interface to improve skin surface visualization and the use of the same for diagnosis of pigmented lesions was described.^[3] Large dedicated dermoscopic devices were first used in the late 1980s, and hand-held devices started to be developed for the same in the early 1990s. Clear criteria for use in the diagnosis of pigmented lesions started developing around the same time.^[4,5]

Work in the area of dermoscopy has increased exponentially over the last couple of decades. A Medline search with the

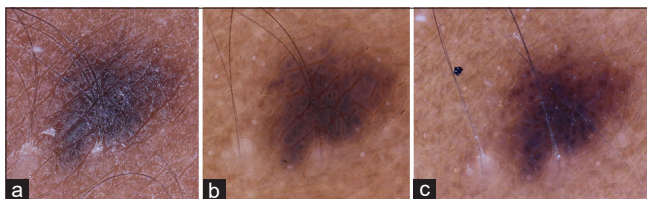


Figure 1: (a) Normal macro image; (b) contact dermoscopy; (c) polarized light dermoscopy – DermLite Foto II pro – The macro image does not capture the globular pattern suggestive of a benign melanocytic nevus in a child

key words “dermoscopy,” “dermatoscopy,” “trichoscopy,” and “epiluminescence microscopy” reveals more than 3500 results at present, most being published in the last decade. There is an active International Dermoscopy Society (IDS) which at present offers free membership (<http://dermoscopy-ids.org/>) and also conducts regular conferences and multicentre studies in the field of dermoscopy. The IDS also conducts the world dermoscopy congresses, the next one (the fifth one) will be held in Greece in June 2018 (<http://dermoscopy-congress2018.com/site>). Sessions and workshops on dermoscopy have also become a routine part of general dermatology conferences.

Which instrument should I use? Another question that often comes up related to dermoscopy in the Indian context is regarding choosing an ideal dermoscope. A number of factors need to be taken into account, namely, quality, budget, need for documentation, and even the major types of cases that you see. The most commonly used dermoscopes are the independent hand-held units (these do not need to be connected to a monitor to visualize skin lesions), which usually have a magnification of around $\times 10$ to $\times 20$. The same can be used to take photographs by connecting them with cameras – smart phone cameras, point



Figure 2: Using screw-on adapters to connect cameras to hand-held units

and shoot as well as digital SLRs, using adapters [Figure 2]. There are discernible differences in the quality of images depending on both the device and the camera used, especially if the image has to be cropped or magnified [Figure 3]. There is always an option of simply placing the lens of the point and shoot camera directly over the viewing area of the dermoscope and shooting, however, the disadvantage is that both hands are required to produce a good quality image [Figure 4]. The other category of dermoscopes are ones that need to be connected to a viewing monitor, usually with a USB connection. A larger view is obtained which can also be shared with the patients, if needed, for counselling purposes and images can be stored easily. There are a large number of options, with the cost increasing according to the quality of the lens, lighting system, and other specific features [Table 1]. High quality video dermoscopes are limited by their high cost and are usually restricted to research centres. Similarly, whole body mapping systems and advanced serial image capturing dermoscopy systems can be quite expensive (an example is the Fotofinder® Dermoscope studio). Low cost alternatives include using devices such as microscope eye pieces and jeweller's loupes. However the quality of the imaging in these devices are far less than standard dermoscopes.^[6,7]

Before deciding on a dermoscope, it is recommended to actually get a feel of the different available devices (besides, of course, asking the opinion of those more experienced in dermoscopy). Polarized light dermoscopy has the advantage of better visualization of vascular structures as compression with the contact plate is avoided. However, some structures such as milia-like cysts and crypts (seen in seborrheic dermatitis) and the blue-white veil seen in melanoma are better seen with contact dermoscopy compared to polarized light dermoscopy. For dermoscopy, in general dermatology (including trichoscopy), polarized light alone is good enough in most cases. Polarized light dermoscopy also avoids the rare but definite possibility of cross infection from the contact plate when visualizing infectious dermatosis. The use of disposable contact caps, food wraps, adhesive tapes, and using 70% ethanol as the interface fluid help to avoid cross infection in contact dermoscopy.^[8] Multispectral dermoscopes and UV dermoscopes enable better visualization of specific structures, for example, surface pigmentation is better viewed under blue light, superficial

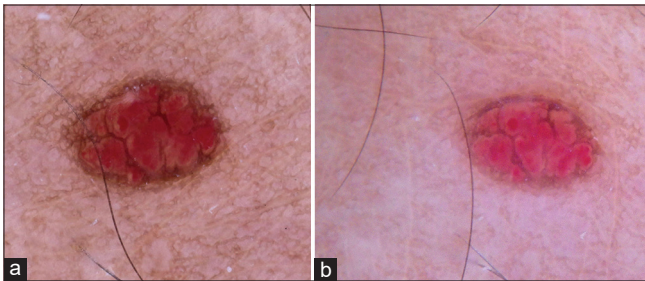


Figure 3: Small cherry angioma: (a) Digital SLR – DermLite® Foto II pro, (b) Point and shoot camera attached to a DermLite® Pro II HR (both polarized light)

vascularity under yellow light, and deeper pigmentation and vascularity with red light which penetrates deeper [Figure 5].

For a beginner, a relatively good quality hand-held, independent device with both contact dermoscopy and cross polarized light options might be the best option.

How do I train in dermoscopy? As in any other area related to clinical medicine, the key is practice. Keep using your dermoscope for as many skin lesions as possible. Try to correlate what you see with the histopathology in cases where histopathology is available. Remember that to understand what is abnormal you need to be really familiar with what is normal. So, keep looking at normal skin, hair, and nails. Try to familiarize with patterns that might be different according to site, age, or race. In the Indian context, you will not be able to see too many cases for which dermoscopy has been classically described and established (such as melanoma). Hair disorders (trichoscopy), nail disorders (onychoscopy), inflammatory dermatosis (inflammoscopy), infectious dermatoses, infestations, and disorders of pigmentation are likely to be the areas which you need to focus on. It should also be mentioned that, in many cases in general dermatology, you may not really need dermoscopy for diagnosis *per se*, but it may still be useful in evaluating other parameters such as disease activity or prognosis and to avoid unnecessary investigations [Figures 6-8].^[9-11] It is a



Figure 4: Taking dermoscopic images by placing the extended camera lens over the eyepiece end of the dermoscope

Table 1: Common models/brands of dermoscopes with specific features

Model	Manufacturer	Cross polarized light	Normal nonpolarized light	Other features
Dermlite DL100	3 Gen®	Yes	Yes	Very handy, relatively lower cost, no adapters for camera attachments
Dermlite II hybrid M	3 Gen®	Yes	Yes	Adapter for cameras/smart phones supplied. Has built-in threaded connection (cameras require the use of stepping rings and or adapters)
Dermlite DL3N	3 Gen®	Yes	Yes	Same as above
Dermlite DL4	3 Gen®	Yes	Yes	Magnetic face plate and eye-piece, magnetic connection system for smart phones, icecap™ disposable caps for infection control
Dermlite Cam®	3 Gen®	Yes	Yes	Intended for digital dermoscopy with an integrated 5 MP camera with LCD screen and touch panel
Dermlite Foto II pro	3 Gen®	Yes	Yes	Intended for digital dermoscopy- attaches to standard Nikon or Canon SLR cameras for high quality imaging
VEOS HD1	Canfield®	Yes	No	Snap on magnetic contact glass plate for immersion fluid dermoscopy, optional iPhone® integration sleeve
VEOS HD2	Canfield®	Yes	Yes	Same as above
VEOS DS3	Canfield®	Yes	Yes	Intended for digital dermoscopy with a mobile device. Embedded iPod® touch and imaging software.
VEOS SLR	Canfield®	Yes	Yes	Only available as with an integrated, calibrated Canon SLR
Handyscope	Fotofinder®	Yes	Yes	Intended for digital dermoscopy with a mobile device. Can be attached to iPhone/iPod®
Delta 20T	Heine®	Yes	Yes	Additional accessories available for connection to standard digital cameras including SLRs
NC1	Heine®	Yes	Yes	Additional accessories available for connection to standard digital cameras including SLRs
Mini 3000	Heine®	No	Yes	No adapters for digital cameras
iC1	Heine®	Yes	Yes	Intended for digital dermoscopy with a mobile device. Can be attached to iPhone/iPod, dedicated app available for same.
DE 300/350	Firefly®	Yes	Yes	Intended for digital video dermoscopy with an external monitor (USB connection). Wireless connectivity is available for DE 350. Dedicated software is supplied
DermaScope (different models available)	Dino-lite®	Yes	Yes	Intended for digital video dermoscopy with an external monitor (USB connection)
TLS ultracam	DermaIndia	Yes	Yes	Intended for digital video dermoscopy with an external monitor (USB connection). Has an additional UV light option

Note: We have referred a lot of latest available literature on the subject and utmost care has been taken to ensure the correctness and authenticity of the information provided in this article. We do not have affiliation to any manufacturer or developer (software or hardware), and we shall not be responsible for any consequences thereof. The readers are requested to thoroughly screen the information and look for reviews prior to investing on resources for their clinical purposes. Further, details for the above devices can be obtained through the manufacturer websites

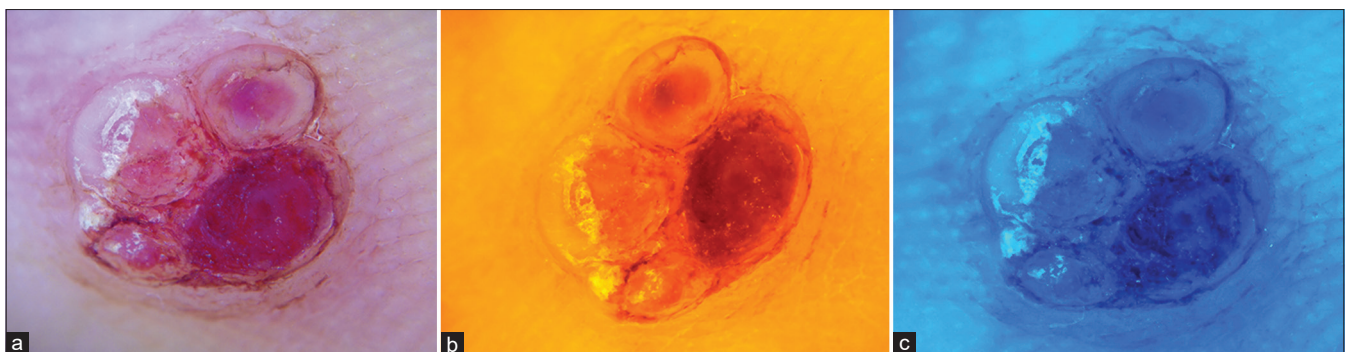


Figure 5: Multispectral dermoscopy of pyogenic granuloma (dermlite multispectral 10X) (a) White light (b) Yellow light (c) Blue light

good idea to take pictures of as many cases as possible so that they can be discussed with others, if necessary, and also in case

of planning for publication and presentation. While documenting dermoscopic image, do not forget to take a good quality clinical

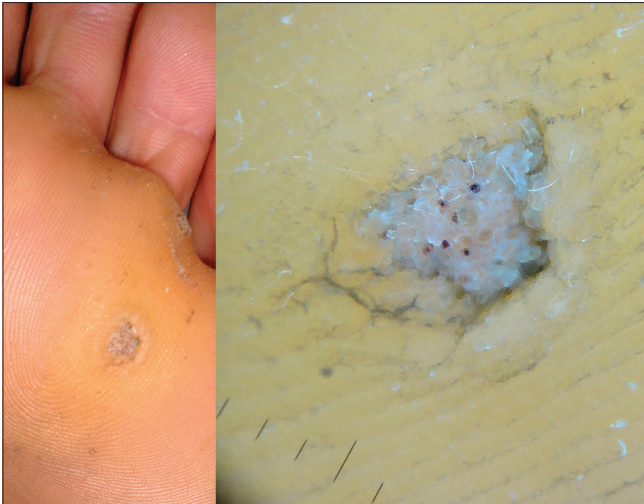


Figure 6: Dermoscopy of plantar wart (Dermlite pro II HR 10× polarized light) showing thrombosed vessels and loss of dermatoglyphics



Figure 7: Onychoscopy (dermoscopy of the nails) in white superficial onychomycosis showing pseudoluekonichia and patches with a yellowish hue (Dermlite pro II HR - polarized light 10X)

image. Also, try to use the in-built measuring scale available in most units to give an idea of the size of the lesion. In case you are thinking of publishing or presenting your case, always make it a point to clearly label the relevant dermoscopic findings using arrows or circles with a color that has sufficient contrast compared to the background, and also while describing dermoscopy images, try to explain the correlation of the dermoscopic picture with the histopathology whenever possible.

Discussion of the details of algorithms for dermoscopy, pigmented lesions or otherwise, is beyond the scope of this article, but for new entrants into the field of dermoscopy, it would be recommended to understand the basic principles and algorithms related to the dermoscopy of pigmented lesions in the context of diagnosis of melanoma. New entrants into dermoscopy should be familiar, if not competent, in algorithms such as the ABCD rule, the Menzies method, the 7-point checklist, the 3-point checklist, chaos and clues, and CASH (color, architecture, symmetry,

and homogeneity).^[12] These have higher grades of evidence as compared to dermoscopy in general dermatology, which is mainly based on lesser quality of evidence.^[13,14] There are some online tutorials – both formal and informal – which can help you get started on dermoscopy (Some examples include: <http://dermoscopy-ids.org/education-elearning/tutorials/>, <http://www.meduni-graz.at/IDD/general.html>, <http://www.dermnetz.org/doctors/dermoscopy-course/>, <http://www.cardiff.ac.uk/learn/training/courses/school-of-medicine/an-introduction-to-dermoscopy/>, <http://www.skincancercollege.org/course/diploma-dermoscopy/>), but as mentioned, most of the formal programs have a primary focus on the early diagnosis and triage of melanoma rather than on dermoscopy in general dermatology.

There are also quite a few other books and atlases which can help to become familiar with dermoscopic patterns in general dermatology (details), and of course newer descriptions of dermoscopy of inflammatory dermatosis continue to appear in dermatology journals regularly. There are some journals (such as *Dermatology Practical and Conceptual*) which have a significant focus on dermoscopy and many top dermatology journals now have sections dedicated to dermoscopy. IDOJ has also taken a proactive step to encourage the establishment of clear criteria for the use of dermoscopy in general dermatology by starting a dedicated section for the same “Through the dermoscope” (detailed Instructions are available at: <http://www.idoj.in/contributors.asp>).

Most of dermoscopy literature revolves around the early diagnosis and triage of cutaneous malignancies, mainly melanoma. While using dermoscopy for general dermatology, one limitation is that there are very few established algorithms available, especially for inflammatory disorders and infections. Usually, the dermatologists has a list of differential diagnosis based on the clinical morphology. Dermoscopic patterns of each of these differentials would have to be reviewed to arrive at a definite conclusion.

However, over the recent years, there has been a considerable build up of literature related to the use of dermoscopy in general dermatology. This is especially true in the case of trichoscopy.

In effect, dermoscopy can be used for any skin lesion. Clear criteria and dermoscopic patterns have been established for conditions such as melanoma/melanocytic nevi, basal cell carcinoma, seborrheic keratosis, squamous cell carcinoma (including Bowen’s disease), and many more benign skin tumors. Dermoscopy of the hair (trichoscopy) is another area which has seen a lot of work being done in the recent past. Trichoscopic criteria for localized and diffuse hair loss have been described.^[15,16] The most important parameters that should be assessed when applying dermoscopy in general dermatology include morphological vascular patterns, arrangement of vascular structures, colors, and follicular abnormalities (where relevant)—and the presence of other specific features (clues).



Figure 8: Trichoscopy-presence of exclamation mark hairs (black arrow) and black dots (cadaverized hairs-white arrow) suggest active alopecia areata (Dermlite foto ii pro - polarized light mode)

Newer studies on dermoscopic findings in inflammatory skin diseases such as psoriasis findings are being published regularly and some of these are clearly established now, for example, the regularly arranged dotted vessels in psoriasis.^[13] However, it would still take a lot more well-designed studies with good sample sizes to establish usable criteria for dermoscopy in inflammatory dermatosis especially considering specific skin types as among the Indian population.

Dermoscopy is a relatively young, dynamic, and exciting field. The dynamic nature is especially true for dermoscopy in general dermatology as newer patterns continue to be described on a regular basis. We hope that the "through the dermoscope" section of this journal will also contribute significantly toward the development of dermoscopy in general dermatology, especially in the context of dermoscopy in Indian skin.

Feroze Kaliyadan

Department of Dermatology, College of Medicine, King Faisal University, Al Hasa, Kingdom of Saudi Arabia
E-mail: ferozkal@hotmail.com

REFERENCES


1. Friedman RJ, Rigel DS, Silverman MK, Kopf AW, Vossaert KA. Malignant melanoma in the 1990s: The continued importance of early detection and the role of physician examination and self-examination of the skin. *CA Cancer J Clin* 1991;41:201-26.
2. Goldman L, Younker W. Studies in microscopy of the surface of the skin; preliminary report of technics. *J Invest Dermatol* 1947;9:11-6.
3. MacKie RM. An aid to the preoperative assessment of pigmented lesions of the skin. *Br J Dermatol* 1971;85:232-8.
4. Steiner A, Pehamberger H, Wolff K. *In vivo* epiluminescence microscopy of pigmented skin lesions. II. Diagnosis of small pigmented skin lesions and early

5. detection of malignant melanoma. *J Am Acad Dermatol* 1987;17:584-91.
5. Pehamberger H, Steiner A, Wolff K. *In vivo* epiluminescence microscopy of pigmented skin lesions. I. Pattern analysis of pigmented skin lesions. *J Am Acad Dermatol* 1987;17:571-83.
6. Kaliyadan F. Using a simple jeweler's loupe as a dermoscopic instrument. *Indian J Dermatol Venereol Leprol* 2011;77:617-20.
7. Kaliyadan F, Ashique KT. A simple and cost-effective device for mobile dermoscopy. *Indian J Dermatol Venereol Leprol* 2013;79:817-9.
8. Kaliyadan F, Kuruvilla J. Using transparent adhesive tape to prevent cross infection during contact dermoscopy. *Indian J Dermatol Venereol Leprol* 2016 [Epub ahead of print].
9. Lacarrubba F, Verzi AE, Dinotta F, Scavo S, Micali G. Dermoscopy in inflammatory and infectious skin disorders. *G Ital Dermatol Venereol* 2015;150:521-31.
10. Lallas A, Giacomel J, Argenziano G, García-García B, González-Fernández D, Zalaudek I, *et al.* Dermoscopy in general dermatology: Practical tips for the clinician. *Br J Dermatol* 2014;170:514-26.
11. Errichetti E, Stinco G. The practical usefulness of dermoscopy in general dermatology. *G Ital Dermatol Venereol* 2015;150:533-46.
12. Carrera C, Marchetti MA, Dusza SW, Argenziano G, Braun RP, Halpern AC, *et al.* Validity and Reliability of Dermoscopic Criteria Used to Differentiate Nevi From Melanoma: A Web-Based International Dermoscopy Society Study. *JAMA Dermatol* 2016;152:798-806.
13. Russo T, Piccolo V, Lallas A, Argenziano G. Recent advances in dermoscopy. *F1000Res* 2016;5. pii: F1000 Faculty Rev-184.
14. National Institute for Health and Care Excellence. United Kingdom. Melanoma assessment and management of melanoma. (NG14). Available from: www.nice.org.uk/guidance/ng14. [Updated 2015 July 25, Cited 2016 July 27].
15. Inui S. Trichoscopy for common hair loss diseases: Algorithmic method for diagnosis. *J Dermatol* 2011;38:71-5.
16. Rakowska A, Rudnicka L, Olszewska M, Ross A. Algorithms in trichoscopy. In: Rudnicka L, editor. *Atlas of trichoscopy*. 1st ed. London: Springer-Verlag; 2012. p. 453-56.

DISCLAIMER

We have referred a lot of latest available literature on the subject and utmost care has been taken to ensure the correctness and authenticity of the information provided in this article. We do not have affiliation to any manufacturer or developer [software or hardware] and we shall not be responsible for any consequences thereof. The readers are requested to thoroughly screen the information and look for reviews prior to investing on resources for their clinical purposes. Further details for the above devices can be obtained through the manufacturer websites.

This is an open access article distributed under the terms of the Creative Commons Attribution-NonCommercial-ShareAlike 3.0 License, which allows others to remix, tweak, and build upon the work non-commercially, as long as the author is credited and the new creations are licensed under the identical terms.

Access this article online	
Quick Response Code:	Website: www.idoj.in
	DOI: 10.4103/2229-5178.190496
Cite this article as: Kaliyadan F. The scope of the dermoscope. <i>Indian Dermatol Online J</i> 2016;7:359-63.	