

Post-transplant biliary complications: advances in pathophysiology, diagnosis, and treatment

Matthew Fasullo ¹, Milan Patel,¹ Lauren Khanna,² Tilak Shah¹

To cite: Fasullo M, Patel M, Khanna L, *et al.* Post-transplant biliary complications: advances in pathophysiology, diagnosis, and treatment. *BMJ Open Gastro* 2022;**9**:e000778. doi:10.1136/bmjgast-2021-000778

Received 4 January 2022
Accepted 21 February 2022

ABSTRACT

Liver transplantation (LT) is the only curative therapy in patients with end-stage liver disease. Long-term survival is excellent, yet LT recipients are at risk of significant complications. Biliary complications are an important source of morbidity after LT, with an estimated incidence of 5%–32%. Post-LT biliary complications include strictures (anastomotic and non-anastomotic), bile leaks, stones, and sphincter of Oddi dysfunction. Prompt recognition and management is critical as these complications are associated with mortality rates up to 20% and retransplantation rates up to 13%. This review aims to summarise our current understanding of risk factors, natural history, diagnostic testing, and treatment options for post-transplant biliary complications.

INTRODUCTION

Liver transplantation (LT) has revolutionised the care of end-stage liver disease. Since the first human LT in 1960s, advances in preoperative assessment, surgical technique, post-operative care, immunosuppression, and antiviral therapy have dramatically improved graft and patient survival.^{1 2} Currently, the 1-year, 3-year, and 5-year patient survival rates are 91.8%, 83.8%, and 76.1%, respectively.³ Yet biliary complications remain a major source of morbidity and mortality in LT patients, with an incidence ranging from 10% to 15% in deceased donor transplants. With living donor liver transplant (LDLT), the risk is even higher, ~15%–30%.⁴ Prompt recognition and management is critical as these complications are associated with retransplantation and mortality rates as high as 13% and 19%, respectively.⁵

Common post-LT biliary complications include anastomotic strictures (AS), non-anastomotic strictures (NAS), bile leaks, bile duct stones, bile casts, bilomas, and sphincter of Oddi dysfunction (SOD) (table 1).⁶ Prompt recognition and treatment of post-LT biliary complications reduces morbidity and mortality and improves graft survival.^{7 8} This review provides an up-to-date summary of

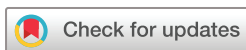epidemiology, pathogenesis, risk factors, diagnostic testing, and treatment options for post-LT biliary complications.

BILE LEAK

Post-orthotopic liver transplantation (OLT) bile leaks can be divided into early (<4 weeks post-OLT) and late (>4 weeks post-OLT). Bile leaks are further subclassified into anastomotic versus non-anastomotic leaks.^{9 10}

Early bile leaks most commonly occur at the anastomotic site, with ischaemia being an important mechanism. In theory, the risk of bile leak is lower with choledochocholedochostomy (duct-to-duct) compared with choledochojejunostomy (Roux-en-Y) because duct-to-duct anastomosis leaves the recipient bile duct better vascularised. In clinical practice, data have not clearly demonstrated a difference in the rate of bile leaks between these two types of anastomoses.¹¹ Procedure-related risk factors that may predispose to ischaemia at the anastomosis include excess tension, extensive dissection of the donor bile duct on procurement, and the amount of electrocautery used to control bleeding from cut ends of donor and recipient bile ducts.^{9 12 13} An important postoperative risk factor is hepatic artery thrombosis (HAT), which can cause necrosis of the anastomosis, leading to strictures or leaks (figure 1). LDLT requires donor hilum dissection and dissection of the recipient bile duct. These manoeuvres can result in biliary devascularisation and increase ischaemic time. In a meta-analysis, the pooled risk of bile leak was 7.8% for deceased donor liver transplant (DDLT) and 9.5% for LDLT. In more recent studies, the bile leak rate was 7.1% with DDLT vs 11.8% with LDLT (p<0.03).^{14 15}

With regard to late bile leaks, important risk factors are T-tube placement at the anastomosis or recurrence of an early bile leak. Because of the increased incidence



© Author(s) (or their employer(s)) 2022. Re-use permitted under CC BY-NC. No commercial re-use. See rights and permissions. Published by BMJ.

¹Gastroenterology, Virginia Commonwealth University Health System, Richmond, Virginia, USA

²Gastroenterology, New York University Medical Center, New York, New York, USA

Correspondence to

Dr Matthew Fasullo;
Matthew.Fasullo@vcuhealth.org

Table 1 Biliary complications following orthotopic liver transplantation

Complication	Presentation	Incidence	Time to presentation	Risk factors	Management
Anastomotic strictures	<ul style="list-style-type: none"> ▶ Abdominal pain. ▶ Jaundice. ▶ Cholestatic liver injury. ▶ Asymptomatic. 	▶ 6.6%–12.3%.	▶ Early to late.	<ul style="list-style-type: none"> ▶ Ischaemia. ▶ Genetic factors. ▶ Infection. 	▶ ERCP with balloon dilatation or stenting.
Non-anastomotic strictures	<ul style="list-style-type: none"> ▶ Abdominal pain. ▶ Jaundice. ▶ Cholestatic liver injury. ▶ Asymptomatic. 	▶ 10%–16%.	▶ Late.	<ul style="list-style-type: none"> ▶ Ischaemia. ▶ Genetic factors. ▶ Infection. ▶ Rejection. 	<ul style="list-style-type: none"> ▶ ERCP with balloon dilatation or stenting. ▶ Retransplant.
Bile leak	<ul style="list-style-type: none"> ▶ Liver injury. ▶ Fever. ▶ Bilious drainage (if drain in place). 	▶ 7.1%–11.8%.	▶ Early to late.	<ul style="list-style-type: none"> ▶ Ischaemia. ▶ T-tube placement. ▶ Iatrogenic. 	<ul style="list-style-type: none"> ▶ ERCP with sphincterotomy or stenting. ▶ Percutaneous drainage.
Vanishing bile duct	<ul style="list-style-type: none"> ▶ Jaundice. ▶ Abdominal pain. ▶ Fatigue. 	▶ Low (minimal data currently present).	▶ Early to late.	<ul style="list-style-type: none"> ▶ Rejection. ▶ Infection. 	<ul style="list-style-type: none"> ▶ Retransplant. ▶ Spontaneous resolution (quite rare).
Bile duct filling defects	<ul style="list-style-type: none"> ▶ Jaundice ▶ Cholestatic liver injury. ▶ Abdominal pain. 	▶ 3%–6%.	▶ Early to late.	<ul style="list-style-type: none"> ▶ Ischaemia. ▶ Infection. ▶ Rejection. 	<ul style="list-style-type: none"> ▶ ERCP with stenting. ▶ EUS drainage.
Sphincter of Oddi stenosis	<ul style="list-style-type: none"> ▶ Cholestatic liver injury. ▶ Abdominal pain. 	▶ 2%–3.5%.	▶ Early to late.	▶ Ischaemia.	▶ ERCP with sphincterotomy.

ERCP, endoscopic retrograde cholangiopancreatography; EUS, endoscopic ultrasound.

of T-tube-associated bile leaks, their use has decreased over the past two decades.¹⁶ Non-anastomotic bile leaks typically occur from the donor or recipient cystic duct remnants. The aetiologies may be iatrogenic (eg, improper ligation) or a distal obstruction that can occur from a mass, stricture, or stone. A less common aetiology is injury to the liver surface from the transplant itself. This aetiology is more common with LDLT.¹⁷

Clinicians should suspect bile leak in any post-LT patient with worsening liver enzymes of unclear aetiology,

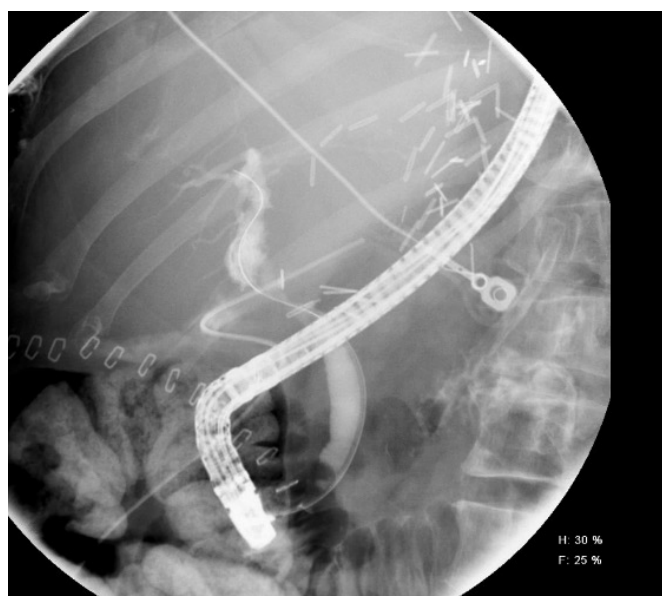


Figure 1 Image showing a single, severe anastomotic biliary stricture with duct disruption and subsequent bile leak found at the post-transplant anastomosis.

which should prompt abdominal imaging or bilious fluid noted from peritoneal drains.⁹ Bile leaks can result in abdominal pain, and fever if infected; but in many instances, leaks can occur without any of these typical symptoms. Initial abdominal imaging should include liver ultrasound with Doppler to evaluate for biliary dilatation and hepatic artery anastomosis. Over the past two decades, MRI has evolved as a highly sensitive and non-invasive alternative to percutaneous or endoscopic cholangiogram.^{18–20} Occasionally, MRI may not identify small leaks, in which case endoscopic or percutaneous cholangiogram may be necessary.

Once a bile leak is determined, the type of intervention depends on the anatomy allowing access to the biliary tree. In a duct-to-duct anastomosis, endoscopic retrograde cholangiopancreatography (ERCP) is the first-line intervention. For small leaks, a sphincterotomy alone is sufficient; stents are often used for larger leaks.^{21 22} Nasobiliary catheters and percutaneous transhepatic biliary drainage (PTBD) through interventional radiology are also options in the setting of a major bile leak.²³ Overall, success with ERCP is reported to be from 80% to 90%.^{24 25} Surgery is largely reserved for large leaks that lead to uncontrollable infection and sepsis, or leaks presumed secondary to ischaemia that are unlikely to improve with stenting or percutaneous drainage.

In patients with choledochojejunostomy, the Roux limb contains the remnant bile duct, which makes endoscopic access challenging. These patients typically require percutaneous drainage.²⁶ Recent publications have described successful cases of endoscopic ultrasound (EUS)-guided antegrade drainage approaches.^{16 23} Surface injury from

LDLT is treated with either percutaneous drainage or surgery.²²

BILIARY STONES, SLUDGE, AND CASTS

Bile duct filling defects (BDFDs) like biliary sludge, casts, and stones are another important biliary complication post-LT, occurring in about 3%–6% of patients.^{27 28} BDFDs can occur with any physiological process that slows the flow of bile leading to an increase in viscosity.^{29 30} The slow flow of bile can lead to formation of a cast or stone composed of bilirubin, collagen, bile acids, cellular debris, and cholesterol. Thus, any aetiology that slows bile flow (eg, biliary strictures, ischaemia, infection, cellular rejection, and medications) can predispose to sludge, casts, and stones. Biliary strictures are a particularly important risk factor for BDFDs; up to 45% of patients with BDFD have a concurrent stricture.¹⁰ Strictures often arise as a result of ischaemic injury to bile duct mucosa (eg, hepatic artery thrombus, ‘cold’ time during the transplant, or surgical technique). Similarly, infections and acute cellular rejection predispose to BDFDs because they disrupt bile duct epithelial cells.³⁰ Any medication that causes cholestasis can predispose to BDFDs. For example, ciclosporin inhibits bile salt secretion, which induces cholestasis and thereby increases risk of BDFDs.³¹ In terms of BDFD risk based on type of anastomosis, one older study suggested that there was a slightly increased risk with choledochojejunostomy. Subsequent studies failed to show any difference in risk of BDFDs based on type of anastomosis.³²

Bile casts are dark and hard in appearance and formed by lithogenic material confined to the bile duct dimensions. Casts occur most frequently in the common hepatic and right and left main intrahepatic ducts. They were first described after LT in the late 1970s when patients presented with multiple intrahepatic biliary strictures leading to large casts.³³ As with bile duct stones, the major risk factor is ischaemia, in particular the amount of ‘warm’ time compared with ‘cold’ time.³⁴ Additionally, if T-tubes and internal stents do not pass into the small bowel after the biliary anastomosis sutures dissolve, they can serve as a nidus for cast formation.³⁵

The diagnosis of BDFD relies on clinical factors such as abdominal pain and more objective data such as rise in liver enzymes, usually in a cholestatic pattern.³⁶ These findings should prompt liver imaging to rule out a hepatic artery thrombus and to evaluate the biliary ducts. MRI is highly sensitive at identifying BDFDs. The characteristic finding is a high signal intensity.

ERCP is the first-line approach for BDFDs in patients with choledochocholedochal anastomoses. Standard techniques including sphincterotomy, balloon dilatation, and balloon and basket retrieval are highly effective. Mechanical, electrohydraulic, and laser lithotripsy have been used successfully in patients with large or complex BDFDs.^{24 25} In patients with choledochojejunostomy, successful removal of BDFD using balloon-assisted

ERCP and EUS-guided approaches has been reported.³⁷ More frequently, percutaneous drainage performed by interventional radiology is used in this setting.^{17 36} The evidence supporting ursodeoxycholic acid for BDFDs is limited and inconsistent.

SPHINCTER OF ODDI STENOSIS

A less common complication of post-LT is SOD, also known as papillary dysfunction. SOD was initially classified into three subtypes using the Milwaukee classification: type I is believed to represent true sphincter stenosis and is most likely to respond to endoscopic therapy; type II likely represents an overlap between a structural dysfunction and a motility disorder; and type III represents functional biliary type pain.³⁷ More recently, the Rome III criteria has advocated for the removal of SOD type III to be replaced by the more accurate terminology of functional biliary or pancreatic SOD.³⁸ SOD type I is suspected in the setting of distal common bile duct (CBD) dilatation and elevated liver enzymes without an obvious stricture. One proposed mechanism involves injury to the innervation of the sphincter of Oddi leading to hypertonia.^{38 39} Data on SOD are quite limited and focused on studies involving manometry from the 1990s. Based on these studies, there were elevated resting basal pressures at the sphincter of Oddi demonstrated in patients who had an LT with choledochocholedochostomy anastomosis.^{40 41} In addition, T-tube manometry findings were also analysed showing elevated resting CBD pressures. Currently, the use of T-tube has been less prevalent due to the associated complications and manometry is also no longer routinely used as its utility has been questioned.

From a clinical standpoint, abnormal elevations in liver enzymes in a cholestatic pattern without a clear mechanical obstruction such as a stone or stricture should lead to consideration of SOD. Interventions include ERCP with sphincterotomy and consideration of stent placement.⁴² In extreme cases, surgery for conversion from a choledochocholedochostomy to a choledochojejunostomy has been reported.

VANISHING BILE DUCT SYNDROME

Vanishing bile duct syndrome (VBDS) is a rare complication of LT. VBDS is defined as small bile duct loss caused by acute or chronic cellular rejection.^{42 43} The proposed pathogenesis of VBDS with acute cellular rejection is a T cell response against bile duct cells, leading to destructive cholangitis, severe ductopaenia, and portal tracts without bile ducts.⁴⁴ VBDS with chronic rejection is still not fully understood, but some studies suggest macrophage activation which leads to histological features of lobular hepatitis, marked hepatocyte apoptosis, and small bile duct injury.^{45–47} Acute and chronic rejection may occur as a result of cytomegalovirus (CMV) infection, medications (eg,

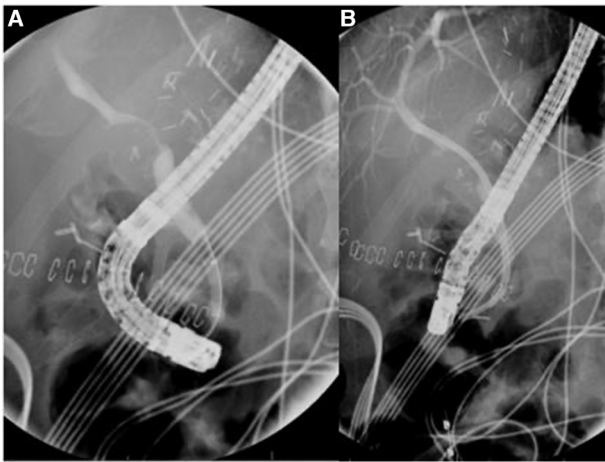


Figure 2 Fluoroscopic image demonstrating a severe anastomotic stricture (A) following endoscopic placement of plastic stent across the anastomotic site (B).

sertraline), and ischaemic cholangitis as the instigating event.⁴⁸ Case reports have described resolving ductopaenia, but such resolution appears to be highly unpredictable. Acute VBDS almost inevitably requires retransplantation.⁴⁹

ANASTOMOTIC STRICTURES

AS are a localised narrowing at the site of biliary anastomosis between the donor and recipient bile duct and are typically single and short (figure 2). They can present any time after transplantation, but the majority are diagnosed within 12 months following LT.⁵⁰ The cumulative risk of AS increases with time (6.6% at 1 year and 12.3% at 10 years).⁵¹ AS are more common than non-anastomotic biliary strictures and constitute up to 86% of all biliary strictures post-LT.⁵²

The pathophysiology for the development of AS is believed to be ischaemia or fibrosis of the bile duct following a suboptimal surgical technique or a bile leak in the early postoperative period.⁵³ In patients presenting early after LT, AS likely result from technical issues during surgery. These include small calibre of the bile ducts, size mismatch between the donor and recipient ducts, postoperative bile leak, inappropriate suture material, tension at the anastomosis, and excessive use of cauterisation to control bleeding.⁵⁴ Although many risk factors have been implicated in the development of AS, there is discordance among studies. Risk factors for the development of AS can be grouped into several broad categories, including ischaemic (surgical technique, longer intensive care unit (ICU) stay, and longer cold and warm ischaemia times), genetic factors, and inflammatory (CMV, Epstein-Barr Virus, and acute/chronic cellular rejection).^{55 56}

The clinical presentation of AS can differ significantly, with some presenting with signs of biliary obstruction (abdominal pain, jaundice, fever, chills, cholangitis, and anorexia) and some discovered incidentally in asymptomatic LT recipients due to persistent elevations in cholestatic liver function tests. As many other post-LT

complications (HAT, acute cellular rejection, choledocholithiasis) may present in a similar fashion, the diagnosis of AS requires a high clinical suspicion prompting radiographic or endoscopic confirmation. To date there have been no biomarkers or biochemical abnormalities that can diagnose AS with adequate accuracy.⁵⁷

Because of the relatively low cost and convenience, transabdominal ultrasound is often the first radiographic test performed when biliary stricture is suspected. Unfortunately, its ability to assess the anastomotic site is dismal, with a sensitivity ranging from 30% to 70%.⁵⁸ Similarly, the use of CT scan has led to suboptimal results, with a reported accuracy of diagnosing AS of around 40%.⁵⁹ MRI/magnetic resonance cholangiopancreatography (MRCP) is the most accurate radiological test for AS, with a reported sensitivity and specificity of up to 95%.⁶⁰ MRCP can accurately demonstrate a focal luminal narrowing across the biliary anastomosis, but not all narrowing are clinically relevant so close attention to the clinical context is essential.⁶¹ Endoscopic retrograde cholangiography (ERC) is the invasive gold standard diagnostic test, but interobserver variability is reported even with invasive cholangiography; ERC is generally reserved for therapeutic rather than diagnostic purposes.⁵³

T-tubes were once thought to protect against the development of AS, but more recent data have not demonstrated reduction in AS with T-tube. In fact, routine use of T-tubes may even lead to an increase in overall biliary complications.^{62 63} Because AS are unifocal, short-segment, and located within the extrahepatic bile duct, they are easily amenable to endoscopic or percutaneous therapy. While the success rates between endoscopic therapy and PTBD are similar, PTBD is associated with higher recurrence rates, increased patient discomfort, and increased risk of complications such as drain dislodgement or infection.^{64–66} As a result, endoscopic therapy with ERCP is the first-line approach for the management of AS.

Endoscopic treatment options include balloon dilatation or stenting. Treatment failure and recurrence rates are much higher with balloon dilatation alone, or placement of a single stent when compared with placement of multiple plastic stents (MPS).⁶⁴ In a meta-analysis assessing the effectiveness of MPS, resolution rates of 94%–100% were reported.⁶⁷ Patients typically required between three and four endoscopic sessions over the course of 12 months, with recurrence after an initial resolution occurring in up to 37%. An alternative to MPS is the placement of a single fully covered self-expandable metal stent (FCSEMS) across the anastomosis. While they are relatively easy to deploy, care is required to ensure that the proximal end of the stent is distal to the bifurcation to avoid obstructing flow from one lobe of the liver to the CBD. One approach to mitigate this complication is to prophylactically deploy plastic stents into the secondary branch ducts to prevent their occlusion. While cost-effective studies are needed, a meta-analysis comparing the effectiveness of FCSEMS with MPS

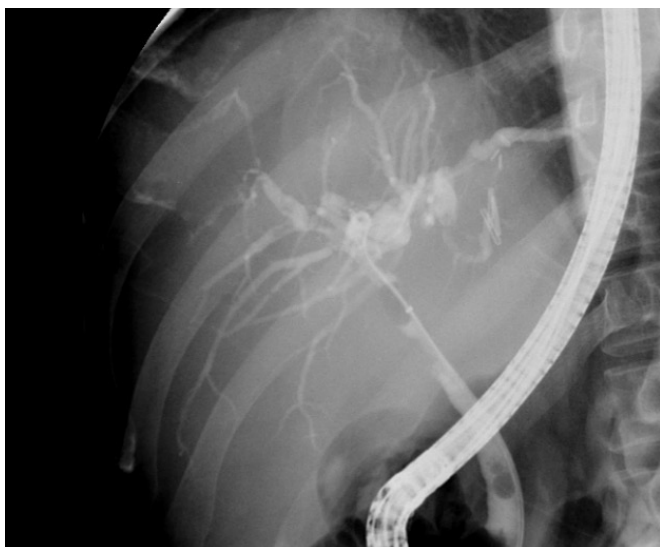


Figure 3 Fluoroscopic image demonstrating several areas of narrowing and dilatation representing non-anastomotic strictures. There is also bile duct filling defect seen in the distal common bile duct likely representing a gallstone in the recipient duct.

demonstrated similar rates of AS resolution, but found that FCSEMS reduced the number of ERCP procedures (mean difference: 1.69 ERCP; $p < 0.01$) and duration of treatment (mean difference: 40.2 days; $p = 0.03$).⁶⁸

Refractory AS have been treated with a myriad of novel endoscopic techniques, including magnetic compression anastomosis (MCA) and cholangioscopy-guided steroid injection with balloon dilatation. MCA has been shown to be effective in treating up to 88% of refractory AS.⁶⁹ A novel through-the-scope magnet has demonstrated similar rates of success while overcoming the technical difficulties of prior methods.⁷⁰ In a small case series by Franzini *et al*,⁷¹ cholangioscopy-guided steroid injection in conjunction with balloon dilatation was a safe, effective, and durable therapy for refractory AS. Historically, endoscopic therapies were not considered for patients with altered foregut anatomy (eg, Roux-en-Y hepaticojejunostomy or choledochojejunostomy), but recent novel approaches, including laparoscopic-assisted ERCP, balloon-assisted ERCP, and EUS-directed transgastric ERCP, have made endoscopic therapy safe and feasible.⁷²⁻⁷⁴

NON-ANASTOMOTIC STRICTURES

NAS, also referred to as ischaemic-type biliary strictures, are defined as a stricture, dilatation, or irregularity of the intrahepatic or extrahepatic bile ducts of the liver graft proximal to the anastomosis (figure 3).⁵³ NAS are associated with significant morbidity and mortality, with graft loss of up to 46%.⁷⁵ NAS typically present at a median of 6 months post-LT and recent long-term studies have documented that the incidence of NAS gradually increased from 10% at 1 year to ~16% at 10 years post-LT.^{53 76}

Similar to AS, the risk factors for the development of NAS can be grouped into several broad categories, including ischaemic (HAT, surgical technique, longer ICU stay, and longer cold and warm ischaemia times), grafts from donation after cardiac death, genetic factors, and inflammatory (CMV, Primary sclerosing cholangitis, autoimmune hepatitis, and acute/chronic cellular rejection).⁷⁷⁻⁷⁹

Like AS, the diagnosis of NAS is often challenging as the initial clinical presentation may be variable and often subtle. Some patients present with signs and symptoms of biliary obstruction, while others are asymptomatic and identified incidentally based on abnormal liver enzymes or imaging. Other subtle clues may include new-onset jaundice, Gram-negative sepsis, or signs of graft failure. Transabdominal ultrasound is often the first non-invasive test but is limited in its ability to identify NAS, with sensitivities for detecting NAS ranging between 38% and 66%.⁸⁰ The sensitivity of hepatobiliary scintigraphy with 99-technetium labelled iminodiacetic acid is similarly only 65%–75%.⁸¹ CT scan has a sensitivity >80% for NAS, but its specificity is only ~70%.⁵⁹ MRI/MRCP is the most accurate non-invasive test for NAS, with sensitivities and specificities as high as 95%.⁸²

NAS are a challenging biliary complication following LT because they may occur at multiple locations and are frequently resistant to minimally invasive endoscopic and percutaneous therapies. Medical management is generally used initially and involves optimisation of immunosuppression along with treatment of complications such as sepsis. Given the challenges in management, prevention of NAS has become an important focus of research over the last decade. Machine perfusion has become a promising technique to prevent bile duct injury at the time of transplant.⁸³ These initial findings were supported by several studies which again demonstrated decreased incidence of NAS in those who underwent dual hypothermic oxygenated machine perfusion.^{84 85}

Endoscopic therapy generally involves maximal endoscopic stenting with MPS with or without balloon dilatation, yet results have been suboptimal, with a success rate around 50%.^{86 87} The success rate in those with LDLT has been reported to range from 25% to 33%.⁸⁸ As a last resort in non-responders, endoscopic therapy may also serve as a bridge to retransplantation.⁸⁹ PTBD insertion has similar efficacy as endoscopic management for NAS, but complications such as drain malfunctions and patient discomfort preclude its use unless endoscopic management fails, in altered surgical anatomy or peripheral lesions not amenable to endoscopic therapy.⁹⁰ Surgery or retransplantation is typically reserved for patients who fail endoscopic or percutaneous therapy or progress to graft failure.⁶⁴

CONCLUSION

Biliary complications remain a major source of morbidity after LT and are commonly encountered. Considerable inroads have been made in understanding the aetiology and natural history of these complications. Minimally

invasive endoscopic therapies have obviated the need for repeat surgery or retransplant in a large proportion of patients, yet gaps remain in our understanding of the pathogenesis of many of these complications, which has curtailed the development of prophylactic therapeutics or interventions to prevent their occurrence.

Contributors MF: conception and design, analysis and interpretation of data, drafting of the article, critical revision of the article for important intellectual content, figure design, final approval of the article. MP, LK: critical revision of the article for important intellectual content, final approval of the article. TS: conception and design, critical revision of the article for important intellectual content, final approval of the article.

Funding The authors have not declared a specific grant for this research from any funding agency in the public, commercial or not-for-profit sectors.

Competing interests TS: CSA Medical research advisory board, Allergen research support, Research support Lucid.

Patient consent for publication Not required.

Ethics approval This study does not involve human participants.

Provenance and peer review Commissioned; externally peer reviewed.

Data availability statement No data are available.

Open access This is an open access article distributed in accordance with the Creative Commons Attribution Non Commercial (CC BY-NC 4.0) license, which permits others to distribute, remix, adapt, build upon this work non-commercially, and license their derivative works on different terms, provided the original work is properly cited, appropriate credit is given, any changes made indicated, and the use is non-commercial. See: <http://creativecommons.org/licenses/by-nc/4.0/>.

ORCID ID

Matthew Fasullo <http://orcid.org/0000-0001-9868-5084>

REFERENCES

- Boeva I, Karagoyozov PI, Tishkov I. Post-liver transplant biliary complications: current knowledge and therapeutic advances. *World J Hepatol* 2021;13:66–79.
- Charlton MR. Roadmap for improving patient and graft survival in the next 10 years. *Liver Transpl* 2016;22:71–8.
- United network for organ sharing organ procurement and transplantation network 2019.
- Daniel K, Said A. Early biliary complications after liver transplantation. *Clin Liver Dis* 2017;10:63–7.
- Thethy S, Thomson BN, Pleass H, et al. Management of biliary tract complications after orthotopic liver transplantation. *Clin Transplant* 2004;18:647–53.
- Moy BT, Birk JW. A review on the management of biliary complications after orthotopic liver transplantation. *J Clin Transl Hepatol* 2019;7:61–71.
- Lee HW, Shah NH, Lee SK. An update on endoscopic management of post-liver transplant biliary complications. *Clin Endosc* 2017;50:451–63.
- Pfau PR, Kochman ML, Lewis JD, et al. Endoscopic management of postoperative biliary complications in orthotopic liver transplantation. *Gastrointest Endosc* 2000;52:55–63.
- Jagannath S, Kalloo AN. Biliary complications after liver transplantation. *Curr Treat Options Gastroenterol* 2002;5:101–12.
- Thuluvath PJ, Atassi T, Lee J. An endoscopic approach to biliary complications following orthotopic liver transplantation. *Liver Int* 2003;23:156–62.
- Kasahara M, Egawa H, Takada Y, et al. Biliary reconstruction in right lobe living-donor liver transplantation: comparison of different techniques in 321 recipients. *Ann Surg* 2006;243:559–66.
- Thuluvath PJ, Pfau PR, Kimmey MB, et al. Biliary complications after liver transplantation: the role of endoscopy. *Endoscopy* 2005;37:857–63.
- Moser MA, Wall WJ. Management of biliary problems after liver transplantation. *Liver Transpl* 2001;7:S46–52.
- Akamatsu N, Sugawara Y, Hashimoto D. Biliary reconstruction, its complications and management of biliary complications after adult liver transplantation: a systematic review of the incidence, risk factors and outcome. *Transpl Int* 2011;24:379–92.
- Humar A, Ganesh S, Jorgensen D, et al. Adult living donor versus deceased donor liver transplant (LDLT versus DDLT) at a single center: time to change our paradigm for liver transplant. *Ann Surg* 2019;270:444–451.
- Pascher A, Neuhaus P. Bile duct complications after liver transplantation. *Transpl Int* 2005;18:627–42.
- Ostroff JW. Management of biliary complications in the liver transplant patient. *Gastroenterol Hepatol* 2010;6:264–72.
- Stadnik A, Cieszanowski A, Maj E, et al. Biliary complications after liver transplantation: the role of Mr imaging using different hydrographic sequences in patients with biliary-enteric and duct-to-duct biliary anastomosis. *Ann Transplant* 2013;18:460–70.
- Beltrán MM, Marugán RB, Oton E, et al. Accuracy of magnetic resonance cholangiography in the evaluation of late biliary complications after orthotopic liver transplantation. *Transplant Proc* 2005;37:3924–5.
- Pecchi A, De Santis M, Di Benedetto F, et al. Role of magnetic resonance cholangiography in biliary complications of orthotopic liver transplantation. *Radiol Med* 2010;115:1065–79.
- Ayoub WS, Esquivel CO, Martin P. Biliary complications following liver transplantation. *Dig Dis Sci* 2010;55:1540–6.
- Akamatsu N, Sugawara Y, Hashimoto D. Biliary reconstruction, its complications and management of biliary complications after adult liver transplantation: a systematic review of the incidence, risk factors and outcome. *Transpl Int* 2011;24:379–92.
- Lee HW, Shah NH, Lee SK. An update on endoscopic management of Post-Liver transplant biliary complications. *Clin Endosc* 2017;50:451–63.
- Park JS, Kim M-H, Lee SK, et al. Efficacy of endoscopic and percutaneous treatments for biliary complications after cadaveric and living donor liver transplantation. *Gastrointest Endosc* 2003;57:78–85.
- Polese L, Cillo U, Brolese A, et al. Endoscopic treatment of bile duct complications after orthotopic liver transplantation. *Transplant Proc* 2007;39:1942–4.
- Fang C, Yan S, Zheng S. Bile leakage after liver transplantation. *Open Med* 2017;12:424–9.
- Sheng R, Sammon JK, Zajko AB, et al. Bile leak after hepatic transplantation: cholangiographic features, prevalence, and clinical outcome. *Radiology* 1994;192:413–6.
- Spier BJ, Pfau PR, Lorenze KR, et al. Risk factors and outcomes in post-liver transplantation bile duct stones and casts: a case-control study. *Liver Transpl* 2008;14:1461–5.
- Lee SP, Maher K, Nicholls JF. Origin and fate of biliary sludge. *Gastroenterology* 1988;94:170–6.
- Parry SD, Muiesan P. Cholangiopathy and the biliary cast syndrome. *Eur J Gastroenterol Hepatol* 2003;15:341–3.
- Chan FK, Zhang Y, Lee SS, et al. The effects of liver transplantation and cyclosporine on bile formation and lipid composition: an experimental study in the rat. *J Hepatol* 1998;28:329–36.
- Sheng R, Ramirez CB, Zajko AB, et al. Biliary stones and sludge in liver transplant patients: a 13-year experience. *Radiology* 1996;198:243–7.
- Starzl TE, Putnam CW, Hansbrough JF, et al. Biliary complications after liver transplantation: with special reference to the biliary cast syndrome and techniques of secondary duct repair. *Surgery* 1977;81:212–21.
- Gor NV, Levy RM, Ahn J, et al. Biliary cast syndrome following liver transplantation: predictive factors and clinical outcomes. *Liver Transpl* 2008;14:1466–72.
- Buck DG, Zajko AB. Biliary complications after orthotopic liver transplantation. *Tech Vasc Interv Radiol* 2008;11:51–9.
- Girotra M, Soota K, Klair JS, et al. Endoscopic management of post-liver transplant biliary complications. *World J Gastrointest Endosc* 2015;7:446–59.
- Bistriz L, Bain VG. Sphincter of Oddi dysfunction: managing the patient with chronic biliary pain. *World J Gastroenterol* 2006;12:3793–802.
- Londoño M-C, Balderramo D, Cárdenas A. Management of biliary complications after orthotopic liver transplantation: the role of endoscopy. *World J Gastroenterol* 2008;14:493–7.
- Neuhaus P, Blumhardt G, Bechstein WO, et al. Technique and results of biliary reconstruction using side-to-side choledochocholedochostomy in 300 orthotopic liver transplants. *Ann Surg* 1994;219:426–34.
- Douzdjian V, Abecassis MM, Johlin FC. Sphincter of Oddi dysfunction following liver transplantation. screening by bedside manometry and definitive manometric evaluation. *Dig Dis Sci* 1994;39:253–6.

- 41 Pascher A, Neuhaus P. Biliary complications after deceased-donor orthotopic liver transplantation. *J Hepatobiliary Pancreat Surg* 2006;13:487–96.
- 42 Kochhar G, Parungao JM, Hanouneh IA, et al. Biliary complications following liver transplantation. *World J Gastroenterol* 2013;19:2841–6.
- 43 van Hoek B, Wiesner RH, Krom RA, et al. Severe ductopenic rejection following liver transplantation: incidence, time of onset, risk factors, treatment, and outcome. *Semin Liver Dis* 1992;12:41–50.
- 44 Boraschi P, Donati F. Postoperative biliary adverse events following orthotopic liver transplantation: assessment with magnetic resonance cholangiography. *World J Gastroenterol* 2014;20:11080–94.
- 45 Hubscher SG, Buckels JA, Elias E, et al. Vanishing bile-duct syndrome following liver transplantation—is it reversible? *Transplantation* 1991;51:1004–10.
- 46 Ludwig J, Wiesner RH, Batts KP, et al. The acute vanishing bile duct syndrome (acute irreversible rejection) after orthotopic liver transplantation. *Hepatology* 1987;7:476–83.
- 47 Nemes B, Gámán G, Doros A. Biliary complications after liver transplantation. *Expert Rev Gastroenterol Hepatol* 2015;9:447–66.
- 48 Harnois DM, Watt KDS. Cholestasis Post-Liver Transplantation. In: Carey EJ, Lindor KD, eds. *Cholestatic liver disease*. New York: Springer, 2014: 189–99.
- 49 Reau NS, Jensen DM. Vanishing bile duct syndrome. *Clin Liver Dis* 2008;12:x:203–17.
- 50 Macías-Gómez C, Dumonceau J-M. Endoscopic management of biliary complications after liver transplantation: an evidence-based review. *World J Gastrointest Endosc* 2015;7:606–16.
- 51 Verdonk RC, Buis CI, Porte RJ, et al. Anastomotic biliary strictures after liver transplantation: causes and consequences. *Liver Transpl* 2006;12:726–35.
- 52 Baccarani U, Risaliti A, Zoratti L, et al. Role of endoscopic retrograde cholangiopancreatography in the diagnosis and treatment of biliary tract complications after orthotopic liver transplantation. *Dig Liver Dis* 2002;34:582–6.
- 53 Buis CI, Verdonk RC, Van der Jagt EJ, et al. Nonanastomotic biliary strictures after liver transplantation, part 1: radiological features and risk factors for early vs. late presentation. *Liver Transpl* 2007;13:708–18.
- 54 Koneru B, Sterling MJ, Bahramipour PF. Bile duct strictures after liver transplantation: a changing landscape of the Achilles' heel. *Liver Transpl* 2006;12:702–4.
- 55 Amer A, McColl K, Bouayyad S, et al. The association of pregnane X receptor activation with outcomes after liver transplantation-A retrospective study. *Clin Transplant* 2019;33:e13734.
- 56 Iacob S, Cicinnati VR, Dechêne A, et al. Genetic, immunological and clinical risk factors for biliary strictures following liver transplantation. *Liver Int* 2012;32:1253–61.
- 57 Kohli DR, Vachhani R, Shah TU, et al. Diagnostic accuracy of laboratory tests and diagnostic imaging in detecting biliary strictures after liver transplantation. *Dig Dis Sci* 2017;62:1327–33.
- 58 Altman A, Zangan SM. Benign biliary strictures. *Semin Intervent Radiol* 2016;33:297–306.
- 59 Zoepf T, Maldonado-Lopez E-J, Hilgard P, et al. Diagnosis of biliary strictures after liver transplantation: which is the best tool? *World J Gastroenterol* 2005;11:2945–8.
- 60 Boraschi P, Braccini G, Gigoni R, et al. Detection of biliary complications after orthotopic liver transplantation with Mr cholangiography. *Magn Reson Imaging* 2001;19:1097–105.
- 61 St Peter S, Rodriguez-Davalos MI, Rodriguez-Luna HM, et al. Significance of proximal biliary dilatation in patients with anastomotic strictures after liver transplantation. *Dig Dis Sci* 2004;49:1207–11.
- 62 Sotiropoulos GC, Sgourakis G, Radtke A, et al. Orthotopic liver transplantation: T-tube or not T-tube? systematic review and meta-analysis of results. *Transplantation* 2009;87:1672–80.
- 63 Zhao J-Z, Qiao L-L, Du Z-Q, et al. T-tube vs no T-tube for biliary tract reconstruction in adult orthotopic liver transplantation: An updated systematic review and meta-analysis. *World J Gastroenterol* 2021;27:1507–23.
- 64 Villa NA, Harrison ME. Management of biliary strictures after liver transplantation. *Gastroenterol Hepatol* 2015;11:316–28.
- 65 Nacif LS, Bernardo WM, Bernardo L, et al. Endoscopic treatment of post-liver transplantation anastomotic biliary stricture: systematic review and meta-analysis. *Arq Gastroenterol* 2014;51:240–9.
- 66 Kobayashi N, Kubota K, Shimamura T, et al. Complications of the treatment of endoscopic biliary strictures developing after liver transplantation. *J Hepatobiliary Pancreat Sci* 2011;18:202–10.
- 67 Kao D, Zepeida-Gomez S, Tandon P, et al. Managing the post-liver transplantation anastomotic biliary stricture: multiple plastic versus metal stents: a systematic review. *Gastrointest Endosc* 2013;77:679–91.
- 68 Landi F, de'Angelis N, Sepulveda A, et al. Endoscopic treatment of anastomotic biliary stricture after adult deceased donor liver transplantation with multiple plastic stents versus self-expandable metal stents: a systematic review and meta-analysis. *Transpl Int* 2018;31:131–51.
- 69 Jang SI, Choi J, Lee DK. Magnetic compression anastomosis for treatment of benign biliary stricture. *Dig Endosc* 2015;27:239–49.
- 70 Parlak E, Küçükay F, Köksal Aydın Şeref, et al. Recanalization of complete anastomotic biliary obstruction after living donor related liver transplantation with a novel through-the-scope magnet. *Liver Transpl* 2015;21:711–2.
- 71 Franzini T, Sagae VMT, Guedes HG, et al. Cholangioscopy-guided steroid injection for refractory post liver transplant anastomotic strictures: a rescue case series. *Ther Adv Gastrointest Endosc* 2019;12:2631774519867786.
- 72 Runge TM, Chiang AL, Kowalski TE, et al. Endoscopic ultrasound-directed transgastric ERCP (edge): a retrospective multicenter study. *Endoscopy* 2021;53:611–8.
- 73 Koornstra JJ, Fry L, Mönkemüller K. Ercp with the balloon-assisted enteroscopy technique: a systematic review. *Dig Dis* 2008;26:324–9.
- 74 Mönkemüller K, Fry LC, Bellutti M, et al. Ercp using single-balloon instead of double-balloon enteroscopy in patients with Roux-en-Y anastomosis. *Endoscopy* 2008;40 Suppl 2:E19–20.
- 75 Guichelaar MMJ, Benson JT, Malinchoc M, et al. Risk factors for and clinical course of non-anastomotic biliary strictures after liver transplantation. *Am J Transplant* 2003;3:885–90.
- 76 Colonna JO, Shaked A, Gomes AS, et al. Biliary strictures complicating liver transplantation. incidence, pathogenesis, management, and outcome. *Ann Surg* 1992;216:34–52.
- 77 Larivière J, Giard J-M, Zuo RM, et al. Association between intraoperative fluid balance, vasopressors and graft complications in liver transplantation: a cohort study. *PLoS One* 2021;16:e0254455.
- 78 Forrest EA, Reiling J, Lipka G, et al. Risk factors and clinical indicators for the development of biliary strictures post liver transplant: significance of bilirubin. *World J Transplant* 2017;7:349–58.
- 79 Dulaney DT, Dokus KM, McIntosh S, et al. Tobacco use is a modifiable risk factor for post-transplant biliary complications. *J Gastrointest Surg* 2017;21:1643–9.
- 80 Sharzei K. Biliary strictures in the liver transplant patient. *Tech Gastrointest Endosc* 2016;18:91–7.
- 81 Kim YJ, Lee KT, Jo YC, et al. Hepatobiliary scintigraphy for detecting biliary strictures after living donor liver transplantation. *World J Gastroenterol* 2011;17:2626–31.
- 82 den Dulk AC, Wasser MNJM, Willemsen FEJA, et al. Value of magnetic resonance cholangiopancreatography in assessment of Nonanastomotic biliary strictures after liver transplantation. *Transplant Direct* 2015;1:e42.
- 83 Weeder PD, van Rijn R, Porte RJ. Machine perfusion in liver transplantation as a tool to prevent non-anastomotic biliary strictures: rationale, current evidence and future directions. *J Hepatol* 2015;63:265–75.
- 84 van Rijn R, van den Berg AP, Erdmann JI, et al. Study protocol for a multicenter randomized controlled trial to compare the efficacy of end-ischemic dual hypothermic oxygenated machine perfusion with static cold storage in preventing non-anastomotic biliary strictures after transplantation of liver grafts donated after circulatory death: DHOPE-DCD trial. *BMC Gastroenterol* 2019;19:40.
- 85 Dutkowski P, Polak WG, Muesan P, et al. First comparison of hypothermic oxygenated perfusion versus static cold storage of human donation after cardiac death liver transplants: an International-matched case analysis. *Ann Surg* 2015;262:764–71.
- 86 Barbaro F, Tringali A, Larghi A, et al. Endoscopic management of non-anastomotic biliary strictures following liver transplantation: long-term results from a single-center experience. *Dig Endosc* 2021;33:849–57.
- 87 Verdonk RC, Buis CI, van der Jagt EJ, et al. Nonanastomotic biliary strictures after liver transplantation, part 2: management, outcome, and risk factors for disease progression. *Liver Transpl* 2007;13:725–32.
- 88 Tsujino T, Isayama H, Sugawara Y, et al. Endoscopic management of biliary complications after adult living donor liver transplantation. *Am J Gastroenterol* 2006;101:2230–6.
- 89 Ryu CH, Lee SK. Biliary strictures after liver transplantation. *Gut Liver* 2011;5:133–42.
- 90 Lu N-N, Huang Q, Wang J-F, et al. Non-anastomotic biliary strictures following orthotopic liver transplantation: treatment with percutaneous transhepatic biliary drainage. *Hepatogastroenterology* 2012;59:2569–72.