

# Superficial temporal artery access for percutaneous coronary artery stenting during the COVID-19 pandemic: a case report

Ádám Csavajda<sup>1\*</sup>, Olivier F. Bertrand<sup>2</sup>, Béla Merkely<sup>3</sup>, and Zoltán Ruzsa<sup>1,3</sup>

<sup>1</sup>Bács-Kiskun County Hospital, Teaching Hospital of the Albert Szent-Györgyi Medical School, University of Szeged, Kecskemét, Invasive Cardiology, 6000, Nyíri Street 38, Hungary; <sup>2</sup>Quebec Heart–Lung Institute, Laval University, Quebec, Canada; and <sup>3</sup>Semmelweis University Heart and Vascular Centre, Budapest, Hungary

Received 12 June 2020; first decision 15 July 2020; accepted 24 November 2020

## Background

The COVID-19 pandemic creates new challenges for healthcare, including invasive cardiology.

## Case summary

We discuss the case of a 65-year-old man who presented with non-ST segment elevation myocardial infarction combined with bilateral pneumonia. The patient had known severe iliac artery lesions with prior interventions and bilateral subclavian artery occlusions. After unsuccessful femoral artery access, the diagnostic angiography and the right coronary artery percutaneous coronary intervention were successfully performed from ultrasound-guided lower superficial temporal artery access.

## Discussion

We showed that superficial temporal access can be used as an alternate access site for diagnostic coronary angiography and intervention when standard wrist and femoral access sites are not readily accessible.

## Keywords

Superficial temporal artery access • Coronary angioplasty • COVID-19 pandemic • Case report

## Learning points

- The therapeutic management of a patient who presented with non-ST segment elevation myocardial infarction combined with bilateral pneumonia during the COVID-19 pandemic.
- The importance of the superficial temporal artery which can be used as an alternate access site for diagnostic coronary angiography and intervention.

major impact on interventional cardiology, particularly in terms of patient's pathways and diagnostic steps. Nowadays, non-ST segment elevation acute coronary syndrome (NSTEMI-ACS) is often associated with community-acquired pneumonia, and coronary angiography and interventions are particularly challenging.<sup>1</sup> Moreover, coronary angiography in severe peripheral artery disease might be extremely complicated or impossible from standard femoral or radial access sites. In these rare cases, direct aortic puncture has been described, but this access site is rarely performed and the risks of complications are high. Superficial temporal artery access (STA) has been used for percutaneous carotid interventions in the case of iatrogenic carotid artery dissection or ostial common carotid artery lesion as an alternative access site.<sup>2,3</sup>

## Introduction

The COVID-19 pandemic poses new and substantial challenges for present-day healthcare. This ongoing crisis is also having a

\* Corresponding author. Tel: +36703346374, Email: [csavajda92@gmail.com](mailto:csavajda92@gmail.com)

Handling Editor: Parham Eshtehardi

Peer-reviewers: Elad Asher and Ivan Ilic

Compliance Editor: Matteo Parollo

Supplementary Material Editor: Ross Thomson

© The Author(s) 2020. Published by Oxford University Press on behalf of the European Society of Cardiology.

This is an Open Access article distributed under the terms of the Creative Commons Attribution Non-Commercial License (<http://creativecommons.org/licenses/by-nc/4.0/>), which permits non-commercial re-use, distribution, and reproduction in any medium, provided the original work is properly cited. For commercial re-use, please contact [journals.permissions@oup.com](mailto:journals.permissions@oup.com)

## Timeline

Timeline	Description
Day 1	Patient admission at emergency department in our hospital. Diagnosis was made: non-ST segment elevation myocardial infarction combined with bilateral pneumonia.
Day 1–1 h after admission	PCR test, intensive care unit consultation, and endotracheal intubation were performed.
Day 1–2 h after admission	Diagnostic angiography and right coronary artery percutaneous coronary intervention was performed from lower superficial temporal artery access.
Day 1–2	The patient was isolated in a COVID-19 dedicated ward. Dual antiplatelet therapy was initiated and combined antibiotic therapy was started.
Day 3	PCR results came back negative. The patient was transferred to regular cardiology ward.
Day 5	The patient was extubated and intravenous vasopressor support was weaned.
Day 12	Hospital discharge.

## Case presentation

We discuss the case of a 65 years old man who presented with NSTEMI-ACS during the COVID-19 pandemic. The patient initially was transported by ambulance to the emergency department with severe dyspnoea and chest pain. His blood pressure was 140/80 mmHg, heart rate 116 b.p.m., and saturation 89% on 7 L of oxygen through an oxygen mask. On physical examination, faded breathing sounds were detected on the right side. Based on the clinical findings and chest X-ray imaging, bilateral pneumonia was confirmed and the patient was suspected of having a COVID-19-based infection. After intensive care unit consultation, endotracheal intubation was performed due to the respiratory failure and rapidly deteriorating vital parameters.

In laboratories negative procalcitonin (0.17 ng/mL), discrete C-reactive protein elevation (24.2 mg/L), leucocytosis (27.25 G/L), neutrophilia (94.2%), relevant CK (238 U/L)/CK-MB (50 U/L) elevations, and elevated troponin level (140 ng/L) had been seen. According to the initial complaints, electrocardiogram (ECG) changes (Figure 2), elevated levels of cardiac enzymes, and segmental wall motion abnormalities on bedside echocardiography, diagnostic coronary angiography ± intervention were planned.

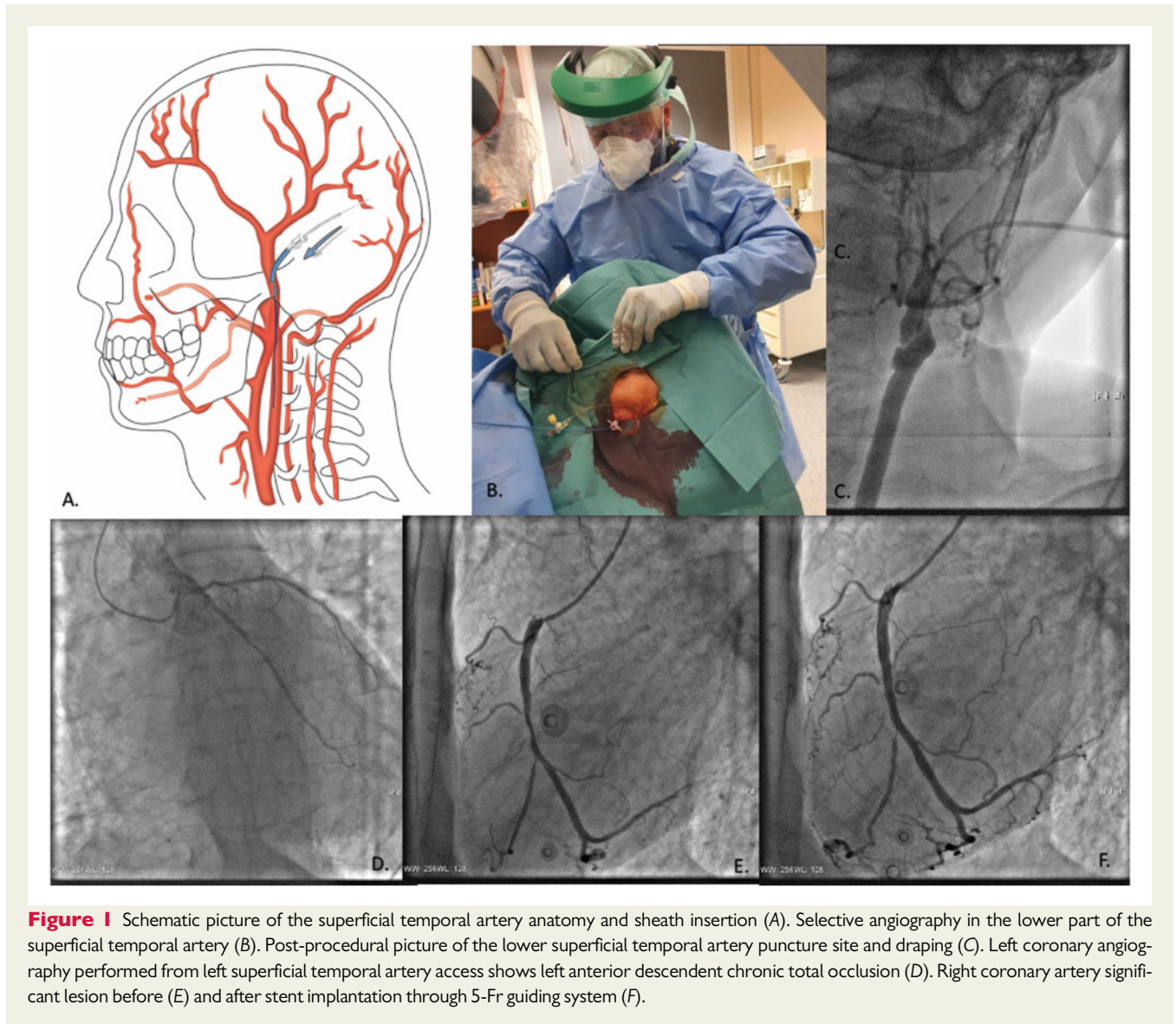
Beside echocardiography demonstrated decreased left ventricular function [ejection fraction (EF): 28%; left ventricular outflow tract velocity time integral (LVOT VTI): 7 cm], inferior wall hypokinesia and anterior wall akinesia with moderate mitral valve insufficiency (PISA radius 0.5 cm; vena contracta: 4 mm). The echocardiographic image suggested a low output syndrome formed on the ground of acute coronary syndrome.

The patient was known to have bilateral subclavian artery occlusions, internal carotid artery occlusion on the left side and previously he had a left external iliac artery percutaneous transluminal angioplasty. He had several comorbidities including hypertension, hyperlipidaemia, chronic alcohol abuse, and a previous cerebrovascular accident with right-sided paralysis. Chronic medication consisted of clopidogrel (75 mg once daily), vinpocetine (5 mg three times daily), pentoxifylline (400 mg twice daily), famotidine (20 mg twice daily), and rosuvastatin (20 mg once daily). Upon physical examination, the radial and femoral arteries were hardly palpable. Initial access through left femoral artery access failed due to the left external iliac artery occlusion. Right common femoral artery access was also unsuccessful due to the right external iliac artery occlusion.

Then, the left temporal scalp was shaved, sterile prepped and draped (Figure 1C). The left STA was punctured under ultrasonography guidance, and a 5-Fr 7.5 cm radial sheath (Radiofocus, Terumo, Japan) was advanced into the common carotid artery. In addition to antiplatelet treatment, 5000 IU heparin sodium, and 250 mcg nitroglycerine were administered directly to the STA through the sheath.

Additional Na-Heparin was given until reaching 100 IU/kg. Routine activated clotting time (ACT) was not measured during the intervention. Diagnostic coronary angiography using left and right Judkins catheter (Impulse, Boston Sci, USA) revealed chronic total occlusion of the left anterior descending artery (LAD) and a tight right coronary artery (RCA) lesion with feeding collaterals to the LAD (Figure 1D and E). Urgent heart team consultation decided to treat the RCA as a culprit lesion. Based on bedside ultrasonography and ECG, the anterior wall was not viable. To treat the culprit lesion, the RCA was cannulated with a 5-Fr guiding catheter (Figure 1E) and a Balance Heavy Weight guidewire was advanced in the distal RCA (Abbot Co, CA, USA) (Figure 1E). Another Balance Middle Weight guidewire was used as a buddy wire (Abbot Co, CA, USA). The RCA lesion was stented with a 3 mm × 38 mm Endeavor Resolute drug eluting stent (Medtronic Co, MN, USA). Post-procedural angiographic result showed thrombolysis in myocardial infarction (TIMI) III flow and no residual stenosis. Post-dilatation was not needed due to adequate stent expansion.

The sheath was pulled out immediately and a StatSeal haemostatic patch (Bioline, USA) was used followed by a local compression and gaze covering. During procedure, staff remained protected with N95 masks and plastic protection (Blue Eagle, China) in a regular Cath lab room. Following the intervention, dual antiplatelet therapy was continued with aspirin and clopidogrel. Using prasugrel or ticagrelor was not considered as the patient was classified as at high risk of bleeding due to comorbidities and there was an absolute contraindication to prasugrel due to previous stroke. We also started combined antibiotic therapy (intravenous ceftriaxone plus clarithromycin) which resulted in a gradual healing of pneumonia. The temporal artery patency was checked using echosonography, which showed normal flow values without any vascular complications. Four days after initial presentation, the patient was extubated and intravenous vasopressor support was weaned. Pending results of the polymerase chain reaction (PCR) testing for COVID-19, the patient was isolated in the



COVID-19 dedicated ward of our hospital. Since PCR results came back negative, the patient was transferred to regular cardiology ward.

During his inpatient stay, the patient's medication regimen was optimized with an angiotensin-converting enzyme inhibitor (enalapril), beta-blocker (nebivolol), mineralocorticoid receptor antagonist (spironolactone), hydroxymethylglutaryl-coenzyme A (HMG-CoA) reductase inhibitor (atorvastatin), PPI (pantoprazole), and furosemide in addition to dual antiplatelet therapy (aspirin and clopidogrel). No further complication occurred, and the patients was discharged from hospital on Day 12.

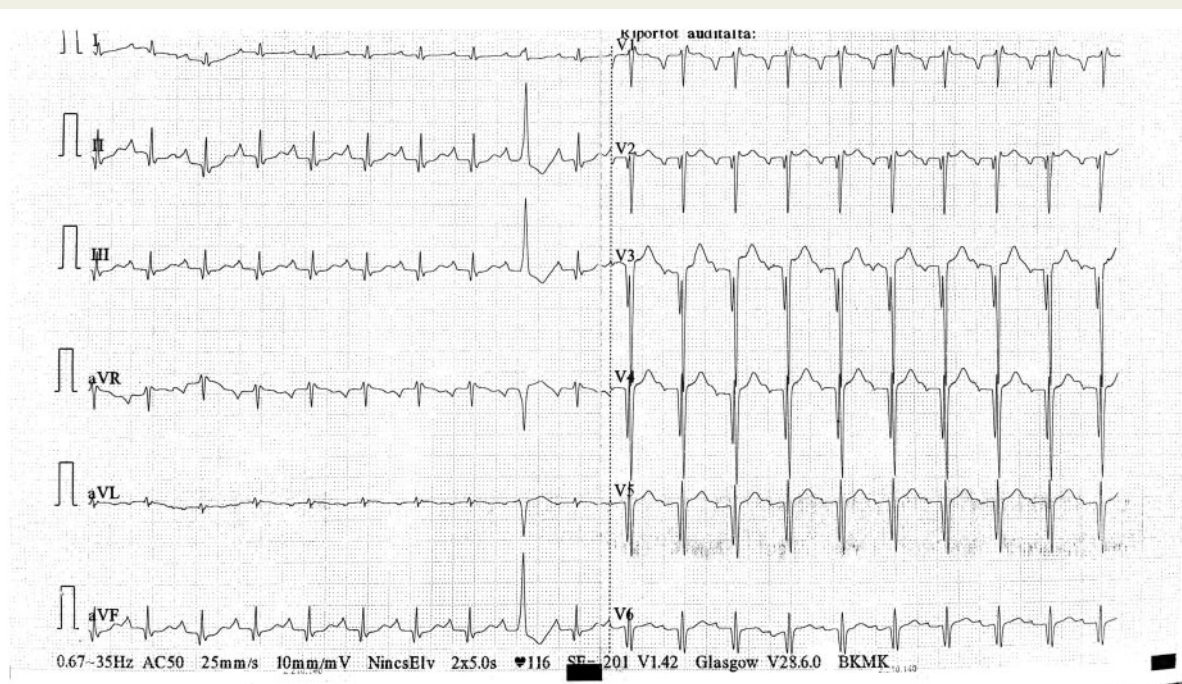
Based on the experience of the 3-month follow-up visit, the patient was compensated, free of angina, and feeling well. Echocardiography confirmed improved left ventricular function (EF 35%). To assess the myocardial viability of the LAD territories, stress echocardiography is planned further.

## Discussion

We showed that STA can be used as an alternate access site for diagnostic coronary angiography and intervention when standard wrist and femoral access sites are not readily accessible.

The STA arises from the external carotid artery (ECA), it is 1 of the 2 terminal branches of the ECA. It gives off many branches that supply the scalp and muscles, it has got a very important role in neurovascular diseases, and it might serve as bypass for intracranial ischaemic vascular disease.<sup>4</sup>

The puncture technique for the STA is not frequently used, however it is similar to those used in other small vessels like the radial artery or for the snuffbox approach.<sup>5</sup> Both arteries have similar diameter, are superficial and well visualized with ultrasound. STA access has several advantages and disadvantages, however. Contrary to popular belief, the major advantage of this type of arterial puncture is its ease of access. Furthermore, haemostasis is



**Figure 2** Initial electrocardiogram—sinus rhythm, heart rate: 116 b.p.m., normal QRS axis, PQ: 200 ms, QRS: 80 ms, discrete ST depression across the inferior leads, J-point elevation across the anterior leads, 1-1 isolated ventricular extrasystoles.

also very easy because it runs close to a bony surface and then it is readily compressible.

Yet in some cases, the small calibre of STA can be a limitation and it is also very susceptible to vasospasm.<sup>2,3</sup> Approach is difficult if the STA is stenotic or markedly tortuous. During the puncture facial nerve must be avoided, especially in case of an inferior approach. Yet, it is worth noticing the potential risk of retrograde embolization from ECA into the internal carotid artery with devastating consequences.<sup>6</sup>

## Conclusion

In this suspected COVID-19 case presenting with NSTEMI-ACS, bilateral pneumonia and severe peripheral artery disease, STA was successfully used as a safe and effective access site to complete diagnostic coronary angiography and intervention.



## Lead author biography

My name is Dr Adam Csavajda. I was born in Kecskemet, Hungary on 20 September 1992. I studied Medicine at University of Szeged where I completed my Master's degree in 2018. Since 2018 I'm a Cardiology resident at the Bacs-Kiskun County Hospital, Department of Invasive

Cardiology. I have particular interest in Emergency Medicine so I also work as an Emergency Physician in the Emergency Care Unit at the same hospital since 2019. My clinical and academic interests are acute coronary syndrome, percutaneous coronary interventions and angiology.

## Supplementary material

Supplementary material is available at *European Heart Journal - Case Reports* online.

**Slide sets:** A fully edited slide set detailing this case and suitable for local presentation is available online as [Supplementary data](#).

**Consent:** The authors confirm that written consent for submission and publication of this case report including images and associated text has been obtained from the patient in line with COPE guidelines.

**Conflict of interest:** none declared.

**Funding:** none declared.

## References

1. Ewig S, Torres A. Community-acquired pneumonia as an emergency: time for an aggressive intervention to lower mortality. *Eur Respir J* 2011;**38**:253–260.
2. Ivancev K, Resch T, Malina M. Novel access technique facilitating carotid artery stenting. *Vascular* 2006;**14**:219–222.
3. Syed MI, Sinnathamby S, Shaikh A, Tyrrell R, Neravetla S, Morar K. Percutaneous superficial temporal artery access for carotid artery stenting in patients with a hostile aortic arch. *J Endovasc Ther* 2011;**18**:729–733.
4. Pinar YA, Govsa F. Anatomy of the superficial temporal artery and its branches: its importance for surgery. *Surg Radiol Anat* 2006;**28**:248–253.

- 
5. Nardai S, Végh E, Óriás V, Nemes B, Tóth J, Hüttl A et al. Feasibility of distal radial access for carotid interventions: the RADCAR-DISTAL pilot study. *EuroIntervention* 2020;**15**:1288–1290.
6. Hou K, Guo Y, Xu K, Yu J. Clinical importance of the superficial temporal artery in neurovascular diseases: a PRISMA-compliant systematic review. *Int J Med Sci* 2019;**16**:1377–1385.