

Free-style Approach to the Pedicled Lower Medial Thigh Perforator Flap

Keith Koh, MBBS, MMED

Yuan Kong, MBBS, MD

Mei Ling Loh, MBBS, MMED

Yijun Wu, MBBS, MMED, FAMS

Chong Han Pek, MBBS, MMED,
FAMS

Summary: Soft tissue reconstruction around joints such as the knee requires a few additional considerations compared with other regions. The overlying skin must be pliable, with adequate distensibility to maintain the range of motion as a hinge joint, and ideally be replaced with “like-for-like” tissue to restore its delicate contour. The advent of perforator flaps has provided reconstructive surgeons with thin, pliable flaps conferring superior aesthetic results, good preservation of joint range of motion, and less donor site morbidity. Utilizing locoregional options also allows replacement with “like-for-like.” We retrospectively reviewed lower medial thigh perforator flaps performed for traumatic and debrided infected knee wounds, using a free-style approach to flap harvest. The described technique was found to be reliable, with consistent anatomy. All flaps survived and successfully covered small- to medium-sized critical defects in healthy individuals and those with multiple comorbidities. (*Plast Reconstr Surg Glob Open* 2021;9:e3848; doi: [10.1097/GOX.0000000000003848](https://doi.org/10.1097/GOX.0000000000003848); Published online 4 October 2021.)

INTRODUCTION

Fasciocutaneous flaps offer an ideal alternative to the conventional gastrocnemius workhorse flap, providing thin, pliable, and aesthetically superior soft tissue coverage. Perforator flaps from the lower medial thigh region have been described using various nomenclatures,^{1–3} owing to a complex vascular network around the knee.

The lower medial thigh perforator (LMTP) flap was described by Scaglioni et al in 2015 as a free perforator flap for head and neck reconstruction, and later as a propeller flap for knee reconstruction.⁴ We present our experience with six cases, using a free-style approach to the pedicled LMTP flap for reconstruction of knee defects.

MATERIALS AND METHODS

A retrospective review was conducted for all patients with critical knee defects (eg, exposed bone, tendon, or implant requiring soft tissue coverage) requiring flap reconstruction from September 2017 to September 2020 in a single tertiary center.

Patient demographic data, defect characteristics, flap reconstruction performed, perioperative details, and outcomes were collected before analysis. Patient identifiers

were not included. Institutional review board approval was obtained for the data collected.

Flap Anatomy

Perforators to the LMTP flap may arise from any four arterial sources: the superficial femoral artery, descending genicular artery (DGA), saphenous artery, and superomedial genicular artery (SMGA). The DGA originates from the superficial femoral artery at the level of the adductor hiatus (11.9–17 cm above the joint line) and has a robust branching system that includes the saphenous artery, muscular branches, and osteoarticular branches.^{5,6} The superomedial genicular artery originates from the popliteal artery at an average of 4 cm above the medial condyle, 2 cm medial to the longitudinal axis of the leg. The origin of the saphenous artery is variable and may be absent. When present, it may arise as a branch of the DGA or originate directly from the femoral or popliteal artery.⁶ These serve as a reliable source of skin perforators for flaps in the medial knee and distal thigh, with a highly variable angiosome area. Furthermore, many anastomoses exist between these arteries in this region.

Surgical Technique for the Lower Medial Thigh Perforator Flap

The LMTPs were identified preoperatively using a hand-held vascular Doppler. A V-Y rotation-advancement skin paddle design was then marked out around these perforators, guided by medial thigh tissue laxity (Fig. 1). The thigh was routinely positioned on a stack of surgical towels to flex the knee to about 30 degrees flexion, allowing the critical knee defect (eg, exposed bone tendon or implant requiring soft

From the Department of Plastic, Reconstructive and Aesthetic Surgery, Khoo Teck Puat Hospital, Singapore.

Received for publication May 18, 2021; accepted August 10, 2021.

Copyright © 2021 The Authors. Published by Wolters Kluwer Health, Inc. on behalf of The American Society of Plastic Surgeons. This is an open-access article distributed under the terms of the [Creative Commons Attribution-Non Commercial-No Derivatives License 4.0 \(CCBY-NC-ND\)](https://creativecommons.org/licenses/by-nc-nd/4.0/), where it is permissible to download and share the work provided it is properly cited. The work cannot be changed in any way or used commercially without permission from the journal.

DOI: [10.1097/GOX.0000000000003848](https://doi.org/10.1097/GOX.0000000000003848)

Disclosure: The authors have no financial interest to declare in relation to the content of this article.

tissue coverage) to be reconstructed on stretch. Subfascial elevation of flaps was performed (Fig. 2) until the perforators could be identified in the interface between the vastus medialis and sartorius muscles, over the distal third of the medial thigh. Perforator dissection may be performed further proximally to maximize the degree of flap advancement. Suction drains were placed in the subcutaneous plane before layered closure (Fig. 3) of the flap inset and donor site.

Postoperatively, our patients were placed on an incisional negative pressure wound therapy dressing and a knee-spanning backslab for the first 5 days before conversion to a functional knee brace. Protected weight bearing was gradually allowed from 2 weeks postsurgery.

RESULTS

Twenty flap reconstructions for critical knee defects were performed during the study period. Of these 20 flaps, there were 10 pedicled gastrocnemius (medial or lateral) muscle flaps, six pedicled LMTP flaps, and four local flaps.

The average age of patients who underwent LMTP flaps was 58.5 years. The most prevalent comorbidities within each patient group were smoking, diabetes, and ischemic heart disease.

Most wounds were a result of either trauma from motor vehicle accidents (40%) or infection (55%). The majority (90%) were moderate- to large-sized defects. Twenty percent of the defects extended to involve the distal thigh or proximal tibia.

All flaps survived and provided successful soft tissue coverage of critical knee defects. Overall complication rate was 5% (1 of 20): One gastrocnemius flap was complicated by superficial infection requiring debridement. Time taken to complete wound healing and length of hospital stay was expectedly shortest for local flaps (21 days and 5.5 days) and longest for gastrocnemius flaps (41.2 days and 20 days). This is likely reflective of more severe injuries and larger wound sizes in the gastrocnemius flap group.

DISCUSSION

With the reintroduction of fasciocutaneous flaps by Pontén in 1981 and subsequent perforator vascular studies

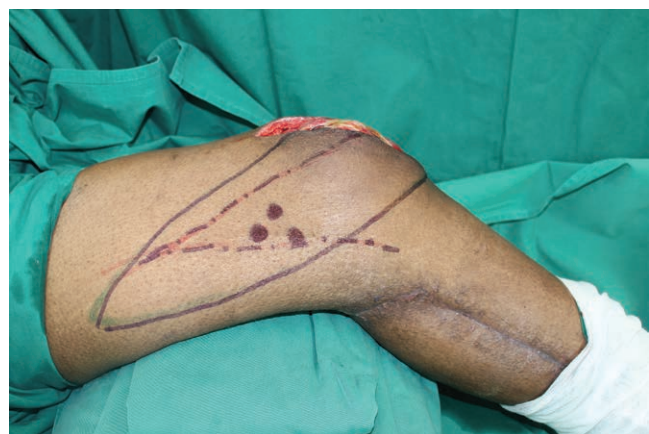

Fig. 1. Marked perforators and V-Y skin paddle design for anterior knee defect.

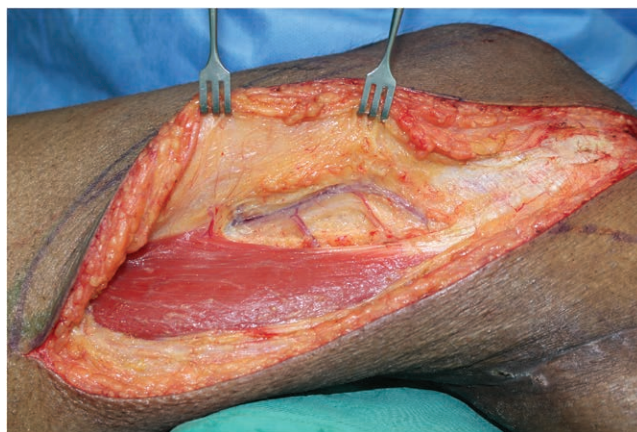


Fig. 2. The lower medial thigh perforator flap.

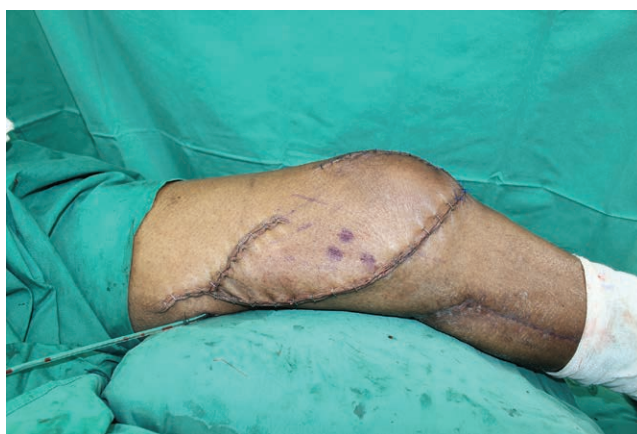

Fig. 3. Flap inset and closure.

by Nakajima et al, a new paradigm in flap selection protocols emerged for lower extremity reconstruction.⁷ Furthermore, the concept of free-style flaps by Wei and Mardini⁸ has been extrapolated to applications in perforator flap harvest in the upper medial thigh,⁹ termed “upper medial thigh perforator flap” to reflect the heterogeneity of perforators in this region. Similarly, the angiosomes over the lower medial thigh are highly variable, and a free-style approach to raising flaps in this region would likewise be applicable.

In our series of cases, the LMTPs were found to be reliably present, allowing safe flap elevation up to the mid-thigh. Most of the identified perforators were found to arise from the DGA arterial system (Fig. 4). Laxity of tissue around the thigh allowed easy mobilization of the flap, tension-free inset, and primary closure of the donor site. In contrast, the use of a more conventional gastrocnemius flap and skin graft would have resulted in two donor sites (calf and thigh), some functional loss from the harvest of a muscle, and a poorer color match.

Knee Reconstruction Algorithm

Despite its advantages, the LMTP flap is not a “one-size-fits-all” option, and we recognize that some situations still warrant a conventional muscle flap. Main defect-related considerations in flap selection included the (1)

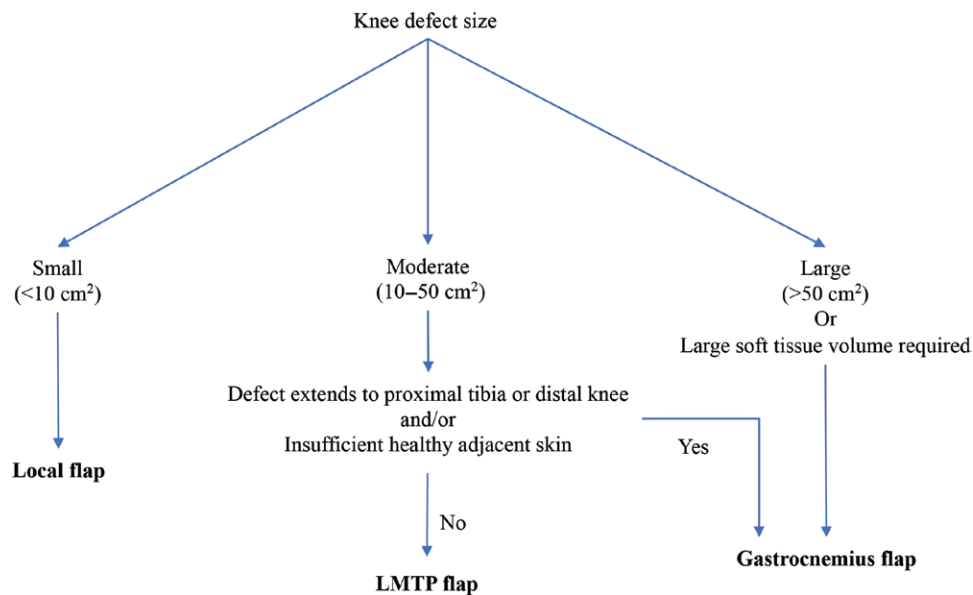


Fig. 4. Knee reconstruction algorithm.

wound etiology, (2) size of the critical defect and whether this extended beyond the knee to involve the distal thigh or proximal tibia region, and (3) availability of the LMTP and skin as a donor site.

Taking these factors into consideration, our observations suggest that the vast majority of defects around the knee can be reconstructed using one of the three techniques: LMTP flap, pedicled gastrocnemius muscle flap, or local flap. The LMTP flap can be safely used for moderate-sized (10–50 cm²) knee defects arising from both trauma and infection. Our series has also proved its efficacy in patients with multiple comorbidities. However, large defects may still require the conventional gastrocnemius muscle flap, which was the favored option in half of our cases.

SUMMARY

Soft tissue reconstruction around joints such as the knee requires a few additional considerations compared with other regions. The overlying skin must be pliable with adequate distensibility to maintain the range of motion as a hinge joint, and ideally replaced with “like-for-like” tissue to restore its delicate contour.

The advent of perforator flaps has provided reconstructive surgeons with thin pliable flaps conferring superior aesthetic results, good preservation of joint range of motion, and less donor site morbidity. Utilizing locoregional options also allows replacement of like with like tissue. Furthermore, donor sites are limitless as long as a significant perforator can be identified, and can be fashioned locally as a pedicled rotation, advancement, or propeller flap.¹⁰

The LMTP flap is a reliable alternative to the conventional gastrocnemius muscle flap for knee reconstruction, worthy to be included in the reconstructive armamentarium. It is simple to perform, obviates the need for two donor sites, does not require muscle harvest, and allows primary closure of the donor site with a scar inconspicuously placed in the medial thigh. As the

evolution of lower extremity reconstruction continues in this new paradigm of perforator flaps, this represents yet another step forward in our quest to balance simplicity and reliability to find the “best flap” for various lower extremity wounds.

Keith Koh, MBBS, MMED
National Healthcare Group
Singapore
E-mail: keithkoh22@gmail.com

REFERENCES

- Hayashi A, Maruyama Y. The medial genicular artery flap. *Ann Plast Surg.* 1990;25:174–180.
- Sananpanich K, Kraissarin J. Descending genicular artery free flaps: Multi-purpose tissue transfers in limb reconstruction. *J Plast Reconstr Aesthet Surg.* 2015;68:846–852.
- Mojallal A, Boucher F, Shipkov H, et al. Superficial femoral artery perforator flap: Anatomical study of a new flap and clinical cases. *Plast Reconstr Surg.* 2014;133:934–944.
- Scaglioni MF, Giunta G, Barth AA, et al. Lower medial thigh perforator (LMTP) propeller flap for reconstruction of soft tissue defects around the knee. *Microsurgery.* 2020;40:298–305.
- Sananpanich K, Athakomol P, Luevitonvechki S, et al. Anatomical variations of the saphenous and descending genicular artery perforators: Cadaveric study and clinical implications for vascular flaps. *Plast Reconstr Surg.* 2013;131:363e–372e.
- Hirtler L, Lübbers A, Rath C. Vascular coverage of the anterior knee region - an anatomical study. *J Anat.* 2019;235:289–298.
- Hallock GG. A paradigm shift in flap selection protocols for zones of the lower extremity using perforator flaps. *J Reconstr Microsurg.* 2013;29:233–240.
- Wei FC, Mardini S. Free-style free flaps. *Plast Reconstr Surg.* 2004;114:910–916.
- Eom JS, Sun SH, Hong JP. Use of the upper medial thigh perforator flap (gracilis perforator flap) for lower extremity reconstruction. *Plast Reconstr Surg.* 2011;127:731–737.
- AlMugaren FM, Pak CJ, Suh HP, et al. Best local flaps for lower extremity reconstruction. *Plast Reconstr Surg Glob Open.* 2020;8:e2774.