

Suprachoroidal Buckling: Technique and Indications

Ehab N El Rayes, MD, PhD; Ebrahim Elborgy, MD

Retina Department, Institute of Ophthalmology, Cairo, Egypt

The authors herein report the feasibility of suprachoroidal buckling (SCB) procedure as a new approach for treating different forms of retinal detachment (RD) by creating suprachoroidal indentation (buckling effect). With this technique, specially designed devices, i.e. a catheter or cannula, are guided in the suprachoroidal space to reach the target area. Then, a suprachoroidal filler (long lasting hyaluronic acid) is injected to indent the choroid creating SCB, thereby closing retinal tears and supporting the overlying retina. This procedure was performed to treat both myopic tractional maculopathy (MTM), including myopic macular holes, as well as peripheral retinal breaks. SCB may be used alone or in conjunction with vitrectomy. In myopic patients, restoration of retinal layers was achieved in all eyes with myopic foveoschisis. Most eyes with macular hole detachments demonstrated closure of the holes. All peripheral retinal breaks were adequately buckled and closed in a single procedure. The buckling effect was long enough in duration to seal the tears and promote adequate chorioretinal scarring. The procedure was safe and relatively simple in terms of reaching the treatment area and injecting the filler. SCB adds to our surgical options for treating selected cases of peripheral retinal tears and rhegmatogenous RD, and avoids potential problems of episcleral buckles. Moreover it may avoid vitrectomy in selected cases of rhegmatogenous RD.

Keywords: Suprachoroidal Buckling; Retinal Detachment; Myopic Holes; Myopic Foveoschisis; Peripheral Breaks

J Ophthalmic Vis Res 2013; 8 (4): 393-399.

Correspondence to: Ehab N. El Rayes, MD, Ph.D. Retina Department, Institute of Ophthalmology, 35 Salah Salem, El Obour Bldg, Suite 702, Cairo, Egypt; Tel: +20 2 2402 6225, Fax: +20 2 2402 6225; e-mail: Retina-clinic@hotmail.com

Received: June 18, 2013

Accepted: November 22, 2013

INTRODUCTION

Scleral buckles in conjunction with chorioretinal adhesions around retinal breaks form the basis of therapy for many uncomplicated rhegmatogenous retinal detachments (RRDs). Vitrectomy and gas or even Pnuematic retinopexy all share in the concept of preventing fluid from reaching subretinal space via retinal breaks.¹ Scleral buckling brings the retina into contact with the treated choroid around retinal tears.² This is accomplished by indenting both

the sclera and the choroid toward the retina, but the procedure is associated with potential problems with ocular motility depending on the size and location of the buckle.

Based on the rationale of indenting the choroid alone to close the retinal tear through the suprachoroidal space, we demonstrate a novel technique using a specially designed catheter to inject a suprachoroidal filler (long lasting hyaluronic acid) in the suprachoroidal space. The filler creates a pass to displace the choroid creating an indentation effect similar to

a buckle. This is accomplished through a 3 mm incision, through which the catheter is guided toward the retinal tear, thus avoiding potential difficulties of placing scleral buckles.

Apart from peripheral tears, the indentation achieved by suprachoroidal buckling (SCB) can be used as an alternative method for managing myopic tractional maculopathy (MTM). MTM is a descriptive terminology for schisis like thickening in outer retinal layers of highly myopic eyes with posterior staphyloma, also known as myopic foveoschisis. In addition to the schisis thickening, findings may also include inner retinal fluid accumulation, foveal detachment, and lamellar or even full thickness macular holes.^{3,4}

Management of MTM has focused on eliminating epiretinal traction forces by means of par plana vitrectomy (PPV) with or without internal limiting membrane (ILM) peeling in several reports.⁵⁻¹¹ Macular buckling is a well-established technique through which the posterior scleral wall is supported and traction forces on the vitreomacular interface in the area of the staphyloma are released. Several reports have shown favorable results from applying different forms of episcleral macular buckles (EMB) for MTM. Several types and modifications of materials used for EMB have decreased difficulties and complications of placing these buckles on the thin scleral wall from the outside of the globe. Yet, there is a learning curve and a challenge in proper localization of the buckle, as well as fixation of the EMB in some eyes with extremely thin sclera and long axial length.




Figure 1. The specially designed catheter; one arm is connected to a light source and the other is connected to the filler material.

The novel technique we present herein creates a choroidal buckle through the suprachoroidal space, for management of posterior retinal pathologies such as vitreoretinal interface problems in myopic patients and peripheral retinal tears. This technique circumvents difficulties of scleral buckling in the macular area by direct and controlled delivery of a buckle-like effect (indentation) in the suprachoroidal space in the area of the staphyloma. The procedure creates choroidal indentation, relieving traction at the vitreomacular interface.

SURGICAL TECHNIQUE

We use a 450 μm catheter (El Rayes Flextip Catheter; MedOne Surgical, Sarasota, USA) (Figure 1). It has dual injection-illumination capability. One end connected to a regular bright illumination light source which illuminates a 39-gauge light fiber when placed in the suprachoroidal space. The other end on the catheter is connected to high-pressure tubing to deliver stabilized (naturally entangled) long lasting hyaluronic acid (HA) filler (Perlane; Q-med, Sweden) to the injection port of the catheter when placed in the suprachoroidal space. This works for both posterior pole retinal pathologies and peripheral breaks.

Recently, as an alternative to the illuminated tip catheter, we successfully used a non-illuminated 20-gauge curved cannula with an olive tip for injecting the filler and creating a suprachoroidal buckling effect. The advantage of the olive tip is that it acts as a choroidal



Figure 2. The suprachoroidal cannula, notice the olive tip acting as a gentle choroidal depressor.

depressor (Figure 2). But this cannula can be used for peripheral pathology only; it cannot be guided into the postequatorial region.

For the filler substance to create the dome we use Restylane which is a high purity gel containing non-animal hyaluronic acid stabilized with minimal modification resulting in a long-lasting three dimensional (3D) gel network with excellent safety profile. This filler is known to last 8 to 12 months in dermal tissues and is used for restoring space and contour by its gel strength. The strength of the gel depends on the total number of crosslinkings between HA disaccharides (both chemical and natural entanglement). Shorter acting substances such as Healon 5 (Abbott Medical Optics, Santa Ana, CA, USA) may also be used for treating peripheral breaks since it remains for 2-3 weeks in the suprachoroidal space which is enough to create choroiretinal adhesion after treating the break.

Technique for Rhegmatogenous Retinal Detachment

This technique may be done with or without vitrectomy. If performed along with vitrectomy, a chandelier light (25 gauge or smaller) is placed at 12 o'clock position (or any other quadrant if the tears are at 12 o'clock). Then the operating microscope and wide-angle viewing system are used to examine the fundus. The tear site is located using direct illumination from the chandelier. The tear is indented and marked applying the microscope viewing system. The conjunctiva in the quadrant of the tear is incised and a 3 mm circumferential sclerotomy, 4 mm from the limbus, is performed to expose the choroid. We then create a 1-2 mm pocket for introduction of the suprachoroidal catheter. The catheter is then threaded through the sclerotomy in the suprachoroidal space towards the tear location, pushing against the scleral wall in the suprachoroidal space. Once the proper location is achieved (assisted with illumination from the catheter under the middle of the tear), injection of the filler material is started. This results in controlled choroidal indentation that expands in height and direction as desired, as in adjusting

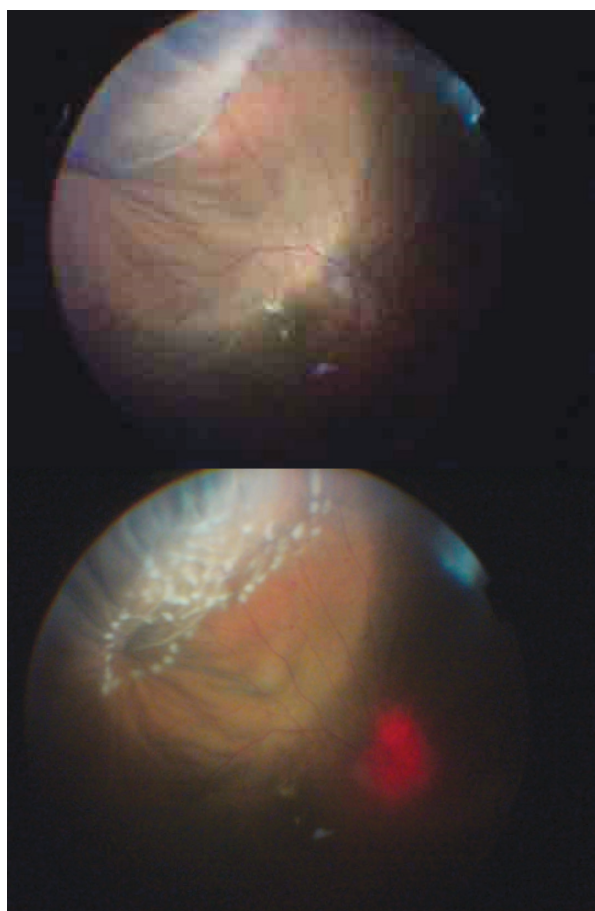


Figure 3. Intraoperative view of the suprachoroidal buckle: top image, the dome shaped elevation created by suprachoroidal buckling; lower image, post laser application at the same area.

episcleral buckle height and location (Figure 3). The procedure usually requires 0.2-0.5 ml of suprachoroidal gel and is accompanied by anterior chamber paracentesis or subretinal fluid drainage to control intraocular pressure (IOP).

The catheter helps in targeting posteriorly located breaks irrespective of the anterior location of the sclerotomy. If two or more tears are close to each other (within 1-2 clock hours), the same entry site can achieve buckling effect for all of them. The specially developed cannula may also be used with this technique and provides the advantage of gentle choroidal indentation to examine the breaks; furthermore it can reach 2-3 clock hours on either side of the entry site (Figure 4). Once the tear is closed by the suprachoroidal buckle, the catheter is withdrawn and the sclerotomy is immediately

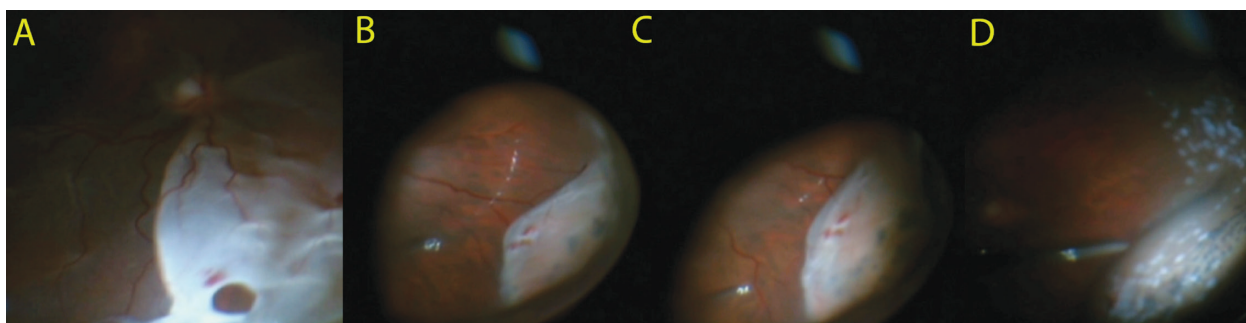


Figure 4. Composite intraoperative picture: A, open break; B, depressing the tear site with the cannula; C, after injecting the suprachoroidal filler; D, laser application to the break site.

closed by sutures. The conjunctiva is closed with sutures and the chandelier is removed from the eye. Next the tear is treated by indirect laser ophthalmoscopy. IOP is rechecked and the need for another paracentesis is re-evaluated (this step is not essential if the buckling process is part of a vitrectomy procedure).

Technique for Myopic Traction Maculopathy

In macular buckling, the surgical procedure for all patients is a standard three-port, 25 gauge PPV and dissection of the posterior hyaloid. Then the same technique of suprachoroidal buckling as for RRD is adopted, however, care is taken while attempting to cross the edges of the posterior staphyloma as the choroid is extremely thin especially at the superior edge of the staphyloma. Prior to crossing this site, we inject a small amount of filler to dissect and lift the choroid at the edge, prior to pushing the catheter into the area of the posterior staphyloma.

Once the catheter is placed in the suprachoroidal space underneath the target

tissue (foveoschisis or macular hole), we inject the filler to dissect the thin choroid towards the retina creating an indentation effect bypassing the staphyloma. This effect restores the normal contour of the choroid or even indents it to a convex configuration supporting the retina. The illuminated tip of the catheter is seen with ease in patients with foveoschisis and in patients with macular holes associated with shallow posterior pole detachment (Figure 5). Fluid/air exchange is used prior to filler injection, if the subretinal fluid is extensive enough to obscure the catheter tip light.

DISCUSSION

The surgical options in treating RRDs evolved over the years. All of these options are based on closing retinal tears as a key issue and eliminating traction forces on the retina or indenting the chorio-scleral wall to close the retinal break. Even pneumatic closure of the tear and creating a chorioretinal reaction is sometimes adequate for repair.¹²

Undoubtedly, scleral buckles help to reduce vitreous traction and diminish the flux of vitreous fluid through retinal tears, thus promoting reposition of the retina to the retinal pigment epithelium (RPE).¹² Achieving this goal through the suprachoroidal space avoids some of the difficulties associated with episcleral buckles. We were inspired to treat peripheral retinal pathologies after our initial experience with suprachoroidal buckles for myopic vitreomacular interface problems.¹³

The base of this technique is only choroidal (not scleral) buckles efficiently to close retinal

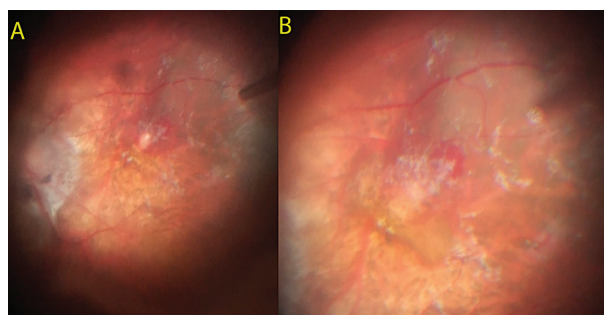


Figure 5. Intraoperative images: A, cannula tip light under the macular hole in a posterior staphyloma in a myopic patient; B, Post-injection, notice the choroidal buckling effect created at the site of break closure.

tears and to support the retina. Applying a catheter to achieve this provides us with the option of a small incision with navigation in the suprachoroidal space to reach the target area irrespective of location. The limitation of one incision is that we treat single or a group of tears in one to two clock hours.

The Catheter can be used to treat inferior breaks as well as breaks in cases of recurrent inferior retinal detachment under silicone oil by creating a choroidal buckling support effect. Certainly, posteriorly located breaks are the main indication for use of this catheter, thus avoiding a long radial episcleral buckle. Furthermore, phakic retinal detachments in young myopes are another indication to avoid vitreous base shaving over a single break by the vitrectomy cutter behind the crystalline lens. This procedure also avoids refractive changes induced by episcleral buckles in patients who have previously undergone refractive surgery.

We have also learned that it is possible to augment the height of pre-existing episcleral buckles by injecting under the choroid (over the buckle) or creating a radial choroidal extension to an existing episcleral buckle. It was interesting to find in the literature ideas of choroidal indentation reported by Poole and Sudarsky in 1986. The limitation at that time was the direct injection site (using a 27 gauge cannula) and substance (1% sodium hyaluronate). Yet it worked in 14 patients for treating retinal detachments.¹⁴

As of today, we have a broad range of substances for use as suprachoroidal buckles depending on how long retinal support or chorioretinal indentation is required to achieve chorioretinal adhesions. Hyaluronic acid can be modified to a wide range of molecular weights and concentrations as well as crosslinking, resulting in variable soluble forms to gels with more resistance to resorption such as Healon (10 mg/ml), Healon GV (14 mg/ml), Healon 5 (23 mg/ml). Healaflow (Swiss Antis Company, Switzerland) is a 22.5 mg/ml preparation used by glaucoma surgeons to keep filtering blebs open; this is achieved by the characteristics of the gel: a slowly resorbable cross-linked interlacing long molecular chain.¹⁵

In our study we used Restylane Perlane (20 mg/ml hyaluronic acid), but with natural stabilization and entanglement made it a more resistant 3D gel form remaining 8-12 months in the dermis with similar duration in the suprachoroidal space (previous experience). We have also used Healon 5 (cross-linked HA by AMO) 23 mg/ml with success in peripheral retinal breaks.

So the choice of filler material depends on the pathology. We also know that even unsupported but sealed chorioretinal thermal adhesion is sufficient to seal retinal holes permanently and that removal of extruding buckles and relaxation of segmental buckles do not lead to failure of previous RD surgery if we have a well treated tear in the absence of traction. Even vitrectomy alone with air or gas in a treated tear is an effective treatment for RRD. The question of how long we need the indentation determines what substance we should use.

We have also shown that this technique could be performed with vitrectomy or as a seldom used approach, illuminating the fundus with just a chandelier with the ability to indent and direct the chandelier height to the peripheral tear and complete the procedure without need for any intravitreal instruments.

Regarding myopic vitreomacular interface problems, treatment options in the literature for myopic foveoschisis and myopic macular holes have focused on surface vitreoretinal traction as the primary mechanism for development of myopic traction maculopathy, therefore PPV with or without ILM peeling to remove the source of traction seems a logical intervention.^{5-9,16} However, several authors have reported the use of episcleral macular buckling in patients with high myopia complicated by foveoschisis associated macular hole and retinal detachment.¹⁷⁻²⁰

The aim of macular buckling is to release traction caused by the posterior staphyloma and the anterior-posterior traction caused by the vitreous cortex on the inner retina. It also brings the RPE closer to the retina, reinforcing the weak adhesion between the RPE and the neurosensory retina.^{20,21}

Certainly, suprachoroidal macular buckling requires a learning curve especially for guiding

the catheter toward the target tissue. However once mastered, the procedure has the potential to avoid difficulties in episcleral buckle placement, alignment, extrusion, problems with thin sclera and choroidal hemorrhages, as well as post-operative esotropia. We found that the suprachoroidal approach for macular buckling circumvents some of these difficulties. We can reach the target area and create the desired buckling height and choroidal indentation to support the retina.

The rationale behind this approach is to restore the normal choroidal contour by separating the choroid from the sclera and thus releasing traction on retinal layers. We have shown that suprachoroidal indentation lasts up to one year and was enough to support the retina. In our experience the suprachoroidal approach for macular buckling is very promising, both anatomically and functionally, with better control of the location and desired height of indentation. It avoids difficulties of buckle placement and fixation in eyes with thin sclera. However, caution should be exercised in eyes with thin choroid to avoid hemorrhage. This was achieved in part by developing the atraumatic tip design of the catheter, as well as proper atraumatic guidance with close attention to choroidal dissection at the edge of the staphyloma. Based on the report by Yamagishi et al²² that the choroid is markedly thinner at the upper border of a posterior staphyloma, we might consider doing an inferior crossing technique to see if it is safer.

We observed no ischemic choroidal changes at the site of choroidal indentation, perhaps because the cushion-like effect created by the indentation causes less mechanical pressure or deformation to the choroidal circulation as compared to silicone explants. We noted two cases of hyperpigmentation at the edge of the indentation which we believe was due to RPE heaping at the edge of the dome; this hyperpigmentation decreased with time.

In summary, we believe that suprachoroidal buckling using catheter guided fillers could be a surgical option for repair of selected cases of retinal detachment. This procedure achieves good chorioretinal closure of tears and avoids

potential problems associated with scleral buckles in eyes with posteriorly located breaks and thin sclera. The buckling height and location is controllable, by the amount and site of filler injection. The ability to be guided posteriorly provides this surgical approach with the advantage of treating myopic vitreomacular interface problems in highly myopic eyes.

Conflicts of Interest

None.

REFERENCES

1. American Academy of Ophthalmology. Information statement: the repair of rhegmatogenous retinal detachment. *Ophthalmology* 1990;97:1562-1572.
2. Schepens CL, Okamura ID, Brockhurst RJ. The scleral buckling procedures. 1. Surgical techniques and management. *AMA Arch Ophthalmol* 1957;58:797-811.
3. Shimada N, Ohno-Matsui K, Yoshida T, Sugamoto Y, Tokoro T, Mochizuki M. Progression from macular retinoschisis to retinal detachment in highly myopic eyes is associated with outer lamellar hole formation. *Br J Ophthalmol* 2008;92:762-764.
4. Fujimoto M, Hangai M, Suda K, Yoshimura N. Features associated with foveal retinal detachment in myopic macular schisis. *Am J Ophthalmol* 2010;150:863-870.
5. Yeh SI, Chang WC, Chen LJ. Vitrectomy without internal limiting membrane peeling for macular retinoschisis and foveal detachment in highly myopic eyes. *Acta Ophthalmol* 2008;86:219-224.
6. Ikuno Y, Tano Y. Vitrectomy for macular holes associated with myopic foveoschisis. *Am J Ophthalmol* 2006;141:774-776.
7. Kwok AK, Lai TY, Yip WW. Vitrectomy and gas tamponade without internal limiting membrane peeling for myopic foveoschisis. *Br J Ophthalmol* 2005;89:1180-1183.
8. Spaide RF, Fisher Y. Removal of adherent cortical vitreous plaques without removing the internal limiting membrane in the repair of macular detachment in highly myopic eyes. *Retina* 2005;25:290-295.
9. Kuhn F. Internal limiting membrane removal for macular detachment in highly myopic eyes. *Am J Ophthalmol* 2003;136:477-481.
10. Shimada N, Sugamoto Y, Ogawa M, Takase H, Ohno-Matsui K. Foveal-sparing internal

- limiting membrane peeling for myopic traction maculopathy. *Am J Ophthalmol* 2012;154:693-701.
11. Kanda S, Uemura A, Sakamoto Y, Kita H. Vitrectomy with internal limiting membrane peeling for macular retinoschisis and retinal detachment without macular hole in highly myopic eyes. *Am J Ophthalmol* 2003;136:177-180.
 12. Wilkinson CP, Rice TA. Michel's retinal detachment. 2nd ed. St Louis: Mosby; 1997.
 13. El Rayes EN. Suprachoroidal buckling: A novel approach in treating vitreomacular interface disorders in severe myopia: Initial 1-year data. Annual ASRS symposium syllabus, Las Vegas, NV, USA. August 26, 2012.
 14. Poole TA, Sudarsky D. Suprachoroidal implantation for treatment of retinal detachment. *Ophthalmology* 1986;93:1408-1412.
 15. Roy S, Thi HD, Feusier M, Mermoud A. Crosslinked sodium hyaluronate implant in deep sclerotomy for surgical treatment of glaucoma. *Eur J Ophthalmol* 2012;22:70-76.
 16. Ho TC, Chen MS, Huang JS, Shih YF, Ho H, Huang YH. Foveola nonpeeling technique in internal limiting membrane peeling of myopic foveoschisis surgery. *Retina* 2012;32:631-634.
 17. Ando F, Ohba N, Touura K, Hirose H. Anatomical and visual outcomes after episcleral buckling compared with those after pars plana vitrectomy for retinal detachment caused by macular hole in highly myopic eyes. *Retina* 2007;27:37-44.
 18. Ripandelli G, Coppé AM, Fedeli R, Parisi V, D'Amico DJ, Stripe M. Evaluation of primary surgical procedures for retinal detachment with macular hole in highly myopic eyes: a comparison of vitrectomy versus posterior episcleral buckling surgery. *Ophthalmology* 2001;108:2258-2264, discussion 2265. Erratum in: *Ophthalmology* 2002;109:222.
 19. Theodossiadis GP and Theodossiadis PG. The macular buckling procedure in the treatment of retinal detachment in highly myopic eyes with macular hole and posterior staphyloma: mean follow up of 15 years. *Retina* 2005;25:285-289.
 20. Mateo C, Burés-Jelstrup A, Navarro R, Corcóstegui B. Macular buckling for eyes with myopic foveoschisis secondary to posterior staphyloma. *Retina* 2012;32:1121-1128.
 21. Ichibe M, Yoshizawa T, Murakami K, Ohta M, Oya Y, Yamamoto S, et al. Surgical management of retinal detachment associated with myopic macular hole: anatomic and functional status of the macula. *Am J Ophthalmol* 2003;136:277-284.
 22. Yamagishi T, Koizumi H, Yamazaki T, Kinoshita S. Choroidal thickness in inferior staphyloma associated with posterior serous retinal detachment. *Retina* 2012;32:1237-1242.