

## ORIGINAL ARTICLE

# Classification of Metastatic versus Non-Metastatic Axillary Nodes in Breast Cancer Patients: Value of Cortex-Hilum Area Ratio with Ultrasound

Sung Eun Song, Bo Kyoung Seo, Seung Hwa Lee, Ann Yie<sup>1</sup>, Ki Yeol Lee, Kyu Ran Cho<sup>2</sup>, Ok Hee Woo<sup>3</sup>, Sang Hoon Cha, Baek Hyun Kim

Department of Radiology, Korea University Ansan Hospital, Korea University College of Medicine, Ansan; <sup>1</sup>Department of Radiology, Seoul National University College of Medicine, Seoul; <sup>2</sup>Department of Radiology, Korea University Anam Hospital, Korea University College of Medicine, Seoul; <sup>3</sup>Department of Radiology, Korea University Guro Hospital, Korea University College of Medicine, Seoul, Korea

**Purpose:** To investigate the significance of the cortex-hilum (CH) area ratio and longitudinal-transverse (LT) axis ratio and the blood flow pattern for diagnosis of metastatic axillary lymph nodes by ultrasound in breast cancer patients. **Methods:** From October 2005 to July 2006, we prospectively evaluated axillary nodes with ultrasound in 205 consecutive patients who had category 4B, 4C or 5 breast lesions according to the Breast Imaging Reporting and Data System-Ultrasound (BI-RADS-Ultrasound<sup>®</sup>). Among the 205, there were 24 patients who had pathologic verification of breast cancer and axillary lymph node status. For a total of 80 axillary nodes we measured the areas of the cortex and hilum of lymph nodes and calculated the area ratio. We also measured the length of the longitudinal and transverse axis of the lymph nodes and calculated the length ratio. We evaluated the blood flow pattern on power Doppler imaging and classified each lymph node into a central or peripheral pattern. Diagnostic performance was analyzed according to positive criteria for lymph node metastasis (CH area ratio >2, LT axis ratio <2, peripheral type on power

Doppler imaging). **Results:** The sensitivity of the CH area ratio was superior to that of the LT axis ratio (94.1% vs. 82.3%,  $p=0.031$ ) and to that of the blood flow pattern (94.1% vs. 29.4%,  $p=0.009$ ). For specificity, all three evaluating parameters had high values (89.1-95.6%) and no significant differences were found ( $p=0.121$ ). The CH area ratio had a better positive predictive value than the LT axis ratio (94.1% vs. 80.0%,  $p=0.030$ ) and power Doppler imaging (94.1% vs. 66.6%,  $p=0.028$ ). For the negative predictive value, the CH area ratio was superior to the LT axis ratio (95.6% vs. 86.6%,  $p=0.035$ ) and the blood flow pattern (95.6% vs. 63.0%,  $p=0.027$ ). **Conclusion:** We recommend the CH area ratio of an axillary lymph node on ultrasound as a quantitative indicator for the classification of lymph nodes. The CH area ratio can improve diagnostic performance when compared with the LT axis ratio or blood flow pattern.

**Key Words:** Breast, Lymph nodes, Lymphatic metastasis, Ultrasonography

## INTRODUCTION

Axillary lymph node status is significant for staging and treatment planning in women with breast cancers because it is the most important prognostic factor [1]. The presence of nodal metastases decreases 5-year survival by approximately 40% compared to node-negative patients [2].

In recent years, the sentinel lymph node biopsy has replaced axillary lymph node dissection for nodal staging. The sentinel

lymph node is the hypothetical first lymph node or group of nodes reached by metastasizing cancer cells from a primary tumor. If the sentinel node is not cancerous, there is a high likelihood that the cancer has not spread to any other area of the body. The sentinel lymph node biopsy is performed to predict the indication of axillary node dissection. However, slow or faulty radiotracer distribution, extended operating time, and prompt decisions based on the analysis of frozen sections by pathologists are problems of sentinel lymph node biopsy [3-7]. The sentinel lymph node biopsy has 1-15% false negative results, which leads to the axillary lymph node dissection not being performed in patients with a negative sentinel node biopsy but who in fact have axillary metastases [6].

Thus, less invasive modalities such as ultrasound (US), power Doppler US, mammography, computed tomography

**Correspondence:** Bo Kyoung Seo and Seung Hwa Lee

Department of Radiology, Korea University Ansan Hospital, Korea University College of Medicine, 123 Jeokgeum-ro, Danwon-gu, Ansan 425-707, Korea  
Tel: +82-31-412-5228, Fax: +82-31-412-5224  
E-mail: seoboky@korea.ac.kr, yaaong@hitel.net

Received: September 4, 2011 Accepted: February 13, 2012

(CT), dynamic contrast enhanced magnetic resonance imaging (MRI) and positron emission tomography (PET) have been increasingly attempted to stage an axillary lymph node preoperatively and to diagnose a malignant lymph node.

US had been the most widely used method for the evaluation of lymph nodes [8,9]. Moreover, preoperative lymph node staging with US combined with either fine needle aspiration or core needle biopsy can achieve high diagnostic accuracy [5,9]. The assessment of axillary nodal status, size, morphology, cortical thickness, and vascularity are used as feasible diagnostic criteria. Of these criteria, longitudinal-transverse (LT) axis ratio, concentric or eccentric cortical thickening, and absent or displaced fatty hilum on gray scale US and higher peripheral vascularity on power Doppler US are reported as the most reliable criteria for predicting metastatic lymph nodes [10-13]. However, some criteria such as cortical thickening or displaced fatty hilum are subjective.

The purpose of this study was to investigate the significance of the cortex-hilum (CH) area ratio and LT axis ratio on gray-scale imaging, and vascularity on power Doppler imaging for decisions regarding axillary lymph node metastasis in breast cancer patients.

## METHODS

This prospective study was approved by our Institutional Review Board. From October 2005 to July 2006, we examined axillary lymph nodes by US in 205 patients who had category 4B, 4C, or 5 breast lesions according to the Breast Imaging Reporting and Data System-Ultrasound (BI-RADS-Ultrasound®) [14]. Among the 205, there were 24 patients who had pathologic verification of breast cancer and axillary lymph node status. These patients had no history of surgical excision, neoadjuvant chemotherapy or radiation therapy for breast cancers during US examination. A total of 80 nodes were pathologically verified by US-guided core biopsy (n = 44), US-guided fine needle aspiration (n = 20), or surgical excision after needle localization (n = 16) for node-to-node correlation with histopathology and US results. The lymph nodes were prospectively examined using gray-scale and power Doppler US. Patients ranged in age from 32 to 59 years (mean, 43.5 years) and all patients were female.

### US examination

We examined axillary lymph nodes with iU 22 or HDI 5000 SonoCT (Philips Medical Systems, Bothell, USA) using linear high frequency transducers with 5-12 MHz broad band width. The patient was placed in the supine or contralateral side-down oblique position on the table, with the ipsilateral

hand placed behind the head. A breast radiologist who had 7 years of breast imaging experience scanned both the axillae in transverse and longitudinal directions.

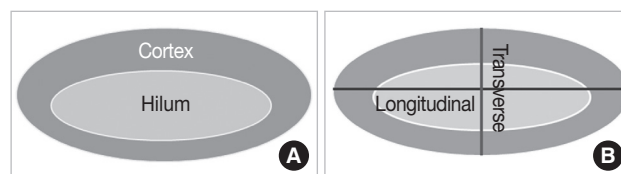
Initially, gray scale imaging was used for detection of a lymph node. Spatial compound or tissue harmonic imaging was used for improving image contrast if necessary. If an enlarging lymph node was found on US, we obtained the image at the section of the maximum size of the lymph node. We traced the hypoechoic cortical portion and hyperechoic hilar portion on the US monitor and measured the areas (cm<sup>2</sup>) of the cortex and hilum of the lymph node at the section of the maximum size of the lymph node. We then obtained the CH area ratio (area of cortex/area of hilum) (Figure 1A). If a node had complete loss of hilum due to severe cortical thickening, the CH area ratio was an infinite value, and we considered the CH area ratio as more than 2. We measured the length (cm) of the longitudinal and transverse diameter of the lymph node, respectively, and calculated the LT axis ratio (longitudinal diameter/transverse diameter) (Figure 1B).

Power Doppler US was performed with low-velocity parameter settings and high gain using a slow scanning technique. We evaluated the vascularity of the lymph nodes and classified them into one of three types: 1) peripheral type that had abundant blood flow at the peripheral cortex of the lymph node, 2) central type that had abundant blood flow at the hilum of the lymph node, or 3) no blood flow type (Figure 2). If a node had the same amount of blood flow in the cortex and hilum, we considered it as peripheral type.

US results were considered to be positive when the CH area ratio was greater than 2 and the LT axis ratio was less than 2 on gray scale imaging, and the blood flow pattern was the peripheral type on power Doppler imaging.

### Statistical analyses

Diagnostic performances including sensitivity, specificity, accuracy, positive predictive value (PPV), and negative pre-



**Figure 1.** Drawings illustrate how to obtain cortex-hilum area ratios and longitudinal-transverse axis ratios of a lymph node on gray-scale ultrasound imaging. (A) We traced the outer margins of hypoechoic cortex and hyperechoic hilum of a lymph node and obtained areas (cm<sup>2</sup>) of each site at the section of the maximum size of a lymph node. And then we calculated the cortex-hilum area ratio. (B) We measured lengths (cm) of longitudinal and transverse diameters at the section of the maximum size of a lymph node and then calculated the longitudinal-transverse axis ratio.

dictive value (NPV) for the diagnosis of an axillary node were calculated for US findings. The probability of malignancy was dichotomized for assessment of diagnostic performances. An LT axis ratio < 2, CH area ratio > 2, or peripheral blood pattern by US was defined as 'positive' for the purpose of calculating diagnostic parameters. Diagnostic performances were based on pathologic results or follow-up images. If a lymph node had a benign histopathologic result, the node was considered to be non-metastatic.

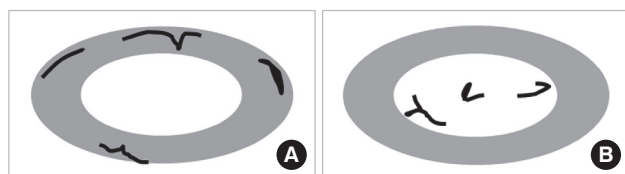
For comparisons of the diagnostic performance for each US criteria, McNemar's test was used. A finding was found to be statistically significant if the *p*-value was less than 0.05. All statistical analyses were performed using SAS version 9.12 (SAS Institute, Cary, USA).

### RESULTS

The histopathologic types of the 24 breast cancers were invasive ductal carcinomas in 20 patients, ductal carcinoma *in*

*situ* in one, metaplastic carcinoma in one, mucinous carcinoma in one, and melanoma in one. In the 80 lymph nodes, eight (10.0%) lymph nodes were palpable and the remaining 72 (90.0%) nodes were not detected by physical examination. Eighty nodes were pathologically verified as metastasis in 34 (42.5%) and reactive hyperplasia in 46 (57.5%). Sixty-seven (83.7%) nodes were located in axillary level I, eleven (13.7%) in level II, and two (2.5%) in level III.

Table 1 demonstrates the diagnostic performances of the CH area ratio, LT axis ratio, and blood flow pattern on power Doppler imaging for evaluation of axillary lymph nodes. The sensitivity of the CH area ratio was superior to that of the LT axis ratio (94.1% vs. 82.3%, *p* = 0.031) and to that of the blood flow pattern on the power Doppler imaging (94.1% vs. 29.4%, *p* = 0.009) (Figures 3, 4). For specificity, all three evaluating parameters had high values (95.6% for the CH area ratio, 89.1% for the LT axis ratio, 89.1% for the blood flow pattern) and no significant differences were found (95.6% vs. 89.1%, *p* = 0.121). The CH area ratio had a better PPV than the LT

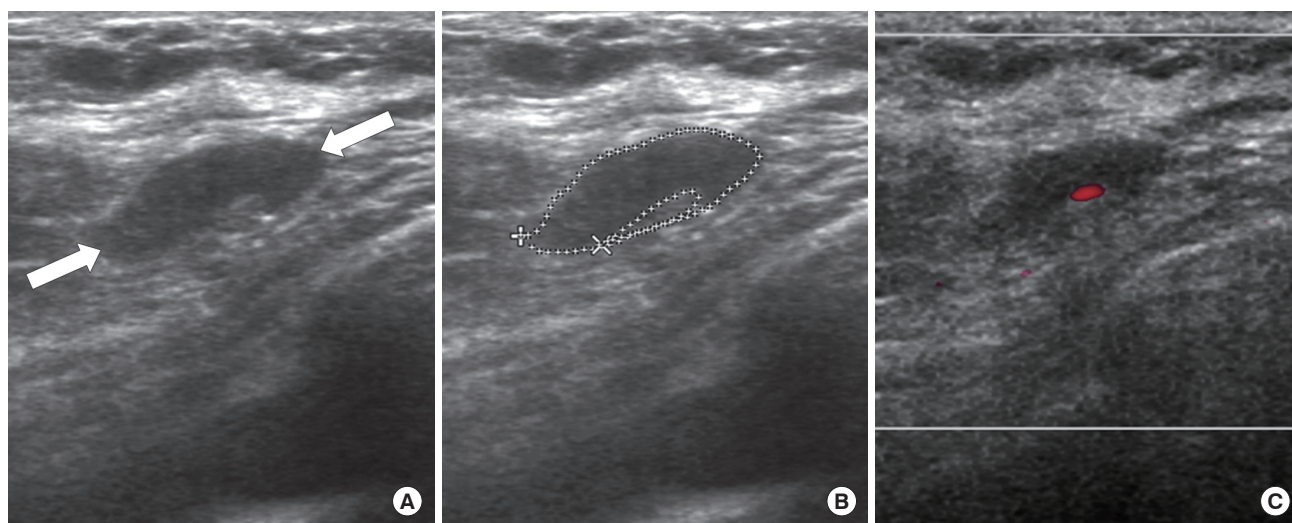


**Figure 2.** Drawings illustrate how to classify the blood flow pattern of a lymph node on power Doppler imaging. We evaluated vascular predominance in peripheral or central portions of a lymph node and then divided into peripheral (A) or central (B) types. If a node had no vascularity, we classified it as having no blood flow.

**Table 1.** Diagnostic performances of CH area ratio, LT axis ratio, and blood flow pattern on power Doppler imaging for evaluation of axillary lymph nodes

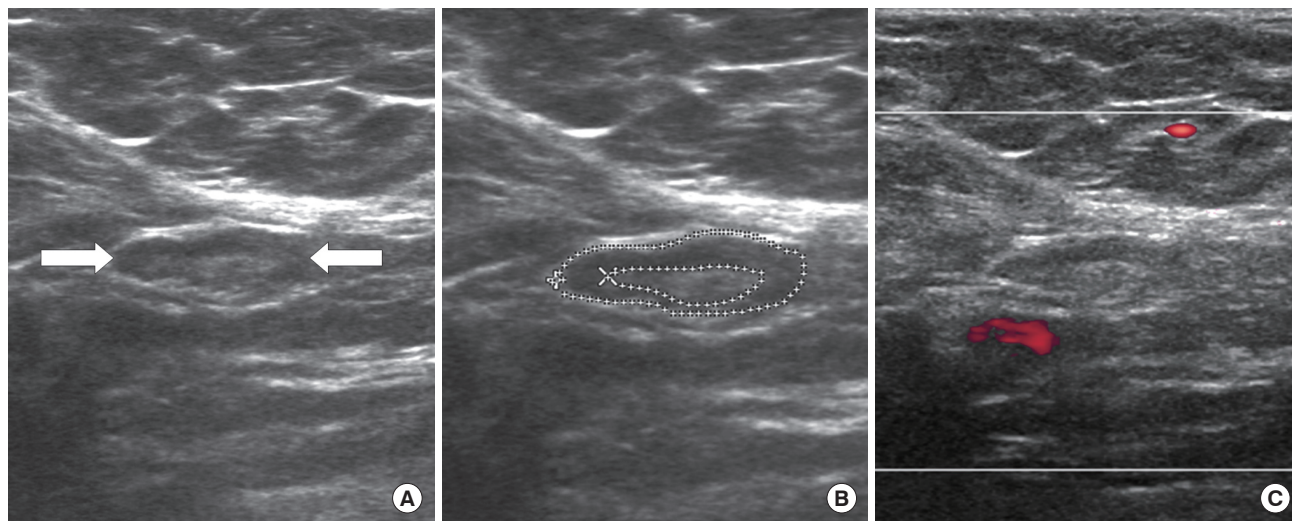
	CH area ratio (%)	LT axis ratio (%)	Blood flow pattern (%)
Sensitivity	94.1 (32/34)	82.3 (28/34)	29.4 (10/34)
Specificity	95.6 (44/46)	89.1 (41/46)	89.1 (41/46)
PPV	94.1 (32/34)	80.0 (28/35)	66.6 (10/15)
NPV	95.6 (44/46)	86.6 (39/45)	63.0 (41/65)

CH = cortex-hilum; LT = longitudinal-transverse; PPV = positive predictive value; NPV = negative predictive value.



**Figure 3.** A 32-year-old woman with invasive ductal carcinoma with positive lymph node metastasis. (A) A lymph node (arrows) is seen on ultrasound (US). (B) The cortex-hilum area ratio was 11.6 and the longitudinal-transverse axis ratio was 3.09. (C) Power Doppler US shows a central type of blood flow.





**Figure 4.** A 39-year-old woman with invasive ductal carcinoma with positive lymph node metastasis. (A) A lymph node (arrows) is seen on ultrasound (US). (B) The cortex-hilum area ratio was 3.60 and the longitudinal-transverse axis ratio was 2.68. (C) On power Doppler US, there was no blood flow.

axis ratio (94.1% vs. 80.0%,  $p=0.030$ ) and the power Doppler imaging (94.1% vs. 66.6%,  $p=0.028$ ) (Figures 3, 4). For the NPV, the CH area ratio was superior to the LT axis ratio (95.6% vs. 86.6%,  $p=0.035$ ) and the blood flow pattern (95.6% vs. 63.0%,  $p=0.027$ ) on power Doppler imaging. Therefore, the CH area ratio had high values in all test performance characteristics (sensitivity, specificity, PPV, and NPV).

## DISCUSSION

Assessment of axillary lymph node status is essential for determining tumor staging and treatment as well as establishing prognoses for breast cancer patients. The exclusion of lymph node metastases by non-invasive methods could reduce the rate of unnecessary axillary surgery. However, a physical examination of the axilla is not an accurate method for predicting lymph node status [15,16]. Thus, various imaging techniques have been used for evaluation of axillary lymph nodes. US is a convenient imaging modality to evaluate axillae. Node size and morphology were used as criteria for positivity on US [17]. For node size, sensitivity varied between 48.8% and 87.1% and specificity, between 55.6% and 97.3%. For lymph node morphology, sensitivity ranged from 26.4% to 75.9% and specificity, from 88.4% to 98.1%. As a result, US is moderately sensitive and fairly specific for the diagnosis of axillary metastatic involvement. However, US has various ranges of diagnostic performance and the experience of the examiner and period of availability are crucial for the diagnostic precision and prediction.

To make a determination of the axillary lymph node status by US, we focused on cortical changes. Metastatic cells travel-

ing through afferent lymphatic channels are first embedded in the marginal sinus at the cortex of a lymph node, which drains to the hilum [13,18]. Thickening of the cortex is an indicator of an early change in metastasis. After cortical enlargement, the absence of a fatty hilum develops as a later change and is considered to be the most specific finding for the detection of metastases.

For the assessment of cortical thickening of a lymph node by US, quantitative or qualitative methods have been used. The quantitative indicators include the maximum thickness of the cortex or LT axis ratio or the number of peripheral blood vessels. The qualitative methods used for the diagnosis of lymph node metastases on US include a round morphology, hypoechogenicity, loss of central hilum, or eccentric cortical hypertrophy. Abnormal lymph nodes tend to become more rounded due to the neoplastic involvement enlarging the short plane of the LN. Therefore, a low LT axis ratio, which indicates that the shape of the node is round, is usually detected in malignant nodes [11,18,19]. We used a cutoff value of 2 because an LT ratio  $>2.0$  indicates [11] that the lymph node is more likely to be non-metastatic.

In previous studies about cortical thickness on US, various cortical-size criteria were used for suspected lymph nodes. A recent study by Cho et al. [20] suggested a cortical thickness of 2.5 mm to be the threshold for designating a lymph node as being suspicious.

For evaluation of blood flow in a lymph node, Doppler US with or without contrast media has been used. Malignant lymph nodes had a greater total and number of peripheral vessels compared with benign axillary lymph nodes [12]. However, the heterogeneity of qualitative or quantitative

methods shows that the results also continue to be variable in each group in meta-analyses [17].

To improve the diagnostic performance of the axillary lymph node, we measured the areas of the cortex and hilum of the lymph node. We believed that the area might be more accurate than the length in assessing the thickened cortex of the lymph nodes. We traced the cortical and hilar margins on the US monitor to obtain the areas of each cortex and hilum and then compared the areas of the two sites. We firstly mentioned about "CH area ratio of lymph nodes" in the current study, therefore, there is no comparable previous data about CH area ratio. We obtained diagnostic performances at various CH area ratio,  $> 2$ ,  $> 2.5$ , or  $> 3$ . Using our criteria (CH area ratio  $> 2$ ), we achieved substantially higher sensitivity (94.1%), specificity (95.6%), PPV (94.1%), and NPV (95.6%). On the other hand, CH area ratio  $> 2.5$  or CH area ratio  $> 3$  had lower sensitivity (85% or 79%) and NPV (84% or 76%) than CH area ratio  $> 2$ , although CH area ratio  $> 2.5$  or CH area ratio  $> 3$  had higher specificity (97% or 100%) and PPV (96% or 100%). Therefore, we used CH area ratio  $> 2$  for classification of metastatic versus non-metastatic lymph nodes in the current study.

The current study demonstrates that the CH area ratio has the best results in diagnosis performance. Additionally, in sensitivity and PPV, the results of the CH area ratio were significantly superior to the LT axis ratio and power Doppler findings. The CH area ratio may improve diagnostic performance for lymph nodes with even smooth cortical thickening, oval morphology, and unincreased peripheral blood flow. A lymph node with even smooth cortical thickening can be missed for malignant detection if we use the maximum thickness of the cortex. The oval morphology may have a false negative result in the LT axis ratio because of a long longitudinal diameter. Increased peripheral blood flow of lymph nodes cannot be detected with Doppler imaging without contrast media because of slow velocity or an inadequate number of vessels.

In our results, the LT axis ratio and power Doppler imaging features show limited PPVs. And power Doppler imaging also has very low sensitivity. Low PPV can produce unnecessary lymph node biopsies or unnecessary surgical dissections and increased medical costs and increased patient anxiety. Low sensitivity has missed diagnoses and created false negative results for diagnosis of node metastases. Therefore, we recommend the CH area ratio to evaluate axillary lymph nodes for diagnosis of metastases because of high diagnostic performance and a convenient, objective method. The CH area ratio can be used as a quantitative indicator for the diagnosis of a metastatic lymph node in addition to the subjective morpho-

logic features.

This study has several limitations. First, because of the prospective design of our study, we evaluated 165 consecutive patients who had BI-RADS<sup>®</sup> category 4B, 4C, or 5 lesions and then included only 24 patients who had pathologic verification of breast cancer and axillary nodal status. Thus, the number of lymph nodes was small, 80. Though the CH area ratio showed satisfactory diagnostic performance to determine between metastatic and non-metastatic nodes, we cannot assure that the CH area ratio will replace tissue sampling in the near future. Furthermore, the CH area ratio was firstly described in the current study and there is no comparable previous study. We recommend a further study in a large population with breast cancers to apply our results in clinical practice. Second, we compared the vascular predominance between the cortex and hilum of a lymph node; however, we did not count the number of vessels. This is a subjective method. Third, we did not analyze the lymph nodes according to the location or size of the nodes. The results may be influenced by these factors. Forth, 20 lymph nodes were pathologically diagnosed by US-guided fine needle aspiration in the current study. Fine-needle aspiration of axillary nodes is highly sensitive and specific for lymph node involvement by primary breast carcinoma when compared with clinical and radiologic examination alone [21,22]. Thus, axillary fine needle aspiration can play a role in sparing sentinel lymph node biopsy in triaging advanced cases for systemic and neoadjuvant therapy. However, diagnostic performance of axillary fine needle aspiration still has limitations in low suspicious lymph nodes when compared with core needle biopsy or excisional biopsy [21]. If a lymph node was positive on fine needle aspiration, we performed lymph node dissection and obtained final pathologic diagnoses. However, node-to-node correlation with pathologic findings and US results could not be performed after node dissection.

In conclusion, we recommend that the CH area ratio of an axillary lymph node on US be used as a quantitative indicator for the diagnosis of lymph node metastasis. The CH area ratio can improve diagnostic performance when compared with the LT axis ratio or peripheral vascularity on power Doppler imaging.

## CONFLICT OF INTEREST

The authors declare that they have no competing interests.

## REFERENCES

1. Banerjee M, George J, Song EY, Roy A, Hryniuk W. Tree-based model for breast cancer prognostication. *J Clin Oncol* 2004;22:2567-75.

2. Carter CL, Allen C, Henson DE. Relation of tumor size, lymph node status, and survival in 24,740 breast cancer cases. *Cancer* 1989;63:181-7.
3. Reynolds C, Mick R, Donohue JH, Grant CS, Farley DR, Callans LS, et al. Sentinel lymph node biopsy with metastasis: can axillary dissection be avoided in some patients with breast cancer? *J Clin Oncol* 1999;17:1720-6.
4. McMasters KM, Giuliano AE, Ross MI, Reintgen DS, Hunt KK, Byrd DR, et al. Sentinel-lymph-node biopsy for breast cancer: not yet the standard of care. *N Engl J Med* 1998;339:990-5.
5. de Kanter AY, van Eijck CH, van Geel AN, Kruijt RH, Henzen SC, Paul MA, et al. Multicentre study of ultrasonographically guided axillary node biopsy in patients with breast cancer. *Br J Surg* 1999;86:1459-62.
6. Fraile M, Rull M, Julián FJ, Fusté F, Barnadas A, Llatjós M, et al. Sentinel node biopsy as a practical alternative to axillary lymph node dissection in breast cancer patients: an approach to its validity. *Ann Oncol* 2000;11:701-5.
7. Kumar R, Jana S, Heiba SI, Dakhel M, Axelrod D, Siegel B, et al. Retrospective analysis of sentinel node localization in multifocal, multicentric, palpable, or nonpalpable breast cancer. *J Nucl Med* 2003;44:7-10.
8. Michel SC, Keller TM, Fröhlich JM, Fink D, Caduff R, Seifert B, et al. Preoperative breast cancer staging: MR imaging of the axilla with ultrasmall superparamagnetic iron oxide enhancement. *Radiology* 2002;225:527-36.
9. Tate JJ, Lewis V, Archer T, Guyer PG, Royle GT, Taylor I. Ultrasound detection of axillary lymph node metastases in breast cancer. *Eur J Surg Oncol* 1989;15:139-41.
10. Damera A, Evans AJ, Cornford EJ, Wilson AR, Burrell HC, James JJ, et al. Diagnosis of axillary nodal metastases by ultrasound-guided core biopsy in primary operable breast cancer. *Br J Cancer* 2003;89:1310-3.
11. Lernevall A. Imaging of axillary lymph nodes. *Acta Oncol* 2000;39:277-81.
12. Yang WT, Metreweli C, Lam PK, Chang J. Benign and malignant breast masses and axillary nodes: evaluation with echo-enhanced color power Doppler US. *Radiology* 2001;220:795-802.
13. Abe H, Schmidt RA, Sennett CA, Shimauchi A, Newstead GM. US-guided core needle biopsy of axillary lymph nodes in patients with breast cancer: why and how to do it. *Radiographics* 2007;27 Suppl 1:S91-9.
14. American College of Radiology, BI-RADS Committee. *ACR BI-RADS Breast Imaging and Reporting Data System: Breast Imaging Atlas*. 4th ed. Reston: American College of Radiology; 2003.
15. Sacre RA. Clinical evaluation of axillar lymph nodes compared to surgical and pathological findings. *Eur J Surg Oncol* 1986;12:169-73.
16. Specht MC, Fey JV, Borgen PI, Cody HS 3rd. Is the clinically positive axilla in breast cancer really a contraindication to sentinel lymph node biopsy? *J Am Coll Surg* 2005;200:10-4.
17. Alvarez S, Añorbe E, Alcorta P, López F, Alonso I, Cortés J. Role of sonography in the diagnosis of axillary lymph node metastases in breast cancer: a systematic review. *AJR Am J Roentgenol* 2006;186:1342-8.
18. Feu J, Tresserra F, Fábregas R, Navarro B, Grases PJ, Suris JC, et al. Metastatic breast carcinoma in axillary lymph nodes: in vitro US detection. *Radiology* 1997;205:831-5.
19. Esen G, Gurses B, Yilmaz MH, Ilvan S, Ulus S, Celik V, et al. Gray scale and power Doppler US in the preoperative evaluation of axillary metastases in breast cancer patients with no palpable lymph nodes. *Eur Radiol* 2005;15:1215-23.
20. Cho N, Moon WK, Han W, Park IA, Cho J, Noh DY. Preoperative sonographic classification of axillary lymph nodes in patients with breast cancer: node-to-node correlation with surgical histology and sentinel node biopsy results. *AJR Am J Roentgenol* 2009;193:1731-7.
21. Chang MC, Crystal P, Colgan TJ. The evolving role of axillary lymph node fine-needle aspiration in the management of carcinoma of the breast. *Cancer Cytopathol* 2011;119:328-34.
22. Rao R, Lilley L, Andrews V, Radford L, Ulissey M. Axillary staging by percutaneous biopsy: sensitivity of fine-needle aspiration versus core needle biopsy. *Ann Surg Oncol* 2009;16:1170-5.