

# Arthroscopic Transosseous Suture Button Fixation Technique for Treatment of Large Anterior Glenoid Fracture



Arasch Wafaisade, M.D., Thomas R. Pfeiffer, M.D., Maurice Balke, M.D., Daniel Guenther, M.D., and Paola Koenen, M.D.

**Abstract:** To date, several open and arthroscopic surgical procedures are available for the treatment of anterior glenoid fractures after anterior shoulder dislocation. Open approaches require extensive soft-tissue dissection and are associated with poorer outcomes. Arthroscopic screw fixation techniques are technically challenging and related to complications as well, for example, risk of brachial plexus injury or hardware impingement. Alternative arthroscopic fixation techniques use suture anchors placed along the fracture rim with sutures passed around the fragment. However, these techniques require an intact capsulolabral complex and cannot be used effectively for large fracture fragments. This article describes a safe interfragmentary, transosseous, all-arthroscopic procedure using a double—cortical button fixation technique. This method can be used to achieve anatomic reduction and stable fixation of intermediate to large anterior glenoid fractures while minimizing the difficulties associated with previously described arthroscopic or open approaches.

Traumatic anterior shoulder dislocation may lead to anterior glenoid fracture, which subsequently can result in persistent instability and degenerative joint disease.<sup>1</sup> In general, operative intervention is recommended for displaced fractures, especially if the articular step is greater than 5 mm.<sup>2</sup> However, surgical treatment of intra-articular glenoid fractures remains technically challenging. Traditionally, these procedures have been performed through an extensive open approach with internal screw fixation, which is

associated with numerous potential intraoperative and postoperative complications.<sup>3,4</sup> As a result, several arthroscopic techniques have been developed to minimize the morbidity of open surgery. Of these methods, arthroscopic screw fixation still represents a technical challenge because it usually requires an approach through the subscapularis muscle and places the brachial plexus at risk.<sup>5</sup> Thus, subsequently, several authors have described alternative arthroscopic fixation techniques applying suture anchors placed along the fracture rim with sutures passed around the fracture fragment and the adjacent capsulolabral complex.<sup>6-9</sup> However, these fixation methods cannot be used effectively for large fragments or if the capsulolabral complex is interrupted. Furthermore, placement of multiple suture anchors in a linear arrangement has been associated with recurrent glenoid rim fractures along the anchor insertion sites.<sup>10</sup>

Therefore, the aim of this article was to describe a safe interfragmentary, transosseous technique for arthroscopic fixation of large anterior glenoid fractures (Ideberg type 1A) using a double—cortical button technique (Video 1). This procedure uses a system (Round EndoButton System; Smith & Nephew) that originally was designed for placement of tricortical iliac crest bone on the eroded anterior glenoid in cases of chronic instability.<sup>11,12</sup> This technique can be used to achieve anatomic reduction and stable fixation of

From the Department of Trauma and Orthopedic Surgery, University of Witten/Herdecke, Cologne-Merheim Medical Center (A.W., T.R.P., D.G., P.K.), and Sportsclinic Cologne (M.B.), Cologne, Germany.

The authors report the following potential conflicts of interest or sources of funding: A.W. is a consultant for Stryker; receives travel costs from Arthrex and DePuy-Synthes; and is a consultant for and receives travel costs from Smith & Nephew. M.B. is a consultant for Smith & Nephew and ConMed. Full ICMJE author disclosure forms are available for this article online, as supplementary material.

Received April 15, 2019; accepted July 6, 2019.

Address correspondence to Arasch Wafaisade, M.D., Department of Trauma and Orthopedic Surgery, University of Witten/Herdecke, Cologne-Merheim Medical Center, Ostmerheimer Strasse 200, Cologne D-51109, Germany. E-mail: wafaisadea@kliniken-koeln.de

© 2019 by the Arthroscopy Association of North America. Published by Elsevier. This is an open access article under the CC BY-NC-ND license (<http://creativecommons.org/licenses/by-nc-nd/4.0/>).

2212-6287/19500

<https://doi.org/10.1016/j.eats.2019.07.007>

intermediate to large anterior glenoid fractures while minimizing the risks associated with the previously described arthroscopic or open approaches.

## Surgical Technique

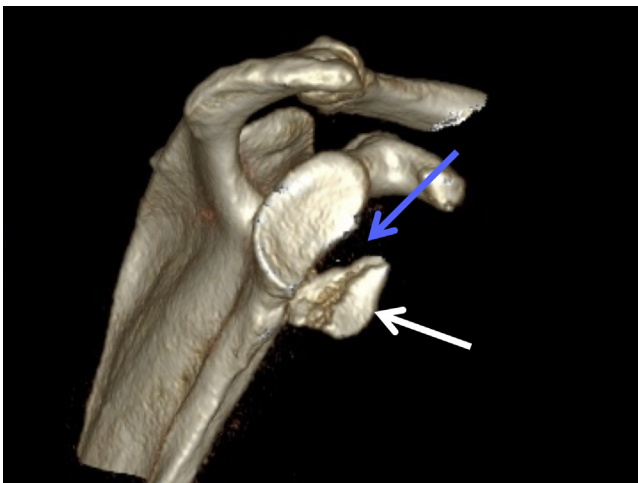### Preoperative Planning

Preoperatively, computed tomography including 3-dimensional reconstruction and subtraction of the humerus is obtained (Fig 1), which facilitates planning of repositioning and implant placement.

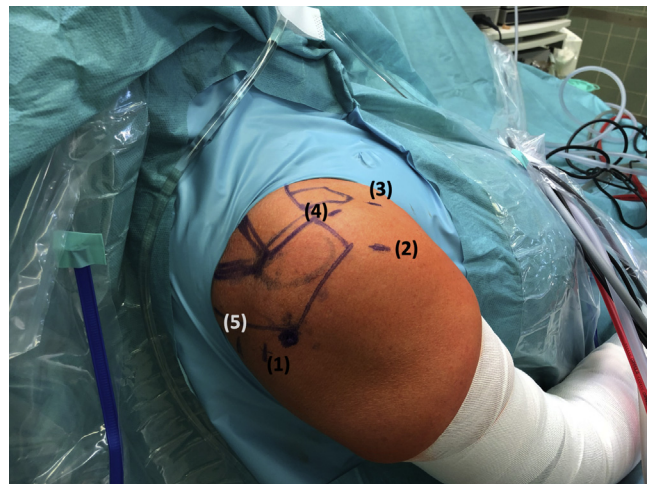
### Patient Positioning and Portal Placement

Under general anesthesia, the patient is placed in the beach-chair position. The shoulder is prepared and draped in the usual sterile fashion. The arm remains draped free to allow for intraoperative manipulation of the upper extremity.

Five portals are required for this technique (Fig 2): A standard posterior portal is used for the initial diagnostic arthroscopy and in the further course of the surgical procedure for introduction of the glenoid guide (Fig 3). An anterolateral portal perpendicular to the glenoid is used during the main course of the operation as the viewing portal. Two anterior portals are used in the rotator interval: a low anterior portal just at the upper border of the subscapularis tendon and a high anterior portal at the anterior border of the supraspinatus tendon. Clear threaded cannulas are introduced over these portals. Finally, a posteromedial incision is made about 1 cm medial to the posterior



**Fig 1.** Preoperative computed tomography of the right shoulder with 3-dimensional reconstruction and subtraction of the humerus shows the en face view of the glenoid with the displaced anterior glenoid fracture (Ideberg type 1A). The large fragment (white arrow) measures approximately 30% of the glenoid surface, and the gap of the joint surface measures 10 mm (blue arrow), clearly indicating the need for surgical treatment.



**Fig 2.** View of the right shoulder with the patient in the beach-chair position. Five portals are required: a standard posterior portal (1) for the initial diagnostic arthroscopy and in the further course of the surgical procedure for introduction of the glenoid guide; an anterolateral portal (2) perpendicular to the glenoid used as the main viewing portal; 2 anterior portals in the rotator interval, comprising a low anterior portal (3) and high anterior portal (4); and a posteromedial incision (5) about 1 cm medial to the posterior portal for introduction of the bullets of the glenoid guide.

portal for introduction of the bullets of the glenoid guide (Fig 4).

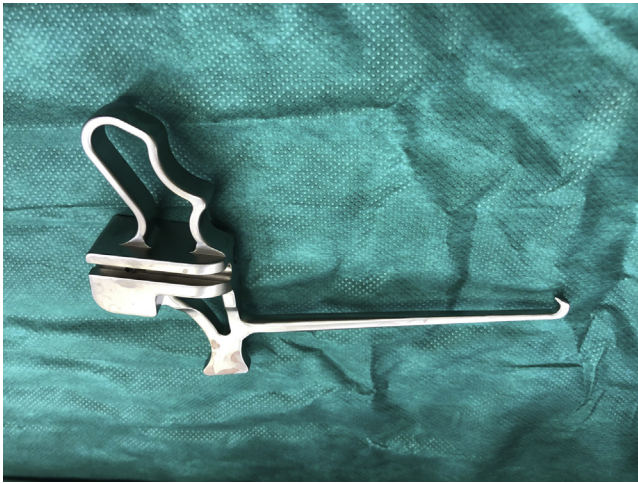### Diagnostic Arthroscopy

Viewing from the posterior portal, the surgeon performs a diagnostic arthroscopy. Both anterior portals and the anterolateral portal are established. Usually, fracture hematoma is encountered and removed. The arthroscope is inserted through the anterolateral portal, remaining there for the rest of the procedure. In the presented case, the anterior labrum is ruptured just at the upper border of the large anterior glenoid fragment at the 2-o'clock position (Fig 5).

### Fracture Reduction

Several instruments (e.g., elevator, probe, and Bankart knife) are used via both anterior portals for fracture reduction (Fig 6). A polydioxanone suture is shuttled through the anterior labrum to facilitate cranialization of the fragment.

Then, the anterior hook end of the glenoid guide (Fig 3) is inserted through the posterior portal and advanced anteriorly, parallel to the glenoid, with the hook turned cranially to avoid damage to the glenohumeral cartilage (Fig 7). Prior to this step, a half-pipe cannula can be introduced through the posterior portal to facilitate hook insertion. Once sufficiently advanced, the guide is rotated to capture the anterior edge of the anterior fragment under the hook. Depending on fracture morphology, the hook is usually

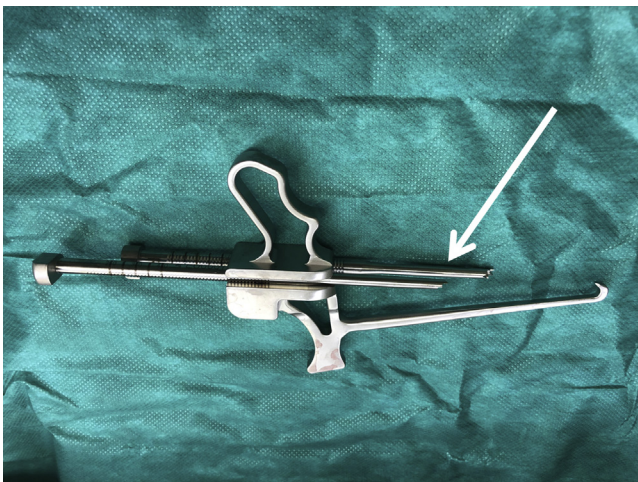


**Fig 3.** Glenoid guide used to create 2 holes from posterior to anterior at the level of the glenoid rim (specific instrument created by Smith & Nephew [T-Handle Dual Glenoid Guide, model 72203340]). The anterior hook end of the guide is inserted through the posterior portal.

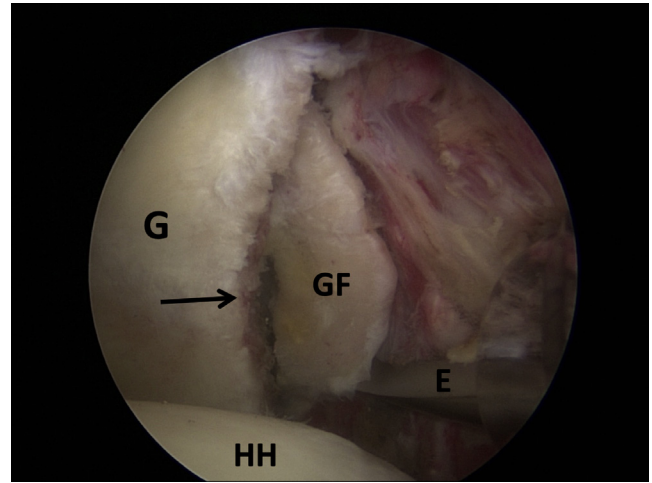
placed between the 3- and 4-o'clock position, with the glenoid guide parallel to and flush with the glenoid surface (Fig 8). Together with the instruments introduced from the 2 anterior portals, the anterior hook of the glenoid guide can then be applied as a reduction tool to pull the anterior glenoid fragment firmly in a posterior direction (Table 1).

### Fracture Fixation

Anatomic reduction is maintained with the hook while 2 bullets are placed over the glenoid guide (Fig 4) through the posteromedial skin incision. Each bullet

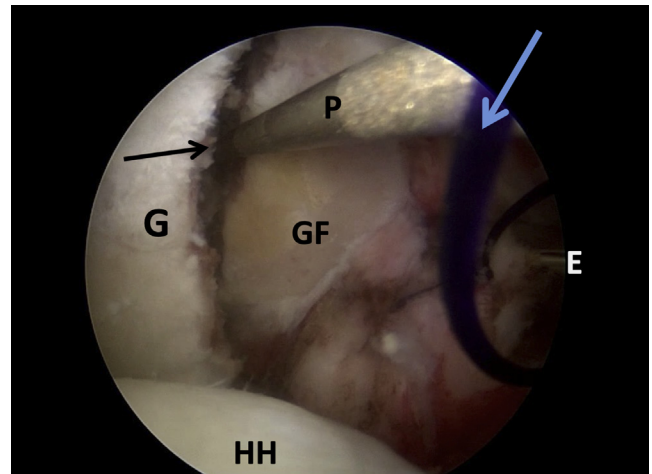


**Fig 4.** Glenoid guide (as in Fig 3) with 2 special bullets (arrow) that are inserted from the posteromedial incision and advanced until they firmly contact the posterior aspect of the glenoid neck (specific instruments created by Smith & Nephew: 1 T-Handle Dual Glenoid Guide; 1 Bullet, Glenoid Guide, Long [model 72203341]; and 1 Bullet, Glenoid Guide, Short [model 72203342]).

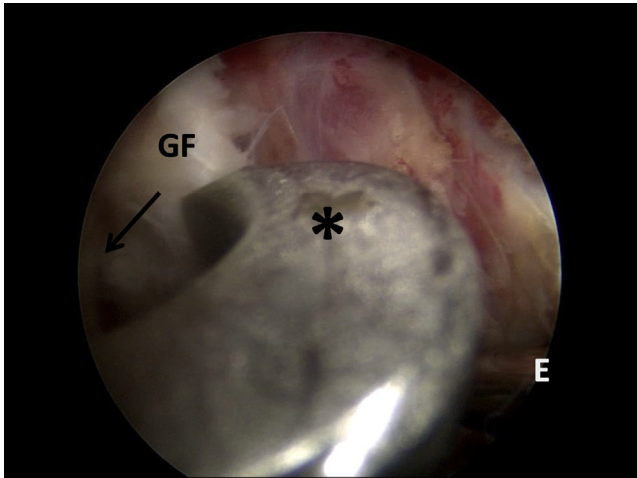


**Fig 5.** The patient is in the beach-chair position, and arthroscopy is performed on the right shoulder. The arthroscope is introduced through the anterolateral portal, allowing an excellent view of the glenoid (G) with the humeral head (HH) at the lower border. After the fracture hematoma has been removed, the fracture line is identified (arrow) and the displaced glenoid fracture fragment (GF) is mobilized using a soft-tissue elevator (E) inserted through the low anterior portal.

can be advanced until it firmly contacts the posterior aspect of the glenoid neck. A 2.8-mm drill bit comprising an inner K-wire and an outer sleeve is placed through each bullet. While fracture reduction is being maintained, both drills are advanced under



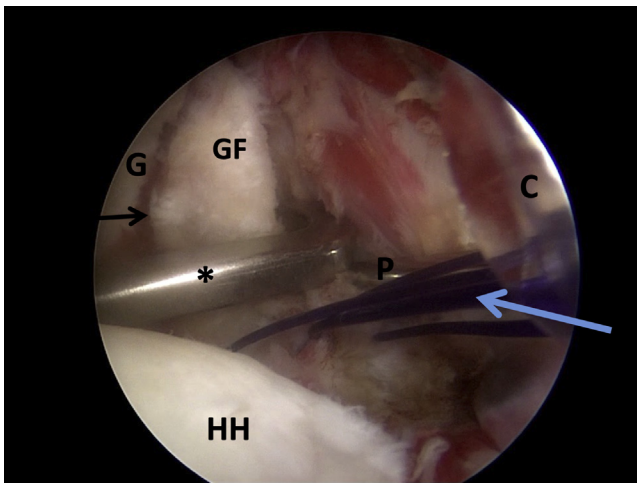
**Fig 6.** Arthroscopic view of the right shoulder with the patient in the beach-chair position. The arthroscope is in the anterolateral portal with an en face view of the glenoid (G) and the humeral head (HH) at the lower border. The fracture line (black arrow) and glenoid fracture fragment (GF) are shown. Several instruments, for example, a probe (P) and elevator (E), are used via both anterior portals for fracture reduction. A polydioxanone suture (blue arrow) is shuttled through the anterior labrum to facilitate cranialization.



**Fig 7.** Arthroscopic view of the right shoulder with the patient in the beach-chair position. The arthroscope is in the anterolateral portal. The anterior hook end of the glenoid guide (asterisk) is inserted through the posterior portal and advanced anteriorly, parallel to the glenoid. The arrow indicates the fracture line. (E, elevator; GF, glenoid fracture fragment.)

power until exiting from the anterior aspect of the anterior fragment (Fig 9).

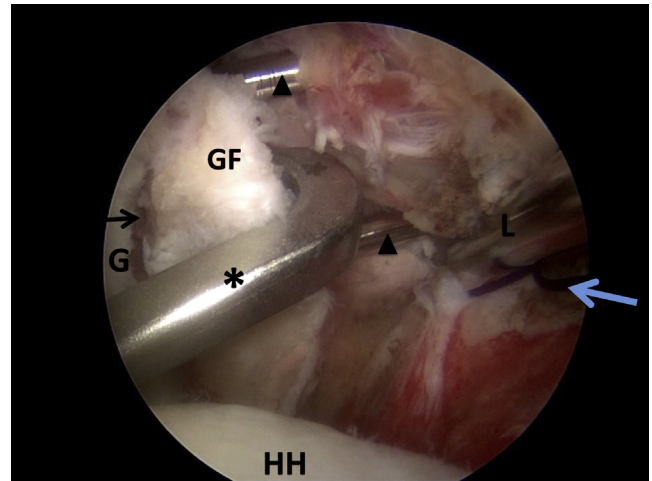
Each drill will be 5 mm below the cortical edge of the glenoid surface, parallel to one another and 10 mm apart. At this stage, the bullets and glenoid guide can be



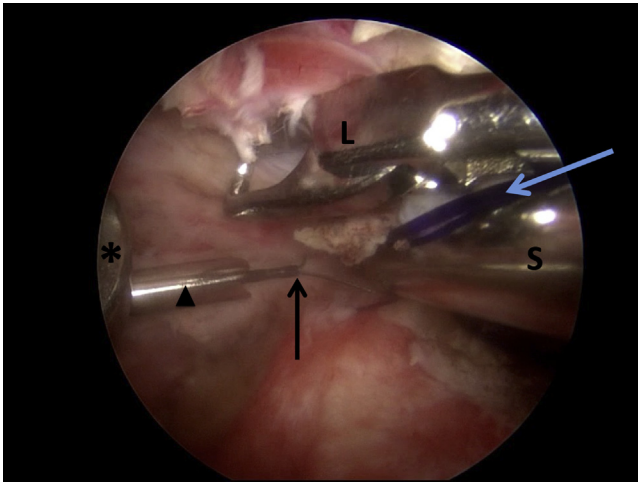
**Fig 8.** Arthroscopic view of the right shoulder with the patient in the beach-chair position. The arthroscope is in the anterolateral portal with an en face view of the glenoid (G) and humeral head (HH) at the lower border. The anterior hook end of the glenoid guide (asterisk) is placed at the 4-o'clock position, with the glenoid guide parallel to and flush with the glenoid surface. Together with a probe (P), the hook is used to reduce the fracture (black arrow) by pulling the anterior glenoid fragment (GF) firmly in a posterior direction. The blue arrow indicates the polydioxanone suture placed in the anterior labrum. (C, cannula.)

**Table 1.** Pearls and Pitfalls of Suture Button Fixation Technique

Technique	
<b>Pearls</b>	
Two anterior portals (high and low) facilitate fragment repositioning.	
A half-pipe cannula can be inserted through the posterior portal to facilitate insertion of the hook of the glenoid guide.	
The hook is useful for fragment repositioning by pulling firmly in a posterior direction before advancing the 2.8-mm drill bits.	
A looped grasper should be available to retrieve the looped-end guidewire.	
<b>Pitfalls</b>	
Mobilization of a medially displaced fragment should not rely only on the shaver; the use of elevators, probes, Bankart knives, and so on is recommended.	
After mobilization of the fragment, repositioning can remain difficult but can be facilitated by applying a sharp pointed instrument (e.g., curved suture grasper).	
Because the native capsulolabral complex should be preserved, retrieval of the looped-end guidewire out of the sleeve can be difficult because it is advanced into the medial glenohumeral ligament. A switching stick (coming from the high anterior portal) can be used to push anteriorly and open the space between the anterior labrum and subscapularis tendon. With a looped grasper, inserted through the low anterior portal, the looped wire can be retrieved.	



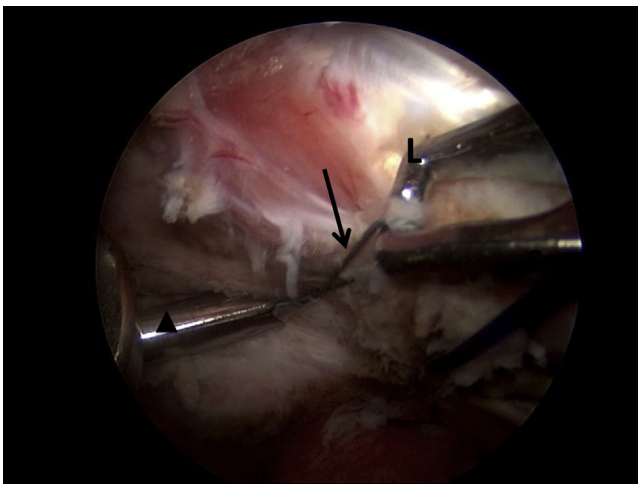
**Fig 9.** Arthroscopic view of the right shoulder with the patient in the beach-chair position. The arthroscope is in the anterolateral portal with an en face view of the glenoid (G), glenoid fracture fragment (GF), and humeral head (HH). The hook of the glenoid guide (asterisk) has been placed to reduce the fracture (black arrow). At this surgical step, 2 holes are created from posterior to anterior using 2 2.8-mm drills (arrowheads), each comprising an outer sleeve and an inner K-wire (2 guidewires with 2.8-mm sleeve [model 72202973]; Smith & Nephew). These are drilled through the 2 parallel bullets of the glenoid guide (Fig 4), through the glenoid, and through the repositioned fragment, parallel to and 5 mm below the joint surface. A looped grasper (L), placed through the high anterior portal, pushes the capsule and subscapularis tendon anteriorly to visualize both drills. The blue arrow indicates a polydioxanone suture placed in the anterior labrum.



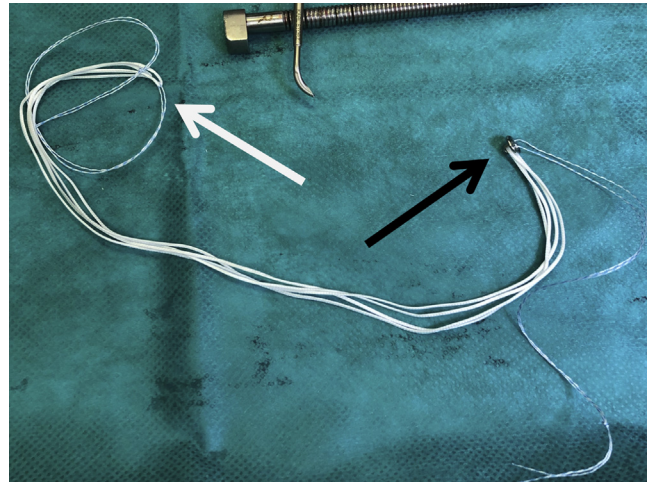
**Fig 10.** Arthroscopic view of the right shoulder with the patient in the beach-chair position. The arthroscope is in the anterolateral portal. As in the presented case, the upper sleeved drill usually exits at the upper border of the fragment; thus, only the lower sleeve (arrowhead) is used. The inner K-wire of the lower drill has been removed posteriorly. A flexible looped guidewire (black arrow) is passed through the lower sleeve from posterior to anterior. A looped grasper (L) and a switching stick (S), placed through the 2 anterior portals, push the capsule and subscapularis tendon anteriorly to visualize the looped guidewire. The blue arrow indicates a polydioxanone suture placed in the anterior labrum. The asterisk indicates the hook of the glenoid guide.

removed posteriorly, ensuring that the sleeves remain positioned in the glenoid neck.

As in the presented case, the upper sleeved drill usually exits just above the fragment; thus, only the

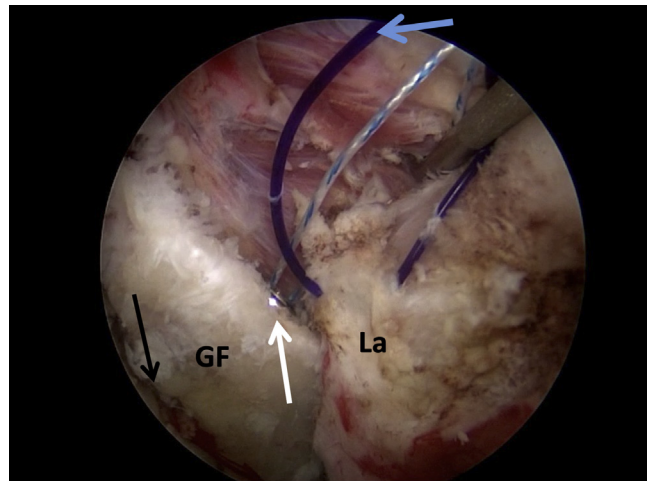


**Fig 11.** Arthroscopic view of the right shoulder with the patient in the beach-chair position. The arthroscope is in the anterolateral portal with a view of the anterior capsule. The flexible looped guidewire (arrow) has been passed through the lower sleeve (arrowhead) from posterior to anterior. The looped guidewire is retrieved through the high anterior portal using a looped grasper (L).

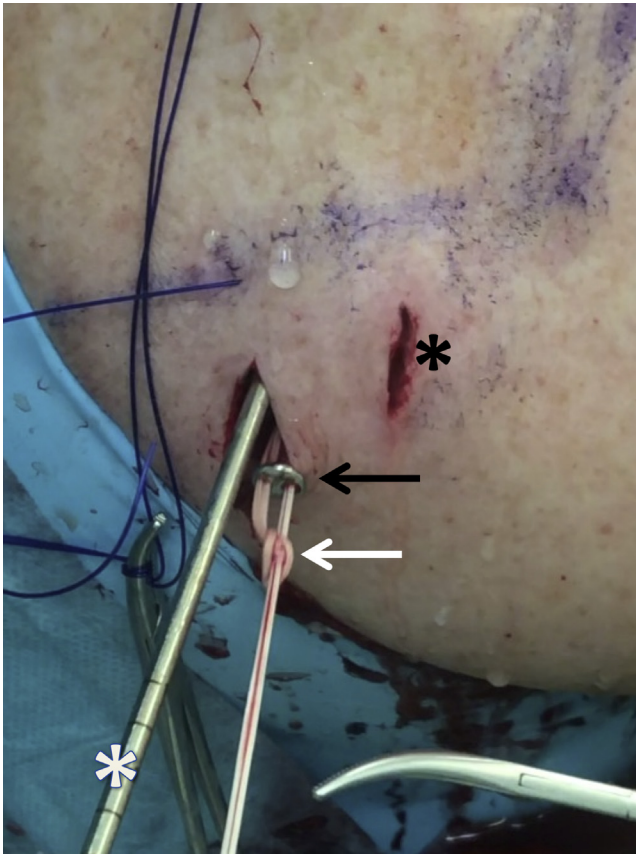


**Fig 12.** EndoButton suture fixation device (Round EndoButton S2 3/4 Suture Loop [model 71934993]; Smith & Nephew) comprising a pegged round anterior EndoButton (black arrow) and a 4-strand suture. The anterior EndoButton has a pegged eyelet to avoid cutting the bone with the suture. A posterior single button (not shown) is placed after the posterior end of the suture (white arrow) has been pulled out of the posteromedial incision. The blue-white sutures (on both ends) work as retrieval sutures; thus, they are removed at the end of the surgical procedure.

lower sleeve is used during the further course of the surgical procedure. Therefore, the inner K-wire of the lower drill is removed posteriorly, leaving its cannulated outer sleeve in place. Then, a flexible looped



**Fig 13.** Arthroscopic view of the right shoulder with the patient in the beach-chair position. The arthroscope is in the anterolateral portal with an en face view of the glenoid fracture fragment (GF) and the fracture line (black arrow). All 4 strands of the EndoButton suture fixation device have been shuttled through the glenoid. Thus, the anterior EndoButton (white arrow) is engaged on the anterior surface of the anterior glenoid fragment, lying flat on the bone. A polydioxanone suture (blue arrow) has been placed in the anterior labrum (La).



**Fig 14.** Posterior view of the right shoulder with the patient in the beach-chair position. Both loops of the suture have been passed through the 2 eyelets of a posterior round EndoButton (black arrow). The posterior EndoButton (2-hole round EndoButton, model 71934990) is advanced into the posteromedial incision using a sliding-locking knot, in this case a so-called Nice knot (white arrow). Although generally not necessary, in this case the outer sleeve of the upper drill (white asterisk) has been left in place to ensure rotational stability of the fragment until the knot is tied against the posterior surface of the scapular neck. The black asterisk indicates the posterior portal.

guidewire is passed through the sleeve from posterior to anterior (Fig 10). The looped guidewire is retrieved through the high anterior portal using a looped grasper (Fig 11). Both drill sleeves are now removed, finally leaving only the looped guidewire in the lower drill tunnel.

The posterior end of the EndoButton suture fixation device is tied to the anterior end of the looped guidewire (Fig 12). Then, the looped guidewire is withdrawn posteriorly. Thus, all 4 strands of the EndoButton suture fixation device are shuttled into the high anterior portal, through the glenoid, and out the posteromedial incision. Hence, the anterior EndoButton is engaged on the anterior surface of the anterior glenoid fragment, lying flat on the bone (Fig 13). As the sutures are retrieved from the posteromedial incision, the looped

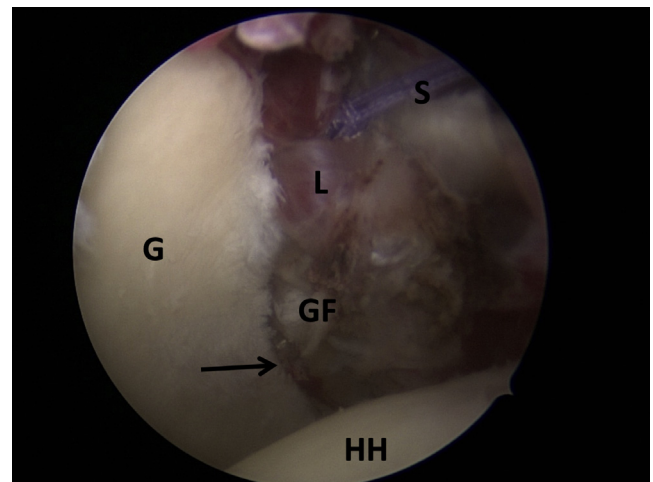
guidewire can be removed. With application of a suture retriever, both sides of the suture are passed through the 2 eyelets of a posterior round EndoButton. The posterior EndoButton is then advanced until it sits flush against the posterior face of the scapular neck using a sliding-locking knot, in this case a so-called Nice knot (Fig 14). Under arthroscopic control, a suture tensioner is placed on the sutures posteriorly, and tension of 75 to 100 N is applied on the posterior button. The suture tensioner can be removed, and a knot pusher is used to tie 3 square knots to lock the construct definitively.

### Capsulolabral Repair

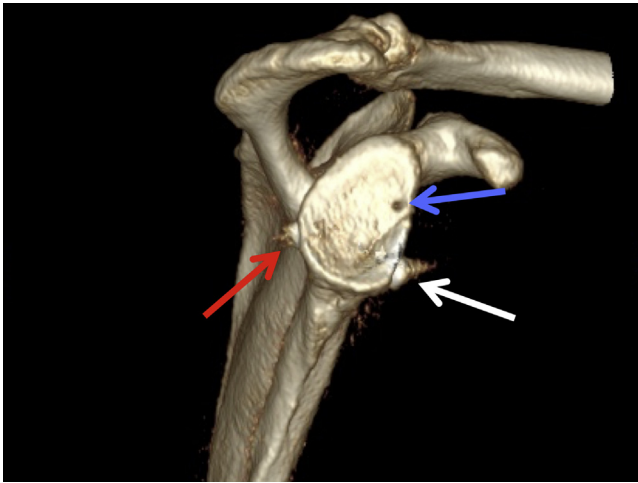
The interrupted capsulolabral ring is reconstructed as the anterior labrum and capsule are reattached to the glenoid rim at the 2-o'clock position, with application of a standard arthroscopic soft-tissue repair technique using a suture anchor, curved penetrating grasper, and knot pusher (Fig 15).

### Postoperative Protocol

Postoperative 3-dimensional computed tomography shows excellent fracture repositioning (Fig 16). A sling is used for the first 6 weeks, placing the arm in a neutral position. Passive motion is allowed up to 90° of abduction and anteversion. After 6 weeks, as osseous healing is visualized on follow-up radiographs, active physiotherapy is initiated without limitation of range of



**Fig 15.** Arthroscopic view of the right shoulder with the patient in the beach-chair position. The arthroscope is introduced through the anterolateral portal with an en face view of the glenoid (G) and humeral head (HH) at the lower border. The final result at the end of the surgical procedure is shown; the glenoid fracture fragment (GF) has been fixed, displaying excellent repositioning without a step along the fracture line (arrow). Refixation of the anterior labrum (L) has been performed using a suture anchor in the 2-o'clock position of the glenoid and a standard soft-tissue Bankart repair technique. The 2 strands of the suture anchor (S) are visible in the 1-o'clock position of the image before being cut with an arthroscopic suture cutter.



**Fig 16.** En face view of the glenoid in the right shoulder on computed tomography with 3-dimensional reconstruction and subtraction of the humerus 3 days postoperatively, after suture button fixation of the large, displaced anterior glenoid fracture (Ideberg type 1A). Fracture repositioning is optimal, showing no step of the joint surface, with the anterior EndoButton sitting flat on the anterior aspect of the fragment (white arrow) and the posterior EndoButton on the posterior glenoid neck (red arrow). In the 2-o'clock position, the drill hole of the suture anchor, which was used for re-fixation of the labrum, is visible (blue arrow).

motion. Return to heavy labor activities or to contact sports is usually allowed 4 months postoperatively.

## Discussion

Scapular fractures with extension into the glenoid are rare but can result in chronic instability and osteoarthritis. In general, surgery is indicated for displaced intra-articular fractures, in particular with an articular step greater than 5 mm.<sup>1</sup>

Several surgical techniques have been described for anterior glenoid fractures (Ideberg type 1A). Traditionally, these injuries have been approached surgically through an open approach and internal screw fixation.<sup>2</sup> However, open surgery including arthrotomy with splitting or detachment of the subscapularis tendon is associated with several potential complications due to the substantial soft-tissue injury or owing to the risk of fracture fragmentation. Range of motion is poorer and the complication and reoperation rates are higher after open surgery compared with arthroscopic techniques.<sup>3,4</sup> Arthroscopy enables perfect visualization of the articular surface, minimizes the need for soft-tissue dissection, and offers the opportunity to both detect and address concomitant intra-articular injuries. Therefore, multiple arthroscopic methods have been described. Arthroscopic screw fixation techniques remain problematic as well because the optimal positioning of the implants—from inferior and medial—usually necessitates a portal through the subscapularis muscle and places the brachial

plexus at risk.<sup>5</sup> In addition, screw heads might lead to hardware impingement especially when a safer, lateral insertion point is chosen.

As a consequence, several alternative arthroscopic fixation procedures have been developed adapting soft-tissue repair techniques, as suture anchors are placed along the fracture rim onto the glenoid surface. However, the disadvantage is that nonabsorbable sutures are passed not only around the labrum but also around the fracture fragment and the joint surface.<sup>6-9</sup> Furthermore, these fixation methods cannot be used for large fragments that extend far medially, and they are complicated considerably if the capsulolabral complex is ruptured. Moreover, placement of multiple suture anchors in a linear arrangement has been associated with recurrent glenoid rim fractures along the anchor insertion sites.<sup>10</sup>

Therefore, our aim was to describe a safe interfragmentary, transosseous technique for arthroscopic fixation of intermediate or large anterior glenoid fractures (Ideberg type 1A) using a double-cortical button technique. This procedure uses a system (Round EndoButton System) that originally was developed for placement of tricortical iliac crest bone on the eroded anterior glenoid in cases of chronic instability.<sup>11,12</sup> Particularly, the hook of the glenoid guide—primarily designed for orientation on the eroded anterior glenoid—can be used optimally as a repositioning tool to pull an anterior glenoid fragment in the posterior direction (Video 1).

With respect to limitations (Table 2), the presented method cannot be applied to small fragments or multifragmentary fractures. In addition, the technique requires 2 experienced shoulder surgeons. However, it offers several advantages: It preserves the integrity of the subscapularis tendon. Placement of anchors onto the surface of the glenoid is not necessary, and the technique avoids sutures passing over the glenoid cartilage. It only leaves one or at most two 2.8-mm tunnels in the glenoid and the fracture fragment, parallel to the articular surface. Biomechanically, it allows an optimal spread of compression onto the fragment through the anterior button.<sup>13</sup> Hardware irritation is

**Table 2.** Advantages and Disadvantages of Suture Button Fixation Technique

Advantages	<ul style="list-style-type: none"> <li>Completely arthroscopic technique, just requiring standard portals</li> <li>Ability to address concomitant intra-articular injuries</li> <li>No risk of plexus injury as in arthroscopic screw osteosynthesis</li> <li>No need for detachment or a split of the subscapularis tendon (as in open surgery) or for a portal through the subscapularis tendon (as in arthroscopic techniques)</li> </ul>
Disadvantages	<ul style="list-style-type: none"> <li>Technically challenging method because it requires 2 surgeons capable of performing shoulder arthroscopy</li> <li>Not applicable for small fragments or multifragmentary fractures</li> </ul>

unlikely; thus, potential hardware removal is not necessary. Altogether, this technique can be used to achieve anatomic reduction and stable fixation of intermediate to large anterior glenoid fractures while minimizing the previously described risks associated with arthroscopic or open approaches.

## References

- Ideberg R, Grevsten S, Larsson S. Epidemiology of scapular fractures. Incidence and classification of 338 fractures. *Acta Orthop Scand* 1995;66:395-397.
- Mayo KA, Benirschke SK, Mast JW. Displaced fractures of the glenoid fossa. Results of open reduction and internal fixation. *Clin Orthop Relat Res* 1998;347:122-130.
- Bonnevialle N, Clavert P, Arboucalot M, et al. Contribution of arthroscopy in the treatment of anterior glenoid rim fractures: A comparison with open surgery. *J Shoulder Elbow Surg* 2019;28:42-47.
- Plath JE, Feucht MJ, Bangoj R, et al. Arthroscopic suture anchor fixation of bony Bankart lesions: Clinical outcome, magnetic resonance imaging results, and return to sports. *Arthroscopy* 2015;31:1472-1481.
- Cameron SE. Arthroscopic reduction and internal fixation of an anterior glenoid fracture. *Arthroscopy* 1998;14:743-746.
- Porcellini G, Campi F, Paladini P. Arthroscopic approach to acute bony Bankart lesion. *Arthroscopy* 2002;18:764-769.
- Sugaya H, Kon Y, Tsuchiya A. Arthroscopic repair of glenoid fractures using suture anchors. *Arthroscopy* 2005;21:635.
- Voleti PB, Camp CL, Sinatro AL, Dines JS. Arthroscopic fixation of glenoid rim fractures after reduction by labral repair. *Arthrosc Tech* 2016;18:e379-e383.
- Millett PJ, Braun S. The "bony Bankart bridge" procedure: A new arthroscopic technique for reduction and internal fixation of a bony Bankart lesion. *Arthroscopy* 2009;25:102-105.
- Nakagawa S, Hirose T, Tachibana Y, Iuchi R, Mae T. Postoperative recurrence of instability due to new anterior glenoid rim fractures after arthroscopic Bankart repair. *Am J Sports Med* 2017;45:2840-2848.
- Taverna E, D'Ambrosi R, Perfetti C, Garavaglia G. Arthroscopic bone graft procedure for anterior inferior glenohumeral instability. *Arthrosc Tech* 2014;3:e653-e660.
- Taverna E, Guarella V, Freehill MT, Garavaglia G. Arthroscopic reduction with EndoButton fixation for glenoid fracture. *Joints* 2017;5:127-130.
- Boileau P, Saliken D, Gendre P, et al. Arthroscopic Latarjet: Suture-button fixation is a safe and reliable alternative to screw fixation. *Arthroscopy* 2019;35:1050-1061.