

Detection of neurokinin-1 receptor by immunohistochemistry in canine mammary gland tumours

Duri Song¹ | Ye-In Oh¹  | Jeong-Mi Kim¹ | Doo-Sung Cheon² | Dae-Yong Kim³ |
Kyoung-Won Seo¹ 

¹College of Veterinary Medicine, Chungnam National University, Daejeon, Korea

²Postbio, Guri, Korea

³College of Veterinary Medicine, Seoul National University, Seoul, Korea

Correspondence

Kyoung-won Seo, N13-2, #308, VMTH of College of Veterinary Medicine, Chungnam National University, 99 Daehak-ro, Yuseong-gu, Daejeon 34134, Republic of Korea.
Email: kwseo@cnu.ac.kr

Funding information

Chungnam National University

Abstract

Canine mammary gland tumour (cMGT) is the most common tumour in intact female dogs. Surgery is the only effective treatment for cMGT, and dogs with metastasis at the time of diagnosis or those diagnosed at an advanced stage have poorer prognosis. Thus, novel diagnostic biomarkers and therapeutic targets are needed. Neurokinin-1 receptor (NK-1 receptor) is involved in cancer progression and has been detected in various malignant tumours including breast cancer in humans. Furthermore, NK-1 receptor antagonists inhibit cancer progression. We evaluated NK-1 receptor expression in malignant and benign cMGT compared with that in normal mammary gland tissues and analysed the relationship between the expression of NK-1 receptor and histopathological type or malignancy grade. Specimens from 34 malignant MGT and 35 benign MGT cases were used for immunohistochemistry and scored according to intensity and percentage. Healthy margins from each tumour were used as internal controls. The scores for NK-1 receptor intensity, percentage of positive cells and overall immunohistochemistry were higher in malignant MGT than in benign MGT and normal tissue ($p < .000$). NK-1 receptor expression was not correlated with either malignancy grade or histopathological type. Expression of the NK-1 receptor in malignant MGT was higher than that in benign MGT and normal tissues. Thus, NK-1 receptor could be considered a novel therapeutic target for cMGT. Further studies using other quantitative tests such as western blotting or PCR and the evaluation of substance P in patient tumour tissue or serum are needed.

KEYWORDS

dogs, immunohistochemistry, mammary gland, neurokinin-1 receptor, tumour

1 | INTRODUCTION

Neurokinin-1 receptor (NK-1 receptor), also known as tachykinin receptor 1 or substance P receptor, is a G protein-coupled receptor distributed in the central and peripheral nervous system.

Substance P (SP), an undecapeptide, is a member of the tachykinin neuropeptide family and has high affinity for the NK-1 receptor (Datar, Srivastava, Coutinho, & Govil, 2004; Maggi, Patacchini, Rovero, & Giachetti, 1993). SP functions as a neuromodulator and neurotransmitter through the NK-1 receptor

This is an open access article under the terms of the Creative Commons Attribution-NonCommercial-NoDerivs License, which permits use and distribution in any medium, provided the original work is properly cited, the use is non-commercial and no modifications or adaptations are made.

© 2020 The Authors. *Veterinary Medicine and Science* Published by John Wiley & Sons Ltd

(Datar et al., 2004). NK-1 receptor and SP have been reported to mediate physiologic processes such as pain transmission (Saria, 1987), the vomit reflex (Saito, Takano, & Kamiya, 2003), wound healing, tissue homeostasis, inflammation (Suvas, 2017), haematopoiesis (Nowicki, Ostalska-Nowicka, Kondraciuk, & Miskowiak, 2007) and cardiovascular functions (Mistrova, Kruzliak, & Dvorakova, 2016).

NK-1 receptor and SP have been reported to be involved in cancer progression, and numerous studies aimed to identify new targets for cancer diagnosis and therapy have focused on the NK-1 receptor (Munoz, Rosso, & Covenas, 2011). NK-1 receptor and SP are detected not only in tumour cells but also in intratumoral and peritumoral blood vessels and are therefore thought to be involved in tumour angiogenesis (Hennig, Laissue, Horisberger, & Reubi, 1995; Munoz et al., 2011). NK-1 receptor and SP were reported to inhibit tumour cell apoptosis and induce tumour cell proliferation by acting as mitogens, induce the migration of tumour cells and stimulate neoangiogenesis (Covenas & Munoz, 2014; Rosso, Munoz, & Berger, 2012). Moreover, NK-1 receptor antagonists suppress the angiogenesis, proliferation and migration of tumour cells and decrease viability of tumour cells (Covenas & Munoz, 2014; Rosso et al., 2012). NK-1 receptor and SP were previously detected in various cancers including lung cancer (Muñoz et al., 2012), colon cancer (Rosso, Robles-Frias, Coveñas, Salinas-Martín, & Muñoz, 2008), pancreatic cancer (Friess et al., 2003), endometrial cancer (Gharaee, Pourali, Jafarian, & Hashemy, 2018) and melanoma (Muñoz et al., 2010). In human breast cancer (HBC), various studies have confirmed the increased serum levels of SP, as well as the overexpression of SP and NK-1 receptors, in tumour tissues compared with those in normal tissues through various methods (Davoodian et al., 2019; Huang, Wang, Chen, Wei, & Chen, 2010; Munoz et al., 2014; Zhou et al., 2013). Thus, the NK-1 receptor might be useful as a novel diagnostic biomarker or therapeutic target for HBC.

Canine mammary gland tumour (cMGT) is the most common neoplasia in intact female dogs, and approximately 50% of these cases are malignant tumours. The main cause of death from this tumour is metastasis (Klopfleisch et al., 2011; Sleenckx, de Rooster, Veldhuis Kroeze, Van Ginneken, & Van Brantegem, 2011; Sorenmo, 2003). Surgery is the only effective treatment for cMGT, and few studies have evaluated the effect of anticancer therapy or radiotherapy on this disease (Cassali et al., 2011). cMGT has numerous similarities with HBC including histology, tumour genetics, biological behaviour and response to therapy (Khanna & Hunter, 2005; Khanna et al., 2006; Paoloni & Khanna, 2007, 2008; Pinho, Carvalho, Cabral, Reis, & Gärtner, 2012; Paoloni and Khanna, 2008; Vail & Macewen, 2000). Many studies have also shown that the NK-1 receptor is highly expressed in HBC; however, in veterinary medicine, its expression has only been evaluated in melanoma (Borrego et al., 2016). In this study, NK-1 receptor expression was evaluated in cMGT by immunohistochemistry, and the correlation between NK-1 receptor expression and malignancy grade or histopathological type was analysed.

2 | MATERIALS AND METHODS

2.1 | Cell line validation statement

No cell lines were used for this study.

2.2 | Mammary specimens

Thirty-four malignant and 35 benign MGT samples obtained from female dogs after surgery at various animal hospitals in 2018 and 2019, supplied by Pobanilab (Guri, Republic of Korea), were subjected to histopathological diagnosis at Pobanilab.

2.3 | Immunohistochemistry analysis of NK-1 receptor expression

Paraffin-embedded cMGT sections (4- μ m) were deparaffinized in xylene and rehydrated in a graded ethyl alcohol series. The sections were incubated with antigen retrieval solution (Sigma-Aldrich) in a water bath (95°C) under high pressure. To quench endogenous peroxidase, the sections were placed in 3% methanolic H₂O₂ for 30 min and treated with 0.5% triton X-100 for 30 min. To block nonspecific binding sites, the sections were incubated in normal goat serum (Vector Laboratories) at room temperature for 2.5 hr. A primary antibody specific for the NK-1 receptor (rabbit polyclonal, Advanced Targeting Systems) was diluted 1:300 with distilled phosphate-buffered saline and added to the sections at 4 °C for overnight incubation (at least 16 hr). This synthetic peptide corresponds to the C-terminus of the dog NK-1 receptor. The healthy margin of each tumour was used as a control sample to evaluate NK-1 receptor expression. Negative control sections were treated with distilled phosphate-buffered saline. After incubation at room temperature for 1 hr and washing, secondary antibody (goat anti-rabbit IgG, Ab Frontier, Seoul, South Korea) diluted 1:200 was added to the sections. The sections were incubated in AB complex (Vector Laboratories) at room temperature for 30 min and then treated with 3,3'-diaminobenzidine tetrahydrochloride (Vector Laboratories). Mayer's haematoxylin was used for counterstaining, which was followed by dehydration and decolourization using ethyl alcohol and xylene. After mounting with Canada balsam, the sections were incubated at room temperature overnight. Canine colon tissues, used as positive controls, were prepared using the same method as previously (Borrego et al., 2016; Goode et al., 2000).

2.4 | Semi-quantitative scoring of positive cells

Immunohistochemistry results were examined by an investigator and confirmed by a pathologist blinded to the identity of each specimen. Ten immunopositive areas in each section were evaluated at 400 \times magnification. Brown colours in the cytoplasm, plasma membrane

and nucleus were considered indicative of a positive reaction. The intensity of staining and percentage of positive cells were assessed semi-quantitatively by assigning scores of 1–3 and 1–4, respectively (Table 1). The immunohistochemical (IHC) score of the NK-1 receptor was obtained by multiplying the intensity and positivity scores (range 1–12). IHC scores below 6 were considered to reflect low expression, whereas those over 6 were considered to reflect high expression of the NK-1 receptor at the tissue level (Pandey et al., 2018).

2.5 | Statistical analysis

Statistical analysis was performed using SPSS ver. 24 (SPSS, Inc.). All IHC results are presented as the mean \pm SD, and statistical significance was considered at a p -value $< .05$.

3 | RESULTS

Sixty-nine archived MGT specimens including 34 malignant and 35 benign tumour specimens were investigated in this study. Details of the types of specimens and their histological grade are shown in Table 2.

3.1 | NK-1 receptor expression

3.1.1 | Immunolocalization

Immunoreactivity was detected in the cytoplasm of both cMGT cells and normal cells (Figure 1). Of the 69 specimens, 40 (57%) showed immunoreactivity in the plasma membrane, 20 (30%) showed immunoreactivity in the nucleus and 14 (20%) showed immunoreactivity in the cytoplasm, plasma membrane and nucleus.

3.1.2 | Staining intensity

All sections were evaluated based on a semi-quantified score according to the scoring system shown in Table 1. The mean staining intensity scores in malignant MGTs, benign MGTs and healthy margins were 2.09 ± 0.668 , 1.63 ± 0.770 and 1.30 ± 0.564 , respectively. Scores were significantly different among the three groups, with the

TABLE 1 Scoring system for immunohistochemistry in canine mammary gland tumours and healthy margins

Score	Intensity of staining	Score	Percentage of positive cells
1	Weak	1	$\leq 25\%$
2	Moderate	2	26%–50%
3	Strong	3	51%–75%
		4	$\geq 76\%$

highest score observed in malignant MGTs and the lowest score observed in healthy margins based on nonparametric Kruskal-Wallis tests ($p = .008$, $p < .000$, respectively) and the Jonckheere-Terpstra test ($p < .000$).

3.1.3 | Percentage of stained cells

The mean scores for the percentage of stained cells in malignant MGTs, benign MGTs and healthy margins were 3.44 ± 0.660 , 2.31 ± 0.758 and 2.03 ± 0.698 , respectively. For malignant MGTs, this score was significantly different than that for benign MGTs and healthy margins. The highest score was observed for malignant MGTs and the lowest score was observed for healthy margins based on a nonparametric Kruskal-Wallis test ($p < .000$) and the Jonckheere-Terpstra test ($p < .000$). There was no significant difference between benign tumours and healthy margin tissues ($p = .095$).

3.2 | IHC score of NK-1 receptor

Each score of intensity and percentage of positive cells was multiplied to obtain the final IHC scores for NK-1 receptor expression. The mean IHC scores in malignant MGTs, benign MGTs and healthy margins were 7.41 ± 3.201 , 4.03 ± 2.833 and 2.80 ± 1.924 , respectively. Among the 40 MGT specimens with a healthy margin, 27

TABLE 2 Histopathological types of canine mammary gland tumour specimens and grade of malignancy

	Histopathological type	Grade	<i>n</i>
Malignant tumour	Mixed carcinoma	1	2
	Ductal carcinoma	1	6
		2	8
		3	1
	Simple carcinoma	1	2
		2	1
	Complex carcinoma	1	6
		2	2
	Malignant myoepithelioma	1	5
		2	1
	Total		34
Benign tumour	Simple adenoma		3
	Intraductal papillary adenoma		5
	Complex adenoma		8
	Mixed adenoma		8
	Ductal adenoma		8
	Cystadenoma		2
	Myoepithelioma		1
	Total		35

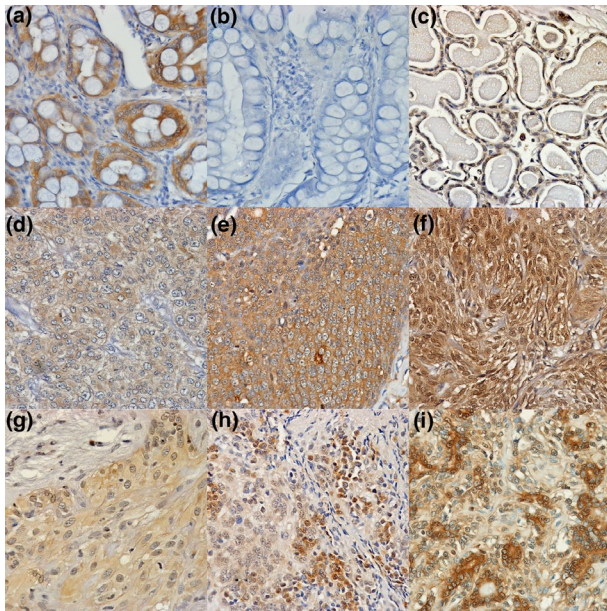


FIGURE 1 Immunohistochemistry for NK-1 receptor in canine colon tissue, malignant MGT and benign MGT specimens at 400x magnification. (a) Positive staining of canine colon tissue. (b) Negative control staining for canine colon tissue. (c) Weak staining of healthy margin of MGT. (d) Weak staining (score 1) of malignant MGT. (e) Moderate staining (score 2) of malignant MGT. (f) Strong staining (score 3) of malignant MGT. (g) Weak staining (score 1) of benign MGT. (h) Moderate staining (score 2) of benign MGT. (i) Strong staining (score 3) of benign MGT. MGT, mammary gland tumour

(67.5%) showed higher scores, 11 (27.5%) showed similar scores and 2 specimens (5%) showed lower scores in tumour tissues compared with those in the healthy margin of each tumour (Figure 2). High expression (IHC score ≥ 6) of the receptor was observed in 76%, 31.4% and 17.5% of malignant MGTs, benign MGTs and healthy margins, respectively. The IHC score significantly differed among the three groups, with the highest scores observed in malignant MGTs and the lowest scores observed in healthy margins, based on the nonparametric Kruskal-Wallis Jonckheere-Terpstra test ($p < .000$).

3.3 | Relationships between NK-1 receptor expression and malignancy grade or histopathological type

Results indicated that 72% of grade I malignant MGTs and 80% of grade II MGTs showed high receptor expression (IHC score ≥ 6). One (1/1) grade III malignant MGT showed high receptor expression. Furthermore, 86% of ductal carcinoma, 37.5% of complex carcinoma and 66.6% of malignant myoepithelioma cases showed high expression. All mixed carcinoma (2/2) and simple carcinoma (3/3) cases showed high expression. In addition, 33% of simple adenoma, 40% of intraductal papillary adenoma, 37.5% of complex adenoma, 25% of mixed adenoma and 12.5% of ductal adenoma showed high receptor expression. All cystadenoma cases (2/2) showed high expression

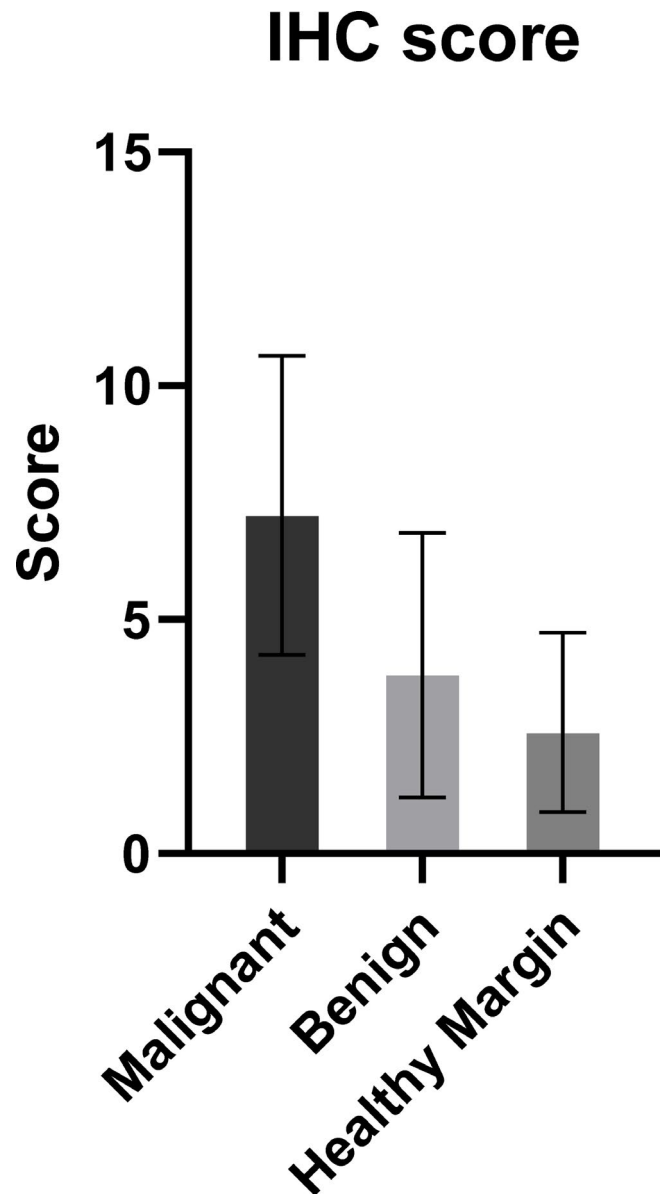


FIGURE 2 Immunohistochemical (IHC) scores for NK-1 receptor expression in malignant and benign MGTs and healthy margins. The mean IHC scores in malignant MGTs, benign MGTs and healthy margins were 7.41 ± 3.201 , 4.03 ± 2.833 and 2.80 ± 1.924 , respectively ($p < .000$). MGT, mammary gland tumour

and myoepithelioma (1/1) showed low expression of the receptor. The relationships among the intensity score, positivity score or combined IHC results and malignancy grade or histopathological type were evaluated by nonparametric Kruskal-Wallis, Mann-Whitney, Spearman and Jonckheere-Terpstra tests. No relationships showed significant results ($p > .05$).

4 | DISCUSSION

Metastasis is the most common cause of death related to malignant cMGT; the median survival time is 5 months for dogs with metastasis and 28 months for dogs without metastasis (Philibert et al., 2003).

However, most dogs with MGT are clinically healthy without disease signs, particularly early in the course of the disease. Dogs with metastasis show only nonspecific signs unless they have a grossly detectable tumour (Sorenmo, 2003). Furthermore, malignant and benign cMGT show similar characteristics in early stages but differ in progression and prognosis. Thus, tools to differentiate malignant and benign cMGT are required. Furthermore, conventional therapy, particularly chemotherapy, is less effective when used alone, and few studies have examined its effectiveness for cMGT (Sorenmo, 2003; Cassali et al., 2011); thus, novel therapeutic targets for adjuvant therapy are required. Most HBCs express oestrogen receptor, human epidermal growth factor receptor type 2 (HER-2) (Yamauchi, Stearns, & Hayes, 2001) and NK-1 receptor (Munoz et al., 2014), and several studies have investigated the anticancer effect of hormonal therapy by targeting these receptors in HBC (Cole, Jones, & Todd, 1971; Munoz et al., 2014). Malignant cMGT, however, shows different oestrogen receptor (Toniti et al., 2009) and HER-2 receptor (Burrai et al., 2015) expression patterns from those of HBC, making it difficult to apply these therapies to cMGT. The expression of NK-1 receptor in cMGT has not been investigated; thus, we studied the possibility of applying NK-1 receptor expression to differentiate malignant and benign tumours and its use as a novel therapeutic target for cMGT.

Whereas several studies demonstrated the expression of NK-1 receptor in HBC cell lines or tumour tissue by various methods (Davoodian et al., 2019; Huang et al., 2010; Munoz et al., 2014; Schulz, Stumm, Röcken, Mawrin, & Schulz, 2006), to our knowledge, this is the first study to evaluate NK-1 receptor expression in cMGT. In this study, NK-1 receptor expression was higher in malignant MGT than in benign and normal tissues, which is similar to the results of previous HBC studies and suggests that the NK-1 receptor is involved in cMGT development. The NK-1 receptor in cMGT was found to be immunoreactive in the cytoplasm, plasma membrane and nucleus (Huang et al., 2010; Munoz et al., 2014; Schulz et al., 2006). Similarly, in HBC, the NK-1 receptor was found to be immunoreactive in these three cellular locations (Davoodian et al., 2019; Huang et al., 2010; Munoz et al., 2014). Expression of the NK-1 receptor is very high in the cytoplasm in both HBC and cMGT (Davoodian et al., 2019). However, its specific function in each region of breast cancer cells is unknown and should be further examined with respect to the cytoplasm, plasma membrane and nucleus.

In human medicine, SP is also known to be overexpressed in malignant breast cancer tissues (Singh et al., 2000), and patients with HBC show higher serum concentrations of SP than normal subjects (Davoodian et al., 2019). This suggests that neuroendocrine mechanisms associated with NK-1 receptor and SP are involved in HBC development. In veterinary medicine, SP serum concentrations in patients with tumours or its expression in tumour tissues have not been evaluated. Further studies are needed to evaluate SP in canine tumour tissues.

The two subtypes of the NK-1 receptor, full-length receptor (NK1-FI) and truncated receptor (NK1-Tr), have been reported in human medicine, and the truncated form of the NK-1 receptor lacks

100 residues in the cytoplasmic tail (Fong, Anderson, Yu, Huang, & Strader, 1992). NK1-FI expression is reduced in malignant tumours, and NK1-Tr is overexpressed in tumour cells and involved in tumour progression and distant metastasis (Zhou et al., 2013). However, several studies have confirmed the expression of NK-1 receptor in malignant tumours with NK1-FI (Huang et al., 2010; Schulz et al., 2006) and have shown increased NK-1 receptor expression in breast cancer cells compared with that in normal breast epithelial cells (Munoz et al., 2014; Patel, Ramkissoon, Patel, & Rameshwar, 2005). Furthermore, metastatic breast cancer cells show higher expression of NK1-FI than nonmetastatic breast cancer cells, and the expression levels of NK1-FI and NK1-Tr were found to be similar in metastatic breast cancer cells (Nizam & Erin, 2018). According to differences in the expression of NK1-FI in malignant breast cancer cells, the rate of NK1-FI expression has not been precisely determined in HBC and has not been studied in cMGT.

In this study, an antibody corresponding to the C-terminus of the canine NK-1 receptor was used to screen NK-1 receptor expression in cMGT, as this antibody had been previously used for immunofluorescence analysis of dog spinal cord neurons (Wiese et al., 2013). This study showed that NK1-FI is increased in malignant cMGT compared with that in healthy tissues. Total NK-1 receptor expression in malignant cMGT is thought to be significantly different from that in normal tissues but was not evaluated in this study. No studies have examined the involvement or function of NK1R-FI and NK1R-Tr in cancer progression in dogs. After further clarifying the function and expression of the two types of NK-1 receptor in canine tumour progression, screening each type and total NK-1 receptors in cMGT will be required.

In this study, a comparison of NK-1 receptor expression based on malignancy grade or histopathologic types revealed no significant association. In one study on HBC, cytoplasmic expression of NK-1 receptor was found to be significantly correlated with most tumour features, such as grade, size, HER-2 expression, and primary tumour, lymph node and metastasis (TNM) stage (Davoodian et al., 2019). Large numbers of invasive ductal carcinoma cases ($n = 39$) and various tumour grades were evaluated in HBC; however, the number of samples from each histopathological type ($n = 1-8$) and grade was low in our study. Thus, further studies comprising larger populations are needed.

NK-1 receptor antagonists such as aprepitant and maropitant show anticancer effects by inhibiting tumour cell growth, angiogenesis and metastasis at the tumour cell level (Munoz, Covenas, Esteban, & Redondo, 2015). In one study, NK-1 receptor antagonists including L-732,138, L-733,060 and aprepitant were shown to dose dependently inhibit the growth of an HBC cell line (Munoz et al., 2014). Another study showed that breast cancer cell growth is inhibited by NK-1 receptor antagonists, with higher sensitivity observed in a metastatic breast cancer cell line than in a nonmetastatic breast cancer cell line (Nizam & Erin, 2018). In veterinary oncology, maropitant treatment inhibits the growth of canine melanoma cells in a concentration-dependent manner (Borrego et al., 2016). Our study demonstrates the potential of NK-1 receptor

antagonists as a novel drug treatment for various cancers. Further studies of the anticancer effects of NK-1 receptor antagonists on cMGT are needed.

Two limitations of this study are as follows. First, we evaluated NK-1 receptor expression only by IHC; other quantitative tests of NK-1 receptor protein or mRNA expression such as western blotting or RT-PCR were not carried out. Furthermore, as the specimens were collected for diagnosis based on the histopathology of tumours and data for each specimen were not collected, the correlation between TNM stage and expression of the NK-1 receptor was not analysed in this study.

We evaluated NK-1 receptor expression by IHC analysis in cMGT. We observed higher NK-1 receptor expression in malignant MGT than in benign MGT and normal mammary gland tissues, indicating that the NK-1 receptor is involved in cancer progression. However, there was no correlation between NK-1 receptor expression and malignancy grade or histopathologic type. Further studies employing other quantitative tests such as western blotting or PCR and those evaluating SP in tumour tissues or serum samples from patients are needed. In addition, the anticancer effect of NK-1 receptor antagonists on MGT requires further analysis. In summary, NK-1 receptor is highly expressed in cMGT and thus may be a novel therapeutic target for cMGT.

ACKNOWLEDGEMENT

This manuscript is written based on the Master's thesis of author Duri Song. This study was supported by Chungnam National University.

CONFLICT OF INTEREST

The authors have no conflicts of interest to declare.

AUTHOR CONTRIBUTIONS

Duri Song: Investigation; Methodology; Writing-original draft. **Ye-In Oh:** Validation; Writing-review & editing. **Jeong-mi Kim:** Methodology; Resources. **Doo-Sung Cheon:** Resources. **Dae-yong Kim:** Resources; Writing-review & editing. **Kyoung Won Seo:** Conceptualization; Investigation; Project administration; Supervision; Validation; Writing-review & editing.

CELL VALIDATION STATEMENT

No cell lines utilized for study.

ETHICAL ASPECTS

This study was approved by the Ethics Committee on Animal Experimentation of the Chungnam National University (Approval number 201909A-CNU-114; Daejeon, Republic of Korea).

DATA AVAILABILITY STATEMENT

The data that support the findings of this study are available from the corresponding author upon reasonable request.

PEER REVIEW

The peer review history for this article is available at <https://publons.com/publon/10.1002/vms3.323>

ORCID

Ye-In Oh  <https://orcid.org/0000-0001-8082-2458>

Kyoung-Won Seo  <https://orcid.org/0000-0002-1561-3278>

REFERENCES

- Borrego, J. F., Huelsmeyer, M. K., Pinkerton, M. E., Muszynski, J. L., Miller, S. A. K., Kurzman, I. D., & Vail, D. M. (2016). Neurokinin-1 receptor expression and antagonism by the NK-1R antagonist maropitant in canine melanoma cell lines and primary tumour tissues. *Veterinary and Comparative Oncology*, 14, 210–224. <https://doi.org/10.1111/vco.12093>
- Burrai, G. P., Tanca, A., De Miglio, M. R., Abbondio, M., Pisanu, S., Polinas, M., ... Antuofermo, E. (2015). Investigation of HER2 expression in canine mammary tumors by antibody-based, transcriptomic and mass spectrometry analysis: Is the dog a suitable animal model for human breast cancer? *Tumour Biology*, 36(11), 9083–9091. <https://doi.org/10.1007/s13277-015-3661-2>
- Cassali, G. D., Lavalle, G. E., De Nardi, A. B., Ferreira, E., Bertagnolli, A. C., Estrela-Lima, A., ... Campos, C. B. (2011). Consensus for the diagnosis, prognosis and treatment of canine mammary tumors. *Brazilian Journal of Veterinary Pathology*, 4(2), 153–180.
- Cole, M. P., Jones, C. T., & Todd, I. D. (1971). A new anti-oestrogenic agent in late breast cancer. An early clinical appraisal of ICI46474. *British Journal of Cancer*, 25(2), 270–275. <https://doi.org/10.1038/bjc.1971.33>
- Covenas, R., & Munoz, M. (2014). Cancer progression and substance P. *Histology and Histopathology*, 29(7), 881–890. <https://doi.org/10.14670/HH-29.881>
- Datar, P., Srivastava, S., Coutinho, E., & Govil, G. (2004). Substance P: Structure, function, and therapeutics. *Current Topics in Medicinal Chemistry*, 4(1), 75–103. <https://doi.org/10.2174/1568026043451636>
- Davoodian, M., Boroumand, N., Mehrabi Bahar, M., Jafarian, A. H., Asadi, M., & Hashemy, S. I. (2019). Evaluation of serum level of substance P and tissue distribution of NK-1 receptor in breast cancer. *Molecular Biology Report*, 46(1), 1285–1293. <https://doi.org/10.1007/s11033-019-04599-9>
- Fong, T. M., Anderson, S. A., Yu, H., Huang, R., & Strader, C. D. (1992). Differential activation of intracellular effector by two isoforms of human neurokinin-1 receptor. *Molecular Pharmacology*, 41(1), 24–30.
- Friess, H., Zhu, Z., Liard, V., Shi, X., Shrikhande, S. V., Wang, L. I., ... Büchler, M. W. (2003). Neurokinin-1 receptor expression and its potential effects on tumor growth in human pancreatic cancer. *Laboratory Investigation*, 83, 731–742. <https://doi.org/10.1097/01.lab.0000067499.57309.f6>
- Gharaee, N., Pourali, L., Jafarian, A. H., & Hashemy, S. I. (2018). Evaluation of serum level of substance P and tissue distribution of NK-1 receptor in endometrial cancer. *Molecular Biology Reports*, 45(6), 2257–2262. <https://doi.org/10.1007/s11033-018-4387-1>
- Goode, T., O'Connell, J., Anton, P., Wong, H., Reeve, J., O'Sullivan, G. C., ... Shanahan, F. (2000). Neurokinin-1 receptor expression in inflammatory bowel disease: Molecular quantitation and localisation. *Gut*, 47, 387–396. <https://doi.org/10.1136/gut.47.3.387>
- Hennig, I. M., Laissue, J. A., Horisberger, U., & Reubi, J. C. (1995). Substance-P receptors in human primary neoplasms: Tumoral and vascular localization. *International Journal of Cancer*, 61(6), 786–792. <https://doi.org/10.1002/ijc.2910610608>
- Huang, W. Q., Wang, J. G., Chen, L., Wei, H. J., & Chen, H. (2010). SR140333 counteracts NK-1 mediated cell proliferation in human breast cancer cell line T47D. *Journal of Experimental and Clinical Cancer Research*, 29, 55. <https://doi.org/10.1186/1756-9966-29-55>
- Khanna, C., & Hunter, K. (2005). Modeling metastasis in vivo. *Carcinogenesis*, 26(3), 513–523. <https://doi.org/10.1093/carcin/bgh261>
- Khanna, C., Lindblad-Toh, K., Vail, D., London, C., Bergman, P., Barber, L., ... Withrow, S. (2006). The dog as a cancer model. *Nature Biotechnology*, 24(9), 1065–1066. <https://doi.org/10.1038/nbt0906-1065b>

- Klopfleisch, R., Von Euler, H., Sarli, G., Pinho, S., Gärtner, F., & Gruber, A. (2011). Molecular carcinogenesis of canine mammary tumors: News from an old disease. *Veterinary Pathology*, 48(1), 98–116. <https://doi.org/10.1177/0300985810390826>
- Maggi, C. A., Patacchini, R., Rovero, P., & Giachetti, A. (1993). Tachykinin receptors and tachykinin receptor antagonists. *Journal of Autonomic Pharmacology*, 13(1), 23–93. <https://doi.org/10.1111/j.1474-8673.1993.tb00396.x>
- Mistrova, E., Kruzliak, P., & Dvorakova, M. C. (2016). Role of substance P in the cardiovascular system. *Neuropeptides*, 58, 41–51. <https://doi.org/10.1016/j.npep.2015.12.005>
- Munoz, M., Covenas, R., Esteban, F., & Redondo, M. (2015). The substance P/NK-1 receptor system: NK-1 receptor antagonists as anti-cancer drugs. *Journal of Biosciences*, 40(2), 441–463. <https://doi.org/10.1007/s12038-015-9530-8>
- Muñoz, M., González-Ortega, A., Rosso, M., Robles-Frias, M. J., Carranza, A., Salinas-Martín, M. V., & Coveñas, R. (2012). The substance P/neurokinin-1 receptor system in lung cancer: Focus on the antitumor action of neurokinin-1 receptor antagonists. *Peptides*, 38(2), 318–325. <https://doi.org/10.1016/j.peptides.2012.09.024>
- Munoz, M., Gonzalez-Ortega, A., Salinas-Martín, M. V., Carranza, A., Garcia-Recio, S., Almendro, V., & Coveñas, R. (2014). The neurokinin-1 receptor antagonist aprepitant is a promising candidate for the treatment of breast cancer. *International Journal of Oncology*, 45(4), 1658–1672. <https://doi.org/10.3892/ijo.2014.2565>
- Munoz, M., Rosso, M., & Covenas, R. (2011). The NK-1 receptor: A new target in cancer therapy. *Current Drug Targets*, 12(6), 909–921. <https://doi.org/10.2174/138945011795528796>
- Muñoz, M., Rosso, M., Robles-Frias, M. J., Salinas-Martín, M. V., Rosso, R., González-Ortega, A., & Coveñas, R. (2010). The NK-1 receptor is expressed in human melanoma and is involved in the antitumor action of the NK-1 receptor antagonist aprepitant on melanoma cell lines. *Laboratory Investigation*, 90(8), 1259–1269. <https://doi.org/10.1038/labinvest.2010.92>
- Nizam, E., & Erin, N. (2018). Differential consequences of neurokinin receptor 1 and 2 antagonists in metastatic breast carcinoma cells; Effects independent of Substance P. *Biomedicine & Pharmacotherapy*, 108, 263–270. <https://doi.org/10.1016/j.biopha.2018.09.013>
- Nowicki, M., Ostalska-Nowicka, D., Kondraciuk, B., & Miskowiak, B. (2007). The significance of substance P in physiological and malignant haematopoiesis. *Journal of Clinical Pathology*, 60(7), 749–755. <https://doi.org/10.1136/jcp.2006.041475>
- Pandey, M., Sunil Kumar, B. V., Gupta, K., Sethi, R. S., Kumar, A., & Verma, R. (2018). Over-expression of mammaglobin-B in canine mammary tumors. *BMC Veterinary Research*, 14(1), 184. <https://doi.org/10.1186/s12917-018-1507-z>
- Paoloni, M. C., & Khanna, C. (2007). Comparative oncology today. *The Veterinary Clinics of North America: Small Animal Practice*, 37(6), 1023–1032. <https://doi.org/10.1016/j.cvsm.2007.08.003>
- Paoloni, M., & Khanna, C. (2008). Translation of new cancer treatments from pet dogs to humans. *Nature Reviews. Cancer*, 8(2), 147–156. <https://doi.org/10.1038/nrc2273>
- Patel, H. J., Ramkissoon, S. H., Patel, P. S., & Rameshwar, P. (2005). Transformation of breast cells by truncated neurokinin-1 receptor is secondary to activation by preprotachykinin-A peptides. *Proceeding of the National Academy of Sciences of the United States of America*, 102(48), 17436–17441. <https://doi.org/10.1073/pnas.0506351102>
- Phillibert, J. C., Snyder, P. W., Glickman, N., Glickman, L. T., Knapp, D. W., & Waters, D. J. (2003). Influence of host factors on survival in dogs with malignant mammary gland tumors. *Journal of Veterinary Internal Medicine*, 17(1), 102–106. [https://doi.org/10.1892/0891-6640\(2003\)017<0102:iophos>2.3.co;2](https://doi.org/10.1892/0891-6640(2003)017<0102:iophos>2.3.co;2)
- Pinho, S. S., Carvalho, S., Cabral, J., Reis, C. A., & Gärtner, F. (2012). Canine tumors: A spontaneous animal model of human carcinogenesis. *Translational Research*, 159(3), 165–172. <https://doi.org/10.1016/j.trsl.2011.11.005>
- Rosso, M., Munoz, M., & Berger, M. (2012). The role of neurokinin-1 receptor in the microenvironment of inflammation and cancer. *The Scientific World Journal*, 2012, 381434. <https://doi.org/10.1100/2012/381434>
- Rosso, M., Robles-Frías, M. J., Coveñas, R., Salinas-Martín, M. V., & Muñoz, M. (2008). The NK-1 receptor is expressed in human primary gastric and colon adenocarcinomas and is involved in the antitumor action of L-733,060 and the mitogenic action of substance P on human gastrointestinal cancer cell lines. *Tumor Biology*, 29(4), 245–254. <https://doi.org/10.1159/000152942>
- Saito, R., Takano, Y., & Kamiya, H. O. (2003). Roles of substance P and NK(1) receptor in the brainstem in the development of emesis. *Journal of Pharmacological Sciences*, 91(2), 87–94. <https://doi.org/10.1254/jphs.91.87>
- Saria, A. (1987). The role of substance P and other neuropeptides in transmission of pain. *Acta Neurochirurgica Supplementum*, 38, 33–35. https://doi.org/10.1007/978-3-7091-6975-9_4
- Schulz, S., Stumm, R., Röcken, C., Mawrin, C., & Schulz, S. (2006). Immunolocalization of full-length NK1 tachykinin receptors in human tumors. *The Journal of Histochemistry and Cytochemistry*, 54(9), 1015–1020. <https://doi.org/10.1369/jhc.6A6966.2006>
- Singh, D., Joshi, D. D., Hameed, M., Qian, J., Gascon, P., Maloof, P. B., ... Rameshwar, P. (2000). Increased expression of preprotachykinin-I and neurokinin receptors in human breast cancer cells: Implications for bone marrow metastasis. *Proceedings of the National Academy of Sciences of the United States of America*, 97(1), 388–393. <https://doi.org/10.1073/pnas.97.1.388>
- Sleeckx, N., de Rooster, H., Veldhuis Kroeze, E. J., Van Ginneken, C., & Van Brantegem, L. (2011). Canine mammary tumours, an overview. *Reproduction in Domestic Animals*, 46(6), 1112–1131. <https://doi.org/10.1111/j.1439-0531.2011.01816.x>
- Sorenmo, K. (2003). Canine mammary gland tumors. *The Veterinary Clinics of North America. Small Animal Practice*, 33(3), 573–596. [https://doi.org/10.1016/s0195-5616\(03\)00020-2](https://doi.org/10.1016/s0195-5616(03)00020-2)
- Suvas, S. (2017). Role of substance P neuropeptide in inflammation, wound healing, and tissue homeostasis. *Journal of Immunology*, 199(5), 1543–1552. <https://doi.org/10.4049/jimmunol.1601751>
- Toniti, W., Buranasinsup, S., Kongcharoen, A., Charoonrut, P., Puchadapirom, P., & Kasorndorkbua, C. (2009). Immunohistochemical determination of estrogen and progesterone receptors in canine mammary tumors. *Asian Pacific Journal of Cancer Prevention*, 10(5), 907–911.
- Vail, D. M., & Macewen, E. G. (2000). Spontaneously occurring tumors of companion animals as models for human cancer. *Cancer Investigation*, 18(8), 781–792. <https://doi.org/10.3109/07357900009012210>
- Wiese, A. J., Rathbun, M., Butt, M. T., Malkmus, S. A., Richter, P. J., Osborn, K. G., ... Yaksh, T. L. (2013). Intrathecal substance P-saporin in the dog distribution, safety, and spinal neurokinin-1 receptor ablation. *Anesthesiology*, 119(5), 1163–1177. <https://doi.org/10.1097/ALN.0b013e3182a95164>
- Yamauchi, H., Stearns, V., & Hayes, D. F. (2001). When is a tumor marker ready for prime time? A case study of c-erb B-2 as a predictive factor in breast cancer. *Journal of Clinical Oncology*, 19(8), 2334–2356. <https://doi.org/10.1200/JCO.2001.19.8.2334>
- Zhou, Y., Zhao, L., Xiong, T., Chen, X., Zhang, Y., Yu, M., ... Yao, Z. (2013). Roles of full-length and truncated neurokinin-1 receptors on tumor progression and distant metastasis in human breast cancer. *Breast Cancer Research and Treatment*, 140(1), 49–61. <https://doi.org/10.1007/s10549-013-2599-6>

How to cite this article: Song D, Oh Y-I, Kim J-M, Cheon D-S, Kim D-Y, Seo K-W. Detection of neurokinin-1 receptor by immunohistochemistry in canine mammary gland tumours. *Vet Med Sci*. 2020;6:958–964. <https://doi.org/10.1002/vms3.323>