

# Occult primary breast cancer presenting with brachial plexopathy: A case report

SAGE Open Medical Case Reports  
Volume 9: 1–5  
© The Author(s) 2021  
Article reuse guidelines:  
sagepub.com/journals-permissions  
DOI: 10.1177/2050313X20985646  
journals.sagepub.com/home/sco



Karen L Zhao<sup>1</sup>, Yusha Liu<sup>1</sup>, Kathryn P Scherpelz<sup>2</sup>, Dennis S Kao<sup>1</sup>  
and Jeffrey B Friedrich<sup>1</sup> 

## Abstract

Breast cancer affects about one in eight women over the course of her lifetime. Occult breast cancer, in which primary breast cancer is detected without evidence of disease in the breast itself, comprises up to 1% of new diagnoses; this is typically detected from abnormal axillary lymph nodes, and distant metastases are rare. Here, we present an unusual case of occult breast cancer presenting as upper extremity pain, edema, and weakness, with a metastatic mass to the brachial plexus being the only site of disease.

## Keywords

Occult breast cancer, brachial plexus tumor

Date received: 9 October 2020; accepted: 14 December 2020

## Introduction

Occult breast cancer is defined as histologically confirmed primary breast cancer without clinical or radiographic evidence of disease in the breast itself. In the vast majority of these cases, cancer is first detected in an axillary lymph node, with an incidence that ranges from 0.1% to 1% of all new breast cancer diagnoses.<sup>1,2</sup> Current National Comprehensive Cancer Network (NCCN) guidelines recommend complete surgical resection with axillary lymph node dissection, plus either whole breast radiation or mastectomy, with or without nodal radiation therapy.<sup>3</sup> Because occult breast cancer tends to present at a more advanced stage, aggressive treatment is often undertaken to optimize patient outcomes.<sup>4</sup>

Occult breast cancer initially presenting with more distant metastases is exceedingly rare.<sup>5,6</sup> These cases, however, are particularly challenging for both diagnosis and treatment, as the structure and function of the affected region and organ system must be carefully considered, even for the initial biopsy. In contrast to axillary involvement in which surgical resection is feasible, metastatic disease in other regions of the body may be either impossible or associated with significant morbidity that may not outweigh potential benefits and may decrease patients' quality of life.

We present a unique case of occult breast cancer presenting as a brachial plexus mass in the absence of axillary lymphadenopathy that was associated with right upper extremity pain, edema, and weakness. The anatomic location of the

metastatic disease encasing critical nerves for upper extremity function had significant implications for diagnostic and therapeutic options.

## Case history

A 68-year-old right-hand dominant woman was referred for evaluation of a right brachial plexus mass. Prior to presentation in our hand surgery clinic, the patient had a history of bilateral shoulder pain following a motor vehicle collision status post left rotator cuff repair; the patient elected to defer right shoulder replacement until she was more symptomatic. Approximately 5 years after her initial injury, she experienced worsening pain in her right shoulder. A large effusion was drained and an arthroplasty was scheduled. However, she continued to have progressive swelling, weakness, and numbness of her right upper extremity. A duplex ultrasound ruled out deep venous thrombosis. Due to concern for

<sup>1</sup>Division of Plastic Surgery, Department of Surgery, University of Washington, Seattle, WA, USA

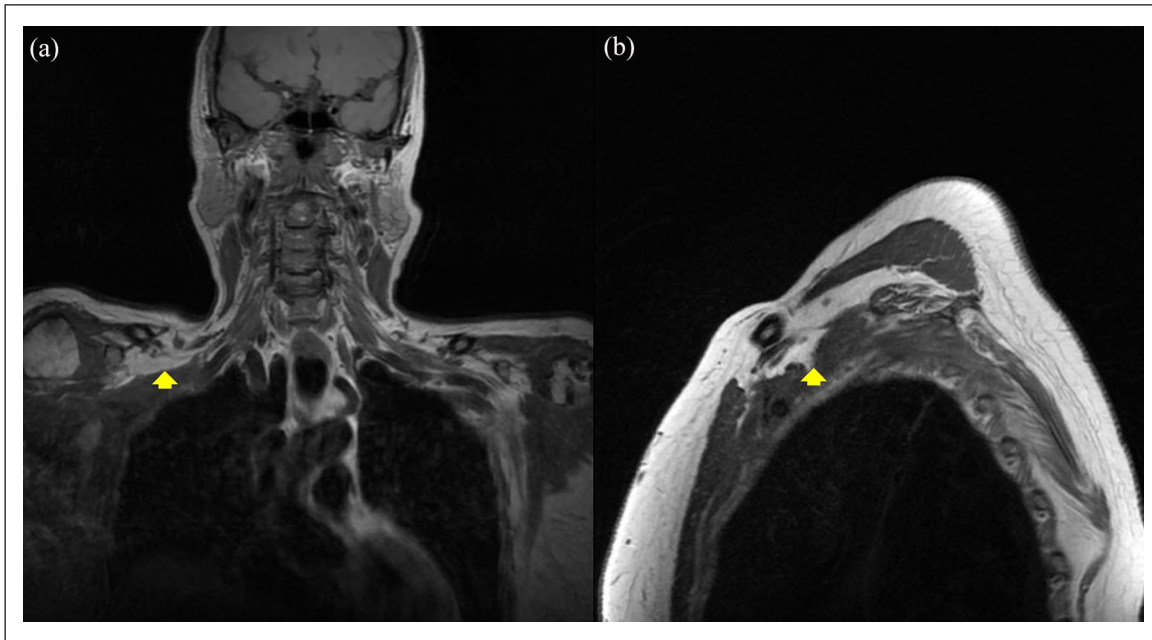
<sup>2</sup>Department of Laboratory Medicine and Pathology, University of Washington, Seattle, WA, USA

### Corresponding Author:

Jeffrey B Friedrich, Division of Plastic Surgery, Department of Surgery, University of Washington, 325 9th Avenue, Box 359796, Seattle, WA 98104, USA.

Email: jfriedri@uw.edu





**Figure 1.** (a) Coronal T1 and (b) sagittal T1. Increased soft tissue with encasement (yellow arrows) is noted of the right brachial plexus divisions and cords superior to the subclavian artery with extension to the axilla.

lymphedema, she was fitted with a compression sleeve and began physical therapy. She was referred to a hand surgeon who preliminarily diagnosed her with bilateral carpal tunnel syndrome and right-sided cubital tunnel syndrome, but advised a second opinion given her lymphedema and unusual clinical presentation. Her sensory and motor function continued to worsen over the course of 6 months, involving both the ulnar and median nerve distributions of the right hand; electrodiagnostic testing was performed with equivocal results, as the report noted that the diagnostic quality of the exam was limited by right upper extremity lymphedema. She was also noted to have neck pain that was relieved by cervical traction so additional imaging was obtained. Magnetic resonance imaging (MRI) revealed a soft tissue mass encasing the right brachial plexus divisions and cords without axillary lymphadenopathy, as well as severe chronic rotator cuff arthropathy with a large shoulder effusion (Figure 1).

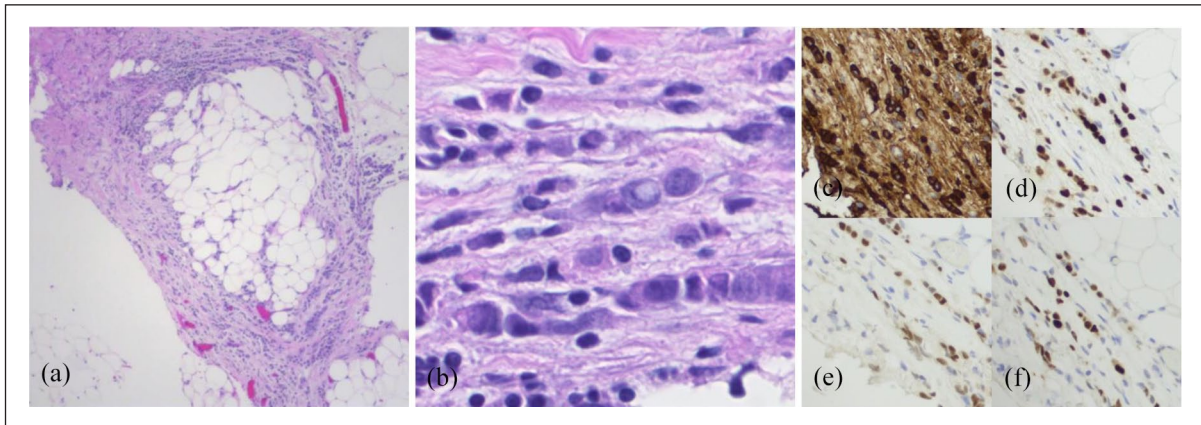
On evaluation, the patient demonstrated profound deficits of the right upper extremity. Motor function was notable for shoulder abduction limited to 10° and inability to abduct, adduct, or cross her fingers. Sensation was absent in the fourth and fifth digits and diminished with paresthesia in the index and middle fingers. Her thumb sensorimotor exam was normal.

The patient was referred to interventional radiology for an image-guided fine-needle aspiration biopsy, but the specimen obtained was non-diagnostic. Due to concern for malignancy, an open excisional biopsy of the mass was performed. Intraoperatively, the lateral and posterior cords of the brachial plexus appeared very swollen and a heavy, fibrotic

perineurium was noted. A tissue sample of the epineurium was obtained, as well as two lymph nodes, one infraclavicular and one supraclavicular. External neurolysis of the lateral and posterior cords was performed.

Histological examination of the brachial plexus mass and adjacent tissue revealed adipose tissue infiltrated by low-grade carcinoma. Immunostaining was consistent with primary breast cancer that was estrogen receptor (ER) and progesterone receptor (PR) positive, and Her2/neu negative (Figure 2). Both lymph nodes that were resected were negative for carcinoma. Full oncologic workup included a staging positron emission tomography–computed tomography (PET/CT) scan, which was negative for an FDG-avid primary mass but showed multiple foci of bony sclerosis in the thoracolumbar spine and sacrum without FDG avidity, as well as focal FDG uptake in the left L5 transverse process, indeterminate for metastasis. No breast abnormalities were noted on PET/CT scan, and no breast MRI was performed as part of her workup. Carcinoembryonic antigen (CEA) and cancer antigen 15-3 (CA15-3) levels were not elevated.

Of note, the patient had been up to date with annual screening mammograms, all of which had been negative including the most recent one performed several months after the onset of her right upper extremity symptoms, 5 months prior to her excisional biopsy. Interestingly, she had a 15-year history of oral contraceptive use, followed by a 20-year history of hormone replacement therapy after total abdominal hysterectomy and bilateral salpingo-oophorectomy. Her family history was notable for Hodgkin's lymphoma, prostate, lung, and colon cancer. Comprehensive



**Figure 2.** (a) Adipose tissue with invasive carcinoma inducing desmoplastic response. Reactive changes including patchy lymphocytic infiltrates and fat necrosis are present (H&E,  $\times 4$ ). (b) Carcinoma is present in “single file” cords. Cells are large, have increased nuclear:cytoplasmic ratio, variably prominent nucleoli, and low mitotic activity (H&E,  $\times 40$ ). (c)-(f) Neoplastic cells are strongly immunoreactive for CK7 (c), GATA3 (d), ER (E, Allred 8 of 8), and PR (F, Allred 8 of 8) ( $\times 20$ ).

genetic testing with the Invitae Common Hereditary Cancers Panel was negative for all 46 tested genes, including BRCA1, BRCA2, CHEK2, PTEN, and PALB2.

In the setting of metastatic disease to the brachial plexus without imaging findings of a primary tumor or nodal involvement, treatment focused on medical and radiation therapy rather than surgical resection. The patient was treated first with palliative radiation (37.5 Gy in 2.5 Gy daily fractions) to her right brachial plexus, followed by letrozole and palbociclib. These treatments were well tolerated, and she showed improvement in right upper extremity strength, sensation, range of motion, and pain.

After completion of radiation treatment and 2 months of letrozole and palbociclib, she was reevaluated in our hand surgery clinic. On motor exam, she demonstrated significant improvement of right shoulder abduction to  $80^\circ$ , as well as normal strength and range of motion of the elbow. She had normal wrist extension but moderate weakness with wrist flexion. Most notably, she lacked active flexion of her right thumb and digits at both the metacarpophalangeal and interphalangeal joints; however, finger extension was preserved. On sensory exam, she endorsed subjective paresthesias of the thumb and index finger with two-point discrimination of 7 mm and numbness in the remainder of the digits with two-point discrimination  $>20$  mm. Due to these significant functional limitations, she underwent a brachialis to anterior interosseous nerve transfer to restore active thumb, index, and middle finger flexion.

Overall, the patient has been doing well and has been stable on letrozole and palbociclib. From a functional standpoint approximately 1 year after surgery, she notes improved range of motion, sensation, and active movement of her right hand. She was started on zoledronic acid due to concern for bony metastases, but her most recent restaging imaging was negative for breast mass, axillary

lymphadenopathy, enlargement of the brachial plexus mass, or osseous or other distant metastasis.

## Discussion

Though unusual, there are a number of reports of breast cancer metastasizing to the brachial plexus in patients with known breast cancer;<sup>7-11</sup> however, to our knowledge, this is the first reported case of brachial plexopathy as the primary presentation of occult breast cancer.

Brachial plexopathy associated with breast cancer is usually secondary to radiation injury or metastatic spread of the tumor.<sup>12</sup> Differentiating between these etiologies is often difficult but essential, as treatment for radiation-associated plexopathy focuses on pain control and physical therapy, whereas treatment for neoplastic brachial plexopathy centers upon therapy targeting the primary cancer.<sup>13,14</sup> Neoplastic plexopathies more commonly present with pain, whereas radiation-associated plexopathies more commonly present with paresthesias and weakness.<sup>15-17</sup> The frequency of neoplastic brachial plexopathy in cancer patients is estimated to be 0.43% in one study, with the most common primary tumors being of breast or lung in origin.<sup>13</sup> MRI is the preferred imaging modality in these patients, and electrodiagnostic testing is often a helpful adjunct; these results are correlated with functional deficits on clinical exam to localize the lesion.<sup>9,18,19</sup>

Surgical exploration and excisional biopsy of the brachial plexus are infrequently performed because advances in imaging techniques have greatly improved the radiologic characterization of brachial plexus masses. In addition, completion staging imaging is usually able to identify a primary tumor in the case of metastatic disease. However, as demonstrated in this case, surgery may be critical in establishing a definitive diagnosis to guide treatment, particularly in cases

of occult cancer. In other instances, lesions that appeared suspicious on imaging ultimately proved to be benign schwannomas on histological analysis.<sup>20,21</sup>

Historically, operations such as tumor debulking and neurolysis were performed with variable rates of success, sometimes in combination with a myocutaneous flap to provide vascularized coverage for irradiated tissues.<sup>12,22–24</sup> In recent years, nerve transfer surgeries are increasingly being used in the management of brachial plexus injuries, particularly for proximal nerve injuries or compression due to the long distance needed for nerve regeneration between the affected nerve and the motor end plates in the muscle. While nerve transfers generally result in functional improvements, surgery must be performed within 6–12 months of injury before irreversible distal muscle denervation occurs.<sup>25,26</sup> Indications for nerve transfers in patients with upper extremity weakness secondary to cancer are not well defined. Our patient has a long life expectancy and significant functional deficits; surgical intervention was pursued to improve quality of life by both restoring function and reducing pain. As nerve transfers become increasingly popular in the treatment of traumatic injuries, they may also prove useful in cancer-related brachial plexopathies, as performed in our patient.<sup>14,27</sup>

## Conclusion

This case report illustrates a rare case of occult primary breast cancer presenting as a metastatic brachial plexus mass without axillary node involvement, highlighting the importance of a thorough pathologic and radiologic workup to reach the proper diagnosis and determine an appropriate treatment plan. Surgery may play a role not only in the diagnostic evaluation of complex brachial plexopathies but also in the treatment of associated upper extremity functional deficits.

## Declaration of conflicting interests

The author(s) declared no potential conflicts of interest with respect to the research, authorship, and/or publication of this article.

## Funding

The author(s) received no financial support for the research, authorship, and/or publication of this article.

## Ethical approval

Our institution does not require ethical approval for reporting individual cases or case series.

## Informed consent

Retrospective written informed consent was obtained from the patient(s) for their anonymized information to be published in this article.

## ORCID iD

Jeffrey B Friedrich  <https://orcid.org/0000-0002-5245-9708>

## References

- Vlastos G, Jean ME, Mirza AN, et al. Feasibility of breast preservation in the treatment of occult primary carcinoma presenting with axillary metastases. *Ann Surg Oncol* 2001; 8(5): 425–431.
- Fayanju OM, Jeffe DB and Margenthaler JA. Occult primary breast cancer at a comprehensive cancer center. *J Surg Res* 2013; 185(2): 684–689.
- National Comprehensive Cancer Network. Breast cancer (Version 62020). [https://www.nccn.org/professionals/physician\\_gls/pdf/breast.pdf](https://www.nccn.org/professionals/physician_gls/pdf/breast.pdf) (accessed 7 December 2020).
- Ge LP, Liu XY, Xiao Y, et al. Clinicopathological characteristics and treatment outcomes of occult breast cancer: a SEER population-based study. *Cancer Manag Res* 2018; 10: 4381–4391.
- Ahmed I, Dharmarajan K, Tiersten A, et al. A unique presentation of occult primary breast cancer with a review of the literature. *Case Rep Oncol Med* 2015; 2015: 102963.
- Patwari A and Bhatlapenumarathi V. Diffuse peritoneal carcinomatosis with ascites and disseminated bone marrow carcinomatosis as initial presentation of occult breast cancer. *Breast J* 2020; 26(11): 2233–2234.
- Mizuma A, Kijima C, Nagata E, et al. A case of suspected breast cancer metastasis to brachial plexus detected by magnetic resonance neurography. *Case Rep Oncol* 2016; 9(2): 395–399.
- Maaroufi M, Kamaoui I, Boubbou M, et al. [A rare cause of brachial plexopathy: a metastasis of breast cancer]. *Pan Afr Med J* 2014; 18: 12.
- Peppoloni G, Baglioni T, Dotti MT, et al. Brachial plexopathy due to breast cancer metastases: electrophysiological and imaging findings. *Neurol Sci* 2018; 39(8): 1503–1505.
- Eksioglu E, Aydog E, Unlu E, et al. Brachial plexopathy due to breast cancer metastases. *Neurol India* 2007; 55(2): 176–177.
- Irioka T and Mizusawa H. Recurrent breast cancer with metastatic brachial plexopathy. *Intern Med* 2010; 49(12): 1257.
- Zingale A, Ponzio G, Ciavola G, et al. Metastatic breast cancer delayed brachial plexopathy. *J Neurosurg Sci* 2002; 46(3–4): 147–149.
- Jaekle KA. Neurologic manifestations of neoplastic and radiation-induced plexopathies. *Semin Neurol* 2010; 30(3): 254–262.
- Wong M, Tang AL and Umapathi T. Partial ulnar nerve transfer to the nerve to the biceps for the treatment of brachial plexopathy in metastatic breast carcinoma: case report. *J Hand Surg Am* 2009; 34(1): 79–82.
- Ferrante MA. Brachial plexopathies: classification, causes, and consequences. *Muscle Nerve* 2004; 30(5): 547–568.
- Lederman RJ and Wilbourn AJ. Brachial plexopathy: recurrent cancer or radiation? *Neurology* 1984; 34(10): 1331–1335.
- Khadiolkar SV and Khade SS. Brachial plexopathy. *Ann Indian Acad Neurol* 2013; 16(1): 12–18.
- Qayyum A, MacVicar AD, Padhani AR, et al. Symptomatic brachial plexopathy following treatment for breast cancer: utility of MR imaging with surface-coil techniques. *Radiology* 2000; 214(3): 837–842.
- Coulier B, Van Cutsem O, Mailleux P, et al. Brachial metastatic plexopathy as the inaugural manifestation of lung cancer: multimodality imaging. *BJR Case Rep* 2016; 2(4): 20150410.

20. Fujii T, Yajima R, Morita H, et al. FDG-PET/CT of schwannomas arising in the brachial plexus mimicking lymph node metastasis: report of two cases. *World J Surg Oncol* 2014; 12: 309.
21. Fujiuchi N, Saeki T, Takeuchi H, et al. A false positive for metastatic lymph nodes in the axillary region of a breast cancer patient following mastectomy. *Breast Cancer* 2011; 18(2): 141–144.
22. LeQuang C. Postirradiation lesions of the brachial plexus. *Results of surgical treatment. Hand Clin* 1989; 5(1): 23–32.
23. Gosk J, Rutowski R, Urban M, et al. Brachial plexus injuries after radiotherapy—analysis of 6 cases. *Folia Neuropathol* 2007; 45(1): 31–35.
24. Lu L, Gong X, Liu Z, et al. Diagnosis and operative treatment of radiation-induced brachial plexopathy. *Chin J Traumatol* 2002; 5(6): 329–332.
25. Nath RK and Mackinnon SE. Nerve transfers in the upper extremity. *Hand Clin* 2000; 16(1): 131–139, ix.
26. Tung TH and Mackinnon SE. Nerve transfers: indications, techniques, and outcomes. *J Hand Surg Am* 2010; 35(2): 332–341.
27. Tung TH, Liu DZ and Mackinnon SE. Nerve transfer for elbow flexion in radiation-induced brachial plexopathy: a case report. *Hand (N Y)* 2009; 4(2): 123–128.