Case Report

Korean J Anesthesiol 2012 August 63(2): 169-172
http://dx.doi.org/10.4097/kjae.2012.63.2.169

Total intravenous anesthesia in a 10-month-old patient with congenital myotonic dystrophy undergoing endoscopic third ventriculostomy
-A case report-

Jung Hwa Joh, Ji Yeon Kim, Seung-Hye Baek, Jun-Gol Song, Yu Mi Lee, and Joung Uk Kim

Department of Anesthesiology and Pain Medicine, Asan Medical Center, University of Ulsan College of Medicine, Seoul, Korea

Myotonic dystrophy is a rare genetic disorder characterized by muscle atrophy and weakness. Surgical treatment of this condition poses various problems for the anesthesiologist. We describe the anesthetic management of a 10-month-old infant with congenital myotonic dystrophy, who was scheduled for endoscopic third ventriculostomy under general anesthesia. Anesthesia was induced with thiopental sodium, fentanyl, and vecuronium, and thereafter maintained via continuous infusion of propofol and remifentanil. The train-of-four ratio was monitored throughout the operation, and muscle relaxation was reversed with pyridostigmine and glycopyrrolate at the end of the procedure. We show that total intravenous anesthesia using propofol and remifentanil is a satisfactory anesthetic technique in very young patients with congenital myotonic dystrophy. (Korean J Anesthesiol 2012; 63: 169-172)

Key Words: Congenital myotonic dystrophy, Genetic test, Total intravenous anesthesia.

Congenital myotonic dystrophy is the neonatal form of myotonic dystrophy type 1, an autosomal-dominant RNA-mediated hereditary disorder characterized by highly variable clinical manifestations including muscle weakness and atrophy, together with a wide spectrum of extramuscular manifestations.

Anesthetic management of patients with myotonic dystrophy type 1 can be complicated by episodes of myotonia, as well as a predisposition to cardiovascular and respiratory complications. Patients with myotonic dystrophy have chronic restrictive respiratory insufficiency, and expiratory muscle weakness may lead to atelectasis while involvement of the inspiratory muscles increases the risk of alveolar hypoventilation [1]. Unpredictable sensitivity to sedatives, anesthetics, and neuromuscular blocking agents may cause recovery from anesthesia to be prolonged, as decribed in previous case reports [2,3]. Volatile anesthetics are best avoided in patients with muscular dystrophy, due to the potential of triggering malignant hyperthermia or rhabdomyolysis and possible cardiac arrest [4]. Successful

Received: May 30, 2011. Revised: 1st, July 29, 2011; 2nd, September 9, 2011. Accepted: September 19, 2011.
Corresponding author: Joung Uk Kim, M.D., Ph.D., Department of Anesthesiology and Pain Medicine, Asan Medical Center, University of Ulsan College of Medicine, 86, Asanbyeongwon-gil, Songpa-gu, Seoul 138-736, Korea. Tel: 82-2-3010-3860, Fax: 82-2-3010-6790, E-mail: jukim@amc.seoul.kr
This is an open-access article distributed under the terms of the Creative Commons Attribution Non-Commercial License (http://creativecommons.org/licenses/by-nc/3.0/), which permits unrestricted non-commercial use, distribution, and reproduction in any medium, provided the original work is properly cited.

Copyright © the Korean Society of Anesthesiologists, 2012

cases of total intravenous anesthesia using propofol for adult patients with myotonic dystrophy have been reported [5]. We describe here a case of a 10-month-old infant who underwent endoscopic third ventriculostomy under general anesthesia using propofol and remifentanil.

Case Report

A 10-month-old female infant of height 67 cm and weight 6.4 kg was scheduled for endoscopic third ventriculostomy under general anesthesia to treat progressive hydrocephalus. She was born via emergency cesarean section at 33 weeks of gestation and had a low birth weight (2,200 g). Her past medical history included treatment with surfactants because of respiratory distress syndrome evident at birth, and admission to the neonatal intensive care unit for prolonged ventilator care, off which she was weaned on day 38. Although self-respiration was achieved, a need for intermittent oxygen support persisted thereafter. Echocardiography at the time of birth revealed a small atrial septal defect and pulmonary hypertension, for which she had received nitric oxide treatment. She underwent a ligation operation on day 8 to treat patent ductus arteriosus. Neonatal brain sonography revealed bilateral intracerebral hemorrhage, which resolved almost completely on follow-up. Apart from the respiratory difficulty, the patient also showed persistent weakness of muscle tone and a significantly low activity level overall. Genetic and metabolic screening test results were all normal. Electromyography and nerve conduction velocity examinations yielded no definite electrophysical evidence of myopathy or neuropathy. She was finally diagnosed with congenital myotonic dystrophy via a chromosomal study which confirmed the presence of the DMPK mutation with > 1,000 repeats of CTG (Fig. 1). The patient's sister and mother were also tested for this gene mutation, and the results were positive.

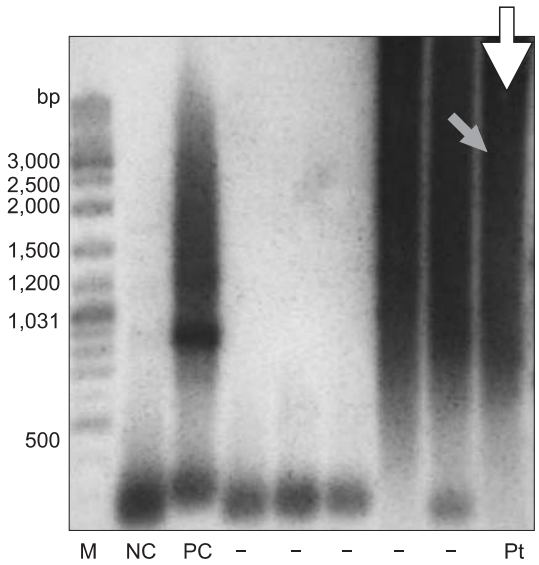

Fig. 1. Analysis of the patient's DMPK gene (large arrow) by Southern blot after amplification via polymerase chain reaction revealed approximately 1,000 copies of the (cytosine, thymine, guanine) trinucleotide expansion, to yield a DNA fragment > 3,000 base pairs in size (small arrow). DMPK: dystrophic myotonic protein kinase, M: size markers, NC: normal control, PC: positive control, Pt: patient.

The patient presented with persistent and progressive hydrocephalus caused by aqueductal stenosis evident upon magnetic resonance imaging of the brain, and was scheduled for endoscopic third ventriculostomy under general anesthesia. On physical examination, the patient had nystagmus and strabismus. Apart from hypotonia, no notable findings were made upon preoperative work-up. Her recent medication history included cough syrup prescribed for symptomatic relief of dry cough. Her head circumference at the time of admission was 49.5 cm.

The patient was not premedicated on the day of the operation. Prior to induction of anesthesia, a three-lead pediatric electrograph, a pulse oximeter, a non-invasive hemodynamometer, a nerve stimulator, and a bispectral index (BIS) sensor (BIS VISTA™ Monitoring System, Aspect Medical Systems, Newton, MA, USA) were placed and confirmed to be functioning. Preoperative vital signs included blood pressure of 86/52 mmHg, a heart rate of 130 beats/min, oxygen saturation rate of 98%, body temperature of 37.1°C, and sinus rhythm on the electrocardiogram. After adequate denitrogenation using 100% oxygen, anesthesia was induced with 30 mg thiopental sodium, 10 μg fentanyl, and 1 mg vecuronium. Mask ventilation employed 100% oxygen, tracheal intubation proceeded without any complications, and stomach decompression was achieved by careful suctioning using a catheter. The patient was mechanically ventilated in the pressure control mode, and end-tidal carbon dioxide levels was monitored and maintained at the range of 30−32 mmHg. Anesthesia was maintained with oxygen (1 L/min), medical air (1.5 L/min), and continuous infusion of 50−150 μg/kg/min of propofol and 0.1 μg/kg/min of remifentanil using an infusion pump (AS50 Auto Syringe Infusion Pump®, Baxter International Inc., Deerfield, IL, USA). The train-of-four ratio (TOF) was monitored throughout the operation to confirm that muscle relaxation was adequate and to guide the choice of additional doses of muscle relaxants. An additional 0.5 mg of vecuronium was given at the time of incision, because the patient showed signs of self-respiration. A TOF ratio of about 20% was maintained during operation. The BIS was maintained in the range of 40−60. Temperature was monitored using an esophageal stethoscope, and was 36.9°C at the end of the operation. Vital signs remained stable during the course of anesthesia. The total amount of fluid administered

was 40 ml of dextrose saline. The total duration of anesthesia was 2 hours and 45 minutes. At the end of the operation, muscle relaxation was reversed with 1.8 mg pyridostigmine and 48 μg glycopyrrolate. The patient regained self-respiration and a TOF ratio of over 90% was confirmed at this time. She was transferred to the pediatric intensive care unit while still intubated. The total amounts of propofol and remifentanil infused were 60 mg and 150 μg, respectively.

In the intensive care unit, the patient was initially ventilated in the CPAP mode with a fraction of inspired oxygen (FiO_2) of 25%. Initial oxygen saturation was 97%. Two hours later, she was extubated after suctioning of the endotracheal tube, with no sign of respiratory distress. An epinephrine nebulizer was applied. When breathing room air she showed oxygen saturation levels of 92−96%. After monitoring for appearance of complications for 24 hours, she was transferred to the general ward on postoperative day (POD) 1. Vital signs were stable throughout her hospital course. Follow-up computed tomography showed that ventricle size had been reduced, and bilateral hygroma was evident. Oral intake was satisfactory and there were no signs of vomiting or regurgitation. Postoperative computed tomography of the brain confirmed that the hydrocephalus had decreased in extent. The patient was discharged on POD 3, by which time her head circumference had decreased to 48 cm. She was scheduled for outpatient clinic follow-up 5 weeks later.

Discussion

Myotonic dystrophy type 1 is a rare autosomal-dominant genetic disorder first described by Steinert in 1909. The responsible mutation is the expansion of an unstable trinucleotide repeat (cytosine, thymine, guanine [CTG]) in the 3'- untranslated region of the dystrophic myotonic protein kinase (DMPK) gene on chromosome 19 [6]. A form of muscular dystrophy, it is the most common of the myotonic syndromes, with a prevalence of 3−5 patients per 100,000 subjects [7]. The phenotype of the disease is highly variable; it is characterized by myotonia and muscle atrophy, with multisystemic involvement featuring cataracts, cardiomyopathy, conduction abnormalities, restrictive lung disease, dysphagia, and endocrine abnormalities [7]. Four subtypes of myotonic dystrophy type 1 have been described: congenital, childhood onset, adult-onset, and late onset/asymptomatic [8]. Congenital myotonic dystrophy is the neonatal form of the disorder, and patients usually present with severe symptoms from the time of birth. Respiratory insufficiency necessitating assisted ventilation is common, and poor muscle tone and feeding difficulties are other frequently encountered problems. Prognosis depends principally on the cardiac and respiratory repercussions of the condition.

Patients with myotonic dystrophy present many potential problems in terms of management of anesthesia. Hypothermia, shivering, and mechanical or electrical stimulation may precipitate generalized myotonia which may in turn render intubation and ventilation difficult, and complicate the course of anesthesia [9]. Patients with myotonic dystrophy often display increased sensitivity to sedatives, anesthetics, and neuromuscular blocking agents, and show abnormal reactions to other drugs. Such unpredictable reactions may cause recovery from anesthesia to be prolonged, or the development of perioperative cardiovascular and respiratory complications.

Inhalation agents should be used with caution in patients with myotonic dystrophy, for several reasons. As volatile agents significantly depress respiratory and myocardial function, deep inhalation anesthesia can be hazardous in patients in whom the respiratory and cardiovascular systems are already compromised [9]. Also, volatile agents may potentially cause postoperative shivering that could trigger an episode of generalized myotonia. Last but of importance, volatile agents are known to be potent triggers of malignant hyperthermia or malignant hyperthermia-like reactions characterized by severe rhabdomyolysis and possible cardiac arrest resulting from hyperkalemia [7,8]. Although the precise relationship between myotonic dystrophy and malignant hyperthermia has yet to be defined, it is advisable to avoid drugs, such as volatile agents or succinylcholine, that may trigger malignant hyperthermia or rhabdomyolysis in myotonic dystrophy patients [8]. In this respect, we decided it was prudent not use any volatile agents or succinylcholine when treating our patient. Anesthesia was maintained with continuous infusion of propofol and remifentanil, with no adverse events.

Propofol has been advocated as a safe alternative to inhalation anesthesia and has been used successfully for both induction and maintenance of anesthesia in patients with myotonic dystrophy [9,10]. However, variations in drug sensitivity in such patients have also been reported, making dose calculations problematic [2,3]. Propofol has also been shown to provoke a myotonic episode [11] and to cause delayed recovery from anesthesia [12]. We utilized BIS monitoring to determine the minimal propofol infusion dose required to ensure adequate sedation of our patient; the BIS was stably maintained in the range 40−60 upon infusion of 50−150 μg/kg/min of propofol. Vigilant monitoring for any abnormal sign indicating generalized myotonia, and adequate postoperative observation, can be helpful to avoid and treat problems associated with a possible propofol overdose.

Use of opioids has been shown to increase the risk of postoperative complications in patients with myotonic dystrophy [13]. Newer short-acting opioids, such as remifentanil, have, however, been successfully used in such patients, and may be a safe alternative to opioids with a longer duration of action [14].

We also used remifentanil as an analgesic in our patient, and no adverse effects were observed.

Patients with myotonic dystrophy are known to vary in terms of sensitivity to neuromuscular blockers [9,15]. TOF monitoring is thus especially helpful in enabling judicious administration of these drugs. At the time of incision, self-respiration was observed, and because endoscopic surgery requires absolutely no patient movement, an additional 0.5 mg of vecuronium was given to ensure adequate muscle relaxation. A TOF ratio of approximately 20% was maintained until reversal of muscle relaxation at the end of the operation.

In our patient, we were careful to maintain normothermia to minimize the risk of triggering a myotonic episode that might have made ventilation and further airway management difficult. The ambient temperature was increased, all fluids given were warmed, and the inspired gases were warmed and humidified.

It should be noted that once mechanical ventilation is initiated in such patients, the probability that postoperative ventilatory assistance will be required is very high [15]. A period of at least 24 hours of observation in a facility capable of rapid intubation and ventilation has been recommended [15]. Our patient regained self-respiration after reversal of muscle relaxation, but the tidal volume achieved was deemed insufficient. Also, as our patient had a history of respiratory problems and had been intermittently dependent on supplemental oxygen preoperatively, we decided that it was safer to keep the endotracheal tube in place until she demonstrated adequate respiratory function. She was transferred to the pediatric intensive care unit for observation, and extubated 2 hours later without any complications. Strict surveillance continued for a further 24 hours, after which time she was sent to the general ward.

We have shown here that total intravenous anesthesia using propofol and remifentanil is a satisfactory anesthetic technique for use in an infant with myotonic dystrophy, but the importance of meticulous postoperative observation of such patients cannot be over-emphasized.

References

1. Bégin P, Mathieu J, Almirall J, Grassino A. Relationship between chronic hypercapnia and inspiratory-muscle weakness in myotonic dystrophy. Am J Respir Crit Care Med 1997; 156: 133-9.
2. Speedy H. Exaggerated physiological responses to propofol in myotonic dystrophy. Br J Anaesth 1990; 64: 110-2.
3. Morimoto Y, Mii M, Hirata T, Matayoshi H, Sakabe T. Target-controlled infusion of propofol for a patient with myotonic dystrophy. J Anesth 2005; 19: 336-8.
4. Gurnaney H, Brown A, Litman RS. Malignant hyperthermia and muscular dystrophies. Anesth Analg 2009; 109: 1043-8.
5. Lee HJ, Chon JY, Hwang SJ. Total intravenous anesthesia using bispectral index for transvaginal uterine myomectomy in a patient with myotonic dystrophy. Korean J Anesthesiol 2007; 53: 238-41.
6. Brook JD, McCurrach ME, Harley HG, Buckler AJ, Church D, Aburatani H, et al. Molecular basis of myotonic dystrophy: expansion of a trinucleotide (CTG) repeat at the 3' end of a transcript encoding a protein kinase family member. Cell 1992; 68: 799-808.
7. Russell SH, Hirsch NP. Anaesthesia and myotonia. Br J Anaesth 1994; 72: 210-6.
8. Parness J, Bandschapp O, Girard T. The myotonias and susceptibility to malignant hyperthermia. Anesth Analg 2009; 109: 1054-64.
9. Bennun M, Goldstein B, Finkelstein Y, Jedeikin R. Continuous propofol anaesthesia for patients with myotonic dystrophy. Br J Anaesth 2000; 85: 407-9.
10. White DA, Smyth DG. Continuous infusion of propofol in dystrophia myotonica. Can J Anaesth 1989; 36: 200-3.
11. Kinney MA, Harrison BA. Propofol-induced myotonia in myotonic dystrophy. Anesth Analg 1996; 83: 665-6.
12. Tzabar Y, Marshall R. Myotonic dystrophy and target-controlled propofol infusions. Br J Anaesth 1995; 74: 108-9.
13. Sinclair JL, Reed PW. Risk factors for perioperative adverse events in children with myotonic dystrophy. Paediatr Anaesth 2009; 19: 740-7.
14. Catena V, Del Monte DD, Rubini A, Guccione C, Ricagna F, Gangeri G, et al. Anesthesia and myotonic dystrophy (Steinert's syndrome). The role of total intravenous anesthesia with propofol, cisatracurium and remifentanyl. Case report. Minerva Anestesiol 2007; 73: 475-9.
15. White RJ, Bass S. Anaesthetic management of a patient with myotonic dystrophy. Paediatr Anaesth 2001; 11: 494-7.