




Since January 2020 Elsevier has created a COVID-19 resource centre with free information in English and Mandarin on the novel coronavirus COVID-19. The COVID-19 resource centre is hosted on Elsevier Connect, the company's public news and information website.

Elsevier hereby grants permission to make all its COVID-19-related research that is available on the COVID-19 resource centre - including this research content - immediately available in PubMed Central and other publicly funded repositories, such as the WHO COVID database with rights for unrestricted research re-use and analyses in any form or by any means with acknowledgement of the original source. These permissions are granted for free by Elsevier for as long as the COVID-19 resource centre remains active.



Case Study

COVID-19 in a young man with hypertension: A case study of missed opportunities in intensive progression



Kun Rao ^{a,*}, Liuzhao Xie ^b, Jianyu Wu ^c, Tianbo Weng ^a, Leile Tang ^d, Jieying Zhou ^e

^a Department of Nutrition, Guangzhou Eighth People's Hospital, Guangzhou Medical University, Guangzhou, China

^b Intensive Isolation Unit, Guangzhou Eighth People's Hospital, Guangzhou Medical University, Guangzhou, China

^c Labor Union, Guangzhou Eighth People's Hospital, Guangzhou Medical University, Guangzhou, China

^d Cardiovascular Medication Department, The Third Affiliated Hospital, Sun Yat-Sen University, Guangzhou, China

^e Intensive Care Unit, Guangzhou Institute of Respiratory Health, First Affiliated Hospital of Guangzhou Medical University, Guangzhou, China

ARTICLE INFO

Article history:

Received 9 April 2020

Revised 11 May 2020

Accepted 23 May 2020

Keywords:

COVID-19

Pneumonia

Viral

Hypertension

Enteral feeding

Heart failure

ABSTRACT

We report the case of a young patient diagnosed with coronavirus disease 2019 with a history of hypertension. The patient improved after antiviral treatment but eventually developed severe respiratory distress syndrome and cardiac insufficiency. His respiratory secretions were tested for nucleic acids and returned negative twice. Computed tomography imaging of the patient showed evidence of viral pneumonia on the 11th day of onset and continued to worsen. The patient was finally intubated and transferred to a higher-level care centre for further treatment. We were very focused on infectious disease protection throughout the treatment, however, suboptimal treatment was provided due to the switch in antihypertensive medication, lack of early nutritional support and fluid restriction management.

© 2020 Elsevier Ltd. All rights reserved.

Implications for clinical practice

- The later the onset of symptoms in COVID-19 patients, the higher the possibility of progression to severe disease.
- Airway care should prevent aerosol transmission of viruses.
- Changes in antihypertensive medications in the setting of COVID-19 should be completed only after carefully assessment.
- The progression of COVID-19 is rapid and early enteral nutritional support has positive effects on the improvement of ARDS and mechanical ventilation.
- Pulmonary circulation congestion caused by COVID-19 may increase the risk of heart failure in patients with heart disease, and fluid restriction management is important.

Coronavirus disease 2019 (COVID-19) is a respiratory infection disease that impairs the lungs caused by severe acute respiratory syndrome coronavirus 2 (SARS-CoV-2), now is a worldwide pandemic (Zhang et al., 2020a). As the disease is highly contagious and comes with a considerable morbidity and mortality, policy makers and healthcare workers are facing challenges in terms of population-based preparedness, infection prevention and control,

disease management and end-of-life care (Garcia-Alamino, 2020; Jansson et al., 2020; Lucchini et al., 2020; Pattison, 2020). COVID-19 pneumonia manifests with chest CT imaging abnormalities peripheral distribution (Shi et al., 2020), probably because the virus can not tolerate the air flow from the central bronchus similar to other infectious pneumonia to invade the bronchioles, resulting in pulmonary circulation disorder and acute respiratory distress syndrome (ARDS). Most people infected with COVID-19 have mild disease and recover, however individuals at highest risk for severe disease include people aged over 60 years or those with multiple comorbidities (WHO-China joint mission, 2020).

* Corresponding author at: Guangzhou Eighth People's Hospital, 627 Dongfeng Road, Guangzhou, Guangdong Province, China.

E-mail address: gzh8hrk@126.com (K. Rao).

In this study, we present the case of a young COVID-19 patient with a history of hypertension. Antiviral therapy was initiated. His respiratory secretions were tested for nucleic acid and returned negative twice but worsened progressively thereafter. In addition to the mechanism of disease, the necessity of prompt nursing interventions might not be neglected during patient care.

Case presentation

A 41-year-old male was admitted to an isolation ward in the infectious disease specialist hospital, Guangzhou, China, with a three-day history of intermittent dry cough and low-grade fever accompanied by chills and his oropharyngeal swabs test was positive for SARS-CoV-2 and verbally confirmed to the patient. He disclosed a visit to Wuhan 14 days ago and contact with a health care provider three days previously because of the symptoms and recent travel. Three years prior to presentation, he was diagnosed

with hypertension and managed with irbesartan. The patient had a body temperature of 37.5 °C, blood pressure of 143/100 mmHg, pulse of 106 beats/minute, respiratory rate of 20 breaths/min and an oxygen saturation of 98%. The laboratory examination revealed an increase of D-dimer and some myocardial enzymes (Table 1). Computed Tomography (CT) scan showed no abnormalities.

The patient received kaletra, oseltamivir and moxifloxacin treatment and supplemental oxygen by nasal cannula at 2 L/min. On days 2–7 of hospitalisation, apart from the intermittent low-grade fever, the patient no longer reported cough and chills. The patient reported dizziness on day 5 and started to take irbesartan orally. On day 7, the patient reported abdominal discomfort and passed loose stool. Given the gastrointestinal side effects of kaletra, bifid triple viable capsules were added for regulating the gastrointestinal tract.

On day 8 of hospitalisation, the patient reported fever (38.6 °C) and chest tightness. Although the real-time reverse transcription-

Table 1
Clinical Laboratory Results.

Measure	Reference Range	Illness Day 4, Hospital Day 1	Illness Day 6, Hospital Day 3	Illness Day 9, Hospital Day 6	Illness Day 11, Hospital Day 8	Illness Day 12, Hospital Day 9	Illness Day 13, Hospital Day 10	Illness Day 14, Hospital Day 11	Illness day 17, Hospital Day 14	Illness day 19, Hospital Day 16	Illness day 20, Hospital Day 17	Illness day 21, Hospital Day 18
White-cell count ($\times 10^9/L$)	3.5–9.5	---	---	6.23	---	6.45	---	4.80	6.88	9.55 \uparrow	22.62 \uparrow	14.62 \uparrow
Absolute neutrophil count ($\times 10^9/L$)	1.8–6.3	---	---	3.48	---	4.97	---	3.59	5.65	8.55 \uparrow	21.43 \uparrow	13.99 \uparrow
Absolute lymphocyte count ($\times 10^9/L$)	1.1–3.2	---	---	2.19	---	0.83 \downarrow	---	0.99 \downarrow	0.74 \downarrow	0.63 \downarrow	0.85 \downarrow	0.50 \downarrow
C-Reactive protein (mg/L)	<10	---	---	<10	---	10.10 \uparrow	---	15.41 \uparrow	---	---	94.59 \uparrow	110.20 \uparrow
Glucose (mmol/L)	3.9–5.8	---	---	---	8.9 \uparrow	---	---	6.6 \uparrow	4.6	5.2	5.4	9.0 \uparrow
Blood urea nitrogen (mmol/L)	3.1–9.5	4.65	---	4.20	---	---	---	---	4.59	---	3.90	---
Procalcitonin (ng/ml)	<0.05	---	---	0.0368	---	---	<0.0200	---	0.0365	---	1.35 \uparrow	---
Alanine aminotransferase (U/liter)	9–50	---	37.6	28.2	---	---	---	---	55.0 \uparrow	---	155.2 \uparrow	---
Aspartate aminotransferase (U/liter)	15–40	19.9	14.6 \downarrow	16.3	---	---	---	---	26.5	---	61.8 \uparrow	---
Plasmad d-dimer (mg/L DDU)	<1000	1440 \uparrow	---	---	---	---	---	---	760	---	---	3060 \uparrow
Lactic dehydrogenase (U/liter)	120–250	258 \uparrow	---	126	---	---	---	---	227	---	519 \uparrow	---
Creatine kinase (U/liter)	50–310	103	---	131	---	---	---	---	80	---	444 \uparrow	---
Creatine kinase isoenzyme (U/liter)	0–24	24.9 \uparrow	---	9.3	---	---	---	---	10.13	---	9.0	---
Troponin I (mg/L)	<0.03	---	---	---	0.002	---	---	---	---	---	---	---
Myohemoglobin (mg/L)	17.4–105.7	---	---	---	12.8 \downarrow	---	---	---	---	---	---	---
B-type natriuretic peptide (ng/L)	<100	---	---	---	---	---	---	---	---	24	---	---
Blood pH	7.35–7.45	---	---	---	7.397	---	---	7.425	7.436	7.425	7.373	7.381
Partial pressure of carbon dioxide (mmHg)	35–45	---	---	---	43	---	---	39.1	40.5	38.3	39.2	41.5
Oxygen partial pressure (mmHg)	83–108	---	---	---	151 \uparrow	---	---	147 \uparrow	109 \uparrow	98.5	59.5 \downarrow	143 \uparrow
Oxygen saturation (%)	92–98	---	---	---	99.6 \uparrow	---	---	99.4 \uparrow	98.6 \uparrow	98.1 \uparrow	90.8 \downarrow	99.2 \uparrow
Lactic acid (mmol/L)	0.5–1.6	---	---	---	1.3	---	---	1.6	1.5	1.9 \uparrow	2.6 \uparrow	1.9 \uparrow
Potassium (mmol/L)	3.4–4.5	---	---	---	2.8 \downarrow	---	---	3.3 \downarrow	3.7	---	3.2 \downarrow	4.0
Calcium (mmol/L)	1.15–1.29	---	---	---	1.13 \downarrow	---	---	1.11 \downarrow	1.15	---	1.08 \downarrow	1.09 \downarrow
N gene of SARS-CoV-2 nucleic acid	(-)	---	---	---	(-)	---	(+)	---	(-)	(+)	(+)	---
ORF 1a/b gene of SARS-CoV-2 nucleic acid	(-)	---	---	---	(-)	---	(+)	---	(-)	(+)	(+)	---

\downarrow The value was below normal.

\uparrow The value was above normal.

polymerase chain reaction (rRT-PCR) was negative on day 8, the second CT scan showed ground-glass opacification in both lungs. Laboratory results from day 8–14 are shown in [Table 1](#). The second rRT-PCR on day 10 was positive, and the third CT scan on day 12 showed higher opacification range than before. The treatment included antipyretic therapy, teicoplanin, and 3-day course of methylprednisolone; the calcium antagonist levamlodipine was given instead of the angiotensin receptor blocker irbesartan because the angiotensin converting enzyme 2 (ACE2) has been shown to be a co-receptor for viral entry for SARS-CoV-2 ([Zhou et al., 2020](#)). The patient had diarrhoea for two days (9th and 13th days). As he had ongoing fevers, eight respiratory pathogens were tested and blood cultures were obtained, but the results were negative. On day 14, negative SARS-CoV-2 RNA reappeared. On day 15, the patient's body temperature was 40 °C with mild cough, expectoration, chills, and muscle soreness. For symptom management, oxygen level was increased at 3 L/min.

Disease progression

On day 16, the patient was lethargic and reported palpitation of sudden onset, paroxysmal cough accompanied with sputum and loss of appetite. His body temperature was 39.7 °C, pulse 130 beats/min, the respiratory rate 31 breaths/minute and the oxygen saturation 99% while breathing oxygen at 6 L/minute. The fourth CT performed showed significant exacerbation of viral pneumonia ([Fig. 1](#)), and the rRT-PCR turned positive for the second time. The patient was notified of severity and admitted to the intensive care unit (ICU). In the ICU, sulperazone were administered intravenously, ambroxol and acetylcysteine were used as expectorants by aerosol inhalation.

The next afternoon, the patient had cyanosis and a cough with bloody sputum. The respiratory rate was 36 breaths/minute and oxygen saturation was 95% with high-flow oxygen. The patient was started on noninvasive positive pressure ventilation [positive end-expiratory pressure (PEEP) was setting 5 cm H₂O; fraction of inspiration (FiO₂) was 70%] under morphine sedation. The chief physician changed medication from sulperazone to meropenem. The laboratory results (after 1 hour) showed ongoing leukocytosis, lymphopenia and an increase in neutrophils, liver enzymes, myocardial enzymes, and a decrease in oxygen partial pressure for the first time ([Table 1](#)). At this point, the ratio of the partial pressure of arterial oxygen (PaO₂) to FiO₂ (PaO₂:FiO₂) < 100 mmHg indicated that severe ARDS had occurred ([World health organization, 2020](#)). Chest radiograph showed enlargement of cardiac shadow ([Fig. 2](#)). As the condition deteriorated, the patient underwent endotracheal intubation via electronic bronchoscope adaptive pressure mode (parameters: respiratory frequency of 20

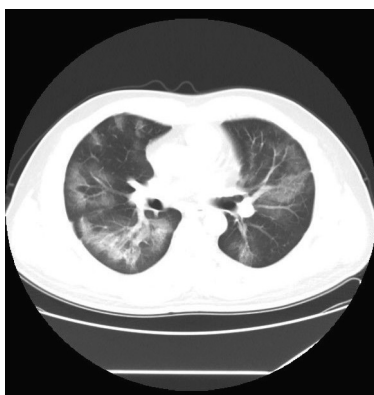

Fig. 1. Chest CT, February 13,2020 (Illness Day 19, Hospital Day 16). Multiple ground-glass opacification in both lungs, more than 75% of the lungs were involved.

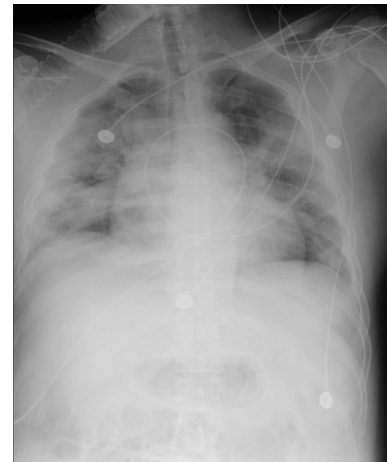

Fig. 2. Posteroanterior Chest Radiograph, February 14,2020 (Illness Day 20, Hospital Day 17). The shadow of the heart was enlarged and full.

times per minute; tidal volume of 420 ml; PEEP of 10 cmH₂O; FiO₂ of 85%). After intubation, the patient's ventilation pattern was smooth, with no obvious patient-ventilator dyssynchrony.

The next day, the patient's vital signs were stable under ventilator-assisted breathing. Given the enhanced inflammatory response, progressive severe ARDS, and the possibility of cardiac insufficiency, the patient was transferred to another high-level ICU for further treatment. After 13 days of follow-up, the patient was weaned from mechanical ventilation. After 17 days of follow-up, the patient tested negative for SARS-CoV-2 and did not become positive since then.

Discussion

Unjust positive speculation

In this patient, the clinical symptoms aggravated only on the eleventh day and CT showed novel coronapneumonia. A recent study found that a majority of patients with COVID-19 are hospitalised after a period of improvement and then deteriorated ([Liu et al., 2020](#)). Several studies reported that patients with negative nucleic acid tests after treatment became positive later ([Zhang et al., 2020b](#)), this is consistent with this patient who turned positive after two negative nucleic acid tests. Possibly as the body's immunity is low, the virus has not been removed and the cells are still in a toxic state, but the amount of detoxification in the body has not yet reached the amount of virus required for a positive nucleic acid test. Therefore, combined with the clinical symptoms, radiography can estimate disease progression more accurately than nucleic acid detection only.

Special protection in oxygen therapy and mechanical ventilation

In this case, the patient wore a surgical mask while inhaling oxygen and the nurse attached the tube with a sling to avoid displacement of the nasal cannula. As high-flow oxygen therapy could not improve the patient's symptoms, he received non-invasive ventilation in a closed loop with virus filtering function. Finally, the anaesthesiologist intubated the patient with the rapid induction of anesthesia using sedatives combined with muscle relaxants to eliminate the patient's cough. These were measures to reduce the spread of the virus through aerosols. However, expectorant treatment was nebulised, and for patients with COVID-19 without chronic obstructive pulmonary disease or asthma, unnecessary

aerosol generation should be avoided (Respiratory care committee of Chinese thoracic society, 2020).

Deprivation of early enteral feeding

The patient had diarrhoea, electrolyte imbalance and loss of appetite; however, enteral feeding was not initiated before or after mechanical ventilation. Nutritional support is recognised as a major support during critical illness (Rice et al., 2012). The incidence of malnutrition in ARDS patients is very high due to severe stress, hypercatabolism and significantly enhanced work of respiratory muscles. Energy demand might increase by 30% to 50%, and the incidence of malnutrition can be as high as 70% (Wheeler and Bernard, 2007). Numerous studies indicated that early enteral feeding initiated within 12–24 hours result in a significant lowering of the level of proinflammatory cytokines, stabilising glycaemia, earlier restoration of gastrointestinal function, improving pulmonary oxygenation and a reduction in the length of mechanical ventilation (Hurt et al., 2012). Total parenteral nutrition is to be avoided when possible, in order to reduce the risk of complications associated with the use of central venous catheters. (Conoscenti and Blot, 2020; Huang et al., 2020; Khoshbaten et al., 2013).

Loss of fluid restriction

However, due to the patient's hypertension and to avoid nosocomial cross-infection, cardiac function was not evaluated by doppler ultrasound, diuretics were not considered to limit fluid overload. Pulmonary circulation congestion caused by COVID-19 pneumonia and the use of meropenem for the prevention of ventilator-associated pneumonia may increase the risk of cardiac insufficiency (Qin et al., 2020). ICU nurses should carefully monitor the rate of intravenous infusion, but no reliable fluid balance was reported. While the latter is standard practice, the failure of complying with this recommendation can be interpreted in the light of the high workload during the COVID-19 outbreak.

Drug effect

In terms of medication management, there is concern that the use of angiotensin receptor blockers will increase expression of ACE2 and increase patient susceptibility to viral host cell entry and propagation. But the switch of antihypertensive medication may lead to the chaos of ACE2 receptor pathway, resulting in the imbalance of renin–angiotensin system and the aggravation of pulmonary inflammation (Patel and Verma, 2020). Antihypertensive medication changes between classes additionally require frequent dose adjustment and management of adverse effects and increases the risk of medical errors. The council on hypertension of the European society of cardiology recommended continuation of treatment with usual antihypertensive therapy because there is no clinical or scientific evidence to suggest that treatment with angiotensin receptor blockers should be discontinued in case of COVID-19 (European Society of Cardiology, 2020).

Limitations

In addition to a part of the epidemic prevention and control factors affected by lack of testing, the blood test for inflammatory mediators was not perfect. No causal relationships can be drawn from this case study because alternative explanations for worsening symptoms cannot be ruled out. The present case study is illustrative for the need for clinical guidelines optimising the processes of care.

Conclusion

This is a case with delayed symptoms who eventually developed severe ARDS. CT images and haemolytic lymphocyte counts are more valuable than rRT-PCR results for the progression of COVID-19. For patients with hypertension, the replacement of anti-hypertensive drugs should be more carefully considered. Failure to administer nutritional support and fluid restriction can weaken the immune system and increase the risk of cardiac insufficiency. For this kind of respiratory tract infectious disease, unnecessary examination should be avoided as far as possible.

Funding source

None.

Acknowledgements

We are deeply grateful to the medical care team led by Dr. Xilong Deng of the Intensive Isolation Unit, Guangzhou Eighth People's Hospital. We would like to thank Ms. Jinger Chen for providing language help with this article.

Declaration of Competing Interest

The authors declare that they have no known competing financial interests or personal relationships that could have appeared to influence the work reported in this paper.

Ethical approval

Informed consent was obtained from the patient for publication of this case study and accompanying image.

References

- European Society of Cardiology, 2020. Position statement of the ESC council on hypertension on ACE-inhibitors and angiotensin receptor blockers. [https://www.escardio.org/Councils/Council-on-Hypertension-\(CHT\)/News/position-statement-of-the-esc-council-on-hypertension-on-ace-inhibitors-and-ang](https://www.escardio.org/Councils/Council-on-Hypertension-(CHT)/News/position-statement-of-the-esc-council-on-hypertension-on-ace-inhibitors-and-ang). (accessed 20.04.24).
- Conoscenti, E., Blot, S., 2020. A necessary evil: Central venous catheters. *Intensive Crit. Care Nurs.* 57, 102810. <http://doi:10.1016/j.iccn.2020.102810>.
- Garcia-Alamino, J.M., 2020. Haman biases and the SARS-CoV-2 pandemic. *Intensive Crit. Care Nurs.* 9, 102861. <http://doi:10.1016/j.iccn.2020.102861>.
- Huang, Z., Chen, H., Liu, Z., 2020. The 100 top-cited systematic reviews/metaanalyses/central venous catheter research. A PRISMA-compliant systematic literature review and bibliometric analysis. *Intensive Crit. Care Nurs.* 57 (102803).
- Hurt, R.T., Frazier, T.H., McClave, S.A., Crittenden, N.E., Kulisek, C., Saad, M., et al., 2012. Stress prophylaxis in intensive care unit patients and the role of enteral nutrition. *JPN J. Parenter. Enteral Nutr.* 36 (6), 721–723. <http://doi:10.1177/0148607112436978>.
- Jansson, M., Liao, X., Rello, J., 2020. Strengthening ICU health security for coronavirus epidemic. *Intensive Crit. Care Nurs.* 57, 102812. <https://doi:10.1016/j.iccn.2020.102812>.
- Khoshbaten, M., Ghaffarifar, S., Jabbar Imani, A., Shahnaazi, T., 2013. Effects of early oral feeding on relapse and symptoms of upper gastrointestinal bleeding in peptic ulcer disease. *Dig. Endosc.* 25 (2), 125–129. <http://doi:10.1111/j.1443-1661.2012.01347.x>.
- Liu, W., Tao, Z.W., Lei, W., Ming-Li, Y., Kui, L., Ling, Z., et al., 2020. Analysis of factors associated with disease outcomes in hospitalized patients with 2019 novel coronavirus disease. *Chin Med J Engl.* <http://doi:10.1097/CM9.0000000000000775>.
- Lucchini, A., Giani, M., Isgrò, S., Rona, R., Foti, G., 2020. The “helmet bundle” in COVID-19 patients undergoing non invasive ventilation. *Intensive Crit. Care Nurs.* 2, 102859. <http://doi:10.1016/j.iccn.2020.102859>.
- Pattison, N., 2020. End-of-life decisions and care in the midst of global coronavirus (COVID-19) pandemic. *Intensive Crit. Care Nurs.* 2, 102862. <http://doi:10.1016/j.iccn.2020.102862>.
- Patel, A.B., Verma, A., 2020. COVID-19 and angiotensin-converting enzyme inhibitors and angiotensin receptor blockers: what is the evidence?. *JAMA.* <https://doi.org/10.1001/jama.2020.4812>.

- Qin, X., Tsoi, M.F., Zhao, X., Zhang, L., Qi, Z., Cheung, B.M.Y., 2020. Vancomycin-associated acute kidney injury in Hong Kong in 2012–2016. *BMC Nephrol.* 21 (1), 41 <http://doi:10.1186/s12882-020-1704-4>.
- Respiratory care committee of Chinese thoracic society, 2020. Expert consensus on preventing nosocomial transmission during respiratory care for critically ill patients infected by 2019 novel coronavirus pneumonia. *Zhonghua Jie He He Hu Xi Za Zhi* 17(0): E020.<http://doi:10.3760/cma.j.issn.1001-0939.2020.0020>.
- Rice, T.W., Wheeler, A.P., Thompson, B.T., Steingrub, J., Hite, R.D., Moss, M., et al., 2012. Initial trophic vs full enteral feeding in patients with acute lung injury: the EDEN randomized trial. *JAMA* 307 (8), 795–803. <http://doi:10.1001/jama.2012.107>.
- Shi, H., Han, X., Jiang, N., Cao, Y., Alwalid, O., Gu, J., et al., 2020. Radiological findings from 81 patients with COVID-19 pneumonia in Wuhan, China: a descriptive study. *Lancet Infect. Dis.* 20 (4), 425–434 [http://doi:10.1016/S1473-3099\(20\)30086-4](http://doi:10.1016/S1473-3099(20)30086-4).
- Wheeler, A.P., Bernard, G.R., 2007. Acute lung injury and the acute respiratory distress syndrome: a clinical review. *Lancet* 369 (9572), 1553–1564 [http://doi:10.1016/S0140-6736\(07\)60604-7](http://doi:10.1016/S0140-6736(07)60604-7).
- WHO-China joint mission, 2020. Report of the WHO-China joint mission on coronavirus disease 2019 (COVID-19). <https://www.who.int/docs/default-source/coronaviruse/who-china-joint-mission-on-covid-19-final-report.pdf> (accessed 20.04.06).
- World health organization, 2020. Clinical management of severe acute respiratory infection (SARI) when COVID-19 disease is suspected: interim guidance. [https://www.who.int/publications-detail/clinical-management-of-severe-acute-respiratory-infection-when-novel-coronavirus-\(ncov\)-infection-is-suspected](https://www.who.int/publications-detail/clinical-management-of-severe-acute-respiratory-infection-when-novel-coronavirus-(ncov)-infection-is-suspected) (accessed 20.05.10).
- Zhang, J.J., Dong, X., Cao, Y.Y., Yuan, Y.D., Yang, Y.B., Yan, Y.Q., et al., 2020a. Clinical characteristics of 140 patients infected with SARS-CoV-2 in Wuhan, China. *Allergy*. <http://doi:10.1111/all.14238>.
- Zhang, Q., Wang, Y., Qi, C., Shen, L., Li, J., 2020b. Clinical trial analysis of 2019-nCoV therapy registered in China. *J. Med. Virol.* <http://doi:10.1002/jmv.25733>.
- Zhou, P., Yang, X.L., Wang, X.G., Hu, B., Zhang, L., Zhang, W., et al., 2020. A pneumonia outbreak associated with a new coronavirus of probable bat origin. *Nature* 579 (7798), 270–273 <http://doi:10.1038/s41586-020-2012-7>.