

## Case Report

# A Rare Anatomical Finding: Bilateral Accessory Mental Foramen

Zülfikar Karabiyik<sup>1</sup> and Mustafa Kıranatlı<sup>2</sup>

<sup>1</sup>Kütahya Health Science University, Dentistry Faculty, Department of Oral and Maxillofacial Surgery, Turkey

<sup>2</sup>Kütahya Health Science University, Dentistry Faculty, Department of Oral and Maxillofacial Radiology, Turkey

Correspondence should be addressed to Zülfikar Karabiyik; [zulfikarkarabiyik60@gmail.com](mailto:zulfikarkarabiyik60@gmail.com)

Received 11 July 2021; Revised 31 July 2021; Accepted 13 August 2021; Published 23 August 2021

Academic Editor: Darko Macan

Copyright © 2021 Zülfikar Karabiyik and Mustafa Kıranatlı. This is an open access article distributed under the Creative Commons Attribution License, which permits unrestricted use, distribution, and reproduction in any medium, provided the original work is properly cited.

*Aim.* Accessory mental foramen (AMF) is a not common anatomical variation. During the surgical procedures involving the mandible such as implant surgery, periapical surgery, jaw surgeries, and periapical surgery and enucleation of pathologies at the mental region, obvious attention should be given to prevent postoperative sequelae. *Case Report.* Orthopantomograph (OPG) is routinely taken to visualize the maxillofacial region at a dental clinic. OPG shows exactly upper and lower jaw and teeth but superficially reveals some pathology or anatomic variation. It misses sometimes an anatomic landmark such as AMF. As the surgery is planned to a maxillofacial region, a detailed knowledge should be known before going into surgery to not interfere with anatomic landmarks. A 52-year-old male patient was referred to Kütahya Health Science University Dental Hospital, Turkey, to rehabilitate his bilateral partial edentulous lower jaw region. Implant surgery was planned in our patient. OPG was taken to evaluate the maxillofacial region but was unremarkable. Before the implant surgery, CBCT was obtained from our patient. CBCT and a three-dimensional reconstructed model of the male patient showed bilateral accessory mental foramen (AMF). *Conclusion.* Accessory mental foramen (AMF) carries additional innervation to the chin, mandibular anterior gingiva, and mental region. Reflection and protection of the AMF during the surgery can prevent hemorrhage and neurosensory disturbance at the mental region and can improve quality of life for the patient. CBCT has higher precision but also a higher price and radiation dose. Although anatomical variations are uncommon, they can be found on digital panoramic radiographs but in limited percentage.

## 1. Introduction

The path and shape of the mandibular canal and mental foramen are significant milestones in surgical operations performed on the mandible such as implant placement, periapical surgeries, enucleations of pathologies, surgical correction of jaw deformities, and extraction of impacted teeth [1]. The mental foramen (MF) is placed on the anterolateral side of the mandible [2, 3]. MF is generally located in an inferior position which is between root apices of the bicuspids. It usually opens a superior-posterior position and carries neurovascular bundle named as the mental nerve. The mental nerve branches while it was exiting from the MF. The mental nerve innervates the skin of the mental and lower lip region. A buccal mucous membrane and buccal gingiva from the

lower midline to the second premolar region is also innervated by the mental nerve [4].

Any foramen in addition to MF is regarded as accessory mental foramen (AMF) [2, 5]. Accessory foramen showing a connection with the mandibular canal is defined as accessory mental foramen, and accessory foramen revealing no connection with the mandibular canal is defined as nutrient foramen [6]. AMF is generally smaller than MF [7]. It can be found in the apical region of the first molar and in the posterior or superior region of the mental foramen as in our case. Detailed knowledge regarding the possible location, incidence, shape, and size of the AMF helps clinician to perform local anesthesia correctly and adequately. Identification of AMF on radiograph prevents misdiagnosis of bone lesions [8]. Identification and protection of AMF result in operation

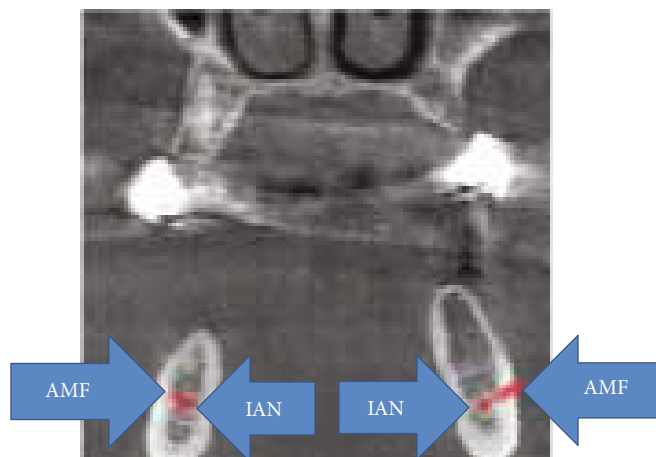


FIGURE 1: Right and left AMF at coronal CBCT.

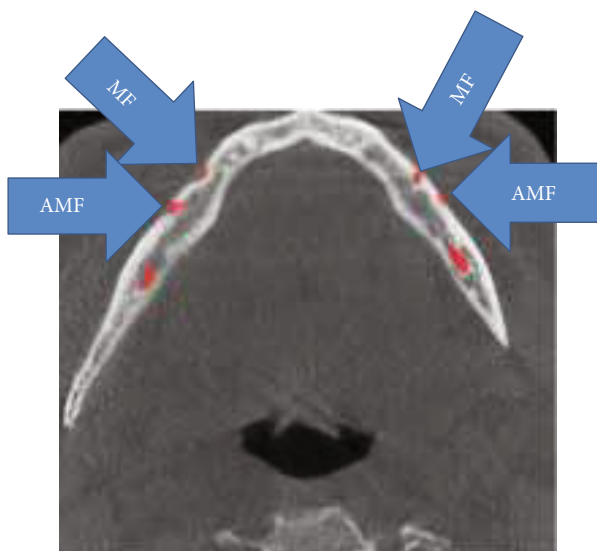


FIGURE 2: Right and left AMF at axial CBCT.

involving the mental region with minimal nerve injury and morbidity [9].

The present paper reports a case of AMF using CBCT.

## 2. A Case Report

A 52-year-old male patient came to the Department of Oral and Maxillofacial Surgery, Kütahya Health Science University Dental Hospital, Turkey, for the implant rehabilitation. His medical history was unremarkable. On the clinical examination, he was partially edentulous. On the panoramic radiograph, MF was identified. For the detailed examination, CBCT was obtained from the patient. Bilateral small round-shaped radiolucency distal to MF was seen at the axial CBCT section and a three-dimensional reconstructed model. These small foramina were connected to the inferior alveolar nerve canal (IAN) (Figure 1). It was referred to as AMF.




FIGURE 3: Right AMF at reconstructed CBCT.

## 3. Discussion

MF is generally only one exit on each side of the lower jaw. MF is not developed until the 12th gestational week. Balcioğlu and Kocaelli asserted that splitting of the mental nerve from the inferior alveolar nerve before the exit to mental foramen may be a reason for the formation of AMF [2]. Double mental foramina are reported in literature [10]. AMF can change from a small indistinct bar to separate foramina [11]. Sawyer et al. added that the number of AMF can change from one to three foramina [4]. In the present case, two distinct foramina distal to MF were seen at axial CBCT and 3D reconstructed model bilaterally (Figures 2–4). Prevalence of AMF ranges from 1.4 to 12% [11–14]. Studies showed no gender differences according to the incidence of AMF [2]. Paraskevas et al. studied cadavers and found that the average diameter of AMF was 1 mm [8]. In our case, the diameter of the AMF was found to be 1.65 mm at the right side and 1.52 mm at the left site (Figures 5 and 6). AMF incidence can differ in ethnic groups [15]. Its incidence does not differ in right and left sides. Paraskevas et al. found that the mean distance from MF to AMF is 5.24 mm [8]. In our case, the distance from the MF to AMF was found to be 6.28 mm at the right side and 3.97 mm at the left side. MF can be observed by periapical radiography and OPG, but it can be detected with CBCT

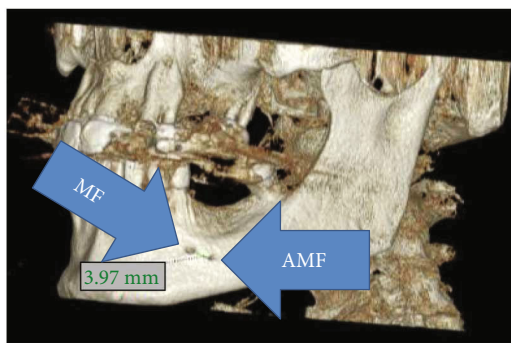


FIGURE 4: Left AMF at reconstructed CBCT.

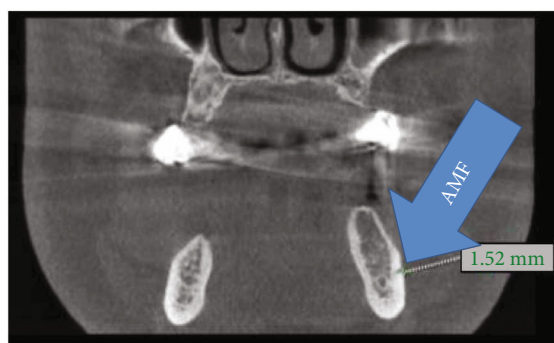


FIGURE 5: Left AMF at coronal CBCT.

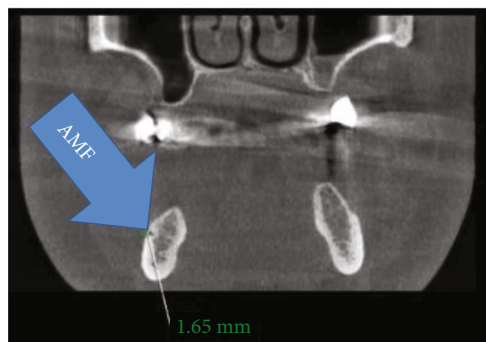


FIGURE 6: Right AMF at coronal CBCT.

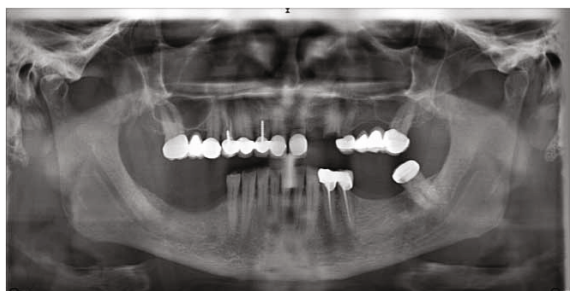


FIGURE 7: Patient's orthopantomograph.

without exception [2]. AMF was detected on CBCT not on orthopantomograph in our case (Figure 7).

While it can be difficult to differentiate MF from AMF on radiographs, the presence of connection between the mandibular canal and such foramina supports the case of AMF.

#### 4. Conclusion

Neurosensory sequelae during the surgery involving the mental region are not scarce. In order to avoid neurovascular complications during the surgery, a possibility of AMF should be kept in mind. Knowledge about anatomic variations can prevent the complications and increase the quality of life after the surgery. CBCT has higher precision but also a higher price and radiation dose. Although anatomical variations (AMF) are uncommon, they can be found on digital panoramic radiographs but in limited percentage. AMF is detected on CBCT without exception.

#### Conflicts of Interest

The authors declare that they have no conflicts of interest.

#### References

- [1] M. Naitoh, K. Yoshida, K. Nakahara, K. Gotoh, and E. Arijii, "Demonstration of the accessory mental foramen using rotational panoramic radiography compared with cone-beam computed tomography," *Clinical Oral Implant Research*, vol. 22, no. 12, pp. 1415–1419, 2011.
- [2] H. A. Balcioglu and H. Kocaelli, "Accessory mental foramen," *North American Journal of Medical Sciences*, vol. 1, no. 6, pp. 314–315, 2009.
- [3] R. Singh, "Evaluation of position, shape, size and incidence of mental foramen and accessory mental foramen in Indian adult human skulls," *Anatomy*, vol. 5, pp. 23–29, 2011.
- [4] D. R. Sawyer, L. M. Kiely, and A. M. Pyle, "The frequency of accessory mental foramina in four ethnic groups," *Archives of Oral Biology*, vol. 43, no. 5, pp. 417–420, 1998.
- [5] S. Gupta and S. J. Soni, "Study of anatomical variations and incidence of mental foramen and accessory mental foramen in dry human mandibles," *National Journal Of Medical Research*, vol. 2, pp. 28–30, 2012.
- [6] Y. Sisman, H. Sahman, E. A. Sekerci, T. T. Tokmak, Y. Aksu, and E. Mavili, "Detection and characterization of the mandibular accessory buccal foramen using CT," *Dentomaxillofacial Radiology*, vol. 41, no. 7, pp. 558–563, 2012.
- [7] N. S. T. Imada, R. S. P. M. L. Fernandes, B. S. Centurion, C. de Oliveira-Santos, H. M. Honório, and I. R. F. Rubira-Bullen, "Accessory mental foramina: prevalence, position and diameter assessed by cone-beam computed tomography and digital panoramic radiographs," *Clinical Oral Implants Research*, vol. 25, no. 2, pp. e94–e99, 2014.
- [8] G. Paraskevas, A. Mavrodi, and K. Natsis, "Accessory mental foramen: an anatomical study on dry mandibles and review of the literature," *Mund Keifer Gesichtschirurgie*, vol. 19, no. 2, pp. 177–181, 2015.
- [9] A. Voljevica, E. Talovic, and A. Hasanović, "Morphological and morphometric analysis of the shape, position, number

- and size of mental foramen on human mandibles," *Acta Medica Academica*, vol. 44, no. 1, pp. 31–38, 2015.
- [10] N. J. Serman, "The mandibular incisive foramen," *Journal of Anatomy*, vol. 167, pp. 195–198, 1989.
- [11] J. Kieser, D. Kuzmanovic, A. Payne, J. Dennison, and P. Herbison, "Patterns of emergence of the human mental nerve," *Archives of Oral Biology*, vol. 47, no. 10, pp. 743–747, 2002.
- [12] C. Igarashi, K. Kobayashi, A. Yamamoto, Y. Morita, and M. Tanaka, "Double mental foramina of the mandible on computed tomography images: a case report," *Oral Radiology*, vol. 20, no. 2, pp. 68–71, 2004.
- [13] L. B. Çağırankaya and H. Kansu, "An accessory mental foramen: a case report," *The Journal of Contemporary Dental Practice*, vol. 9, no. 1, pp. 98–104, 2008.
- [14] H. Toh, J. Kodama, M. Yanagisako, and T. Ohmori, "Anatomical study of the Accessory mental foramen and the distribution of Its nerve," *Okajimas Folia Anatomica Japonica*, vol. 69, no. 2-3, pp. 85–88, 1992.
- [15] N. S. Mamatha, N. S. Kedarnath, M. Singh, and G. Patel, "Accessory mental nerve: a case report," *Journal of Clinical and Diagnostic Research*, vol. 7, pp. 2078–2079, 2013.