

Contents lists available at [ScienceDirect](https://www.sciencedirect.com)

International Journal of Surgery Case Reports

journal homepage: www.casereports.com

A case of retroperitoneal desmoid-type fibromatosis that involved the unilateral ureter after gynaecologic surgery

Hitomi Ono^{a,*}, Kensuke Hori^a, Lena Tashima^a, Tomohiko Tsuruta^a, Shin-ichi Nakatsuka^{b,c}, Kimihiko Ito^a^a Department of Obstetrics and Gynecology, Kansai Rosai Hospital, Japan^b Department of Pathology, Kansai Rosai Hospital, Japan^c Department of Diagnostic Pathology and Cytology, Osaka International Cancer Institute, Japan

ARTICLE INFO

Article history:

Received 19 February 2018

Received in revised form 21 March 2018

Accepted 27 March 2018

Available online 29 March 2018

Keywords:

Case report

Desmoid-type fibromatosis

Hydronephrosis

Retroperitoneal

Ureteral invasion

Gynaecologic surgery

ABSTRACT

INTRODUCTION: Desmoid-type fibromatosis represents a rare, benign, soft tissue tumour that is locally invasive with high recurrence potential.**PRESENTATION OF CASE:** We encountered a case of retroperitoneal desmoid-type fibromatosis in a 45-year-old woman who presented with chief complaints of stomach ache and vomiting. She underwent total abdominal hysterectomy and left salpingo-oophorectomy due to uterine myoma and a paraovarian cyst at 42 years of age. Abdominal computed tomography showed a 5-cm left retroperitoneal tumour and severe hydronephrosis of the left kidney. Multiple imaging studies failed to provide a definitive diagnosis. Therefore, we performed tumour resection, right salpingo-oophorectomy, ureterectomy, and ureterocystostomy. The tumour surrounded the left ureter and adhered to the left internal/external iliac artery, rectum, bladder, and the edge of the vagina. Histopathologic examination yielded a diagnosis of retroperitoneal desmoid-type fibromatosis. One month after the operation, transvaginal sonography showed a 2-cm mass in the pelvis. We suspected tumour recurrence and commenced pharmacotherapy with tranilast (300 mg/day, three times per day). Four months after the operation, the mass disappeared. **DISCUSSION:** There are minimal reports of postoperative intra-abdominal desmoid-type fibromatosis and preoperative diagnosis is difficult. To the best of our knowledge, there are no reported cases of desmoid-type fibromatosis that involved the ureter with severe hydronephrosis following a gynaecologic operation.**CONCLUSION:** We experienced a case of retroperitoneal desmoid-type fibromatosis that involved a unilateral ureter after gynaecologic surgery.© 2018 The Authors. Published by Elsevier Ltd on behalf of IJS Publishing Group Ltd. This is an open access article under the CC BY-NC-ND license (<http://creativecommons.org/licenses/by-nc-nd/4.0/>).

1. Introduction

Desmoid-type fibromatosis is a rare mesenchymal neoplasm that arises from the proliferation of fibroblasts or myofibroblast-like tumour cells in histology. Although desmoid-type fibromatosis is histologically benign, it is locally invasive and frequently recurs; however, it does not metastasize [1,2]. The incidence of desmoid-type fibromatosis is 2.4–4.3 per million per year, and 80% of the patients are female [3]. Moreover, it can occur at any age, but the 20s and 30s are most frequent among patients [4].

This fibrous tumour may arise throughout the body, which is clinicopathologically classified into three types: extra-abdominal (60%), abdominal wall (25%), and intra-abdominal (8–15%) [1]. The

number of reports regarding retroperitoneal desmoid-type fibromatosis is small. Patients with intra-abdominal tumour remain asymptomatic until growth of the tumour leads to intestinal, vascular, ureteric, and neuronal manifestations [5]. The most common complaint is pain (pelvic, abdominal, leg, or vulval) [6]. A previous report stated that desmoid-type fibromatosis was associated with trauma, surgical wounds, and familial adenomatous polyposis in Gardner syndrome [7]. Some occurrences of surgery-related desmoid-type fibromatosis were reported, such as after excision of gastric gastrointestinal stromal tumour, lobectomy for lung cancer, and hysterectomy for fibroid uterus. Herein, we report a case of desmoid-type fibromatosis that occurred in the retroperitoneal space and invaded the ureter after gynaecologic operation. This work has been reported in line with the SCARE criteria [8].

* Corresponding author at: Department of Obstetrics and Gynecology, Kansai Rosai Hospital, 3-1-69 Inabaso, Amagasaki 660-8511, Japan.
E-mail address: hitomi-on@outlook.jp (H. Ono).

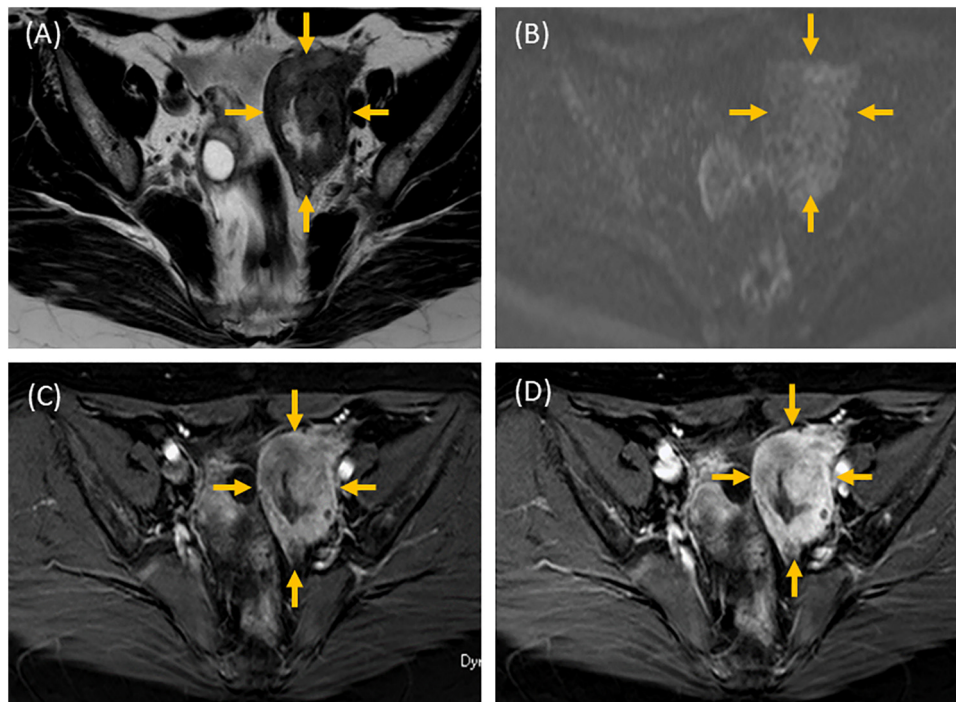


Fig. 1. Abdominal magnetic resonance imaging.

A: T2-weighted image; B: diffusion-weighted image; C: early phase image; D: late phase image.

Abdominal magnetic resonance imaging showed a left retroperitoneal tumour, which was isointense compared to skeletal muscle on T1- and T2-weighted imaging and was slightly hyperintense on diffusion-weighted imaging.

The tumour showed contrast enhancement, which was slight in the early phase and strong in the late phase.

2. Presentation of case

A 45-year-old Japanese woman visited a hospital with complaints of stomach ache and vomiting. She underwent caesarean section at age 25 years, and total abdominal hysterectomy and left salpingo-oophorectomy due to uterine myoma and a paroophoric cyst at age 42 years.

Abdominal computed tomography showed a 5-cm left retroperitoneal tumour and severe hydronephrosis of the left kidney. She was then transported to our hospital for further examination and treatment. Blood examination showed mild renal dysfunction (blood urea nitrogen, 22.7 mg/dL; creatinine, 0.98 mg/dL) and elevated tumour marker levels (carbohydrate antigen [CA] 19-9, 77.1 IU/mL; CA125, 92.9 IU/mL). Abdominal magnetic resonance imaging showed a left retroperitoneal tumour, which was isointense compared to skeletal muscle on T1- and T2-weighted imaging and was slightly hyperintense on diffusion-weighted imaging (Fig. 1). The tumour showed contrast enhancement, which was slight in the early phase and strong in the late phase. Therefore, a rich, fibrous tissue tumour (i.e., desmoid-type fibromatosis, solitary fibrous tumours, or other malignant mesenchymal tumours) was suspected. Fluorodeoxyglucose-positron emission tomography (FDG-PET) showed abnormal uptake at the tumour, with a maximal standardized uptake value (SUV max) of 6.41. Based on the high SUV max on FDG-PET, we suspected a malignant tumour. Preoperative biopsy of the tumour was not performed for two reasons: 1) the retroperitoneal tumour invaded the left ureter, causing severe hydronephrosis of the left kidney; therefore, it was not possible to rescue renal function unless the tumour was resected; and 2) biopsy of the tumour might have induced dissemination if the tumour was malignant.

In response, we performed tumour resection, right salpingo-oophorectomy, ureterectomy, and ureterocystostomy. The left ureter was present in the retroperitoneal tumour, which adhered

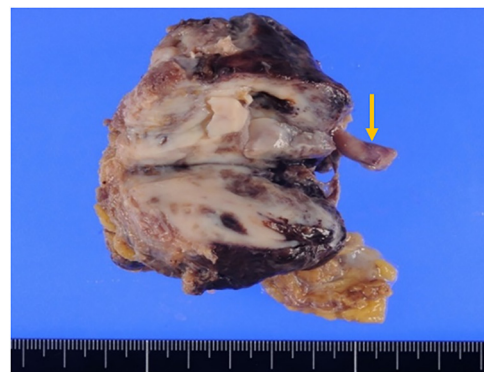


Fig. 2. Macroscopic findings.

Grossly, the tumour included firm, tan, or white masses. The cut surface was firm. The tumour involved the left ureter (yellow arrows).

to the left internal/external iliac artery, rectum, bladder, and the edge of the vagina. Additionally, it invaded the left internal iliac artery and muscularis of the bladder (Fig. 2). It was not possible to isolate the tumour from the left ureter and the internal iliac artery; therefore, en bloc resection was performed. The left ureter and iliac artery were cut superior to the tumour. The bladder was then inflated with air and was peeled off from the tumour. The tumour had partially invaded the posterior wall of the bladder, making the muscularis of the bladder thinner. By peeling off the bladder, the edge of the vagina was opened and later sutured to close after tumour resection. The operation was mainly performed by gynaecologists, and urologists joined to perform the ureterectomy and ureterocystostomy. The left ureter reconstruction was performed with a Boari flap. Macroscopically, the tumour was poorly circumscribed and haemorrhagic. Pathological diagno-

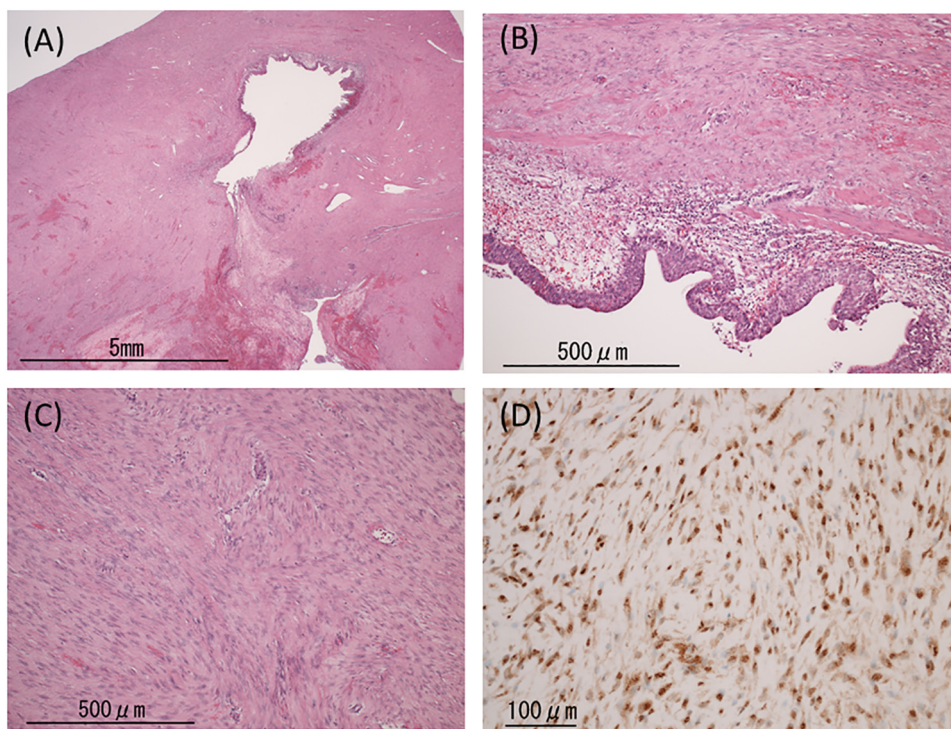


Fig. 3. Hematoxylin and eosin (HE) staining and immunostaining.

A: Histological findings. The tumour involved the left ureter (hematoxylin and eosin [HE] staining; 12.5× magnification).

B: Histological findings. The tumour cells invaded the muscular layer of the left ureter (HE staining; 100× magnification).

C: Hematoxylin and eosin (HE) staining. The desmoid-type fibromatosis was composed of long fascicles of spindle cells (HE staining; 40× magnification).

D: Immunostaining for β -catenin showed nuclear expression in neoplastic cells (100× magnification).

sis of an intraoperative frozen sample was benign mesenchymal tumour.

The postoperative course was uneventful, and the patient was discharged on postoperative day 16. Histopathologically, the tumour comprised spindle-shaped fibroblast-like cells which infiltrated into the ureter lumen and surrounding soft tissues; however, atypical cells were not found in the tumour (Fig. 3A–C).

The resection margin was scant and the tumour border was so vague that an exact evaluation of the resection ends was impossible. Immunohistochemistry for β -catenin showed nuclear expression in almost all tumour cells (Fig. 3D). The number of mitotic figures was less than 1 in 20 representative high-power fields. The Ki-67 labelling index was less than 1%. Based on these results, we diagnosed the tumour as desmoid-type fibromatosis.

One month after the operation, transvaginal sonography showed an irregular-shaped mass (measuring 2.1×1.2 mm) on the inside of the left external iliac artery; however, the patient was asymptomatic. We suspected recurrence of the tumour and commenced pharmacotherapy with tranilast (300 mg/day, three times per day). Four months after the operation, the mass disappeared and tranilast was discontinued. There has been no sign of recurrence 10 months after the operation.

3. Discussion

In the present case, the patient had a history of total abdominal hysterectomy and left salpingo-oophorectomy 3 years before detection of the retroperitoneal tumour. The patient's aetiology was not fully understood, but it was reported that tumour development is related to physical factors, such as trauma or surgery [7]. A definite episode of trauma was observed in a high proportion (19–63%) of cases with this tumour, and 50% of these cases developed in the first 4 years post-trauma or surgery [9,10]. Molecular

interlinks between the wound healing process and mesenchymal fibroproliferative tumour development have been suggested [10,11]. The surgical wound may have triggered tumour development. One case of desmoid tumour with a history of total abdominal hysterectomy and right salpingo-oophorectomy was previously reported [10]; however, to our knowledge, there are no reported cases that involved the ureter with severe hydronephrosis, making the present case unique.

Additionally, it was reported that the 10-year recurrence rate of desmoid-type fibromatosis was 33%, and more than 90% of recurrences occurred within 5 years. One of the risk factors for recurrence is margin-positive resection. Ballo et al. reported that the 10-year recurrence rates were 27% in patients with negative margins and 54% in those with positive margins ($P=0.003$) [12]. In our case, it was difficult to evaluate whether the resection ends were negative, and a mass that was suspected as recurrence appeared in the iliac artery 1 month after the operation. In response, we chose pharmacotherapy with tranilast (Rizaben[®]) and the mass disappeared after administration. Tranilast is used for allergic rhinitis, atopic dermatitis, and allergic conjunctivitis, which inhibit the release of chemical inflammatory mediators, such as prostaglandin E2 (PGE2) and histamine, from mast cells. Tranilast is also effective for keloid and hypertrophic scars [13]. Younai et al. reported that the production of transforming growth factor- β 1 (TGF- β 1) was higher in keloid and hypertrophic scars than in normal fibroblasts; TGF- β 1 stimulates collagen synthesis [14]. Tranilast confines collagen synthesis in keloid or hypertrophic scars through inhibiting TGF- β 1 release from fibroblasts. PGE2 and histamine released from mast cells stimulate the multiplication of fibroblasts. Tranilast inhibits their release from mast cells and inhibits the multiplication of fibroblasts. Therefore, through this inhibitory mechanism of tranilast, the tumour shrinks [13–15]. Additionally, Goto et al. reported a case of a patient with desmoid-type fibromatosis on his chest

wall that was successfully reduced and maintained using tranilast [13]. However, in the present case, it was unclear if the mass was a recurrence of desmoid tumour and if tranilast was effective for treatment, because biopsy, abdominal computed tomography, and magnetic resonance imaging were not performed when recurrence was suspected via transvaginal sonography.

Preoperative diagnosis via magnetic resonance imaging and computed tomography indicated a retroperitoneal tumour that involved the left ureter, but in fact, the tumour also invaded the left internal iliac artery and muscularis of the bladder. In retrospect, it was difficult to detect that the tumour invaded these structures. Similar to this case, it is often difficult to correctly diagnose the extent of tumour invasion via preoperative imaging examination; thus, intraoperative decision making is challenging. Goulding et al. reported that a desmoid-type fibromatosis that was found intraoperatively had invasion of the external iliac vein and internal iliac vessels. The researchers sacrificed these vessels in order to excise the tumour [16]. Therefore, we should assume the possibility of sacrificing the vessels and surrounding structures. Data regarding the behaviour of desmoid-type fibromatosis is minimal; hence, it is important to publish rare cases to guide clinical decision making. In gynaecologic surgery, the surrounding ureter is included in the surgical site; thus, retroperitoneal desmoid-type fibromatosis development after surgery may invade the ureter. Therefore, when we consider desmoid-type fibromatosis, it may be necessary to examine the urinary tract before the operation, such as urography and insertion of a ureteral stent. Considering the possibility of sacrificing the vessels and surrounding structures, it may be necessary to request surgeons and urologists to help with the operation in advance.

4. Conclusion

We experienced a case of retroperitoneal desmoid-type fibromatosis that involved the unilateral ureter after gynaecologic surgery.

Conflict of interest

None.

Funding

This research did not receive any specific grant from funding agencies in the public, commercial, or not-for-profit sectors.

Ethical approval

The ethical committee in our institution approved the publication of this case report. The approval number was 170501.

Informed consent

The patient provided unconditional informed consent to the authors to report the findings.

Author contribution

Hitomi Ono wrote the paper. Kensuke Hori, Lena Tashima, Tomohiko Tsuruta, Shin-ichi Nakatsuka, Kimihiko Ito were involved

with the case, general management of the patient, and revised the manuscript for important intellectual content. All authors read and approved the final manuscript.

Guarantor

Kimihiko Ito.

Acknowledgements

The authors are grateful to Dr. Ryo Yamamoto who belongs to Osaka women's and children's hospital for the useful discussions and writing assistance. We are also grateful to the referees for their useful comments.

References

- [1] G.L. Destri, M.J. Ferraro, M. Calabrini, M. Pennisi, G. Magro, Desmoid-type fibromatosis of the mesentery: report of a sporadic case with emphasis on differential diagnostic problems, *Case Rep. Med.* 2014 (2014) 850180.
- [2] B. Kasper, P. Ströbel, P. Hohenberger, Desmoid tumors: clinical features and treatment options for advanced disease, *Oncologist* 16 (2011) 682–693.
- [3] J.J. Reitamo, P. Häyry, E. Nykyri, E. Saxén, The desmoid tumor I. Incidence, sex-, age- and anatomical distribution in the Finnish population, *Am. J. Clin. Pathol.* 77 (1982) 665–673.
- [4] V. Kumar, A.K. Abbas, N. Fausto, J.C. Aster, Robbins and Cotran Pathologic Basis of Disease, 8th ed., Saunders Elsevier, St. Louis, MO, 2010.
- [5] S. Fakhar, M.P. Qazi, G. Saeed, M. Ashraf, N. Tariq, Successful surgical removal of a huge pelvic desmoid tumor, *Taiwan J. Obstet. Gynecol.* 49 (2010) 361–363.
- [6] A. Mariani, A.G. Nascimento, M.J. Webb, F.H. Sim, K.C. Podratz, Surgical management of desmoid tumors of the female pelvis, *J. Am. Coll. Surg.* 191 (2000) 175–183.
- [7] M. Miyaki, M. Konishi, R. Kikuchi-Yanoshita, M. Enomoto, K. Tanaka, H. Takahashi, et al., Coexistence of somatic and germ-line mutations of APC gene in desmoid tumors from patients with familial adenomatous polyposis, *Cancer Res.* 53 (1993) 5079–5082.
- [8] R.A. Agha, A.J. Fowler, A. Saetta, I. Barai, S. Rajmohan, D.P. Orgill, et al., The SCARE Statement: Consensus-based surgical case report guidelines, *Int. J. Surg.* 34 (2016) 180–186.
- [9] J. Shimizu, Y. Kawaura, Y. Tatsuzawa, K. Maeda, M. Oda, A. Kawashima, Desmoid tumor of the chest wall following chest surgery: report of a case, *Surg. Today* 29 (1999) 945–947.
- [10] S.S. Kumar, P.G.V. Ramachandran, N. Madhusudhan, U. Kumbhar, Intra-abdominal desmoid tumour (DT) with pelvic extension—a case report, *J. Clin. Diagn. Res.* 8 (2014) 168–169.
- [11] S.W. Weiss, J.R. Goldblum, Fibromatoses, in: W. Schmitt, S. Black (Eds.), *Enzinger and Weiss's Soft Tissue Tumours*, 5th ed., Mosby Elsevier, Philadelphia, PA, 2008, pp. 227–256.
- [12] M.T. Ballo, G.K. Zagars, A. Pollack, P.W. Pisters, R.A. Pollack, Desmoid tumor: prognostic factors and outcome after surgery, radiation therapy, or combined surgery and radiation therapy, *J. Clin. Oncol.* 17 (1999) 158–167.
- [13] T. Goto, T. Nemoto, K. Ogura, T. Hozumi, N. Funata, Successful treatment of desmoids tumor of the chest wall with tranilast: a case report, *J. Med. Case Rep.* 4 (2010) 384.
- [14] S. Younai, L.S. Nichter, T. Wellisz, J. Reinisch, M.E. Nimni, T.L. Tuan, Modulation of collagen synthesis by transforming growth factor-beta in keloid and hypertrophic scar fibroblasts, *Ann. Plast. Surg.* 33 (1994) 148–151.
- [15] H. Komatsu, M. Kojima, N. Tsutsumi, S. Hamano, H. Kusama, A. Ujiie, et al., Mechanism of inhibitory action of tranilast on the release of slow reacting substance of anaphylaxis (SRS-A) in vitro: effect of tranilast on the release of arachidonic acid and its metabolites, *Jpn. J. Pharmacol.* 46 (1988) 53–60.
- [16] E.A. Goulding, M. Bunting, R. Harle, P. Blomfield, Surgical management of a retroperitoneal pelvic desmoid tumour involving the sacrifice of external iliac vein and internal iliac vessels, *Gynecol. Oncol. Rep.* 20 (2017) 87–89.

Open Access

This article is published Open Access at [sciencedirect.com](https://www.sciencedirect.com). It is distributed under the [IJSCR Supplemental terms and conditions](#), which permits unrestricted non commercial use, distribution, and reproduction in any medium, provided the original authors and source are credited.