

# Spontaneous pregnancy after full recovery from hypopituitarism caused by lymphocytic hypophysitis

Shunsuke Funazaki<sup>1</sup>, Hodaka Yamada<sup>1</sup>, Kazuo Hara<sup>1</sup> and San-e Ishikawa<sup>1,2</sup>

Division of Endocrinology and Metabolism <sup>1</sup>Department of Medicine, Jichi Medical University Saitama Medical Center, Saitama, Japan and <sup>2</sup>Division of Endocrinology and Metabolism, International University of Health and Welfare Hospital, Tochigi, Japan

Correspondence  
should be addressed  
to H Yamada  
**Email**  
[hyamada0510@jichi.ac.jp](mailto:hyamada0510@jichi.ac.jp)

## Summary

Lymphocytic hypophysitis (LyH) has been known to be associated with pregnancy. We herein report the case of a 33-year-old woman who underwent vaginal delivery without massive bleeding at 40 weeks of gestation. Because of the presence of headache and terrible fatigue after childbirth, she visited our hospital. Severe hyponatremia (Na, 118mEq/L) and visual field abnormality was noted upon examination. MRI revealed pituitary enlargement with a swollen pituitary stalk, albeit at low signal intensity. Basal pituitary hormone levels were all reduced and remained low after exogenous administration of hypothalamic-releasing hormones. She was diagnosed with LyH and was started on prednisolone 60 mg/day. A month later, her pituitary function had gradually improved together with a decrease in pituitary enlargement and recovery of her visual field. The dose of prednisolone was gradually reduced and finally withdrawn 27 months later. After prednisolone withdrawal, her pituitary function remained normal despite the absence of any hormonal replacement. A year later, she became pregnant without medication and delivered a second baby without LyH recurrence. Thereafter, her pituitary function has been normal for more than 5 years. Two valuable observations can be highlighted from the case. First, the patient completely recovered from LyH through prompt prednisolone therapy during its initial phase and had almost normal pituitary function. Second, after recovery from LyH, she was able to undergo spontaneous pregnancy and deliver a baby. We believe that reporting incidences of spontaneous pregnancy after complete normalization of pituitary function in patients with LyH is of great significance.

## Learning points:

- Females are more affected by LyH than males given its strong association with pregnancy.
- LyH possesses characteristic findings on pituitary MRI.
- Glucocorticoid therapy for LyH has been recommended as an effective treatment.
- A history of previous pregnancies does not increase the risk of developing AH in subsequent pregnancies.
- Early induction of high-dose prednisolone was therapeutically effective in treating LyH.

## Background

Lymphocytic hypophysitis (LyH) is an autoimmune disorder characterized by lymphocyte infiltration into the pituitary gland and induction of chronic inflammation, leading to pituitary dysfunction. Its onset has been linked

to gestation or the postpartum period in most females. Despite prednisolone treatment, the disorder may remain persistent and result in hypopituitarism. Accordingly, only a few reports have indicated curable cases of LyH.

The present study details our experience with a female who suffered from LyH. Early prednisolone treatment led to complete recovery from hypopituitarism, which allowed for spontaneous pregnancy given the normal pituitary function.

## Case presentation

A 33-year-old Japanese pregnant woman experienced no problems until her eighth month of pregnancy. However, at 9 months, she experienced headache and visual field narrowing. She underwent vaginal delivery with a blood loss of 200 mL at 40 weeks of gestation. After delivery, she had not been able to lactate, while her visual field narrowing remained. Two weeks after childbirth, she developed not only headache and abnormal vision but also terrible malaise, which prompted her to visit Jichi Medical University Saitama Medical Center. Upon examination, she was found to have severe hyponatremia (118 mEq/L), which led to immediate hospitalization. Her level of consciousness was E4V4M6 (Glasgow Coma Scale). Initial physical examination findings were as follows: height, 163 cm; weight, 58.3 kg; BMI, 21.9 kg/m<sup>2</sup>; blood pressure, 111/79 mmHg; heart rate, 86 beats/min and body temperature, 36.5°C. She had no pertinent physical and neurological examination findings except for hemianopia.

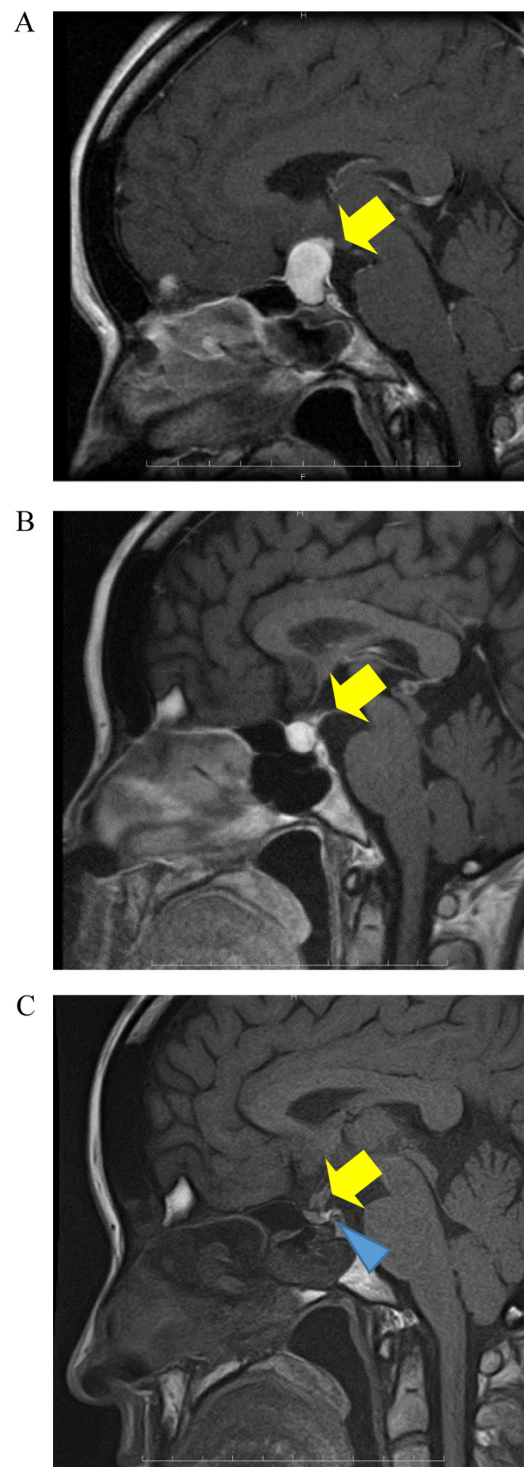
## Investigation

Initial blood data were as follows: hemoglobin: 10.5 g/dL; mean cell volume: 83.7 fL; white cell count: 8600/L; platelet count: 64.5 × 10<sup>4</sup>/L; albumin: 3.1 g/L; alanine aminotransferase: 70 U/L; aspartate aminotransferase: 53 U/L; blood urea nitrogen: 5 mg/dL; serum creatinine: 0.36 mg/dL, sodium: 118 mEq/L; potassium: 4.0 mEq/L;

**Table 1** Endocrinological data upon initial hospitalization.

Parameter	Patient value
Serum TSH (μIU/mL)	0.106
Serum GH (ng/mL)	0.746
Serum LH (mIU/mL)	<1.0
Serum FSH (mIU/mL)	1.46
Plasma ACTH (ng/mL)	<2.0
Serum prolactin (ng/mL)	5.18
Plasma ADH (pg/mL)	0.9
Serum free T4 (ng/dL)	0.61
Serum free T3 (pg/mL)	2.90
Serum cortisol (μg/dL)	<1.0

ADH, antidiuretic hormone.



**Figure 1**

Pituitary MRI findings. Enhanced pituitary MRI upon hospitalization (A) revealed a homogenous enlargement of the anterior pituitary gland and pituitary stalk toward the suprasellar space, albeit at low signal intensity (arrow). The bright spot of the posterior pituitary was unclear. Enhanced pituitary MRI 1 month after starting prednisolone (B) revealed a marked reduction in anterior pituitary gland swelling (arrow). Plane pituitary MRI after prednisolone withdrawal (C) revealed normal morphology (arrow). The bright spot of the posterior pituitary became clear (triangle arrow).

chloride: 90 mEq/L and fasting plasma glucose: 98 mg/dL. Basal pituitary hormone levels are shown in Table 1. Accordingly, basal levels of serum LH, FSH and cortisol, as well as plasma ACTH, were below the normal range. Pituitary MRI revealed a homogenous enlargement of the anterior pituitary gland and the pituitary stalk toward the suprasellar space, albeit at low signal intensity (Fig. 1A). After consulting with the neurosurgeon, a tentative diagnosis of hypopituitarism was established given the reduced serum cortisol and plasma ACTH levels. The patient subsequently received 100 mg of hydrocortisone for 2 days followed by 30 mg of prednisolone.

Hormone-releasing capability was examined through exogenous administration of hypothalamic-releasing hormones (TRH, CRH, LH-RH and GRH). Consequently, TSH, LH, FSH, GH, prolactin and ACTH failed to respond to exogenous hypothalamic-releasing hormones, although basal plasma ACTH level was within the normal range (Table 2A). Moreover, no antibodies against thyroglobulin, TSH receptor, pituitary gland, IgG4 and soluble interleukin-2 receptor were found, except for a positive antinuclear antibody.

**Table 2** Challenge tests stimulated using hypothalamic-releasing hormones (TRH, 500 µg; GnRH, 100 µg; GH-RH, 100 µg; CRH, 100 µg).

	Time (min)				
	0	30	60	90	120
<b>A</b>					
TSH (IU/mL)	0.543	1.529	1.773	1.636	1.323
GH (ng/mL)	0.117	4.048	4.79	4.045	1.51
LH (mIU/mL)	<0.1	0.17	0.19	0.18	0.17
FSH (mIU/mL)	1.9	3.37	4.64	5.09	6.08
PRL (ng/mL)	1.96	8.4	9.88	8.68	7.12
ACTH (pg/mL)	54	154	130	19.3	76.1
<b>B</b>					
TSH (IU/mL)	1.225	8.741	7.376	5.338	3.498
GH (ng/mL)	0.502	20.22	11.45	5.607	1.828
LH (mIU/mL)	1.57	6.92	12.38	16.61	20.28
FSH (mIU/mL)	2.59	4.01	7.03	10.14	12.64
PRL (ng/mL)	19.91	119.53	75.74	54.9	45.4
ACTH (pg/mL)	6.5	76.3	43.5	29.1	28.1
<b>C</b>					
TSH (IU/mL)	1.201	13.932	10.999	9.328	6.018
GH (ng/mL)	0.05	24.9	22.6	18.63	5.226
LH (mIU/mL)	3.54	8.72	8.22	8.65	8.21
FSH (mIU/mL)	5.18	5.81	6.19	6.89	8.08
ACTH (pg/mL)	27.9	40.1	47.7	26	25.2
Cortisol (µg/dL)	20.4	15.6	17.8	14	13.7

Challenge tests were repeated before prednisolone treatment (A), at 1 month after starting prednisolone (B) and after prednisolone withdrawal (C).

## Treatment

Despite the absence of anti-pituitary antibodies, we were strongly convinced of a diagnosis of LyH considering the MRI findings and rapid development of hypopituitarism and visual disturbance. Therefore, she was initially prescribed 60 mg/day of prednisolone (1 mg/kg/day).

## Outcome and follow-up

After prednisolone treatment, three examinations were conducted within a month. As shown in Fig. 2, profound narrowing of the visual field was observed before prednisolone treatment. However, only 10 days into the treatment, the patient's narrowed vision remarkably improved. Moreover, pituitary MRI showed a marked reduction in anterior pituitary gland swelling (Fig. 1B). Challenge tests using hypothalamic-releasing hormones were also performed. Accordingly, pituitary hormone responses were markedly better after compared with before treatment and were normalized within a month after the onset of prednisolone treatment (Table 2B). One year thereafter, her menstruation returned, and the prednisolone dose had been gradually reduced to avoid recurrence and secondary adrenal insufficiency. Until it was finally withdrawn after 27 months (Fig. 3). At that time, the third challenge test was performed. (Table 2C) Similarly, anterior pituitary hormone responses to hypothalamic-releasing hormones were appropriately maintained. However, LH and FSH responses to GnRH seemed to be somewhat poor.

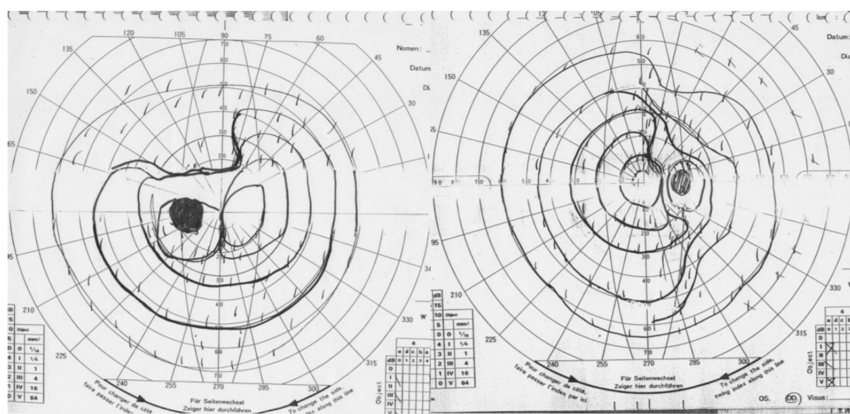
A year after we finished prednisolone therapy, the patient became pregnant again despite receiving no medication. Moreover, her clinical pregnancy course remained uneventful, and her second baby was delivered through Caesarean section at 9 months of gestation. Although no recurrence of LyH was noted, 100 mg of hydrocortisone was infused to prevent adrenal insufficiency only at caesarean operation. Remarkably, the patient maintained normal pituitary gland function and morphology at least 5 years after prednisolone withdrawal (Fig. 1C).

## Discussion

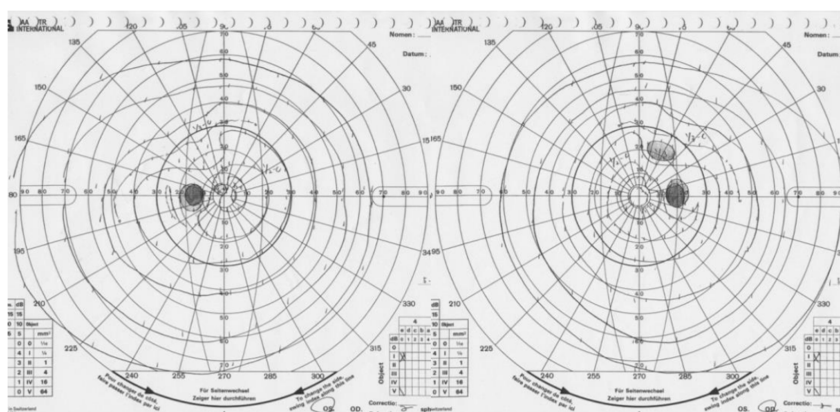
LyH is an autoimmune disorder characterized by lymphocyte infiltration and destruction of the pituitary gland, leading to various degrees of pituitary dysfunction. It may also be associated with other autoimmune disorders. Moreover, females are more affected by LyH than males (1) given its strong association with pregnancy (2).



A



B



**Figure 2**

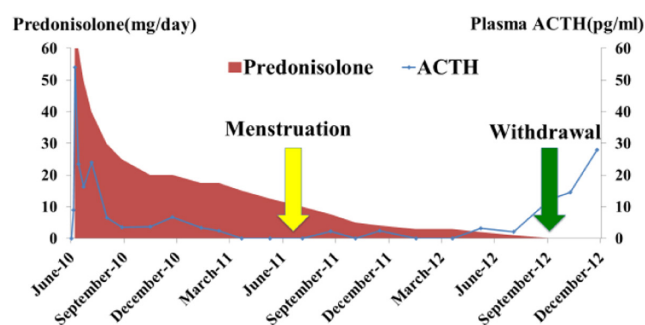
Comparison of campimetry before and after prednisolone treatment. Results for the right and left eyes are shown in the right and left panels, respectively. Campimetry test before prednisolone treatment showed narrowing of the visual field (A). Campimetry test 10 days after starting prednisolone showed improved visual field (B).

Given its association with pregnancy, clinical manifestations of hypopituitarism may differentiate LyH from Sheehan's syndrome, which could occur in patients with a history of massive postpartum hemorrhage. However, our patient did not experience massive postpartum hemorrhage and had an enlarged pituitary gland as seen on MRI; these findings could easily exclude the possibility of Sheehan's syndrome.

LyH possesses characteristic findings on pituitary MRI, including pituitary gland enlargement with diffuse thickening of the pituitary stalk, low signal intensity, uniform enhancement of the pituitary gland using metrizamide and loss of the neurohypophyseal bright spot (3). In addition, pituitary enlargement gradually decreases within months, whereas hypopituitarism, if permanent, may ultimately disappear. LyH may be difficult to diagnose using only imaging findings. However, the difficulty in diagnosing LyH without pituitary biopsy could be considerably reduced if data from all non-invasive examinations are available.

Two valuable observations can be highlighted from the present case. First, glucocorticoid therapy completely

normalized hypopituitarism. Because of the presence of headache, generalized malaise and visual field narrowing, a high dose of prednisolone was initiated during the early stages of LyH. Moreover, considering that LyH is an autoimmune disorder, glucocorticoid therapy has been recommended as an effective treatment. Although others fail to normalize, 17–44% of patients with LyH show improvement in their pituitary function through steroid



**Figure 3**

Prednisolone treatment and plasma ACTH levels during the clinical course.

pulse therapy (4, 5). Unfortunately, no evidence for the optimal initial dose and duration of prednisolone treatment is available. In the present case, prednisolone treatment was continued for approximately 2 years, although its dose was gradually reduced during the clinical course. Furthermore, glucocorticoid therapy was found to reduce pituitary enlargement in 20 of 23 patients with LyH (6). Although spontaneous reduction was observed during the clinical course, glucocorticoid therapy accelerated the process.

Second, the patient was able to undergo spontaneous pregnancy and deliver a second baby. As described earlier, the patient was able to fully recover from hypopituitarism within the first month of therapy. Repeated challenge tests confirmed normal hormone responses to hypothalamic-releasing hormones. The second pregnancy also confirmed normal pituitary gland function after LyH. Only a few reports have noted spontaneous pregnancy after a history of LyH (7, 8, 9, 10). One patient had fully recovered from LyH and completed her pregnancy without any hormonal replacement, although she did not have hypopituitarism (7). Meanwhile, three other patients needed hormonal replacement to successfully induce pregnancy (9, 10).

In summary, we demonstrated that early induction of high-dose prednisolone was therapeutically effective in treating LyH. The patient had fully recovered from hypopituitarism while regaining normal hormone-releasing capability of the anterior pituitary gland. Moreover, the patient was able to undergo spontaneous pregnancy and deliver her baby. We believe that reporting incidences of spontaneous pregnancy after complete normalization of pituitary function in patients with LyH is of considerable significance.

#### Declaration of interest

The authors declare that there is no conflict of interest that could be perceived as prejudicing the impartiality of this case report.

#### Funding

This research did not receive any specific grant from any funding agency in the public, commercial or not-for-profit sector.

#### Patient consent

We obtained the informed consent from the patient for this article.

#### Author contribution statement

Shunsuke Funazaki and Hodaka Yamada wrote this case report. Kazuo Hara and San-e Ishikawa checked, gave counsel and read the proofs.

## References

- 1 Bellastella A, Bizzarro A, Coronella C, Bellastella G, Sinisi AA & De Bellis A. Lymphocytic hypophysitis: a rare or underestimated disease? *European Journal of Endocrinology*, 2003 **149** 363–376. (<https://doi.org/10.1530/eje.0.1490363>)
- 2 Asa SL, Bilbao JM, Kovacs K, Josse RG & Kreines K. Lymphocytic hypophysitis of pregnancy resulting in hypopituitarism: a distinct clinicopathologic entity. *Annals of Internal Medicine* 1981 **95** 166–171. (<https://doi.org/10.7326/0003-4819-95-2-166>)
- 3 Chrisoulidou A, Boudina M, Karavitaki N, Bili E & Wass J. Pituitary disorders in pregnancy. *Hormones* 2015 **14** 70–80 (in English).
- 4 Kristof RA, Van Roost D, Klingmuller D, Springer W & Schramm J. Lymphocytic hypophysitis: non-invasive diagnosis and treatment by high dose methylprednisolone pulse therapy? *Journal of Neurology, Neurosurgery, and Psychiatry* 1999 **67** 398–402. (<https://doi.org/10.1136/jnnp.67.3.398>)
- 5 Khare S, Jagtap VS, Budyal SR, Kasaliwal R, Kakade HR, Bukan A, Sankhe S, Lila AR, Bandgar T, Menon PS, *et al.* Primary (autoimmune) hypophysitis: a single centre experience. *Pituitary* 2015 **18** 16–22. (<https://doi.org/10.1007/s11102-013-0550-9>)
- 6 Lupi I, Manetti L, Raffaelli V, Lombardi M, Cosottini M, Iannelli A, Basolo F, Proietti A, Bogazzi F, Caturegli P, *et al.* Diagnosis and treatment of autoimmune hypophysitis: a short review. *Journal of Endocrinological Investigation* 2011 **34** e245–e252. (<https://doi.org/10.3275/7863>)
- 7 Lu Z, Yang G, Ba J, Dou J, Mu Y & Lu J. Spontaneous pregnancy in a patient with a relapse of lymphocytic hypophysitis successfully treated with azathioprine and glucocorticoids. *Endocrine* 2011 **39** 296–297. (<https://doi.org/10.1007/s12020-011-9458-1>)
- 8 Hayes FJ & McKenna TJ. The occurrence of lymphocytic hypophysitis in a first but not subsequent pregnancy. *Journal of Clinical Endocrinology and Metabolism* 1996 **81** 3131–3132. (<https://doi.org/10.1210/jcem.81.8.8768889>)
- 9 Tsur A, Leibowitz G, Samueloff A & Gross DJ. Successful pregnancy in a patient with pre-existing lymphocytic hypophysitis. *Acta Obstetrica et Gynecologica Scandinavica* 1996 **75** 772–774. (<https://doi.org/10.3109/00016349609065747>)
- 10 Dong AM, Yin HF, Gao YM & Guo XH. Spontaneous pregnancy in a patient with lymphocytic hypophysitis. *Journal of Peking University (Health Sciences)* 2009 **41** 242–244.

Received in final form 4 July 2018

Accepted 17 July 2018