

Received: 2020.06.24
Accepted: 2020.10.30
Available online: 2020.12.18
Published: 2020.12.30

Role of Magnetic Resonance Spectroscopy in Evaluation of Cerebral Metabolic Status Before and After Carotid Endarterectomy/Thromboendarterectomy and Carotid Artery Stenting in Patients with Asymptomatic Critical Internal Carotid Artery Stenosis

Authors' Contribution:
Study Design A
Data Collection B
Statistical Analysis C
Data Interpretation D
Manuscript Preparation E
Literature Search F
Funds Collection G

ABCDEF G 1 **Katarzyna Sklinda**
BE 1 **Bartosz Mruk**
CD 2 **Agnieszka Surowiecka**
B 1 **Marek Ciał**
F 1 **Łukasz Paluch**
A 3,4 **Piotr Andziak**
A 1 **Jerzy Walecki**

1 Department of Diagnostic and Interventional Radiology, Centre of Postgraduate Medical Education, Warsaw, Poland
2 Department of Surgical Research and Transplantology, Mossakowski Medical Research Centre, Polish Academy of Sciences, Warsaw, Poland
3 Department of General and Vascular Surgery, Central Clinical Hospital of the Ministry of Internal Affairs and Administration, Warsaw, Poland
4 Centre of Postgraduate Medical Education, Warsaw, Poland

Corresponding Author: Katarzyna Sklinda, e-mail: katarzyna.sklinda@gmail.com
Source of support: Departmental sources

Background: The relative efficacy of carotid endarterectomy (CEA)/thromboendarterectomy (TEA) and carotid artery stenting (CAS) already has been compared in randomized controlled trials and a meta-analysis, but only limited data exist describing the status of cerebral metabolism before and after these interventions.

The aim of the present study was to compare metabolic changes before and after treatment of carotid stenosis and assess their potential clinical implications.





Material/Methods: Patients with asymptomatic unilateral critical internal CAS were imaged with proton 3T magnetic resonance spectroscopy (H-MRS) because the technique is more sensitive than regular magnetic resonance imaging for detection of the early signs of ischemic events. Abnormal metabolite ratios detected with H-MRS may precede actual morphological changes associated with hypoperfusion as well as reperfusion changes. Ipsilateral and contralateral middle cerebral artery vascular territories were both evaluated before and after vascular intervention. H-MRS was performed within 24 h before and after surgery. Correlations in the metabolic data from H-MRS for N-acetylaspartic acid (NAA)+N-acetylaspartylglutamate, creatinine (Cr)+phosphocreatinine, and phosphocholine+glycerophosphocholine (Cho) were sought.

Results: H-MRS voxels from 11 subjects were analyzed. Values for dCho/CrI, dCho/CrC and Cho/Naal ($P < 0.001$) were significantly higher ipsilaterally than contralaterally. Ratios for dNaa/ChoC and Cho/Naac were significantly higher on the non-operated side ($P < 0.001$).

Conclusions: H-MRS may be helpful for assessment of patients with CAS, particularly because unlike other modalities, it reveals postoperative changes in metabolic brain status. Initial results indicate the important role of perioperative neuroprotective treatment.

MeSH Keywords: Brain • Carotid Stenosis • Hypoxia-Ischemia, Brain • Magnetic Resonance Spectroscopy

Full-text PDF: <https://www.medscimonit.com/abstract/index/idArt/927029>

 2285  1  5  15



Background

Randomized controlled trials (RCTs) have found that both carotid endarterectomy (CEA) and carotid artery stenting (CAS) are effective for preventing subsequent stroke or death in patients with critical internal carotid artery (ICA) stenosis that is symptomatic (e.g., the North American Symptomatic Carotid Endarterectomy Trial [NASCET], the European Carotid Surgery Trial, and the International Carotid Stenting Study) or asymptomatic (e.g., the Asymptomatic Carotid Atherosclerosis Study and the Asymptomatic Carotid Surgery Trial [ACT]). The relative effectiveness of CEA and CAS already has been compared in RCTs such as ACT 1 and the Carotid Revascularization Endarterectomy versus Stenting Trial and a meta-analysis. However, only limited data exist describing and/or comparing cerebral metabolism prior to and after use of the 2 methods. The aim of this study was to compare CEA and CAS using data from localized *in vivo* proton 3T magnetic resonance spectroscopy (H-MRS).

Many studies have shown that CEA and CAS are effective for the management of patients with ICA stenosis. A recent meta-analysis showed that the risk of stroke during long-term follow-up was significantly higher with CAS, but mostly attributable to minor subclinical periprocedural strokes [1,2].

Localized *in vivo* H-MRS is a method used to measure the metabolic status of brain tissue [3]. Because it is noninvasive and more sensitive than regular magnetic resonance imaging for detection of the early signs of ischemic events, H-MRS may be a source of valuable clinical information about vascular interventions. Different metabolite ratios detected by this method may precede actual morphological changes associated with hypoperfusion and reperfusion changes.

The aim of this study was to compare metabolic changes before and after treatment of ICA stenosis and assess their potential clinical implications. Concentrations of the following metabolites were assessed: NAA (N-acetylaspartic acid+N-acetylaspartylglutamate), Cr (creatinine+phosphocreatine), and Cho (primarily phosphocholine+glycerophosphocholine).

Material and Methods

We designed a prospective study to using H-MRS to compare metabolic changes in vasculature in the territory of the middle cerebral artery (MCA) in 11 patients with critical ICA stenosis undergoing either CEA/TEA or CAS. Patients were evaluated using MRI prior to and 1 to 3 days after the procedure. Both the contralateral and ipsilateral sides were evaluated. The comparison involved initial structural recognition of brain structures based on fluid-attenuated inversion recovery (FLAIR) axial

scans. If no exclusion criteria were met, FLAIR images were followed by single-voxel spectroscopy-magnetic resonance spectroscopy (SV-MRS) Point RESolve Spectroscopy (PRESS) with a long echo time (TE) point of 144 ms. All protocols were approved by the Internal Review Board of Central Clinical Hospital of the Ministry of the Interior and Administration and written informed consent was obtained from all participants.

The analyzed parameters included index values on the ipsilateral (I) side (the operated side) for NAA/Cr, Cho/Cr, NAA/Cho, and Cho/NAA before and after surgery (I2), as well as on the contralateral (C) side and in controls (C2). The differences in values before and after the surgery were calculated as delta.

Of 18 consecutive patients (mean age 77 years) with critical ICA stenosis (>70% reduction in diameter), 9 were eligible for CEA and 2 for CAS, based on CT NASCET criteria [4]. According to European Society for Vascular Surgery (ESVS) criteria [5], CEA is the method of choice in patients with ICA stenosis >70%. CAS is considered an option for patients with multiple contraindications to conventional surgical intervention, such as clinically significant cardiac disease, severe pulmonary disease, contralateral carotid occlusion, recurrent stenosis after CEA, previous radical neck surgery, or cervical radiation therapy. Therefore, the number of patients in the study arms differed.

After surgical qualification, a short MR protocol was followed. In 5 patients, post-ischemic changes were diagnosed within the MCA territory. One patient had severe brain atrophy that caused dilatation of intracranial fluid-filled spaces. One patient refused to undergo control imaging after surgery without providing a reason. The remaining 11 patients were evaluated with H-MRS prior to and 1 to 14 days after the designated procedure. Eleven patients met the final inclusion criteria for the study, namely asymptomatic unilateral critical ICA stenosis (>70% reduction in diameter, based on CT NASCET criteria) with neither clinical nor imaging symptoms of stroke and no contraindications to MRI. Patients included in the study had only low-grade ICA stenosis affecting the contralateral side (<50%). The characteristics of the study group are shown in Table 1. Statistical significance was defined as $P<0.05$.

Vascular interventions were carried out by experienced surgeons using heparin, antiplatelet therapy, and appropriate regional anesthesia. All CAS procedures were performed under distal embolic protection. Localized H-MRS was performed on a 3T MR scanner (Ingenia, Philips Healthcare, Best, The Netherlands) and using an Ingenia 3T Scanner Receiver Head Coil.

After routine scout scans of the head, FLAIR images were acquired in the axial plane. The technician was instructed to pay special attention to symmetric positioning of patient's head to facilitate further positioning of the voxel. Based on the FLAIR

Table 1. Characteristics of the group.

Study group	N=11
Gender	Male 8 (73%)
	Female 3 (27%)
Types of surgery	CEA/TEA 9 (82%)
	CAS 2 (18%)
Site of the surgery	LICA 7 (64%)
	RICA 4 (36%)
Mean age	76 yrs

images, patients were qualified for or disqualified from further imaging. Patients were excluded if they had focal lesions within the MCA territory and brain atrophy that caused significant dilatation of brain sulci or ventricles that made subsequent proper voxel placement in the area of interest, such as the basal ganglia, less reliable.

The spectroscopy protocol was based on 1H-SV (single-voxel) PRESS, with a long TE of 144 ms, a repetition time of 2000 ms, and a flip angle of 90 degrees. Both the ipsilateral and contralateral MCA vascular territories were evaluated. The proposed voxel size in the standard protocol was large (2×2×2 cm) to gain as much signal as possible. The basal ganglia are one of the brain regions most prone to ischemic injury and this voxel position increased the chance of detecting subtle changes. The voxels were carefully placed on the ipsilateral and contralateral side, with attention to symmetry and avoidance of fluid-filled spaces.

Results were expressed in raw data and also processed using Philips Spectral Analysis software. Because total Cr concentration is the most constant value in H-MR spectroscopy, it was used as an internal reference marker. The relative metabolite ratios (NAA/Cr, Cho/Cr, NAA/Cho, NAA/Cho, Cho/NAA) were subsequently calculated. Patient data, expressed as means±standard deviation [SD], were compared using a *t* test, which was repeated twice. Any potential correlation was evaluated with a Pearson coefficient. *P*<0.05 was considered statistically significant.

Results

The patients who underwent TEA were significantly older than those who underwent CAS (*P*<0.001). In the TEA group, the mean preoperative and postoperative values were as follows: NAA/Cr I, 1.68 (range 1.28–2.75) and 1.66 (range 1.09–2.19); NAA/Cr C, 1.95 (range 1.05–4.65) and 1.68 (range 0.89–1.98); Cho/Cr I 1.19 (range 0.76–1.6) and 1.58 (range

0.98–5.58); Ch/Cr C, 1.19 (range 0.82–2.22) and 1.9 (range 0.68–2.25); NAA/Cho I 1.47 (range 1.12–1.96) and 1.87 (range 0.99–4.79); NAA/Cho C, 1.72 (range 1.01–2.99) and 1.78 (range 0.49–4.2); Cho/NAA I, 0.72 (range 0.53–0.96) and 0.63 (range 0.21–1.01); and Cho/NAA C, 0.65 (range 0.33–0.99) and 0.702 (range 0.21–1.12).

In the CAS group, the mean preoperative and postoperative values were as follows: NAA/Cr I, 2.78 (range 2.22–3.34) and 1.55 (range 1.37–1.64); NAA/Cr C, 1.46 (range 1.38–1.55) and 2.18 (range 1.38–1.81); Cho/Cr, I 1.51 (range 1.22–1.8) and 0.9 (range 0.85–1.02); Ch/Cr C, 0.85 (range 0.67–1.02) and 0.9 (range 0.85–1.02); NAA/Cho I, 1.83 (range 1.82–1.83) and 1.37 (range 1.13–1.61); NAA/Cho C, 1.8 (range 1.55–2.05) and 2.02 (range 1.87–2.17); Cho/NAA I, 0.55 and 0.62; and Cho/NAA C, 0.57 (range 0.49–0.65) and 0.49 (range 0.46–0.53).

There was a statistically significant difference between dCho/CrI, dCho/CrC, and dCho/Naal (*P*<0.001) values, all of which were higher on the operated side. The dNaa/Cho value was significantly lower on the operated side (*P*<0.001).

The postoperative Cho/Cr index for the ipsilateral site was lower in the older patients.

Levels of dNaa/ChoC for the ipsilateral side were significantly higher than on the operated side (*P*<0.001) as were levels of Cho/Naac (Figures 1–5).

Discussion

As a clinical neuroimaging modality, H-MRS can provide information about metabolic changes in the brains of patients with CAS that may aid preoperative evaluation of their condition and be helpful for monitoring their postoperative state. The spectra in the present study were obtained from single voxels placed in the region of the basal ganglia, which is an area with known sensitivity to oxygen deficiency. We assessed metabolites that are routinely depicted in the 1 to 5 ppm range of the chemical shift scale, namely NAA+N-acetylaspartylglutamate (neuronal integrity), Cr+phosphocreatine (energy metabolism), Cho (membrane stability), and lactate (anaerobic glycolysis). These metabolites may serve as biomarkers for physiologic and pathologic conditions in the brain. An increase in the Cho/Cr ratio combined with a reduced NAA/Cho ratio could serve as a marker for brain damage in a situation in which the sensitivity and specificity of conventional MRI is insufficient. *Ex vivo* [6] and histologic studies [7] have shown that in the mature brain, NAA is present only in neurons, axons, and dendrites – not in glial cells. Therefore, it has been univocally defined as a biomarker for neuronal integrity. tNAA (mainly NAA, with a little from N-acetylaspartylglutamate) is meant

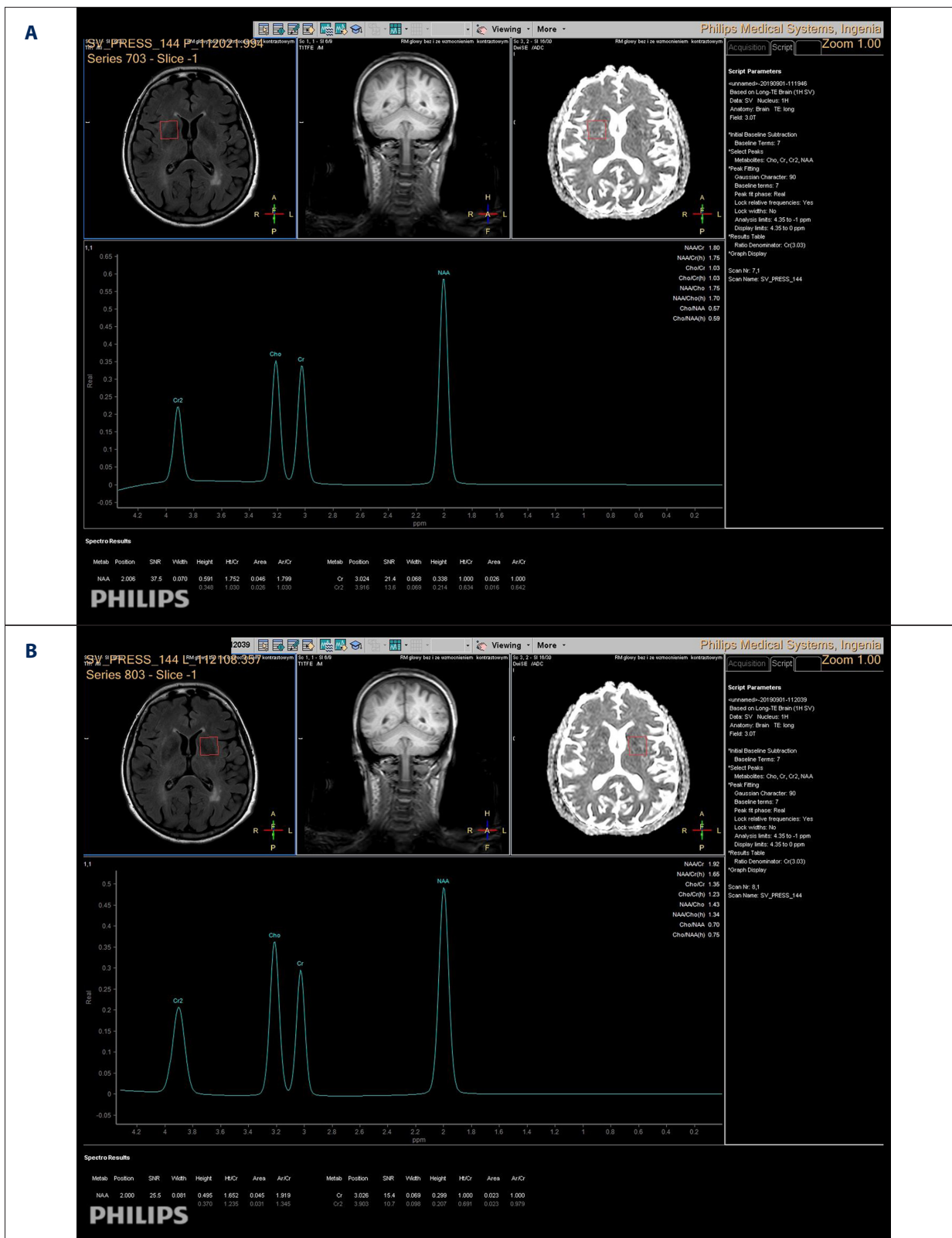


Figure 1. Preoperative single-voxel, 144-ms proton 3T brain magnetic resonance spectroscopy in a patient with asymptomatic unilateral right-sided carotid stenosis. (A) Ipsilateral side. (B) Contralateral side.

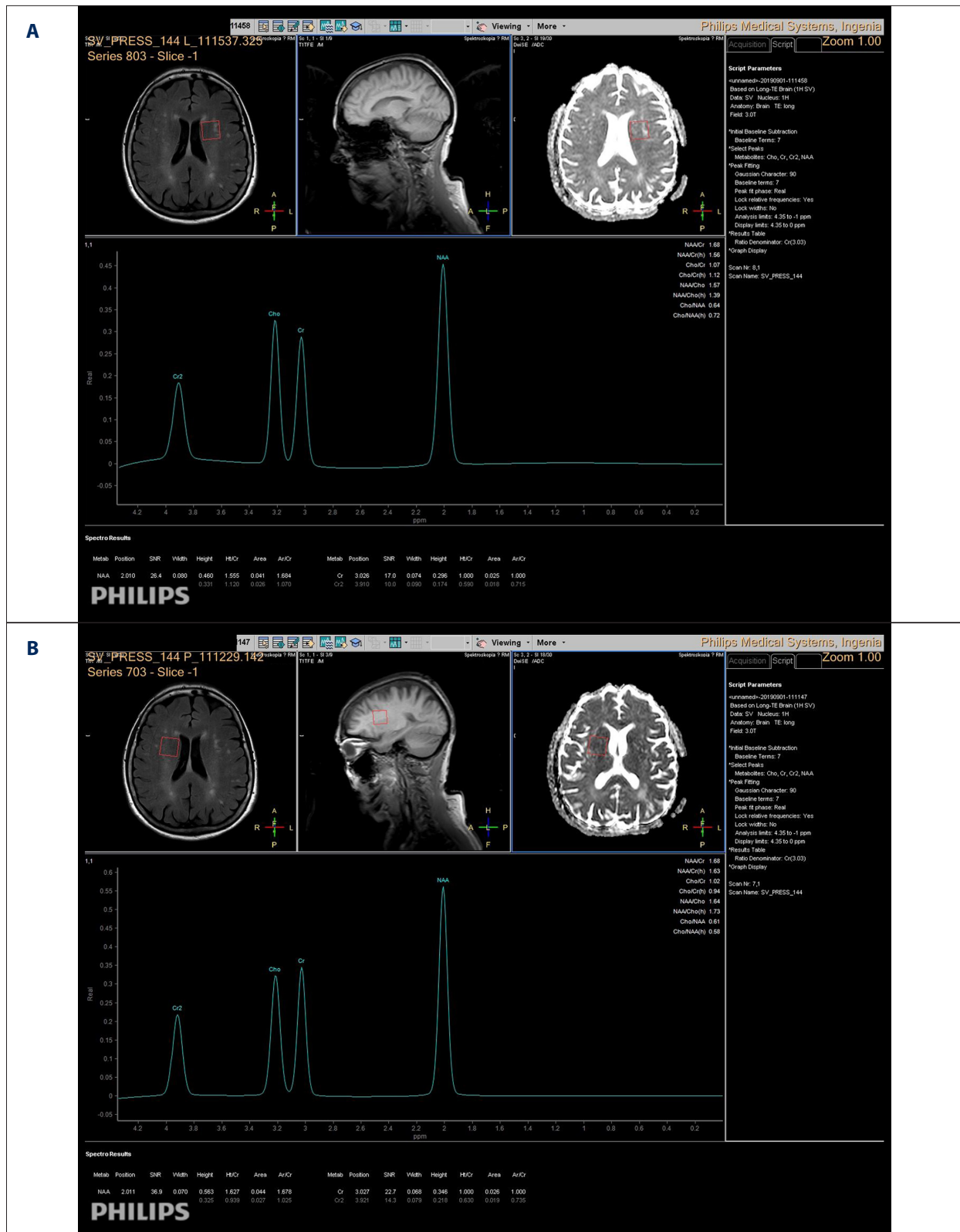

Figure 2. Postoperative single-voxel, 144-ms proton 3T brain magnetic resonance spectroscopy in a patient with asymptomatic unilateral right-sided carotid stenosis. (A) Ipsilateral side. (B) Contralateral side.

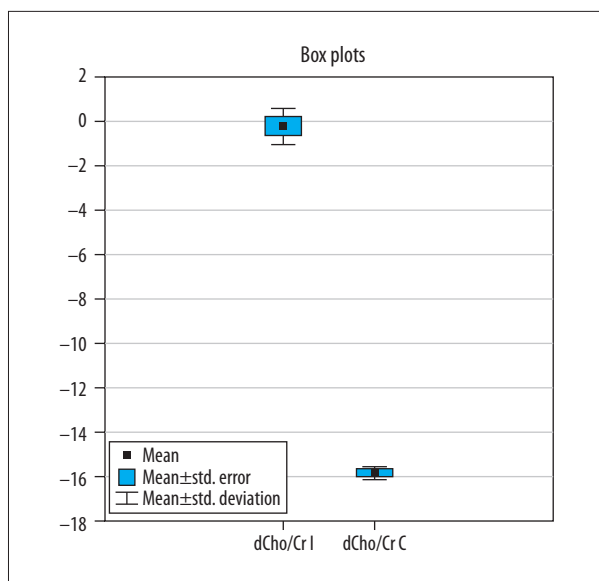


Figure 3. Comparison of delta values for choline/creatine in ipsilateral and contralateral sites. (Subtraction of values before and after surgery.) $P < 0.01$.

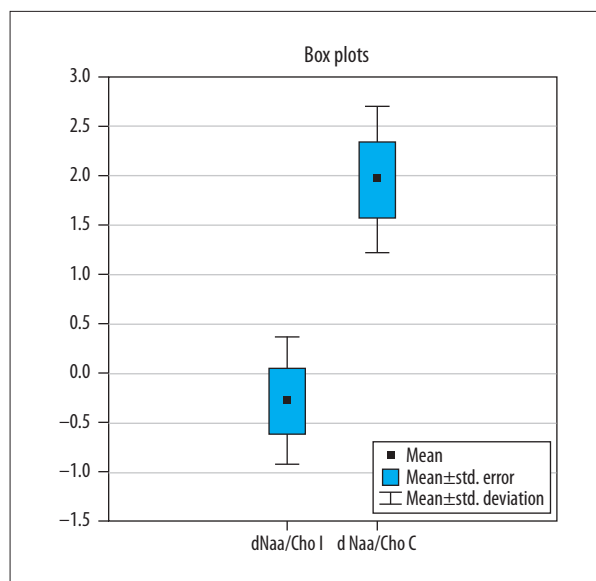


Figure 5. Comparison of delta values for choline/N-acetylaspartic acid in the ipsilateral and contralateral sites. (Subtraction of values before and after surgery.) $P < 0.01$.

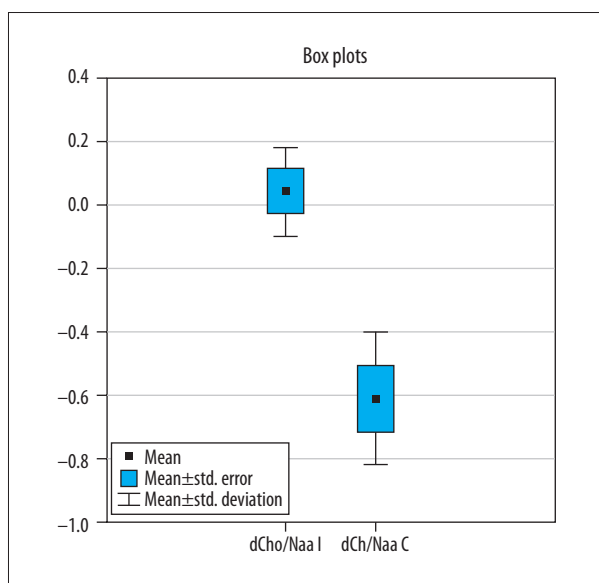


Figure 4. Comparison of delta values for choline/N-acetylaspartic acid in the ipsilateral and contralateral sites. (Subtraction of values before and after surgery.) $P < 0.01$.

to be an *in vivo* biomarker for the presence of viable or damaged neurons [8].

The decrease in NAA in the group of patients we studied was unilateral; therefore, we reject neurodegenerative disorders as a possible explanation [9]. None of the patients manifested clinical symptoms associated with other known causes of unilateral NAA decrease, such as epilepsy [10] and stroke [11].

Ischemic stroke was excluded based on clinical symptoms as well as the FLAIR images. However, all of the patients had chronic hypoxia followed by rapid blood reperfusion, the biochemical characteristics of which can be seen on MRS. The influence of critical CAS on the human brain has yet to be established. The role of metabolism in reperfusion syndrome also is unclear and the usefulness of MR techniques in assessing it has not been described.

Patients with these conditions have a chronic reduction in energy substrates, which results in impairment of cell metabolism. Subsequently, a rapid inflow of oxygen and glucose-rich blood occurs and normal cell metabolism is again possible. In some cases, this scenario changes after approximately 24 h and cell death is observed due to a cascade of intracellular factors that leads to mitochondrial dysfunction. In stroke patients, this process has been described based on its gross manifestations on diffusion coefficient maps and MRI. In patients with CAS, it can only be depicted on MRS because blood flow still exists but is slowly deteriorating [11].

As the ischemia-reperfusion sequence takes place, the membrane breakdown due to cellular necrosis has pathophysiologic effects. Similar changes have been described in neurodegenerative diseases [12], stroke [13], traumatic injury, and diffuse white matter injury in premature infants [14]. Routinely used imaging modalities and clinical examination are not sensitive enough to provide evidence of this process. H-MRS, however, shows an increase in the cerebral Cho/Cr ratio on the ipsilateral side.

The increase in the Cho/Cr ratio seen in the present study was due to increased Cho rather than reduced Cr, as an increase in Cho/NAA coexisted on the same side. An increase in the Cho/Cr ratio has been described in astrogliosis in primates [15].

The present study has a number of limitations. First, because it involved single-voxel MRS, regions that experienced chronic hypoperfusion and that may have had a different metabolic signature, such as the cerebral cortex, may have been missed. In that case, a different imaging modality, such as single-photon emission computed tomography, might be worth using because it covers the whole cerebral volume and is sensitive to changes in brain perfusion. Second, we used the contralateral hemisphere as a reference because all of the patients had unilateral critical CAS and underwent unilateral recanalization. It must be stressed, though, that if the integrity of the circle of Willis has not been compromised, the cerebral blood supply from it may be sufficient for the whole cerebrum even if the patency of 1 of the carotids is impaired. A comparison of results in our patients with normal controls (mean age 76 years) could have resulted in errors due to presence of common neurodegenerative disorders and brain atrophy in this age group as well as less severe CAS.

We did not include in the description of our results changes in lactate level because of errors in assessment of the concentration of that metabolite. The reasons for lack of lactate detection within voxels could include inadequate water suppression, too small voxel size, and limited spectral quality due to head movement.

References:

1. Kim GE, Lee JH, Cho YP: Can carotid endarterectomy improve metabolic status in patients with asymptomatic internal carotid artery flow lesion? Studies with localized *in vivo* proton magnetic resonance spectroscopy. *J Vasc Surg*, 2002; 36(3): 559–64
2. Sardar P, Chatterjee S, Aronow HD et al: Carotid artery stenting versus endarterectomy for stroke prevention: A meta-analysis of clinical trials. *J Am Coll Cardiol*, 2017; 69(18): 2266–75
3. Ross B, Michaelis T: Clinical applications of magnetic resonance spectroscopy. *Magn Reson Q*, 1994; 10(4): 191–247
4. Ferguson GG, Eliasziw M, Barr HW et al: The North American Symptomatic Carotid Endarterectomy Trial: Surgical results in 1415 patients. *Stroke*, 1999; 30(9): 1751–58
5. Naylor AR, Ricco JB, de Borst GJ et al: Editor's Choice – Management of Atherosclerotic Carotid and Vertebral Artery Disease: 2017 Clinical Practice Guidelines of the European Society for Vascular Surgery (ESVS). *Europ J Vasc Endovasc Surg*, 2018; 55(1): 3–81
6. Tallan HH: Studies on the distribution of N-acetyl-L-aspartic acid in brain. *J Biol Chem*, 1957; 224(1): 41–45
7. Moffett JR, Nambodiri MA, Cangro CB, Neale JH: Immunohistochemical localization of N-acetylaspartate in rat brain. *Neuroreport*, 1991; 2(3): 131–34
8. Igarashi H, Suzuki Y, Huber VJ et al: N-acetylaspartate decrease in acute stage of ischemic stroke: A perspective from experimental and clinical studies. *Magn Reson Med Sci*, 2015; 14(1): 13–24
9. Rigotti DJ, Inglese M, Gonen O: Whole-brain N-acetylaspartate as a surrogate marker of neuronal damage in diffuse neurologic disorders. *Am J Neuroradiol*, 2007; 28(10): 1843–49
10. Willmann O, Wennberg R, May T et al: The role of 1H magnetic resonance spectroscopy in pre-operative evaluation for epilepsy surgery. A meta-analysis. *Epilepsy Res*, 2006; 71(2–3): 149–58
11. Parsons MW, Li T, Barber PA et al: Combined (1)H MR spectroscopy and diffusion-weighted MRI improves the prediction of stroke outcome. *Neurology*, 2000; 55(4): 498–505
12. Sturrock A, Laule C, Decolongo J et al: Magnetic resonance spectroscopy biomarkers in premanifest and early Huntington disease [published correction appears in *Neurology*, 2011; 76(3): 309]. *Neurology*, 2010; 75(19): 1702–10
13. Brooks WM, Friedman SD, Gasparovic C: Magnetic resonance spectroscopy in traumatic brain injury. *J Head Trauma Rehabil*, 2001; 16(2): 149–64
14. Kendall GS, Melbourne A, Johnson S et al: White matter NAA/Cho and Cho/Cr ratios at MR spectroscopy are predictive of motor outcome in preterm infants. *Radiology*, 2014; 271(1): 230–38
15. Kim JP, Lentz MR, Westmoreland SV et al: Relationships between astrogliosis and 1H MR spectroscopic measures of brain choline/creatine and myo-inositol/creatine in a primate model. *Am J Neuroradiol*, 2005; 26(4): 752–59

Conclusions

Although MRS may be difficult to include in a routine preoperative MR protocol, it may provide important information about cerebral metabolic status.

Ethical statement

The present study was approved by the local Bioethics Committee (Approval no. 54/2016 issued on January 6, 2016 by the Ethics and Surveillance Committee for Research in Human and Animal Sciences at the Central Clinical Hospital of the Ministry of Internal Affairs).