



# Flow Redirection Endoluminal Device Flow Diverter Placement for Recurrent Dolichoectatic Vertebrobasilar Artery Aneurysm Treated with Multiple Low-Profile Visualized Intraluminal Support Stents: A Case Study

Masahiro Hosogai, Takahito Okazaki, Shigeyuki Sakamoto, Daizo Ishii, Masashi Kuwabara, and Nobutaka Horie

**Objective:** We report a case of dolichoectatic vertebrobasilar aneurysms treated with multiple low-profile visualized intraluminal support (LVIS) stents followed by flow redirection endoluminal device (FRED) flow diverter to prevent the growth of the thrombosed aneurysm.

**Case Presentation:** A 71-year-old man developed diplopia due to oculomotor nerve palsy after 11 years of follow-up for an enlarging thrombosed dolichoectatic vertebrobasilar artery aneurysm. He initially had a fusiform thrombosed aneurysm from the right vertebral artery to the basilar artery. This lesion was tortuous and strongly compressed the pons. A total of 11 LVISs were deployed from the right posterior cerebral artery to the right vertebral artery. Six months after surgery, there was no enlargement of the thrombosed aneurysm on MRI and the contrast leakage out of the stent was markedly reduced in DSA compared to immediately after surgery. One year and seven months after surgery, contrast leakage out of the stent was increased in DSA. The FRED was placed within the overlapped LVISs, and contrast leakage was somewhat reduced. After 2 years and 7 months from the initial treatment, the contrast leakage was still observed. However, there was no enlargement of the aneurysm and no complications related to treatments were observed.

**Conclusion:** Treatment with multiple LVIS stents followed by FRED flow diverter treatment for dolichoectatic vertebrobasilar aneurysms (DVAs) may be one of the treatment options for controlling the growth of thrombotic aneurysms without complications, but the long-term prognosis of this case is unclear, and careful follow-up is mandatory.

**Keywords** ▶ dolichoectatic vertebrobasilar artery aneurysms, flow redirection endoluminal device, low-profile visualized intraluminal support stents

## Introduction

Dolichoectatic vertebrobasilar aneurysms (DVAs) are rare aneurysms characterized by pathologically dilated, elongated,

*Department of Neurosurgery, Graduate School of Biomedical and Health Sciences, Hiroshima University, Hiroshima, Hiroshima, Japan*

Received: June 27, 2022; Accepted: September 15, 2022

Corresponding author: Masahiro Hosogai. Department of Neurosurgery, Graduate School of Biomedical and Health Sciences, Hiroshima University, 1-2-3, Kasumi, Minami-ku, Hiroshima, Hiroshima 734-8551, Japan

Email: d192530@hiroshima-u.ac.jp



This work is licensed under a Creative Commons Attribution-NonCommercial-NoDerivatives International License.

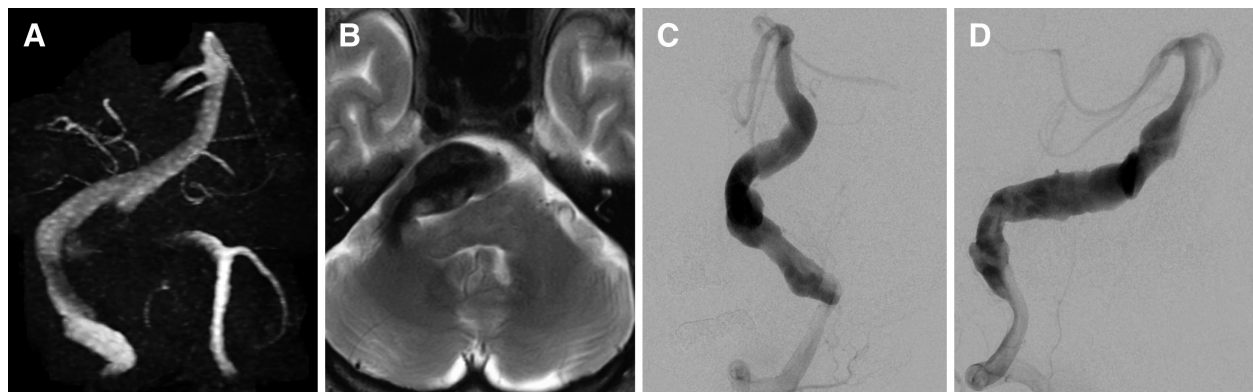
©2023 The Japanese Society for Neuroendovascular Therapy

and abnormally tortuous basilar and vertebral arteries. When treated conservatively, 80% of patients with DVA either become severely disabled or die within 5 years.<sup>1,2)</sup>

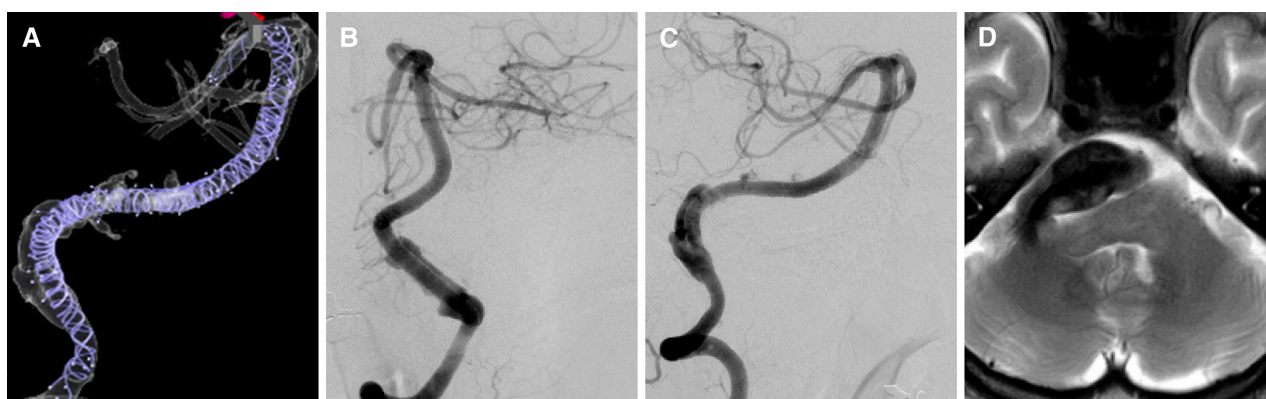There are currently no effective treatments for symptomatic patients with ischemia, hemorrhage, and compression due to DVA. In this study, we report a case of symptomatic DVA treated with multiple low-profile visualized intraluminal support (LVIS) stents (Terumo, Tokyo, Japan) followed by treatment with a flow redirection endoluminal device (FRED) (Terumo) flow diverter.

## Case Presentation

The patient was a 71-year-old man with a history of hypertension, cerebral infarction, and cardiac infarction. He was diagnosed 11 years ago with a thrombosed vertebrobasilar



**Fig. 1** (A) MRI showing a large dolichoectatic vertebrobasilar aneurysm. (B) MRI showing a giant mass effect around the brain stem. (C and D) Frontal and lateral views of right vertebral angiogram revealing the morphology of the aneurysm.



**Fig. 2** (A) Cone beam CT confirming that the overlapping stents were placed from the tip of the right posterior artery to the right vertebral artery. (B and C) Six months after surgery, DSA showed

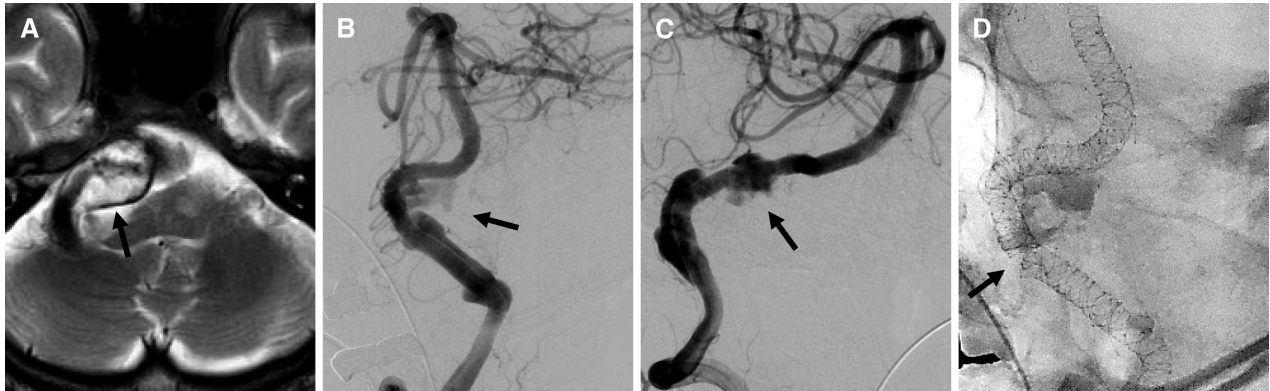favorable vascular remodeling with overlapping stenting. (D) Six months after surgery, MRI showed no enlargement in the thrombosed aneurysm.

artery aneurysm on MRI. During follow-up, the aneurysm gradually increased. About 11 years after the initial finding, diplopia due to left oculomotor nerve palsy was observed. On MRI (**Fig. 1A** and **1B**) and DSA (**Fig. 1C** and **1D**), a large, thrombosed aneurysm (37 mm in length) was found from the right vertebral artery to the basilar artery. This lesion was S-shaped and tortuous, and the pons was highly compressed.

### Initial treatment with multiple LVIS stents

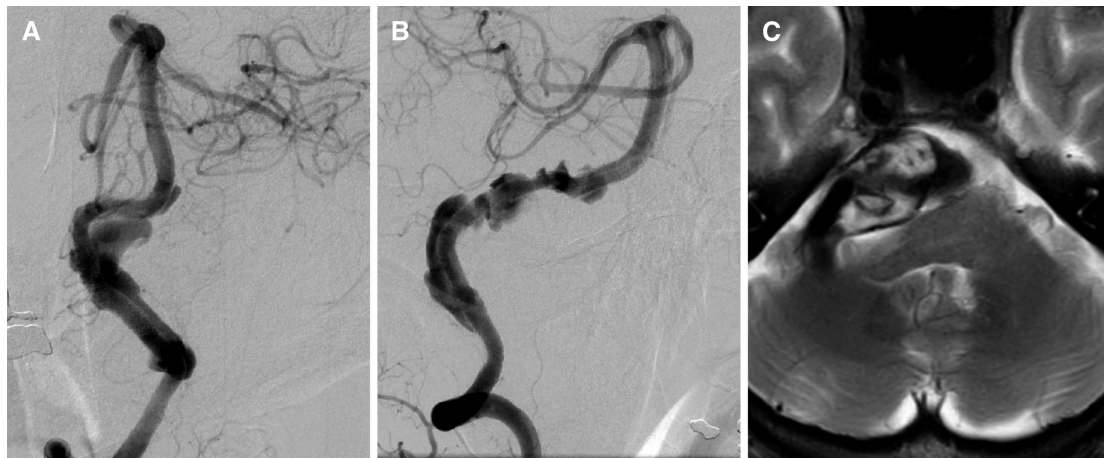
Dual antiplatelet agents (75 mg/day of clopidogrel and 100 mg/day of aspirin) were administered for 7 days before the procedure. Systemic heparinization was conducted under local anesthesia and an 8-Fr Fubuki 90-cm guiding catheter (ASAHI INTECC, Aichi, Japan) was guided to the V2 portion of the right vertebral artery via the right femoral artery. The distal access catheter, a 3.4-Fr TACTICS 130 cm (Technocrat, Aichi, Japan), was guided through the guiding catheter, and Headway 21 156 cm (Terumo) was placed in the right posterior cerebral artery. An

LVIS 4.0 × 28 mm was deployed from the right posterior cerebral artery to the tip of the basilar artery, and ten LVISs 4.5 × 32 mm were then deployed, overlapping with each other from the tip of the basilar artery to the right vertebral artery. Cone beam CT confirmed that the overlapping stents were placed in the targeted position (**Fig. 2A**). No new neurological deficit was noted the day after surgery, and MRI showed no ischemic lesions. The patient's course was favorable, and he was discharged with clinical symptoms on modified Rankin Scale score 1. Aspirin administration was completed 1 month after surgery, and clopidogrel was continued. Six months after surgery, DSA confirmed favorable vascular remodeling with overlapping stenting (**Fig. 2B** and **2C**), and MRI showed no enlargement in the thrombosed aneurysm (**Fig. 2D**). At 1 year and 7 months after surgery, MRI T2-weighted image showed a change in the signal intensity in the thrombosed aneurysm (**Fig. 3A**). DSA showed that the vessel becomes more tortuous and found inadequately overlapped stents and leakage of contrast outside the stent (**Fig. 3B–3D**).



**Fig. 3** (A) One year and seven months after surgery, MRI showed a change in signal intensity in the thrombosed aneurysm (arrow). (B–D) DSA showing that the vessel had become more tortuous, with

findings of inadequately overlapping stents and leakage of contrast outside the stent (arrows).



**Fig. 4** (A and B) One year after FRED placement, the contrast leakage outside the stent slightly increased on DSA. (C) One year after FRED placement, MRI showed no enlargement of the thrombosed aneurysm. FRED: flow redirection endoluminal device

### Retreatment with FRED flow diverter

As with the initial treatment, dual antiplatelet agents were administered. Systemic heparinization was conducted under local anesthesia and a 6-Fr Fubuki 90 cm guiding catheter was guided to the V2 portion of the right vertebral artery through the right femoral artery. A 5-Fr SOFIASELECT EX 115 cm (Terumo) distal access catheter was guided through the guiding catheter, and Headway 27 156 cm was placed in the basilar artery. A FRED 4.5 × 45 mm was deployed from the basilar artery to the right vertebral artery to cover the area where contrast is leaking out of the LVIS stents. Just like with the initial treatment, no complications occurred from the retreatment. The oral administration of aspirin and clopidogrel was continued for 6 months after the second treatment. One year after FRED placement, the contrast leakage outside the stent slightly increased on DSA (**Fig. 4A** and **4B**), but there was no enlargement of the thrombosed aneurysm

on MRI (**Fig. 4C**) or deterioration of the patient on the modified Rankin Scale score.

## Discussion

DVAs are uncommon aneurysms characterized by pathologically enlarged, elongated, and abnormally tortuous vertebral and basilar arteries. According to the literature, the incidence of DVAs is as low as 0.06%–5.8% in the population.<sup>3,4)</sup> The clinical symptoms caused by DVAs can be categorized as subarachnoid hemorrhage, ischemia, or compression of a cranial nerve or the brainstem. Cerebral ischemias, including brain infarction and transient ischemic attack, are the most common symptoms.<sup>5)</sup> Possible mechanisms include occlusion of the perforating artery originating from dolichoectatic aneurysms, thrombosis *in situ*, and embolization of the dolichoectatic artery. However, the rupture rate of DVAs is low. According to past reports, approximately



7% of DVA patients developed subarachnoid hemorrhage, with an annual rupture rate of 0.9%.<sup>6</sup> Compression of the surrounding structures in the vertebrobasilar region can cause brainstem compression syndromes such as monogenic polyneuropathy and hydrocephalus.<sup>7</sup> Studies evaluating the natural history of DVAs have reported progression in about half of patients who present with compression symptoms.<sup>7</sup>

DVAs are catastrophic life-threatening neurovascular diseases associated with high morbidity and mortality.<sup>8</sup> There is no consensus on a management strategy for DVAs.<sup>9</sup> Several studies have reported that the use of anticoagulation and antiplatelet therapy may increase the risk of DVA rupture, especially in aneurysms greater than 10 mm in diameter. However, patients with advanced thrombosis or distal embolism may benefit from anticoagulation and antiplatelet therapy.<sup>10,11</sup>

Currently, stent-only treatment using single or multiple stents, flow diversion, and stent-assisted coil embolization are the main treatment modalities for DVAs.<sup>12,13</sup> Conventional stents were initially designed to be used as an adjunctive technique to provide structural support for coil embolization of cerebral aneurysms. However, reducing intra-aneurysmal flow with conventional stents is usually too low to complete thrombosis of the aneurysm after treatment; this reduces the porosity of the stent and has been reported to promote favorable flow modification.<sup>14</sup> Therefore, the overlapping technique can increase the metal coverage of conventional stents and achieve good flow diversion of the aneurysm lumen. In fact, Kim et al. reported that overlapping could increase the metal coverage rate of the LVIS stents and achieve a flow diversion effect as large as that observed with a flow diverter.<sup>15</sup> At the time of initial treatment, our institution was not approved for the use of a flow diverter; therefore, we chose the overlapping stent technique to reconstruct the lumen of the diseased arteries and the stents were safely implanted with no ischemic or hemorrhagic complications. Wang et al. reported that among 22 patients with DVAs, the treatment modalities were stent-assisted coil in 11 (50%) patients, sole stent in 10 (45%), and parent artery occlusion in one (5%).<sup>16</sup> The major part of this report is the result of treatment with an Enterprise stent, and all patients had a good course except for one patient who had intraoperative complications. Wu et al. also reported that endovascular reconstruction with coil-assisted stent placement or stent placement alone in the vascular lumen for vertebrobasilar aneurysm is a feasible treatment option that can prevent ischemic events compared with the natural course.<sup>17</sup> Another report indicated that in 42 patients with large or giant non-saccular vertebrobasilar

aneurysms who received endovascular treatment with a pipeline flow diverter; the complication rate of treatment was 7.1% within a median follow-up of 28.8 months, and the complete occlusion rate was 90.2%.<sup>13</sup> In recent years, with the popularization of the flow diverter, reports on VDA treatment using flow diverters have increased.<sup>13,18,19</sup> The flow diverter has a metal strut that covers approximately 30% of the neck of the aneurysm. This dense coverage is designed to alter the flow of the aneurysm and allow it to occlude without an intra-aneurysmal coil.<sup>20</sup> The flow diverter is a viable treatment for aneurysms located in the posterior circulation where standard endovascular treatment is difficult or impossible.<sup>21</sup> In addition, a report has shown low incidence of branch occlusion after flow diverter coverage in most vessels.<sup>22</sup> Thus, the safety on the use of flow diverter in the treatment of VDAs has been verified.

On the other hand, in the present case, leakage of contrast medium outside the stent continued 1 year after the flow diverter placement. Suzuki et al. reported on the possibility of worsening flow diverting effects due to morphological changes in vessels with overlapping stents placed for partially thrombosed vertebral artery aneurysms using computational fluid dynamics analysis.<sup>23</sup> Similarly in the present case, the overlapping stents may have worsened the flow diverter effect in the vessel, resulting in residual leakage of the contrast medium outside the stent.

Past reports of treatment of VDAs with stents have been based on small sample sizes and short-term follow-up, and their long-term efficacy is uncertain. This is a short-term report of a total follow-up of 2 years and 7 months.

## Conclusion

Treatment with multiple LVIS stents followed by FRED flow diverter treatment for VDAs may be one of the treatment options for controlling the growth of thrombotic aneurysms without complications, but the long-term prognosis of this case is unclear, and careful follow-up is necessary in the future.

## Disclosure Statement

The authors declare that they have no conflicts of interest.

## References

- 1) Xu DS, Levitt MR, Kalani MYS, et al. Dolichoectatic aneurysms of the vertebrobasilar system: clinical and radiographic factors that predict poor outcomes. *J Neurosurg* 2018; 128: 560–566.

- 2) Wolters FJ, Rinkel GJ, Vergouwen MD. Clinical course and treatment of vertebrobasilar dolichoectasia: a systematic review of the literature. *Neurol Res* 2013; 35: 131–137.
- 3) Yu YL, Moseley IF, Pullicino P, et al. The clinical picture of ectasia of the intracerebral arteries. *J Neurol Neurosurg Psychiatry* 1982; 45: 29–36.
- 4) Pia HW. Classification of vertebro-basilar aneurysms. *Acta Neurochir (Wien)* 1979; 47: 3–30.
- 5) Lawton MT, Abla AA, Rutledge WC, et al. Bypass surgery for the treatment of dolichoectatic basilar trunk aneurysms: a work in progress. *Neurosurgery* 2016; 79: 83–99.
- 6) Passero SG, Rossi S. Natural history of vertebrobasilar dolichoectasia. *Neurology* 2008; 70: 66–72.
- 7) Flemming KD, Wiebers DO, Brown RD Jr., et al. The natural history of radiographically defined vertebrobasilar nonsaccular intracranial aneurysms. *Cerebrovasc Dis* 2005; 20: 270–279.
- 8) Debette S, Compter A, Labeyrie MA, et al. Epidemiology, pathophysiology, diagnosis, and management of intracranial artery dissection. *Lancet Neurol* 2015; 14: 640–654.
- 9) Jiang C, Li Q, Liu JM, et al. Endovascular treatment for the basilar artery dissection. *Cardiovasc Intervent Radiol* 2014; 37: 646–656.
- 10) Kobayashi N, Murayama Y, Yuki I, et al. Natural course of dissecting vertebrobasilar artery aneurysms without stroke. *AJNR Am J Neuroradiol* 2014; 35: 1371–1375.
- 11) Anson JA, Lawton MT, Spetzler RF. Characteristics and surgical treatment of dolichoectatic and fusiform aneurysms. *J Neurosurg* 1996; 84: 185–193.
- 12) Wang J, Liu XF, Li BM, et al. Application of parallel stent placement in the treatment of unruptured vertebrobasilar fusiform aneurysms. *J Neurosurg* 2017; 126: 45–51.
- 13) Wang J, Jia L, Duan Z, et al. Endovascular treatment of large or giant non-saccular vertebrobasilar aneurysms: pipeline embolization devices versus conventional stents. *Front Neurosci* 2019; 13: 1253.
- 14) Zang Y, Wang C, Zhang Y, et al. Long-term follow-up study of 35 cases after endovascular treatment for vertebrobasilar dissecting aneurysms. *Clin Neurol Neurosurg* 2015; 137: 121–131.
- 15) Kim S, Yang H, Hong I, et al. Computational study of hemodynamic changes induced by overlapping and compacting of stents and flow diverter in cerebral aneurysms. *Front Neurol* 2021; 12: 705841.
- 16) Wang J, Jia L, Yang X, et al. Outcomes in symptomatic patients with vertebrobasilar dolichoectasia following endovascular treatment. *Front Neurol* 2019; 10: 610.
- 17) Wu X, Xu Y, Hong B, et al. Endovascular reconstruction for treatment of vertebrobasilar dolichoectasia: long-term outcomes. *AJNR Am J Neuroradiol* 2013; 34: 583–588.
- 18) Tan LA, Moftakhar R, Lopes DK. Treatment of a ruptured vertebrobasilar fusiform aneurysm using pipeline embolization device. *J Cerebrovasc Endovasc Neurosurg* 2013; 15: 30–33.
- 19) Kerolus M, Kasliwal MK, Lopes DK. Persistent aneurysm growth following pipeline embolization device assisted coiling of a fusiform vertebral artery aneurysm: a word of caution! *Neurointervention* 2015; 10: 28–33.
- 20) Kallmes DF, Ding YH, Dai D, et al. A second-generation, endoluminal, flow-disrupting device for treatment of saccular aneurysms. *AJNR Am J Neuroradiol* 2009; 30: 1153–1158.
- 21) Bender MT, Colby GP, Jiang B, et al. Flow diversion of posterior circulation cerebral aneurysms: a single-institution series of 59 cases. *Neurosurgery* 2019; 84: 206–216.
- 22) Adeeb N, Griessenauer CJ, Dmytriw AA, et al. Risk of branch occlusion and ischemic complications with the pipeline embolization device in the treatment of posterior circulation aneurysms. *AJNR Am J Neuroradiol* 2018; 39: 1303–1309.
- 23) Suzuki T, Hasegawa H, Ando K, et al. Possibility of worsening flow diversion effect due to morphological changes of a stented artery with multiple overlapping stents for partially thrombosed vertebral artery aneurysms. *Front Neurol* 2020; 11: 611124.