

# Altered consciousness with transient abnormal signals in the hippocampus: A case report

SAGE Open Medical Case Reports  
Volume 9: 1–4  
© The Author(s) 2021  
Article reuse guidelines:  
sagepub.com/journals-permissions  
DOI: 10.1177/2050313X211054644  
journals.sagepub.com/home/sco



Koshi Ota , Tomonobu Nishii, Kensuke Fujii, Yasuo Oishi, Naoya Onishi, Kanna Ota, Hiroki Yokoyama and Akira Takasu

## Abstract

Hippocampal infarction is relatively rare. Many different diseases can mimic hippocampal infarction including transient global amnesia, Alzheimer's disease, epilepsy, encephalitis, and encephalopathies. An 89-year-old man was transported to our hospital for altered consciousness. Diffusion-weighted magnetic resonance imaging revealed slightly intense signals in the hippocampus with a mildly decreased apparent diffusion coefficient. Serial magnetic resonance imaging revealed features of hippocampal infarction. Symptoms and cognitive function gradually improved with rehabilitation, and he was transferred to a rehabilitation facility on Hospital Day 38. Hippocampal infarction is rare in patients with altered mental status, but should be considered when magnetic resonance imaging shows findings suggestive of this condition. Other differential diseases should be ruled out by serial magnetic resonance imaging and observation of the clinical course.

## Keywords

Amnesia, cerebral infarction, consciousness, hippocampus, magnetic resonance imaging

Date received: 28 June 2021; accepted: 4 October 2021

## Introduction

Blood supply to the hippocampus is mainly from the posterior cerebral artery (PCA) and sometimes from the anterior choroidal artery. The vascular territory supplied by the PCA includes thalamus, mesencephalon, splenium of the corpus callosum, occipital lobe, parts of the temporal and parietal lobes, and hippocampus.

The incidence of PCA infarction is estimated to be between 5% and 10% of all ischemic strokes.<sup>1</sup> Thus, hippocampal infarction (HI) is relatively rare, which accounted for 0.03% of all strokes,<sup>2</sup> and a few studies about HI have been published. Many different diseases can mimic HI, including transient global amnesia (TGA), Alzheimer's disease, epilepsy, encephalitis, and encephalopathies.

Magnetic resonance imaging (MRI) is an essential imaging modality to detect the cause of sudden onset of altered consciousness. Diffusion-weighted imaging (DWI) MRI abnormalities located in the hippocampus have been reported in acute neurological disorders. Characteristic features of hippocampal abnormalities seen on DWI may give diagnostic clues in differentiating the underlying pathology. Here, we describe a previously cognitively normal elderly patient with HI.

## Case report

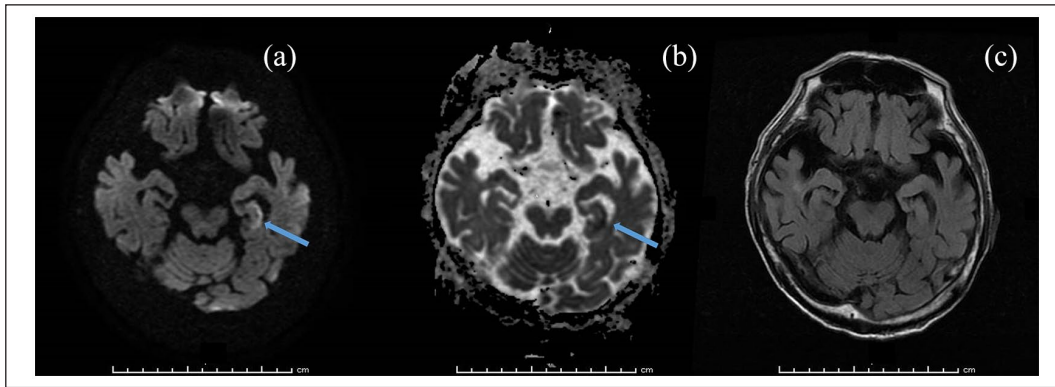
An 89-year-old man with previously normal cognitive function was transported to our hospital for altered consciousness. His wife found him unresponsive one morning when he failed to rise at his usual time. When the Emergency Medical Service arrived, he was not responsive to any stimulation. His past medical history was notable for hypertension, old cerebral infarction (CI), post-percutaneous coronary intervention, chronic pleuritis, and benign prostate hypertrophy. His medications included aspirin 100 mg, candesartan cilexetil 4 mg, allopurinol 100 mg, benidipine 4 mg, famotidine 20 mg, ticlopidine 100 mg, nicorandil 5 mg, and diltiazem 30 mg. He was cognitively active as he worked as a trade consultant until the day before his admission. He smoked half a pack of cigarettes for 60 years.

Department of Emergency Medicine, Osaka Medical College, Takatsuki, Japan

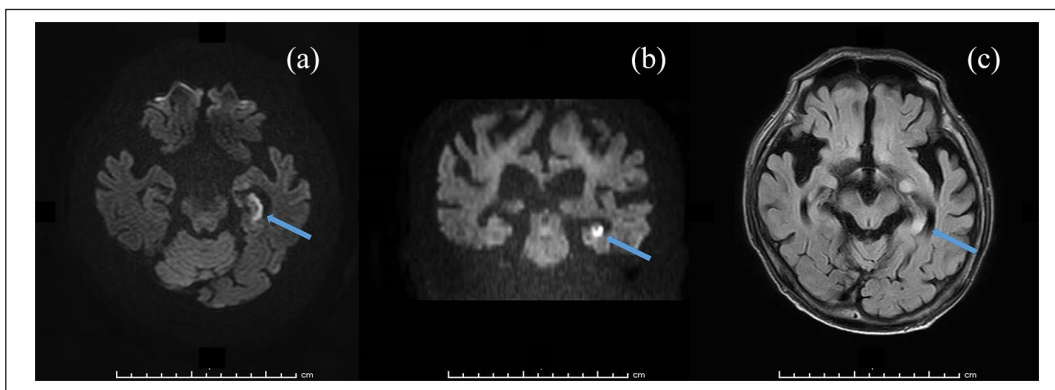
### Corresponding Author:

Koshi Ota, Department of Emergency Medicine, Osaka Medical College, 2-7 Daigaku-machi, Takatsuki 596-8686, Osaka, Japan.  
Email: emm006@osaka-med.ac.jp





**Figure 1.** A high signal on diffusion-weighted imaging (DWI) and a reduction in the apparent diffusion coefficient in the lateral aspect of the hippocampus (a and b). Fluid-attenuated inversion recovery (FLAIR) showed no change in the hippocampus (c).



**Figure 2.** An intense high signal on DWI in both axial and coronal views in the lateral aspect of the hippocampus (a and b). FLAIR showed a high signal in the hippocampus (c).

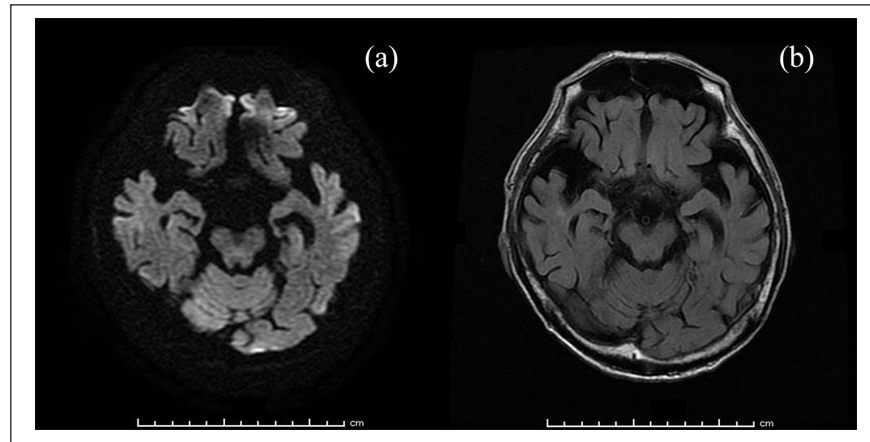
His vital signs upon arrival at the Emergency Department were: temperature, 37.8°C; heart rate, 104 beats per minute; respiratory rate, 32 breaths per minute; blood pressure, 167/106 mmHg; oxygen saturation, 100% on oxygen mask at 6L/min. His conscious level was Glasgow Coma Scale 9 (eye opening 4, best verbal response 1, and best motor response 4). He did not respond to pain, but opened his eyes without stimulation. On physical examination, the patient was well appearing and in no apparent distress. Proper neurological assessment was incomplete due to poor patient compliance. Reflexes were normal bilaterally in the biceps, triceps, brachioradialis, and patellar and Achilles tendons. Babinski sign was absent bilaterally.

Cerebrospinal fluid (CSF) obtained via lumbar puncture on the day of admission were: white blood cell count (WBC), 2 cells/mm<sup>3</sup>; red blood cell count (RBC), 238 cells/mm<sup>3</sup>; total protein, 41.6 (normal=15–45) mg/dL; glucose, 80 (normal=70–110) mg/dL. Hematological and biochemical investigations including tests for autoimmune-associated vasculitis, infections, and hypercoagulopathies showed leukocytosis (WBC count=12,040/mm<sup>3</sup> with 94.6% neutrophils) and elevated C-reactive protein (1.84 mg/dL). Leukocytosis and mildly elevated C-reactive protein were

due to mild aspiration pneumonia. Test for autoimmune-associated vasculitis—for example, anti DNA antibody or Myeloperoxidase anti-neutrophil cytoplasmic antibody (MPO ANCA)—was all negative. Serum ammonia was mildly elevated at 53 (normal=15–45) µg/dL, but other liver enzymes were normal except for lactate dehydrogenase (LDH) 379 (normal=124–222) U/L. Urine toxicology screening was negative for opioids, benzodiazepines, or other prohibited substances. Initial MRI with DWI revealed abnormal signals in the hippocampus with a slightly decreased apparent diffusion coefficient, and no change was seen in the hippocampus with fluid-attenuated inversion recovery (FLAIR) (Figure 1(a)–(c)).

On Hospital Day 2, he could speak naturally, but could not state the date and place correctly. Repeat MRI with DWI on Hospital Day 4 revealed hyperintense signals predominantly in the hippocampus with hyperintense signals on FLAIR in the same location (Figure 2(a)–(c)). The third MRI with DWI and FLAIR showed a very mild signal change in the hippocampus on Hospital Day 13 (Figure 3(a) and (b)).

No epileptiform discharges were recorded on electroencephalogram (EEG), and clinical seizures were not observed during his hospitalization. Mini Mental State Examination



**Figure 3.** Shows almost no signal changes in the hippocampus on DWI and FLAIR (a and b).

(MMSE) is used for mental status examination worldwide, and the Revised Hasegawa's Dementia Scale (HDS-R) is also widely used to measure cognitive function in Asia.<sup>3,4</sup> Both tests were repeated serially to measure his cognitive function over time. MMSE and HDS-R scores on Hospital Day 9 were 22/30 and 12/30, respectively. He underwent physical rehabilitation, and the second MMSE and HDS-R scores on Hospital Day 16 were 25/30 and 14/30, respectively. This result suggested that his memory function was impaired. Finally, his HDS-R on Hospital Day 37 was 19/30, indicating improvement with residual memory impairment. He was transferred to a rehabilitation facility on Hospital Day 38.

## Discussion

HI due to vascular derangement of the PCA is relatively rare, and the diagnosis is challenging in patients presented with altered consciousness. Statistics show mean age of HI patients is 70 years.<sup>5</sup> Hypertension, coronary heart disease, tobacco use, and transient ischemic attack or stroke have been reported as co-morbidities of HI.<sup>5</sup> Our patient was 89 years old and had all the aforementioned co-morbidities of HI, and his laboratory findings including a CSF study revealed no evidence of encephalitis or encephalopathy.

HI typically manifests as memory impairment, clinically similar to TGA as well as disorientation and general confusion. The symptom of amnesia is usually mild. CSF findings of a previous study cited were similar to those of our study except for red blood cells, which were less than ours due to traumatic tap of our specimen.<sup>6</sup> CI including HI usually do not exhibit abnormality in the findings of CSF except for perhaps increased cytokine levels in CSF and blood of CI patients.<sup>7</sup> However, since we did not check the level of inflammatory cytokines, it is not possible to comment on the effect of HI on cytokine levels in CSF.

Emergency physicians must consider HI when encountering a patient with MRI abnormalities in the hippocampus. Previous case report of an elderly male showed an apparent

high-intensity diffusion-weighted sequence in the hippocampal region.<sup>8</sup> However, early MRI finding is usually ambiguous, and distinguishing HI from other similar diseases like TGA and epilepsy is somewhat difficult. In the previous HI case cited, MRI finding was due to thrombosis of atrial fibrillation; hence, infarction was apparent.<sup>8</sup> However, our case was secondary to atherosclerosis and MRI finding was ambiguous at first, but repeat MRI revealed hyperintense signals in the hippocampus. Mismatched findings on DWI-FLAIR are also seen in patients with TGA; however, they usually appear 2 days after the onset of the episode.<sup>9</sup> Epilepsy, especially temporal epilepsy, was another differential diagnosis we entertained.<sup>10,11</sup> However, no seizure activities were observed at home or during hospitalization, and EEG did not show epileptiform discharges. The early high-intensity signal in the lateral hippocampus also resembled epilepsy, which was excluded by history, EEG, and physical findings. Improvements in patient's cognitive function were observed with MMSE and HDS-R, but HDS-R was still less than 21 throughout hospitalization. The gradual improvement was likely due to mild nature of infarction and damage limited to the lateral areas. Thus, his memory recall was impaired first, and then gradually recovered spontaneously with improvements in MRI findings.

## Conclusion

In conclusion, a single MRI scan was insufficient to diagnose HI. TGA and epilepsy must be considered, although serial MRI and assessment of the clinical course may provide diagnostic clues leading to an accurate diagnosis. HI is relatively rare, but incidence is expected to increase with the increasing elderly population. Emergency physicians should be clinically suspicious of HI when changes are seen on serial MRI findings.

## Declaration of conflicting interests

The author(s) declared no potential conflicts of interest with respect to the research, authorship, and/or publication of this article.

### Ethical approval

Our institution does not require ethical approval for reporting individual cases or case series.

### Funding

The author(s) received no financial support for the research, authorship, and/or publication of this article.

### Informed consent

The authors obtained verbal and written informed consent from the patient for reporting this case. Written informed consent was obtained from the patient for his anonymized information to be published in this article after he recovered completely and also verbal consent and written informed consent were obtained from his wife.

### ORCID iD

Koshi Ota  <https://orcid.org/0000-0002-1461-7031>

### References

1. Cereda C and Carrera E. Posterior cerebral artery territory infarctions. *Front Neurol Neurosci* 2012; 30: 128–131.
2. Kumral E, Deveci EE, Erdoğan C, et al. Isolated hippocampal infarcts: vascular and neuropsychological findings. *J Neurol Sci* 2015; 356(1–2): 83–89.
3. Trivedi D. Cochrane review summary: mini-mental state examination (MMSE) for the detection of dementia in clinically unevaluated people aged 65 and over in community and primary care populations. *Prim Health Care Res Dev* 2017; 18(6): 527–528.
4. Kounnavong S, Ratsavong K, Soundavong K, et al. Cognitive function measured with the Revised Hasegawa's Dementia Scale among elderly individuals in Lao PDR. *Nagoya J Med Sci* 2019; 81(2): 281–290.
5. Förster A, Al-Zghloul M, Eisele P, et al. Hippocampal infarction: identification of three new types. *J Neuroradiol* 2018; 45(1): 1–5.
6. Adler AC, Warum D and Sapire JM. Transient global amnesia caused by hippocampal infarct: case report and review of literature. *Clin Imaging* 2012; 36(5): 584–586.
7. Lambertsen KL, Biber K and Finsen B. Inflammatory cytokines in experimental and human stroke. *J Cereb Blood Flow Metab* 2012; 32(9): 1677–1698.
8. Uriu Y and Kuriyama A. Hippocampal infarction. *Postgrad Med J* 2020; 96(1133): 166.
9. Scheel M, Malkowsky C, Klingebiel R, et al. Magnetic resonance imaging in transient global amnesia: lessons learned from 198 cases. *Clin Neuroradiol* 2012; 22(4): 335–340.
10. Förster A, Griebe M, Gass A, et al. Diffusion-weighted imaging for the differential diagnosis of disorders affecting the hippocampus. *Cerebrovasc Dis* 2012; 33(2): 104–115.
11. Monaco F, Mula M and Cavanna AE. Consciousness, epilepsy, and emotional qualia. *Epilepsy Behav* 2005; 7(2): 150–160.