

Common carotid macrothrombosis causing acute ischaemic stroke in a patient with COVID-19

Maria A Parekh ¹, Carlos DeLaGarza,¹ Jeremiah Johnson²

¹Neurology, Baylor College of Medicine, Houston, Texas, USA
²Neurosurgery, Baylor College of Medicine, Houston, Texas, USA

Correspondence to

Dr Maria A Parekh;
m.afirdi.parekh@gmail.com

Accepted 12 July 2021

DESCRIPTION

A 50-year-old woman with a medical history significant only for well-controlled hypertension and recent SARS-CoV-2-positive test presented as a stroke alert for aphasia and right hemiparesis with a National Institutes of Health Stroke Scale score of 20. She was out of the window for thrombolytic therapy. CT head did not reveal any acute abnormalities, with an ASPECTS (Alberta Stroke Program Early CT Score) of 10. CT angiogram demonstrated a focal area of soft plaque within the left common carotid artery, for which the patient was taken to the angiography suite immediately. A diagnostic cerebral angiogram revealed a non-occlusive non-flow-limiting thrombus within the left common carotid artery measuring approximately 2.5 cm caudal to the left carotid bifurcation ([figure 1](#)), with additional findings of a regional perfusion defect within the left M4 cortical branches suspected to be embolic from the carotid thrombus. Thrombectomy was not attempted given concern of clot fragility and the high risk of fragmentation and emboli during manipulation. A non-contrast MRI brain revealed ischaemic infarct in the left distal middle cerebral artery (MCA) territory and external watershed zones of the anterior cerebral artery/MCA and MCA/posterior cerebral artery ([figure 2](#)). Standard serological tests and coagulation markers were sent in addition to standard stroke etiological workup, without any radiographic or echocardiographic evidence of a proximal source of thromboembolism, and the aetiology of her stroke was attributed to macrothrombosis secondary to SARS-CoV-2-related endotheliopathy. She was initiated on heparin infusion and later transitioned to apixaban, which she continued on discharge to inpatient rehabilitation. Follow-up in clinic was planned after repeat CT angiography to document thrombus resolution.

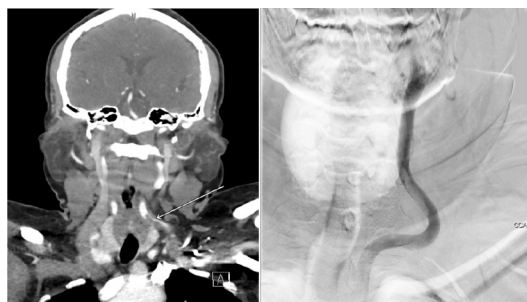

Figure 1 Left common carotid macrothrombosis on CT angiography and left carotid injection on digital subtraction angiography.

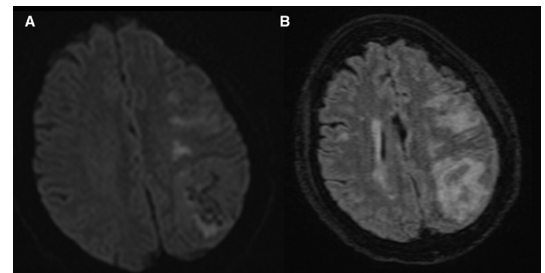
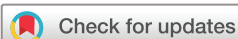

Figure 2 MRI brain without contrast with acute ischaemic infarct in the left distal MCA territory and external watershed zones of the ACA/MCA and MCA/PCA on (A) DWI and (B) FLAIR sequences. ACA, anterior cerebral artery; DWI, diffusion-weighted imaging; FLAIR, fluid-attenuated inversion-recovery; MCA, middle cerebral artery; PCA, posterior cerebral artery.

Prior studies have shown that the extent of coagulopathy correlates with severity of respiratory illness,¹ predominant sequelae of which include venous thromboembolic events, end-organ failure secondary to a microangiopathy believed to be similar to disseminated intravascular coagulation,² and stroke which was seen in 5.7% of those with critical illness in comparison to 0.8% of those with milder COVID-19 disease.³ Tested for suspected exposure to SARS-CoV-2, our patient had no respiratory or infectious symptoms, suggesting that in addition to the previously characterised venous thrombosis and microangiopathy associated with SARS-CoV-2 infection, there may also be a tendency towards large-vessel arterial thrombosis, which may be secondary to virally mediated disruption of the endothelium causing endotheliitis.⁴ A case series of three SARS-CoV-2-infected individuals with mild respiratory symptoms and stroke secondary to large-vessel thrombosis without occlusion has been previously reported,⁵ with the aetiology of coagulopathy attributed to virus-mediated endotheliopathy. Given the significant implications for primary and secondary stroke prevention in patients with COVID-19, further systematic studies are needed to establish the role of anti-inflammatory agents and anticoagulants, if any.

Twitter Maria A Parekh @MariaParekh

Contributors All authors contributed equally to the conception and design, acquisition of data or analysis and interpretation of data, and approved the final version for publication. CDLG and MAP drafted the article, and MAP and JJ revised it critically for important intellectual content. The corresponding author, MAP, takes full responsibility for the data, interpretation and the conduct of the research; has full access to all of the data; and has the right to publish any and all data separate and apart from any sponsor.



© BMJ Publishing Group Limited 2021. No commercial re-use. See rights and permissions. Published by BMJ.

To cite: Parekh MA, DeLaGarza C, Johnson J. *BMJ Case Rep* 2021;**14**:e245081. doi:10.1136/bcr-2021-245081

Learning points

- ▶ Mechanisms of coagulopathy in SARS-CoV-2 infection include previously characterised venous thrombosis and microangiopathy, with the extent of coagulopathy correlating to the severity of respiratory symptoms, as demonstrated by stroke inflicting 5.7% of critically ill patients compared with 0.8% with milder COVID-19 disease.
- ▶ Coagulopathy in the absence of respiratory symptoms in a patient with COVID-19 suggests a tendency toward large-vessel arterial thrombosis, secondary to virally mediated endotheliitis, as demonstrated in this case.

Funding The authors have not declared a specific grant for this research from any funding agency in the public, commercial or not-for-profit sectors.

Competing interests None declared.

Patient consent for publication Obtained.

Provenance and peer review Not commissioned; externally peer reviewed.

This article is made freely available for use in accordance with BMJ's website terms and conditions for the duration of the covid-19 pandemic or until otherwise determined by BMJ. You may use, download and print the article for any lawful, non-commercial purpose (including text and data mining) provided that all copyright notices and trade marks are retained.

ORCID iD

Maria A Parekh <http://orcid.org/0000-0003-0465-8400>

REFERENCES

- 1 Tang N, Bai H, Chen X, *et al.* Anticoagulant treatment is associated with decreased mortality in severe coronavirus disease 2019 patients with coagulopathy. *J Thromb Haemost* 2020;18:1094–9.
- 2 Campbell CM, Kahwash R. Will complement inhibition be the new target in treating COVID-19-Related systemic thrombosis? *Circulation* 2020;141:1739–41.
- 3 Mao L, Jin H, Wang M, *et al.* Neurologic manifestations of hospitalized patients with coronavirus disease 2019 in Wuhan, China. *JAMA Neurol* 2020;77:683–9.
- 4 Varga Z, Flammer AJ, Steiger P, *et al.* Endothelial cell infection and endotheliitis in COVID-19. *Lancet* 2020;395:1417–8.
- 5 Fara MG, Stein LK, Skliut M, *et al.* Macrothrombosis and stroke in patients with mild Covid-19 infection. *J Thromb Haemost* 2020;18:2031–3.

Copyright 2021 BMJ Publishing Group. All rights reserved. For permission to reuse any of this content visit <https://www.bmj.com/company/products-services/rights-and-licensing/permissions/>
BMJ Case Report Fellows may re-use this article for personal use and teaching without any further permission.

Become a Fellow of BMJ Case Reports today and you can:

- ▶ Submit as many cases as you like
- ▶ Enjoy fast sympathetic peer review and rapid publication of accepted articles
- ▶ Access all the published articles
- ▶ Re-use any of the published material for personal use and teaching without further permission

Customer Service

If you have any further queries about your subscription, please contact our customer services team on +44 (0) 207111 1105 or via email at support@bmj.com.

Visit casereports.bmj.com for more articles like this and to become a Fellow