

Diffuse redness in linked color imaging is useful for diagnosing current *Helicobacter pylori* infection in the stomach

Masaya Iwamuro MD, PhD  | Hiroyuki Sakae MD | Hiromitsu Kanzaki MD, PhD | Hiroyuki Okada MD, PhD

Department of Gastroenterology and Hepatology, Okayama University Graduate School of Medicine, Dentistry, and Pharmaceutical Sciences, Okayama, Japan

Correspondence

Masaya Iwamuro, Department of Gastroenterology and Hepatology, Okayama University Graduate School of Medicine, Dentistry, and Pharmaceutical Sciences, Okayama, Japan.

Email: iwamuromasaya@yahoo.co.jp

KEYWORDS: esophagogastroduodenoscopy, *Helicobacter pylori*, Kyoto classification of gastritis

A 67-year-old Japanese man was diagnosed with gastritis following a barium swallow examination, which was performed as an annual screening procedure. He was referred to our hospital for further investigation. Serological testing revealed a negative *Helicobacter pylori* antibody. Esophagogastroduodenoscopic examination (EG-L600ZW; FUJIFILM Medical Co., Ltd., Tokyo, Japan) revealed atrophic gastritis and intestinal metaplasia. Endoscopic examination performed using linked color imaging showed diffuse mucosal redness in the gastric body, which appeared as a deep red (crimson) mucosa in the area of the fundic glands (Figure 1A). Linked color imaging also showed obvious differences in the mucosal color between areas with diffuse redness (areas with active gastritis) and those that appeared clear white (areas with mucosal atrophy) (Figure 1B). The diffuse redness of the gastric body mucosa was less evident using conventional white light imaging (Figure 2). Spotty redness, mucosal swelling, regular arrangement of collecting venules in the angle, and

fundic gland polyps were absent. Based on the presence of the diffuse redness, we performed a urea breath test, which was observed to be positive for *H. pylori* infection. Thus, subsequently, the patient underwent *H. pylori* eradication therapy.

In this patient, despite the negative serological test for *H. pylori* antibody, the findings of an endoscopic examination using linked color imaging prompted us to perform the urea breath test. Eventually, we could prove the presence of current *H. pylori* infection in this patient. Sensitivity of the serum *H. pylori* antibody test is reportedly 78%-100%.¹ Thus, this patient showed a false-negative result to serum antibody testing. In such patients, endoscopic examination plays an important role in identifying current *H. pylori* infection, that is, active gastritis. Several researchers have stated that diffuse redness is the most important endoscopic finding associated with active gastritis.^{2,3} The sensitivity of diffuse redness for diagnosing *H. pylori* infection is reportedly 83.4%, specificity is 66.9%,

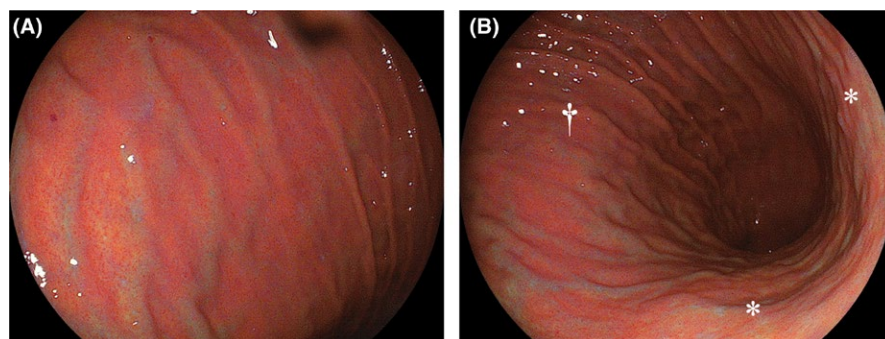


FIGURE 1 Endoscopic images using linked color imaging. Esophagogastroduodenoscopic examination shows diffuse redness of the mucosa of the gastric body, which can be identified as a deep reddish color (A). An obvious difference can be observed in the mucosal color between areas with diffuse redness (B, dagger) and areas showing mucosal atrophy (B, asterisks)

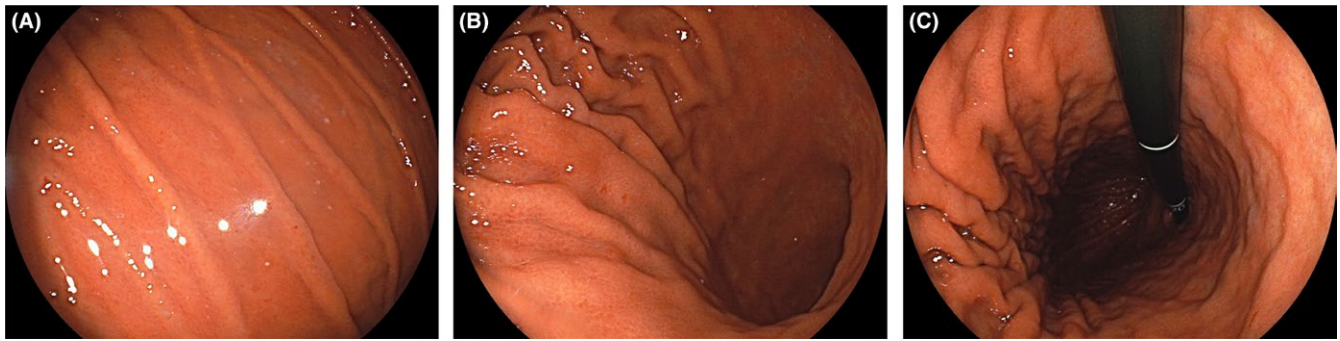


FIGURE 2 Endoscopic images using conventional white light imaging. Diffuse redness of the mucosa of the gastric body is less evident compared with linked color imaging

positive predictive value is 73.8%, and negative predictive value is 78.4%.² Other findings associated with active *H. pylori* infection include spotty redness and mucosal swelling. However, as spotty redness and mucosal swelling were absent in the presented patient, diffuse redness was the sole key feature.

Linked color imaging is a technology that processes the captured image to provide images with color enhancement of reddish hues, such that red areas appear vivid red and white areas appear clear white.⁴ Reportedly, using linked color imaging, the fundic gland mucosa shows diffuse redness (deep crimson red) in patients with active gastritis and appears light orange in color (the color of white apricots) in the *H. pylori*-eradicated stomach.³ Thus, linked color imaging technology is expected to provide useful information to endoscopists to promptly diagnose the *H. pylori* infection status of the stomach.

In conclusion, the present case underscores the importance of diffuse redness as a key endoscopic feature that enables prompt diagnosis of current *H. pylori* infection. Notably, the novel linked color imaging technique probably scores over conventional ones in detecting diffuse redness.

CONFLICT OF INTEREST

The authors have stated explicitly that there are no conflicts of interest in connection with this article.

ORCID

Masaya Iwamuro  <http://orcid.org/0000-0002-1757-5754>

REFERENCES

1. Biranjia-Hurdoyal SD, Seetulsingh-Goorah SP. Performances of four *Helicobacter pylori* serological detection kits using stool antigen test as gold standard. *PLoS ONE*. 2016;11:e0163834.
2. Kato T, Yagi N, Kamada T, et al. Diagnosis of *Helicobacter pylori* infection in gastric mucosa by endoscopic features: a multicenter prospective study. *Dig Endosc*. 2013;25:508–18.
3. Dohi O, Yagi N, Onozawa Y, et al. Linked color imaging improves endoscopic diagnosis of active *Helicobacter pylori* infection. *Endosc Int Open*. 2016;4:E800–5.
4. Kanzaki H, Takenaka R, Kawahara Y, et al. Linked color imaging (LCI), a novel image-enhanced endoscopy technology, emphasizes the color of early gastric cancer. *Endosc Int Open*. 2017;5:E1005–13.

How to cite this article: Iwamuro M, Sakae H, Kanzaki H, Okada H. Diffuse redness in linked color imaging is useful for diagnosing current *Helicobacter pylori* infection in the stomach. *J Gen Fam Med*. 2018;19:176–177. <https://doi.org/10.1002/jgf2.195>