

Available online at [www.sciencedirect.com](http://www.sciencedirect.com)

ScienceDirect

journal homepage: [www.e-jds.com](http://www.e-jds.com)

## Correspondence

# Multiple variations of bilateral mandibular canals: A case report using cone-beam computed tomography



## KEYWORDS

Anatomic variations;  
Bilateral;  
Cone-beam computed  
tomography;  
Mandibular canal

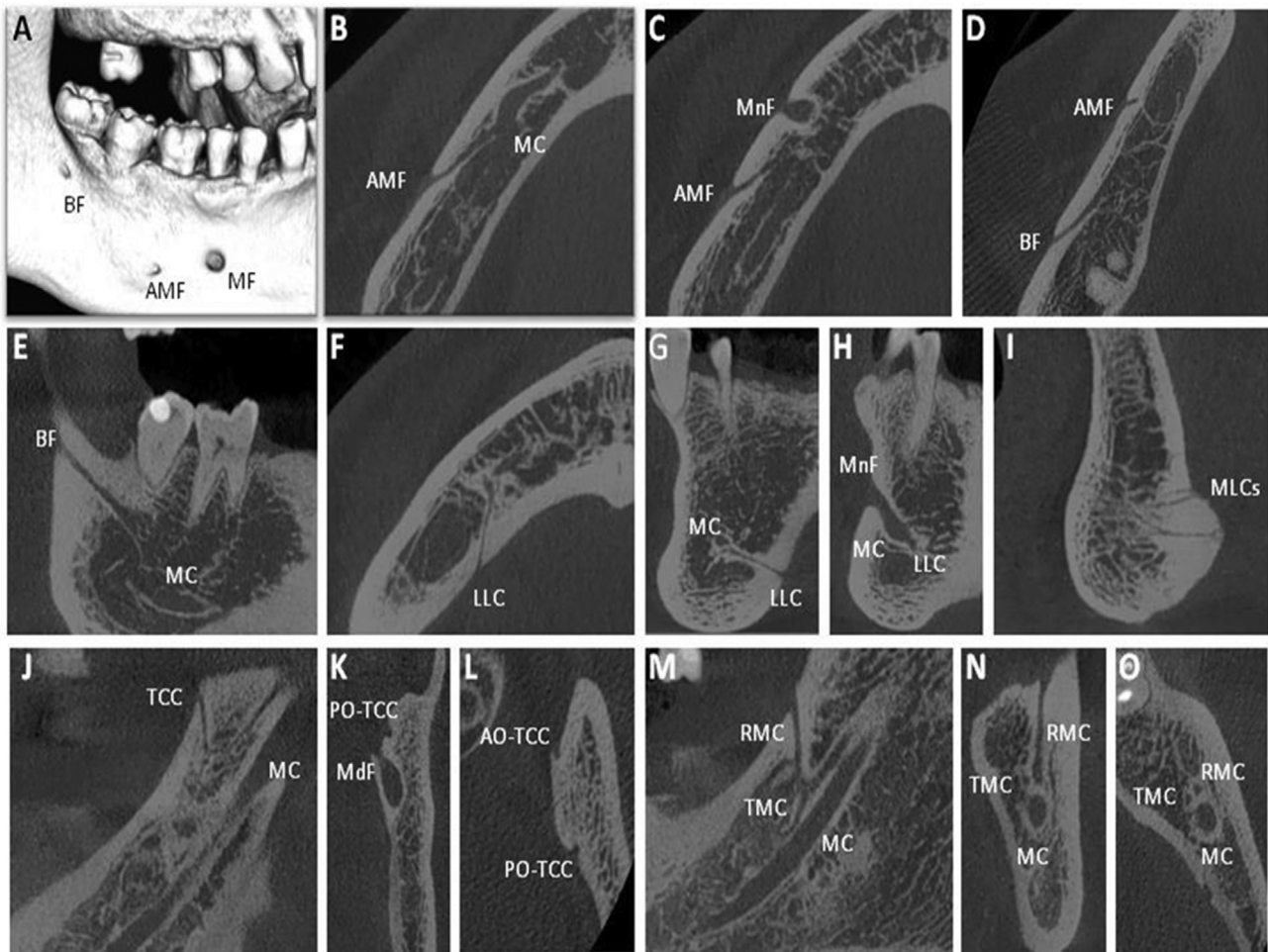
An awareness of variations of neurovascular canals and foramina in oromaxillofacial region is crucial for oral surgical procedures. Damage to these structures can cause serious complications, including hemostatic problems (profuse bleeding, hematoma) and neurologic deficits (hypoesthesia, paraesthesia, dysesthesia).<sup>1–5</sup> Various anatomical variations of mandibular canal (MC) have been described, including bifid/trifid mandibular canal (BMC/TMC),<sup>1</sup> retromolar canal (RMC),<sup>3</sup> temporal crest canal (TCC),<sup>2</sup> accessory mental foramen (AMF),<sup>1,4,5</sup> buccal foramen (BF),<sup>1</sup> medial lingual canal and foramen (MLC),<sup>1</sup> and lateral lingual canal and foramen (LLC).<sup>1,4</sup> The incidence reported in published studies for each variation varies greatly, depending on study design and race.<sup>1–5</sup> Review of English literature, the frequency is 0.08–64.8% for BMC,<sup>1</sup> 8.5–75.4% for RMC,<sup>3</sup> 0.3–5.6% for TCC,<sup>2</sup> 0.12–30% for AMF,<sup>5</sup> 44% for BF<sup>1</sup> and 14–80% for LLC.<sup>4</sup> Here, we present an uncommon case with multiple neurovascular variations in bilateral mandibular canals using cone-beam computed tomography (CBCT).

A 27-year-old male patient visited the Endodontic Division of Kaohsiung Medical University Hospital, complaining biting pain on the lower left teeth for 20 days after trauma. He underwent radiographic evaluation using CBCT (NewTom VGi evo, Milan, Italy; field of view: 12 × 8 cm, first scout view: 110 kV, 21.51 mA, second scout view: 110 kV, 30.00 mA, original axial thickness: 0.150 mm, exposure

time: 6.0 s) for detection of root fracture and apical lesions of related teeth. Apart from the mental foramen, the reformatted 3D CBCT image (Fig. 1A) shows two smaller accessory foramina on the buccal surface of right mandible. One locates posterior to the mental foramen and another locates near tooth 48. The axial and sagittal views (Fig. 1D and E) demonstrate that an accessory canal originates from right mandibular canal at tooth 46 apical area and extends to tooth 48 (buccal side), forming a buccal foramen. Other views (Fig. 1B–C, F–H) reveal two accessory canals branching from the right mandibular canal before it turns to the mental foramen. One extends to buccal surface of tooth 46, forming an accessory mental foramen. The other runs to lingual surface of tooth 45, called lateral lingual canal and foramen. The midsection of mandibular symphysis (Fig. 1I) discloses multiple medial lingual canals and foramina. In the left mandibular ramus, double canals are discovered in Fig. 1J–L. The inferior one is mandibular canal and the superior one is temporal crest canal with posterior opening locating above the mandibular foramen and anterior opening locating anterior to the temporal crest. Trifid of the left mandibular canal is found in the left mandibular body. It first ramifies a superior branch and then the branch further bifurcates into two canals. The buccal one turns upward and exits in the left retromolar region, indicating a retromolar canal. The lingual one runs forward, suggesting a forward trifid mandibular canal.

<https://doi.org/10.1016/j.jds.2022.05.020>

1991-7902/© 2022 Association for Dental Sciences of the Republic of China. Publishing services by Elsevier B.V. This is an open access article under the CC BY-NC-ND license (<http://creativecommons.org/licenses/by-nc-nd/4.0/>).



**Figure 1** The reformatted 3D, axial, coronal, sagittal images of cone-beam computed tomography of bilateral mandibular canals. The reformatted 3D image (A) shows an accessory mental foramen (AMF) locating posterior to the right mental foramen (MnF), and a buccal foramen (BF) locating at tooth 48 (buccal side). The axial views (B, C, D) and coronal view (E) show the relation between these accessory formations and the right mandibular canal (MC). The axial views (F, L, O), coronal views (H, K, N) and sagittal views (G, I, J, M) show a lateral lingual canal (LLC) in the right mandibular body, multiple medial lingual canals (MLCs) at midline of anterior mandible, a temporal crest canal (TCC, AO-TCC: anterior opening of TCC, PO-TCC: posterior opening of TCC) at the left mandibular ramus, and trifid mandibular canal (TMC) including a retromolar canal (RMC) at the left mandibular body.

In the present case, multiple anatomic variations of bilateral mandibular canals area were found by CBCT examination. The variations are difficult to detect using conventional radiographs. Therefore, in order to prevent complications, application of CBCT to obtain more detailed anatomical information before surgery is warranted.

### Declaration of competing interest

The authors have no conflicts of interest relevant to this article.

### References

1. Moro A, Abe S, Yokomizo N, Kobayashi Y, Ono T, Takeda T. Topographical distribution of neurovascular canals and foramina in the mandible: avoiding complications resulting from

their injury during oral surgical procedures. *Heliyon* 2018;4: e00812.

2. Ualcin ED, Akyol S. Assessment of the temporal crest canal using cone-beam computed tomography. *Br J Oral Maxillofac Surg* 2020;58:199–202.
3. Kikuta S, Iwanaga J, Nadmura K, Hino K, Nakamura M, Kusakawa J. The retromolar canals and foramina: radiographic observation and application to oral surgery. *Surg Radiol Anat* 2018;40:647–52.
4. Krishnan U, Monsour P, Thaba K, Lalloo R, Moule A. A limited field cone-beam computed tomography-based evaluation of the mental foramen, accessory mental foramina, anterior loop, lateral lingual foramen, and lateral lingual canal. *J Endod* 2018; 44:946–51.
5. Muinelo-Lorenzo J, Rodriguez-Pato R, Martinez-Reglero C, Salgado-Barreira A, Suarez-Cunqueiro MM. Detection of the accessory mental foramina on human mandibles using cone-beam computed tomography: a systematic review and meta-analysis. *J Endod* 2021;47:1215–28.

Ching-Yi Chen

Chih-Huang Tseng

*Division of Oral Pathology & Maxillofacial Radiology,  
Kaohsiung Medical University Hospital, Kaohsiung, Taiwan  
Oral & Maxillofacial Imaging Center, College of Dental  
Medicine, Kaohsiung Medical University, Kaohsiung, Taiwan  
E-mail addresses: [jeanccytwk@gmail.com](mailto:jeanccytwk@gmail.com) (C.-Y. Chen),  
[r03422001@ntu.edu.tw](mailto:r03422001@ntu.edu.tw) (C.-H. Tseng)*

Han-Jen Hsu

*School of Oral Hygiene, College of Dental Medicine,  
Kaohsiung Medical University, Kaohsiung, Taiwan  
Division of Oral & Maxillofacial Surgery, Kaohsiung Medical  
University Hospital, Kaohsiung, Taiwan  
E-mail address: [880354@mail.kmuh.org.tw](mailto:880354@mail.kmuh.org.tw) (H.-J. Hsu)*

Yuk-Kwan Chen\*

*School of Dentistry, College of Dental Medicine, Kaohsiung  
Medical University, Kaohsiung, Taiwan  
Division of Oral Pathology & Maxillofacial Radiology,  
Kaohsiung Medical University Hospital, Kaohsiung, Taiwan  
Oral & Maxillofacial Imaging Center, College of Dental  
Medicine, Kaohsiung Medical University, Kaohsiung, Taiwan*

\*Corresponding author. School of Dentistry, College of  
Dental Medicine, Kaohsiung Medical University, 100 Shih-  
Chuan 1st Road, Kaohsiung, 80708, Taiwan.

Fax: +886 7 3210637.

E-mail address: [yukkwa@kmu.edu.tw](mailto:yukkwa@kmu.edu.tw) (Y.-K. Chen)

Received 25 May 2022

Available online 9 June 2022