

## R E V I E W

## Allergic rhinoconjunctivitis

*Michele Miraglia del Giudice<sup>1</sup>, Annalisa Allegorico<sup>2</sup>, Gian Luigi Marseglia<sup>3</sup>, Alberto Martelli<sup>4</sup>, Mauro Calvani<sup>5</sup>, Fabio Cardinale<sup>6</sup>, Marzia Duse<sup>7</sup>, Elena Chiappini<sup>8</sup>, Sara Manti<sup>9</sup>, Claudio Cravidi<sup>10</sup>, Maria Angela Tosca<sup>11</sup>, Carlo Caffarelli<sup>12</sup>*

<sup>1</sup>Department of Woman, Child and of General and Specialized Surgery. University of Campania “Luigi Vanvitelli” Naples, Italy; <sup>2</sup>Department of Pediatrics, Bambino Gesù Children’s Hospital, Rome, Italy; <sup>3</sup>Pediatric Clinic Department of Pediatrics, Fondazione IRCCS Policlinico S. Matteo, University of Pavia, Pavia, Italy; <sup>4</sup>Department of Pediatrics, G.Salvini Hospital, Garbagnate Milanese, Milan, Italy; <sup>5</sup>UOC di Pediatria. Azienda Ospedaliera S. Camillo Forlanini, Roma, Italy; <sup>6</sup>Department of Pediatrics and Emergency, Pediatric Allergy and Pulmunology Unit, Azienda Ospedaliera-Universitaria Consorziata-Policlinico, Ospedale Pediatrico Giovanni XXIII, Bari, Italy; <sup>7</sup>Department of Pediatrics, Sapienza University, Rome, Italy; <sup>8</sup>Division of Paediatric Infectious Disease, Anna Meyer Children’s University Hospital, Department of Health Sciences, University of Florence, Florence, Italy; <sup>9</sup>UOC Broncopneumologia Pediatrica e Fibrosi Cistica, AOUP “Vittorio-Emanuele”, San Marco Hospital, Università di Catania, Catania, Italy; <sup>10</sup>Agenzia Tutela della Salute, ATS (National Healthcare System), Pavia, Italy; <sup>11</sup>Allergy Center, Department of Pediatrics, Istituto G. Gaslini, Genoa, Italy; <sup>12</sup>Clinica Pediatrica, Dipartimento di Medicina e Chirurgia, Università di Parma, Italy

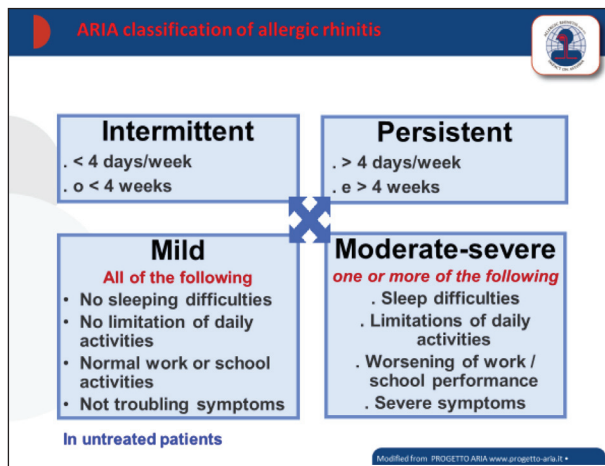
**Abstract.** Allergic rhinitis (AR) is induced by an IgE-mediated immune reaction after allergen exposure. The typical symptoms are itching, nasal discharge, sneezing and nasal obstruction. The diagnosis is based on the concordance between allergic symptoms and diagnostic tests. The skin prick test (SPT) is recommended as the “gold standard” method. First generation H1-antihistamines are widely used for treatment of AR. Intranasal glucocorticosteroids are well tolerated and can be used also in paediatric age. Allergic rhinitis cannot be considered as an isolated pathology. Other atopic diseases (allergic conjunctivitis, atopic eczema, asthma) are commonly associated. ([www.actabiomedica.it](http://www.actabiomedica.it))

**Key words:** allergic rhinoconjunctivitis; allergic rhinitis; ocular allergy; local allergic rhinitis; h1-antihistamines; intranasal corticosteroids; allergen immunotherapy

### Introduction

Allergic rhinitis (AR) affects 10% to 40% of the population. It is often associated with conjunctivitis and is defined as a symptomatic disorder of the nose characterised by: itching, nasal discharge, sneezing, nasal airway obstruction induced by an IgE-mediated immune reaction after allergen exposure (1-4). Ocular allergy (OA) represents a collection of ocular hypersensitivity disorders affecting the eyelid, conjunctiva, and cornea. Allergic rhinoconjunctivitis is the result of IgE-mediated allergy and nasal mucosa inflammation (5, 6). IgE is produced in the lymphoid tissues and locally in response to common environmental al-

lergens (5-7). When allergens bind to mast-cell-bound IgE, mast-cell degranulation occurs and release of a myriad of biochemical mediators. Histamine is the key player in the acute allergic response. The classification of AR was previously based on the time of exposure into seasonal or perennial. A new classification was divided into “intermittent” or “persistent” disease and the severity of AR was classified as “mild” or “moderate/severe” depending on the severity of symptoms and their impact on social life, school and work (Figure 1) (8). OA includes seasonal and perennial allergic conjunctivitis, vernal and atopic keratoconjunctivitis and contact blepharoconjunctivitis.



**Figure 1.** ARIA classification of allergic rhinitis according to symptom duration and severity (8)

## Symptoms and Diagnosing

The diagnosis is based on the concordance between a typical history of allergic symptoms such as rhinorrhea, nasal obstruction or itching, sneezing and diagnostic tests. Other concurring symptoms may affect the eyes such as: tearing, conjunctivae itching, swelling. Ocular symptoms are common, in particular in patients allergic to outdoor allergens. The main symptom caused by perennial allergens is nasal congestion whereas conjunctival swelling, itching and watery discharge can occur. Other symptoms may include: coughing caused by post-nasal drip, cephalalgia caused by oedema of the nasal mucosa, and hearing impairment caused by tympanic dysfunction. Sudden night awakening and apnoea can affect sleep.

Diagnostic tests are based on the demonstration of allergen-specific IgE *in vivo* or *in vitro*. A skin prick test (SPT) is recommended as the “gold standard” method for the diagnosis of IgE-mediated allergies. Detection of IgE to allergenic molecules is a second-line test for determining sensitizations to genuine allergens or to panallergens (9). Contradiction between results of pollen SPT and IgE to allergen components has been found in pollen-related AR because of panallergen sensitization (10)

Local allergic rhinitis (LAR) is a phenotype of rhinitis that is characterized by the same symptoms of allergic rhinitis but with the absence of markers of systemic atopy. Recently, it has been reported that cy-

tological exam of the nasal mucosa offers the possibility of a non-invasive study of cellular changes ongoing within the nasal mucosa. By this analysis, the presence of eosinophils and basophils supports the diagnosis of allergic disease, whilst an increased percentage of neutrophils support the diagnosis of bacterial infection.

## Management

The control of the nasal mucosa allergic inflammation is the goal of all the therapeutic strategies in the management of AR. The key points of the management are patient education, pharmacotherapy and allergen-specific immunotherapy. Mobile-health may improve not only clinical diagnosis but also monitoring and management. H1-antihistamines interfere with actions of histamine at H1-receptors (11). They are widely used for treatment of allergic rhinoconjunctivitis and are classified as older ‘first generation’ and newer ‘second generation’. First generation H1-antihistamines have poor receptor H1-receptor selectivity, and cross blood-brain-barrier. They have a lot of adverse events such as anti-muscarinic, anti- $\alpha$ -adrenergic, anti-serotonin, and sedative effects. In contrast, second generation H1-antihistamines were highly selective for the histamine H1-receptor, do not cross the blood brain barrier, and have minimal adverse events. Oral H1-antihistamines have been shown to be safe and effective in children and also for long-term treatment. The rationale for using intranasal glucocorticosteroids in the treatment of allergic rhinitis is that high drug concentrations can be achieved at receptor sites in the nasal mucosa with a minimal risk of systemic adverse effects (12,13). The current intranasal preparations are well tolerated and can be used on a long-term basis without atrophy of the mucosa. Side-effects are generally mild (crusting, dryness and minor epistaxis) (14-16). Due to their mechanism of action, efficacy appears after 7-8h of dosing, but maximum efficacy may require up to 2 weeks to develop. Topical ocular decongestants and corticosteroids were used in OA (17, 18). This was independent of the specific diagnosis of OA subtype and severity. Topical antihistamines and mast cell stabilizers are the first-line therapy. Allergen immunotherapy (AIT) is a proven

therapeutic option for the treatment of allergic rhinoconjunctivitis (18). The decision to prescribe AIT for the patient should be individualized and based on the relevance of the allergens, the persistence of symptoms despite appropriate medications according to guidelines as well as on the availability of good-quality and efficacious extracts. According to the hygiene hypothesis, probiotics and bacterial lysates have been proposed for children with AR. Primary prevention is still based on avoidance of tobacco smoke.

### Co-morbidities

Allergic rhinitis cannot be considered as an isolated pathology. Other atopic diseases (allergic conjunctivitis, atopic eczema, asthma) are commonly associated. The pollen-food allergy syndrome due to a cross-reaction between pollens that induce AR and vegetable foods is common in AR. It is characterized by pruritus and angioedema at lips and oral cavity. The inflammation that affects the nasal mucosa will consequently affect the eye mucosa, air sinuses, ear and lower airways. Therefore in subjects affected by AR the co-existence of multiple diverse conditions such as deviated septum, nasal turbinate dysfunction, nasal polyps, chronic sinusitis, otitis media with effusion and adenoid hypertrophy can occur. Permanent signs found in allergic rhinitis subjects can be malocclusion or misalignment of teeth and jaws and adenoidal face (long face syndrome).

**Conflict of interest:** Each author declares that he or she has no commercial associations (e.g. consultancies, stock ownership, equity interest, patent/licensing arrangement etc.) that might pose a conflict of interest in connection with the submitted article

### References

1. Bousquet J, Pfaar O, Togias A, et al. 2019 ARIA Care pathways for allergen immunotherapy. *Allergy* 2019;74:2087-2102.
2. Bousquet J, Heinzerling L, Bachert C, et al. Practical guide to skin prick tests in allergy to aeroallergens. *Allergy* 2012; 67: 18-24.
3. Gelardi M, Iannuzzi L, Quaranta N, Landi M, Passalacqua G. NASAL cytology: practical aspects and clinical relevance. *Clin Exp Allergy* 2016;46:785-792.
4. Miraglia Del Giudice M, Marseglia A, Leonardi S, et al. Allergic rhinitis and quality of life in children. *Int J Immunopathol Pharmacol* 2011;24(4 Suppl):25-28.
5. Ciprandi G, Marseglia GL, Castagnoli R, et al. From IgE to clinical trials of allergic rhinitis. *Expert Rev Clin Immunol* 2015;11:1321-1333.
6. Marseglia GL, Poddighe D, Caimmi D, et al. Role of adenoids and adenoiditis in children with allergy and otitis media. *Curr Allergy Asthma Rep* 2009;9:460-464.
7. Kalpaklioglu F, Baccioglu A. Efficacy and safety of H1-antihistamines: an update. *Antiinflamm Antiallergy Agents Med Chem* 2012;11:230-7.
8. Progetto ARIA-Rinite Allergica e suo impatto sull'asma. [www.progetto-aria.it](http://www.progetto-aria.it)
9. Cipriani F, Mastroianni C, Tripodi S, et al. Diagnostic relevance of IgE sensitization profiles to eight recombinant *Phleum pratense* molecules. *Allergy* 2018;73:673-682
10. Mastroianni C, Posa D, Cipriani F, Caffarelli C. Asthma and allergic rhinitis in childhood: what's new. *Pediatr Allergy Immunol* 2016;27:795-803.
11. Jang TY, Kim YH. Recent updates on the systemic and local safety of intranasal steroids. *Curr Drug Metab* 2016;17:992-996.
12. Ratner P, Van Bavel J, Mohar D, et al. Efficacy of daily intranasal fluticasone propionate on ocular symptoms associated with seasonal allergic rhinitis. *Ann Allergy Asthma Immunol* 2015;114:141-7.
13. Licari A, Ciprandi G, Marseglia A, et al. Current recommendations and emerging options for the treatment of allergic rhinitis. *Expert Rev Clin Immunol* 2014;10:1337-1347.
14. Licari A, Castagnoli R, Bottino C, Marseglia A, Marseglia G, Ciprandi G. Emerging drugs for the treatment of perennial allergic rhinitis. *Expert Opin Emerg Drugs* 2016;21:57-67.
15. Licari A, Castagnoli R, De Filippo M, et al. Current and emerging biologic therapies for allergic rhinitis and chronic rhinosinusitis. *Expert Opin Biol Ther* 2020;20:609-619.
16. Van Cauwenbergh P, De Belder T, Vermeiren J, Kaplan A. Global resources in allergy (GLORIA): allergic rhinitis and conjunctivitis. *Clin Exp All Rev* 2003; 3: 46-50.
17. Leonardi A, Silva D, Perez Formigo D et al. Management of ocular allergy. *Allergy* 2019 ;74:1611-1630.
18. Pajno GB, Bernardini R, Peroni D, et al. Clinical practice recommendations for allergen-specific immunotherapy in children: the Italian consensus report. *Ital J Pediatr* 2017;43:13.

Received: 20 July 2020

Accepted: 31 July 2020

Correspondence:

Michele Miraglia del Giudice MD

via De Crecchio 4 - 80134 Napoli- Italy

Tel. +395665922

Fax: +395665922

E-mail: [michele.miraglia@unicampania.it](mailto:michele.miraglia@unicampania.it)