

# Pediatric Necrotizing Fasciitis: Restitutio Ad Integrum after Early Diagnosis and Aggressive Surgical Treatment

Angela Lemaréchal<sup>1</sup> Sabine Zundel<sup>1</sup> Philipp Szavay<sup>2</sup>

<sup>1</sup>Department of Pediatric Surgery, Luzerner Kantonsspital, Luzern, Switzerland

<sup>2</sup>Department of Pediatric Surgery, University of Tübingen, Children's Hospital, Tuebingen, Germany

**Address for correspondence** Angela Lemaréchal, Department of Pediatric Surgery, Luzerner Kantonsspital, Spitalstrasse, Luzern 6000 16, Switzerland (e-mail: angela.lemarechal@luks.ch).

Eur J Pediatr Surg Rep 2016;4:34–36.

## Abstract

### Keywords

- ▶ necrotizing fasciitis
- ▶ negative pressure therapy
- ▶ child

Necrotizing fasciitis (NF) is a severe, life-threatening infectious condition. Diagnosis is difficult due to unspecific symptoms yet crucial for favorable outcomes. We report a case of a 1 year old, previously healthy boy, where early suspicion of NF led to prompt aggressive therapy and consecutive restitutio ad integrum.

## Introduction

In necrotizing fasciitis (NF), bacterial invasion of the subcutaneous tissue with subsequent release of endo- and exotoxins causes tissue ischemia and liquefactive necrosis. Subsequent systemic inflammation is common; morbidity and mortality are high. The estimated prevalence in children is 0.08 per 100,000 children per year,<sup>1</sup> and mortality is found to be ~15%.<sup>2</sup> Early diagnosis is as essential for pediatric NF as for adult cases since it enables early therapy which significantly improves survival and outcome.

We report one case of pediatric NF where early diagnosis and prompt surgical therapy proved to be of success in terms of a full recovery of the patient.

## Case Report

A previously healthy 12-month-old boy was vaccinated for measles, mumps, rubella, and meningococci according to the Swiss national standard. The injection was performed in the left deltoid muscle; additionally, a capillary blood sample was taken on his left middle finger. Two days later, he developed fever and a pustule at the site of the capillary puncture on his finger. The patient was referred to our emergency department when the fever did not resolve after another 2 days.

Clinical examination upon arrival revealed a reduced general health, high temperature (39.9°C), tachycardia (207/min), normal blood pressure (111/75 mm Hg), normal oxygen saturation (98%), tachy- and dyspnea (68/min), rhinitis, and a mild exanthema predominantly on the torso. The site of the capillary puncture showed a local necrosis of ~3 mm in diameter, its surrounding was inconspicuous. White blood count was 14.3 g/L, and C-reactive protein elevated to 180 mg/L.

The child was transferred to a pediatric ward with suspected diagnosis of upper airway infection, and treatment was initiated with nonsteroidal anti-inflammatory drugs and decongestant nose drops.

Reevaluation after 8 hours showed a deteriorated general state, temperature of 37.1°C, pulse 144/min, blood pressure 105/68 mm Hg, and an oxygen saturation of 97%. In addition, a newly developed, mildly painful swelling and erythema was noted on the chest wall (see ▶ Fig. 1). Blood tests were repeated and showed an increased white blood count of 17.8 g/L and C-reactive protein of 280 mg/L. NF was considered a possible diagnosis and decision for prompt treatment was made. Intravenous amoxicillin with clavulanic acid and clindamycin were started and the child was transferred to the operating room. Surgical therapy was started within 3 hours of the initial consideration of NF.

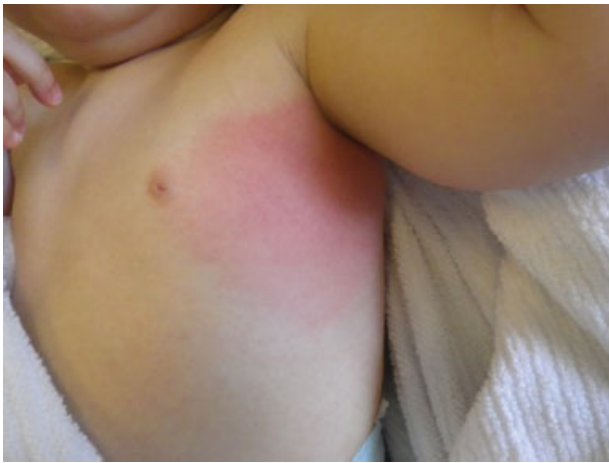received  
July 21, 2016  
accepted after revision  
October 11, 2016  
published online  
November 28, 2016

DOI <http://dx.doi.org/10.1055/s-0036-1594307>.  
ISSN 2194-7619.

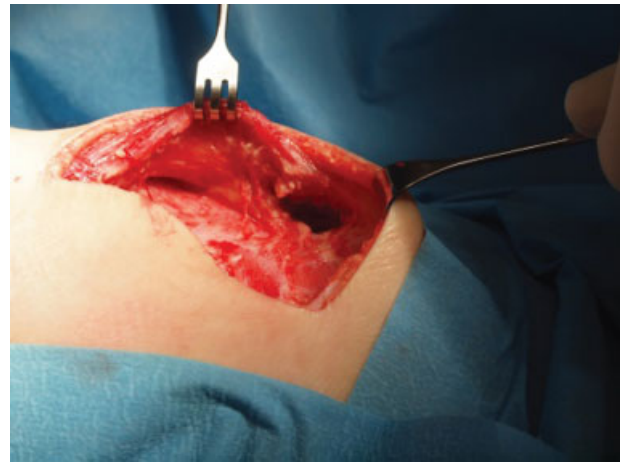
© 2016 Georg Thieme Verlag KG  
Stuttgart · New York

License terms





**Fig. 1** Initial clinical demonstration leading to the diagnosis.



**Fig. 3** Intraoperative site after cleansing.

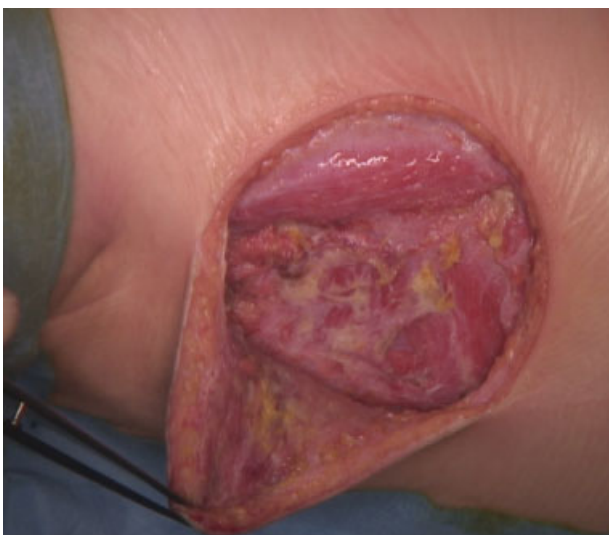The infected site was approached with an incision of 15 cm on the lateral chest wall. Inspection showed intense subcutaneous swelling, enlarged lymph nodes, and the presence of a milky-murky fluid pathognomonic for NF and typically described as dishwater fluid. **Fig. 2** shows the intraoperative site. Suspicious tissue was resected, lymph node and microbiological samples were collected, extensive wound rinse was performed (**Fig. 3**), and vacuum therapy was applied.

All wound cultures grew numerous colonies of *Streptococcus pyogenes*. Histology revealed necrosis of the sampled lymph nodes. The general state of the patient improved after surgery. Vital parameters remained stable; extubation was possible right after surgery and assisted ventilation or catecholamine therapy, respectively, was never necessary. Signs of systemic inflammatory response syndrome or septic shock respectively were not seen at any time. Reevaluation and changes of dressings were repeated regularly under general anesthesia. During the initial changes, small areas of necrotic tissue were detected and resected. After microbiological samples were found to be sterile,

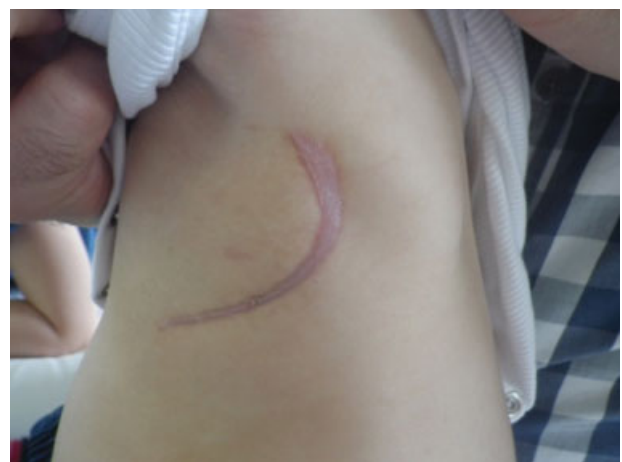the wound could be closed on day 13. A single drain was left in place which could be removed after another 4 days. Intravenous antibiotic therapy was changed to penicillin G according to microbiological testing and continued until discharge on day 18. Oral antibiotic therapy was continued with amoxicillin for another week. The follow-up after 2 months showed a resitutio ad integrum (see **Fig. 4**).

## Discussion

NF is a rapidly progressing and potentially life-threatening infection of the superficial fascia and subcutaneous tissue. Early diagnosis is essential because immediate surgical debridement offers the best chance for survival. It has been reported that delay of surgical intervention by more than 24 hours doubles mortality.<sup>3</sup> Initial symptoms are nonspecific: the most frequently reported signs are fever, tenderness, erythema, and pain.<sup>2</sup> Since the underlying tissue is affected more extensively than the dermal or epidermal layer, edema may extend the erythematous border. The often fulminant progression of skin findings occurs within hours and erythema progresses to violaceous necrotic lesions, vesicles, and bullae if untreated.<sup>3</sup>



**Fig. 2** Intraoperative site after incision.



**Fig. 4** Clinical presentation after 2 months.

“Pain out of proportion” to physical findings is often described as a typical sign in adult NF; a recent literature review did not verify this as a common symptom in pediatric NF.<sup>2</sup> In accordance, our patient showed unspecific symptoms. Prompt recognition was only possible because the physician on call was aware of the differential diagnosis and his or her level of suspicion was high. Diagnosis was confirmed at surgery by a lack of resistance of the normally adherent fascia to blunt dissection,<sup>4</sup> distinctive, local edema (dishwater fluid), which is created by the subcutaneous tissue undergoing necrosis and a gray and nonbleeding subcutaneous tissue.<sup>3</sup>

Negative-pressure wound therapy has been used by various surgeons in cases of NF. It is applied to reduce edema and toxins from the wound.<sup>5,6</sup> The rate of granulation tissue formation is increased and different options for a secondary wound closure remain possible (direct, skin graft, flap). Nevertheless, negative-pressure wound therapy presents the risk of bacterial overgrowth underneath the foam. Consequently, some authors consider it to be contraindicated for infectious wounds. Taking this into account, we performed regular foam changings every second day and monitored vital and laboratory parameters continuously. Taking these precautions, our experience with negative-pressure wound therapy for NF was favorable. We did not consider hyperbaric oxygen therapy, as there is no evidence for its effectiveness.<sup>4,7</sup>

Calculated antibiotic therapy needs to be initiated if NF is suspected after microbiological samples have been collected. According to the microbiological findings, NF is classified into two groups: type 1 infections, typically found in adult patients, involve multiple organisms. Type 2 infections are caused by a single organism infection.<sup>1</sup> For the pediatric patient cohort, type 2 infections seem to be more frequent.<sup>2</sup> Knowing the possible pathogens, patients should receive broad-spectrum IV antibiotics to cover streptococci, staphylococci, gram negative rods, and anaerobes.<sup>8</sup> Clindamycin should be considered since it can switch off exotoxin production and inhibit M protein synthesis, thus promoting phagocytosis and suppressing the effects of bacterial toxins in mediating septic shock.<sup>9</sup> Consistent with current literature our patient had a type 2 infection with *S. pyogenes*. Calculated treatment was effective and could even be reduced to penicillin G after microbiological results were received.

Predisposition to develop NF is repeatedly discussed in literature. On the one hand, numerous risk factors like wounds, immunosuppression, contusion, malnutrition, obesity, omphalitis, mastitis, diaper rash, burns, insect bites, hematologic malignancies, or nephritic syndrome are

described. On the other hand, many cases without underlying diseases or triggering factors are published.<sup>1</sup> In our case, the vaccination, received 4 days prior to diagnosis needs to be discussed as predisposing for NF. There is, however, only one case of postvaccination NF to be found in the pediatric NF literature.<sup>10</sup> Additionally, the site of the injection was always inconspicuous. Furthermore, the small wound from the capillary blood sample might be a possible entry point for bacteria but no sign of lymphangitis was detected and similar cases found in the literature typically present with NF at the site of the lesion.<sup>11</sup> In conclusion, it remains unclear if either the vaccination or the capillary blood sample can be regarded as predisposition.

#### Funding

No funding to be declared.

#### References

- 1 Kumar M, Meeks A, Kearn L. Necrotizing fasciitis of the chest wall: report of pediatric cases. *Pediatr Emerg Care* 2015;31(9):656–660
- 2 Zundel S, Lemaréchal A, Kaiser P, Szavay P. Diagnosis and treatment of pediatric necrotizing fasciitis: a systematic review of the literature. *Eur J Pediatr Surg* 2016 (e-pub ahead of print)
- 3 King E, Chun R, Sulman C. Pediatric cervicofacial necrotizing fasciitis: a case report and review of a 10-year national pediatric database. *Arch Otolaryngol Head Neck Surg* 2012;138(4):372–375
- 4 Hsieh WS, Yang PH, Chao HC, Lai JY. Neonatal necrotizing fasciitis: a report of three cases and review of the literature. *Pediatrics* 1999;103(4):e53
- 5 Szabó L, Szegedi I, Kiss C, et al. Excessive pediatric fasciitis necrotisans due to *Pseudomonas aeruginosa* infection successfully treated with negative pressure wound therapy. *Dermatol Ther (Heidelb)* 2015;28(5):300–302
- 6 Melchionda F, Pession A. Negative pressure treatment for necrotizing fasciitis after chemotherapy. *Pediatr Rep* 2011;3(4):e33
- 7 Machado N. Necrotizing fasciitis: the importance of early diagnosis, prompt surgical debridement and adjuvant therapy. *N Am J Med Sci* 2011;3(3):107–118
- 8 Fustes-Morales A, Gutierrez-Castrellon P, Duran-Mckinster C, Orozco-Covarrubias L, Tamayo-Sanchez L, Ruiz-Maldonado R. Necrotizing fasciitis: report of 39 pediatric cases. *Arch Dermatol* 2002;138(7):893–899
- 9 Jamal N, Teach SJ. Necrotizing fasciitis. *Pediatr Emerg Care* 2011;27(12):1195–1199, quiz 1200–1202
- 10 Thapa R, Mallick D, Biswas B. Necrotizing fasciitis following BCG vaccination. *Indian Pediatr* 2011;48(3):235–237
- 11 Legbo JNSB, Shehu BB. Necrotising fasciitis: experience with 32 children. *Ann Trop Paediatr* 2005;25(3):183–189