

# Relapsing and Immune-Responsive Paroxysmal Jaw Clonus With Blepharospasm and Sialorrhea Associated With D2R Autoantibodies

Yue Liu, MD,\* Xiaoting Hao, MD,\* Dong Zhou, MD, PhD, and Zhen Hong, MD, PhD

*Neurol Neuroimmunol Neuroinflamm* 2022;9:e1172. doi:10.1212/NXI.0000000000001172

## Correspondence

Dr. Hong  
hongzhengoog@aliyun.com

## Abstract

### Objectives

To extend the symptomatic spectrum of acute neurologic syndrome associated with dopamine-2 receptor (D2R) antibodies.

### Methods

A 13-year-old adolescent boy was admitted to the Neurology Department with abnormal jaw movements. The initial evaluation included laboratory examinations of blood, chest radiography, brain MRI, EEG, and neuropsychologic tests. Serum and CSF samples were collected for immunologic studies. The clinical outcome of the patient was followed up for 18 months after the first hospitalization.

### Results

Paroxysmal jaw clonus, blepharospasm, and sialorrhea were observed in the patient with a history of Tourette syndrome and obsessive–compulsive disease and with an acute neurologic syndrome associated with D2R antibodies. The symptoms responded to IV methylprednisolone (IVMP), relapsed twice during prednisone reduction, and, finally, improved after the combined treatment of IVMP and IV immunoglobulin.

### Discussion

Recognizing paroxysmal jaw clonus (possibly with blepharospasm and sialorrhea) and considering the relationship between these episodes and D2R antibodies will be helpful in the early diagnosis and treatment of immune neurologic syndromes.

## MORE ONLINE

 Videos

\*These authors contributed equally to this work.

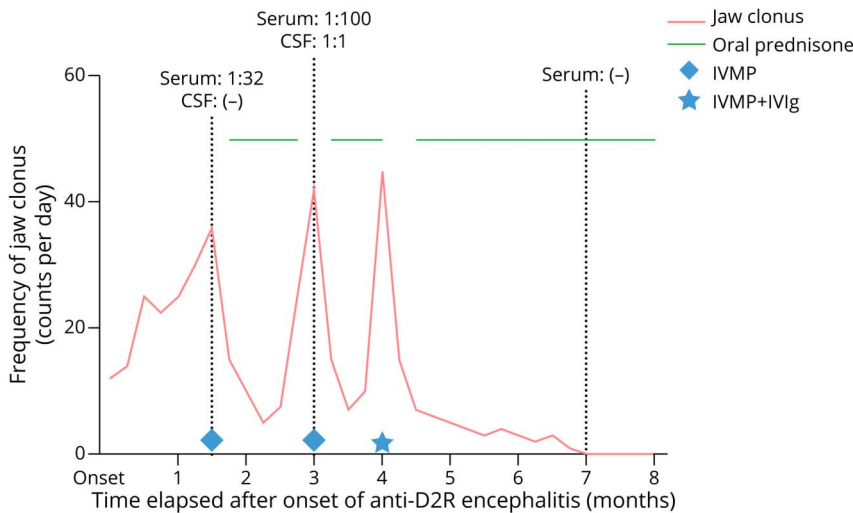
From the Department of Neurology, West China Hospital, Sichuan University, Chengdu, Sichuan, People's Republic of China.

Go to [Neurology.org/NN](https://www.neurology.org/NN) for full disclosures. Funding information is provided at the end of the article.

The Article Processing Charge was funded by the National Natural Science Foundation of China and the National Key R&D Program of China.

This is an open access article distributed under the terms of the Creative Commons Attribution-NonCommercial-NoDerivatives License 4.0 (CC BY-NC-ND), which permits downloading and sharing the work provided it is properly cited. The work cannot be changed in any way or used commercially without permission from the journal.

**Figure 1** Relationship Between Jaw Clonus and Antibody Titer of the Patient



The symptoms of jaw clonus worsened after oral prednisone taper, improved after IVMP treatment, and disappeared after the combined treatment of IVIg and IVMP. Oral prednisone therapy was suspended during the patient's hospitalization. D2R antibodies were detected with a cell-based assay. D2R = dopamine-2 receptor; IVIg = IV immunoglobulin; IVMP = IV methylprednisolone.

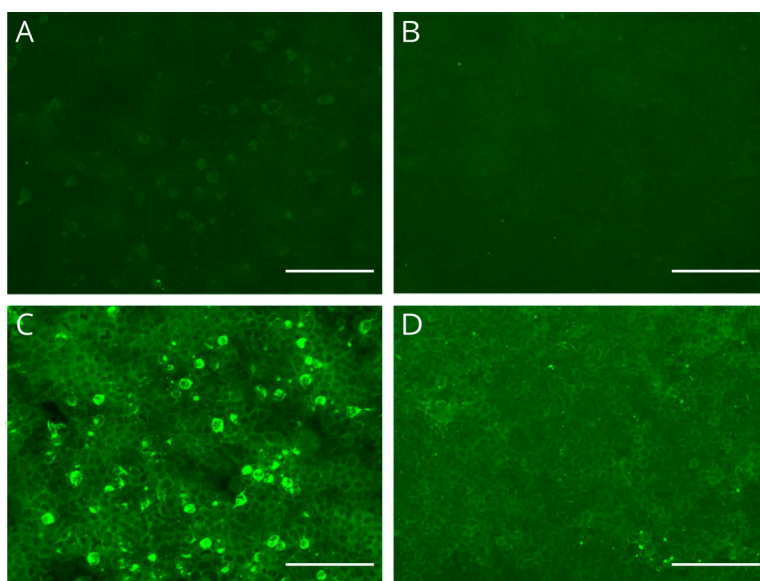
Antidopamine-2 receptor (D2R) encephalitis is a rare condition with typical symptoms including dystonia parkinsonism and emotional lability.<sup>1</sup> The pathogenicity of D2R antibodies is debatable,<sup>2</sup> and the reported responses of most patients to immunotherapy may implicate the involvement of the immune system rather than favoring the identifiable antibody being pathogenic.<sup>1,3,4</sup> We report the case of a 13-year-old adolescent boy with paroxysmal jaw clonus, blepharospasm, and sialorrhea of an acute neurologic syndrome associated with D2R antibodies. The symptoms responded to IV methylprednisolone (IVMP), relapsed twice during prednisone reduction, and, finally,

improved after the combined treatment of IVMP and IV immunoglobulin (IVIg).

## Case

A 10-year-old boy had a 2.5-year history of repetitive tics, with eye blinking, shoulder shrugging, tiptoeing, obscene language, and throat clearing, and these episodes occurred more than 10 times a day. Then, the symptoms of irritability and compulsion gradually evolved over 2 years. He was diagnosed with Tourette syndrome and obsessive-compulsive disease and was treated with risperidone, aripiprazole, and sertraline for approximately half a year. At

**Figure 2** Antibody Testing in CSF and Serum of the Case



D2R IgG autoantibodies were measured on fixed HEK293 cells using a cell-based assay against the long isoform of D2R expressed at the cell surface. Reactivity was analyzed by immunofluorescence. (A) CSF studies showed positive anti-D2R antibodies (1:1). (C) Serum studies showed positive anti-D2R antibodies (1:100). (B, D) Negative controls: HEK293 cells expressing empty vector plasmids were incubated with CSF (B) or serum (D) from the same patient (scale bar: 150  $\mu$ m). D2R = dopamine-2 receptor.

age 13, after a tongue infection, a week later, he developed paroxysmal jaw clonus (2–3 Hz) that occurred more than 10 times per day (Video 1), accompanied by irritability and tongue biting. One month later, the jaw clonus worsened after a respiratory tract infection. The episodes included sudden jaw clonus, commonly with blepharospasm and sialorrhea, occasionally with vocalization, without decreased consciousness, lasting from a few seconds to a minute. These symptoms disappeared during his sleep. A physical examination during the interictal period revealed no abnormalities, except for the tongue injuries in the anterior third of the tongue.

Laboratory examinations further excluded extrapyramidal differential diagnosis induced by CNS infectious diseases (eTable 1, [links.lww.com/NXI/A713](https://links.lww.com/NXI/A713)). An MRI examination of the brain revealed no abnormalities. Chest radiography showed a slight blurring of both lungs. D2R IgG antibodies were detected in serum (1:32) using a cell-based assay (CBA).<sup>5</sup> The tests for other onconeural or neuronal cell surface antibodies were negative with the CBA or dot immunobinding assay (eTable 1, [links.lww.com/NXI/A713](https://links.lww.com/NXI/A713)). Neuropsychological tests for the first time revealed his moderate to severe cognitive impairments (eTable 1, [links.lww.com/NXI/A713](https://links.lww.com/NXI/A713)).

Figure 1 summarizes the relationship between the paroxysmal jaw clonus and D2R antibody titers. The patient's symptoms rapidly improved after IVMP treatment (1 g/d for 5 days). After oral prednisone taper, his jaw clonus relapsed, and a stereotypical repetitive movement of trunk extensor occurred without epileptiform discharge (Video 2), with an increase in anti-D2R antibody titers (Figure 2). After IVMP treatment again, the abovementioned symptoms improved but further worsened on reducing prednisone. After a combination of IVIg (0.4 g/kg per day for 5 days) and IVMP, the anti-D2R antibody test in serum became negative with the disappearance of all symptoms. The symptoms of eye blinking, shoulder shrugging, tiptoeing, obscene language, throat clearing, irritability, compulsion, and cognitive impairments were completely resolved 3 months after the final immunotherapy.

## Discussion

Our presented case extended the symptomatic spectrum of acute neurologic syndromes associated with D2R antibodies by including abnormal jaw movements. The symptoms of paroxysmal jaw clonus (often with blepharospasm and sialorrhea) should be considered as movement disorders of extrapyramidal system after excluding seizures by video EEG monitoring. The jaw clonus (2–3 Hz), seen in Video 1, should not be confused with the jaw tremor of Parkinson disease (3–7 Hz at rest with mouth closure), essential tremor (4–12 Hz postural and kinetic tremor), or isolated jaw tremor. Jaw tremors may also be seen in tardive jaw tremors (previous dopamine-blocking drugs and repetitive and rhythmic tremors).

Although a functional neurologic disorder was a differential diagnosis, the clinical phenomenology, association with

autoantibodies, and improvement with immune therapies support the hypothesis that the neurologic syndrome was an immune-mediated movement disorder. The symptoms of paroxysmal jaw clonus occurred after infection, a possible trigger of autoimmune antibody production, in addition, got improved after immune therapy, which may implicate that the neurologic syndrome is immune mediated. Then, the phenomenon of relapsing after prednisone reduction and the linear relationship between clinical symptoms and antibody titer further supports the autoimmune nature of this phenotype. Mycoplasma etiologic examination may be valuable to exclude other infections and possible triggers of D2R antibodies, not performed in this case.

The strongest association of D2R antibody is with basal ganglia encephalitis, a radiologic basal ganglia syndrome with acute dystonia and akinesia,<sup>1,3,6</sup> but there is also some association with autoimmune chorea,<sup>1</sup> occasional children with tics,<sup>7</sup> or Tourette syndrome.<sup>1</sup> This case presents a novel syndrome and, for this reason, is useful for people to recognize the autoimmune nature of this phenotype. Although the phenotype is novel, the association with D2R antibodies supports the likelihood this phenotype is an immune-responsive movement disorder.

## Acknowledgment

The authors thank all participants for their participation in the study.

## Study Funding

This work was supported by the National Natural Science Foundation of China (grants 81971213 and 81671291) and the National Key R&D Program of China (2018YFC1312300).

## Disclosure

None of the authors have any conflict of interest to disclose. Go to [Neurology.org/NN](https://Neurology.org/NN) for full disclosures.

## Publication History

Received by *Neurology: Neuroimmunology & Neuroinflammation* December 6, 2021. Accepted in final form March 9, 2022. Submitted and externally peer reviewed. The handling editor was Josep O. Dalmau, MD, PhD, FAAN.

## Appendix Authors

Name	Location	Contribution
Yue Liu, MD	West China Hospital, Sichuan University, China	Designed and conceptualized study, literature review, and drafted the article and figure
Xiaoting Hao, MD	West China Hospital, Sichuan University, China	Literature review, interpreted the imaging, and laboratory findings
Dong Zhou, MD, PhD	West China Hospital, Sichuan University, China	Literature review and revised the figure
Zhen Hong, MD, PhD	West China Hospital, Sichuan University, China	Designed and conceptualized the study and revised the article

## References

1. Dale RC, Merheb V, Pillai S, et al. Antibodies to surface dopamine-2 receptor in auto-immune movement and psychiatric disorders. *Brain*. 2012;135(pt 11):3453-3468.
2. Sinmaz N, Tea F, Pilli D, et al. Dopamine-2 receptor extracellular N-terminus regulates receptor surface availability and is the target of human pathogenic antibodies from children with movement and psychiatric disorders. *Acta Neuropathol Commun*. 2016;4(1):126.
3. Marques-Matos C, Melo C, Sampaio M, Rodrigues E, Sousa R, Alves D. Child Neurology: treatable bilateral striatal lesions related to anti-dopamine 2 receptor autoimmunity. *Neurology*. 2018;91(2):98-101.
4. Mohammad SS, Sinclair K, Pillai S, et al. Herpes simplex encephalitis relapse with chorea is associated with autoantibodies to N-Methyl-D-aspartate receptor or dopamine-2 receptor. *Mov Disord*. 2014;29(1):117-122.
5. Dalmau J, Gleichman AJ, Hughes EG, et al. Anti-NMDA-receptor encephalitis: case series and analysis of the effects of antibodies. *Lancet Neurol*. 2008;7(12):1091-1098.
6. Dale RC, Church AJ, Surtees RA, et al. Encephalitis lethargica syndrome: 20 new cases and evidence of basal ganglia autoimmunity. *Brain*. 2004;127(pt 1):21-33.
7. Addabbo F, Baglioni V, Schrag A, et al. Anti-dopamine D2 receptor antibodies in chronic tic disorders. *Dev Med Child Neurol*. 2020;62(10):1205-1212.