



Placement of KANI[®] plate inside the chest wall for rib fixation: Prevention for organ injuries caused by crossed rib edges and plate claws

Asuka Uebayashi  | Yusuke Takanashi | Mikako Oka | Kiyomichi Mizuno | Akikazu Kawase | Kazuhito Funai 

First Department of Surgery, Hamamatsu University School of Medicine, Hamamatsu, Japan

Correspondence

Kazuhito Funai, First Department of Surgery, Hamamatsu University School of Medicine, 1-20-1 Handayama, Higashi-ku, Hamamatsu, Shizuoka 431-3192, Japan.
Email: kfunai@hama-med.ac.jp

Associate Editor: Michael Hsin

Abstract

The claw-type titanium plate has been successfully applied to manage a flail chest. However, rare and life-threatening organ injury occurs due to an insufficient claw bend. We report an ingenuity of surgical fixation using KANI[®] plates (USCI Japan, Tokyo, Japan) in a flail chest. A 60-year-old man with a severe flail chest underwent a surgical rib fixation. He had multiple rib fractures accompanied by dislocation and protruding crossed rib edges; we assumed a possibility of lung injury during a standard procedure in which the KANI[®] plates would be placed from outside the chest wall. Therefore, we placed KANI[®] plates inside the chest wall to ensure sufficient claw bend and to cover crossed rib edges to prevent organ injuries. We propose that our new ingenuity provides a safe and tight rib fixation in rib fractures with protruding crossed rib edges which the standard method cannot flatten.

KEYWORDS

claw-type titanium plate, flail chest, organ injury, surgical fixation

INTRODUCTION

The claw-type titanium plate has been successfully applied for the management of a flail chest.¹ However, rare and life-threatening organ injury occurs due to an insufficient claw bend.² We report an ingenuity of surgical fixation in a flail chest: the claw-type titanium plates, KANI[®] plate (USCI Japan, Tokyo, Japan), were placed from inside the chest wall to ensure sufficient claw bend and to cover crossed rib edges to prevent organ injuries.

CASE REPORT

A 60-year-old man fell down the stairs and exhibited a flail chest. Computed tomography (CT) revealed displaced fractures of the left third to ninth consecutive ribs and left pneumothorax. We diagnosed the patient with flail chest as ventral and dorsal portions of fifth to eighth ribs fractured.

Immediately, a chest drainage tube was placed to stabilize the respiratory condition. As the patient did not exhibit paradoxical breathing, we initiated conservative treatment with pain control and chest banding. However, 2 days after the injury, paradoxical breathing became evident. We instituted emergent intubation and subsequent mechanical ventilator management as the patient got into respiratory failure. As weaning from the mechanical ventilation was failing due to severe instability of the thoracic cage and the positive pressure ventilation exacerbated the air leakage, we performed a surgical repair of the pulmonary fistula combined with a rib fixation 9 days after the injury.

The operation was started in the right lateral decubitus position under general anaesthesia. We planned to fix ventral fractures of the third to sixth ribs, which showed significant dislocation of crossed rib edges on preoperative CT (Figure 1, left panels). Thus, approximately 25 cm longitudinal skin incision was placed along the anterior axial line. Subsequently, a thoracotomy was performed at the fourth

This is an open access article under the terms of the Creative Commons Attribution-NonCommercial-NoDerivs License, which permits use and distribution in any medium, provided the original work is properly cited, the use is non-commercial and no modifications or adaptations are made.

© 2022 The Authors. *Respirology Case Reports* published by John Wiley & Sons Australia, Ltd on behalf of The Asian Pacific Society of Respiriology.

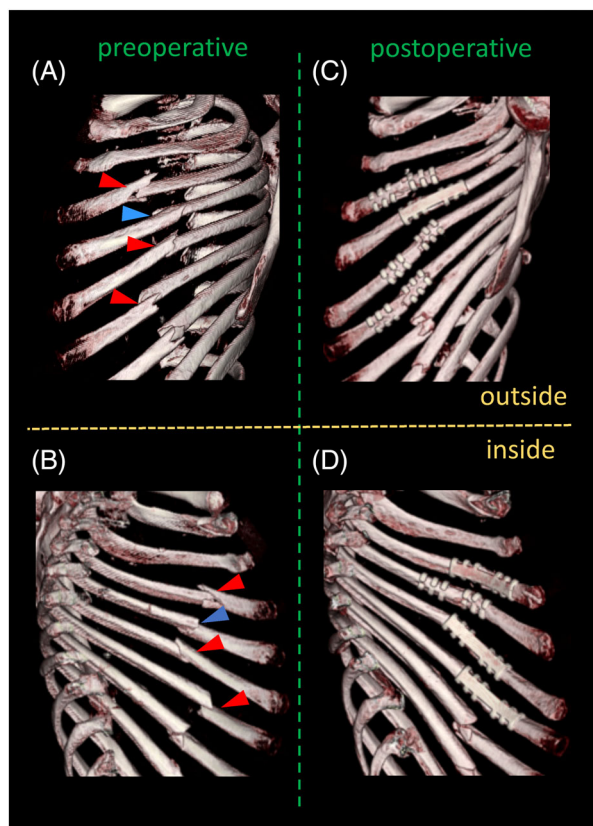


FIGURE 1 On preoperative three-dimensional computed tomography (A, B), crossed rib edges at the third, fifth and sixth rib fractures were protruding towards the thoracic cavity (red arrowheads). KANI[®] plates were placed from inside the chest wall on these fractures. KANI[®] claws were bent sufficiently (C), and the KANI[®] plates covered the crossed rib edges facing inside the chest wall (D). On the fourth rib fracture (A, B, blue arrowhead) with no significant protruding rib edges, the KANI[®] plate was placed from outside the chest wall (C, D)

intercostal space. We confirmed a ruptured bulla with a small fistula at the lingula of the left upper lobe and excised it by stapling. The ventral fractures of the third to sixth ribs with major dislocation were fixed using the KANI[®] plates (53 mm in length and 18 mm in width). We minimally dissected intercostal muscles and encircled each rib to place the plates. Among these four fractures, crossed rib edges protruding towards the thoracic cavity were confirmed at the third, fifth and sixth ribs. We assumed a possibility of lung injury during a standard procedure in which the KANI[®] plates would be placed from outside the chest wall. Therefore, for these three fractures, the KANI[®] plates were placed inside chest wall, wrapping the protruding crossed rib edges, to protect the lung (Figure 2). Regarding the fourth rib with no significant protruding rib edge, the KANI[®] plate was placed in the usual manner (Figure 2). As for the other fracture sites with no major dislocation or instability, we did not perform fixation for them.

The paradoxical breathing and the air leakage disappeared soon after the surgery, and weaning from the mechanical ventilation was safely accomplished on post-operative day 6. With decrease of pleural effusion, the chest

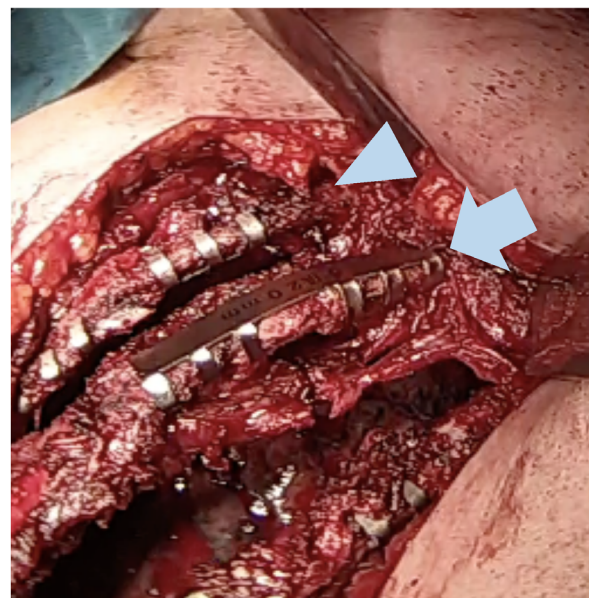

FIGURE 2 The inside-out placement of the KANI[®] plate on the third rib (arrowhead) enabled a sufficient claw bend under direct view. As for the fourth rib, the KANI[®] plate was placed in the usual manner (arrow)

tube was removed on post-operative day 9. A post-operative three-dimensional CT showed that the protruding rib edges were covered by the KANI[®] plates (Figure 1, right panels). He was transferred to another hospital for rehabilitation on post-operative day 19. Finally, he was discharged from the rehabilitation hospital 4 months after the surgery.

DISCUSSION

Surgical fixation of the flail chest can reduce mortality.^{3,4} However, the flail chest cases applicable for this modality are limited. Generally, indications for surgical rib fixation are severe instability of the thoracic cage, which prevents weaning from mechanical ventilation, and other reasons for which a thoracotomy is required (e.g., repair of organ injuries including pulmonary fistulae).⁵ In our case, the patient failed weaning from the mechanical ventilation due to the severe instability of the thoracic cage. In addition, the air leakage from the pulmonary fistula, exacerbated by the positive pressure ventilation, was considered to require surgical intervention.

The claw-type titanium plate has advantages in terms of its tolerance and fewer fixation failures than the other fixation devices.⁵ On the other hand, a fatal complication caused by the titanium plate is reported; plate claws injured the pericardium and caused a cardiac tamponade.² In this reported case, as the claws hidden behind the ribs were difficult to be bent sufficiently, the claws protruding towards the thoracic cavity caused this complication. In our case, protruding rib edges cannot be flattened by the standard procedure of KANI[®] plates; thus, we might have to excise the protruding rib edges to avoid thoracic organ injuries.

However, excising the fractured ribs would lead to further thoracic cage instability. Therefore, we placed the KANI[®] plates from inside the chest wall at the protruding fractures to cover them for protecting thoracic organs. Consequently, we were able to conserve the fractured ribs by avoiding excision. In addition, the KANI[®] claws, facing outward, could never injure the thoracic organs and were easily sufficiently bent under direct view (Figure 2).

The disadvantage of this method should be acknowledged. In our case, the dissection of the intercostal muscles, although just for the minimal length of the KANI[®] plates, was an invasive procedure for the chest wall. However, considering the short post-operative period of the weaning from the mechanical ventilation, thoracic cage stability ensured by the tight fixation using this method may make up for this disadvantage.

We propose that our new ingenuity provides a safe and tight rib fixation in rib fractures with protruding crossed rib edges which the standard method cannot flatten.

ACKNOWLEDGMENTS

We thank Mr John Martin for English proofreading of the manuscript and Mr Hirofumi Watanabe for providing information on the KANI[®] plates.

CONFLICT OF INTEREST

None declared.

AUTHOR CONTRIBUTION

Asuka Uebayashi and Yusuke Takanashi drafted the manuscript. Mikako Oka collected clinical data and revised the manuscript. Kiyomichi Mizuo, Akikazu Kawase and Kazuhito Funai commented and critically revised the drafted manuscript. All authors approved the final manuscript.

ETHICS STATEMENT

The authors declare that appropriate written informed consent was obtained for the publication of this manuscript and accompanying images.

ORCID

Asuka Uebayashi  <https://orcid.org/0000-0001-6610-6033>

Kazuhito Funai  <https://orcid.org/0000-0001-8609-3305>

REFERENCES

1. Jian X, Lei W, Yuyang P, Yongdong X. A new instrument for surgical stabilization of multiple rib fractures. *J Int Med Res.* 2020;48(2):300060519877076.
2. Ryomoto M, Sekiya N, Uemura H, Ueda D, Sato A, Yamashita K, et al. Titanium plate to fix crossed rib can cause cardiac tamponade: a cautionary note. *Gen Thorac Cardiovasc Surg.* 2021;69(2):353–5.
3. Slobogean GP, MacPherson CA, Sun T, Pelletier ME, Hameed SM. Surgical fixation vs nonoperative management of flail chest: a meta-analysis. *J Am Coll Surg.* 2013;216(2):302–11.e1.
4. Apampa AA, Ali A, Kadir B, Ahmed Z. Safety and effectiveness of surgical fixation versus non-surgical methods for the treatment of flail chest in adult populations: a systematic review and meta-analysis. *Eur J Trauma Emerg Surg.* 2021;6:1–10.
5. Simon B, Ebert J, Bokhari F, Capella J, Emhoff T, Hayward T 3rd, et al. Management of pulmonary contusion and flail chest: an Eastern Association for the Surgery of Trauma practice management guideline. *J Trauma Acute Care Surg.* 2012;73(5 Suppl 4):S351–61.

How to cite this article: Uebayashi A, Takanashi Y, Oka M, Mizuno K, Kawase A, Funai K. Placement of KANI[®] plate inside the chest wall for rib fixation: Prevention for organ injuries caused by crossed rib edges and plate claws. *Respirology Case Reports.* 2022;10:e0914. <https://doi.org/10.1002/rcr2.914>