



# Superficial temporal myofascial flap application in temporomandibular joint arthroplasty in a cat

*Journal of Feline Medicine and Surgery*  
*Open Reports*  
 1–5

© The Author(s) 2015  
 Reprints and permissions:  
[sagepub.co.uk/journalsPermissions.nav](http://sagepub.co.uk/journalsPermissions.nav)  
 DOI: 10.1177/2055116915593965  
[jfmsopenreports.com](http://jfmsopenreports.com)



Lisa A Mestrinho<sup>1</sup>, Jerzy P Gawor<sup>2</sup>, Ana M Serrano<sup>3</sup>  
 and Maria M Niza<sup>1</sup>

## Abstract

**Case summary** A 2-year-old, intact female domestic longhair cat was referred for surgical treatment after diagnosis of closed jaw locking secondarily to right temporomandibular joint ankylosis and left pseudoankylosis. The animal underwent successful surgical management with bilateral excision arthroplasty followed by interposition of a temporal superficial myofascial flap. Immediately after surgery, the full range of lower jaw movement was achieved and normal occlusion was maintained. Ankylosis did not recur in the 1 year postoperative follow-up period.

**Relevance and novel information** A temporal myofascial flap could be considered as interposition material after temporomandibular joint arthroplasty to avoid postoperative re-ankylosis and mandibular drift. The main advantages of this flap are its autogenous origin, and the ability to maintain separation between the two bones, preserve mobility and disrupt new bone formation.

**Accepted:** 9 February 2015

## Case description

Temporomandibular joint (TMJ) ankylosis can be caused by intra- or extra-articular injuries that can lead to a reduced range of movement and inability to open the mouth.<sup>1,2</sup> TMJ injuries are most frequently reported secondary to a fall or after vehicular trauma, with ankylosis observed in approximately 10% of cases.<sup>2,3</sup>

A 2-year-old, 1.4 kg, intact female domestic longhair cat was referred for evaluation owing to its inability to open its mouth. Clinical history included a tibial fracture secondary to a fall from the fifth floor 2 months previously, which was managed by internal fixation.

The owner reported that since the traumatic incident the animal was only able to eat soft food. The difficulty in eating had increased progressively and most recently the animal could only eat liquid food. During a re-evaluation by the first-opinion veterinarian, the cat's inability to open its mouth was noted. As the cat continued to lose weight, the case was referred.

General physical examination revealed cachexia and signs of dehydration. Oral examination revealed a normal occlusion, some missing teeth and an inability to open the mouth. There was no inflammation or ulceration of the gingiva, and manual opening of the mouth was not possible, even when force was applied.

The animal was hospitalised and normal hydration was re-established. Afterwards, the cat was sent to a nearby veterinary service to have computed tomography (CT) performed; intubation was impossible and during the examination oxygen was administered by nasal tube until recovery. The following day the animal was submitted to surgery. The sedation protocol included a combination of 5 µg/kg dexmedetomidine intramuscularly (IM) (Dexdomitor; Esteve Pharma) and 0.5 mg/kg morphine IM (Morfina 1%; B Braun). For induction of anaesthesia, Propofol (Propofol 1%, Lipuro; B Braun) was administered at a dose of 1 mg/kg intravenously to effect. After induction, the animal was positioned in dorsal recumbency in order for a temporary tracheostomy to be

<sup>1</sup>CIISA, Faculty of Veterinary Medicine, ULisboa, Av. da Universidade Técnica, Lisbon, Portugal

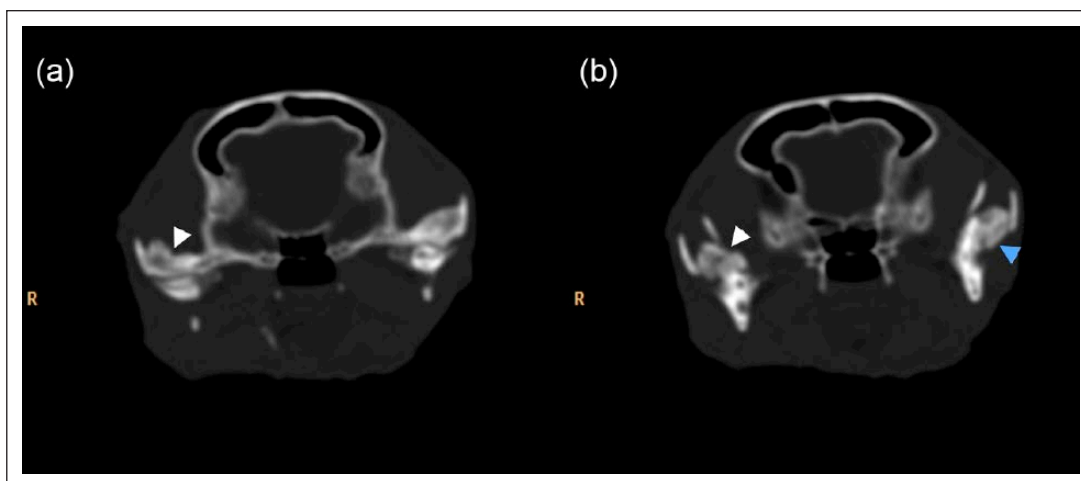
<sup>2</sup>Arka Veterinary Clinic, Krakow, Poland

<sup>3</sup>Anaid Veterinary Clinic, Lisbon, Portugal

### Corresponding author:

Lisa A Mestrinho DVM, MS, CIISA, Faculty of Veterinary Medicine, ULisboa, Avenida da Universidade Técnica, 1300-477, Lisbon, Portugal  
 Email: [lmestrinho@fmv.ulisboa.pt](mailto:lmestrinho@fmv.ulisboa.pt)





**Figure 1** (a,b) Computed tomography axial plan showing increased new bone around the right temporomandibular joint (TMJ) compatible with TMJ ankylosis (white arrows). (b) On the left TMJ there is synostosis between the coronoid process of the left mandible and the left zygomatic arch (blue arrow)

performed. General anaesthesia was maintained with isoflurane.

The maximum width of jaw opening was 3 mm, and the absence of the two maxillary canine and all the incisor teeth was noted. Head radiography showed possible involvement of both mandibles, causing ankylosis.

CT examination using a Philips Brilliance CT 16-slice (Philips Medical Systems) of the skull was performed with a 0.5 mm slice thickness. CT showed increased new bone around the right TMJ, which was compatible with TMJ ankylosis; slight new bone formation around the left TMJ; and synostosis between the coronoid process of the left mandible and the left zygomatic arch (Figure 1).

The treatment plan included right zygomatic arch osteotomy and right condylectomy, followed by pseudoankylosis excision on the left side. Once two bones were involved in the pseudoankylosis it was necessary to perform a left zygomatic arch and a coronoid process osteotomy.

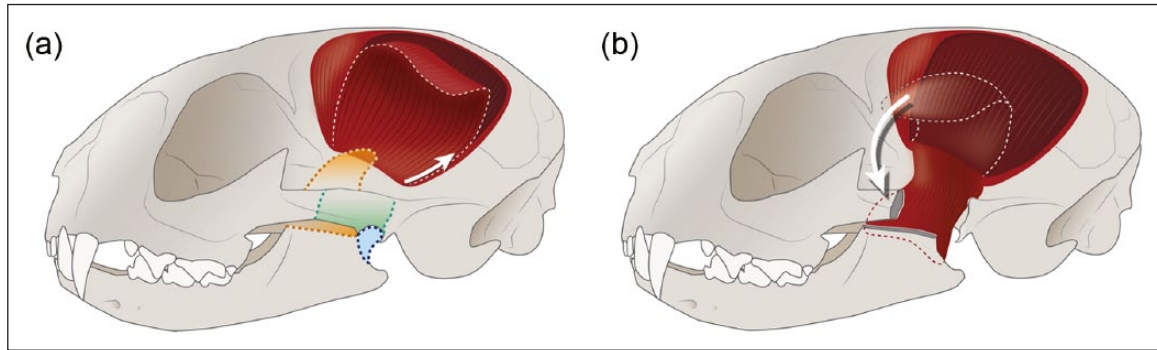
The animal was first placed in a right lateral recumbence. A 2 cm curved skin incision along the ventral border of the zygomatic arch was performed, followed by platysma muscle incision and periosteal incision of the masseter fascia. The masseter muscle was dissected and elevated from the ventral border of the zygomatic arch and the coronoid process laterally and medially. Exposure was extended as needed both at the left and right side in order to expose the limits of osteotomy. On the right side a partial osteotomy of the zygomatic arch and a condylectomy were performed, first with small perforations using a low-speed hand piece on the bone margins of the mandible and zygomatic arch. Approximately 1.5 cm of zygomatic bone was excised. After this first step, osteotomy was carefully completed using a chisel. A periosteal elevator was used to elevate the bone fragment and avoid laceration of the inferior

alveolar nerve and respective blood vessels at the ventromedial aspect of the mandibular angle. On the left side the same surgical approach was used but a total osteotomy of the zygomatic arch and of the coronoid process, which included the pseudoankylosis, was performed. Immediately after the bilateral gap arthroplasty, maximum maxillomandibular distance was achieved.

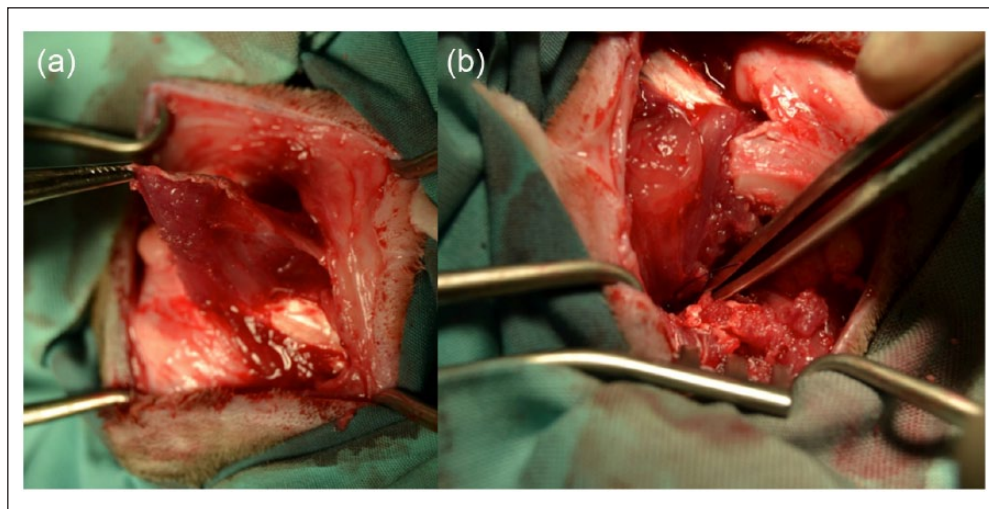
Nerve branches and vessels were identified and avoided throughout the surgery. First, the palpebral branch of the facial nerve, which can be encountered dorsally to the zygomatic arch, and the auriculopalpebral nerve, can be identified caudal to the retroarticular process. The masticatory branches of the trigeminal nerve can be found medial to the condyle, as well as the maxillary, inferior alveolar and deep temporal arteries, ventromedial to the condyle.

After osteotomy, the subcutaneous tissue was dissected dorsally in order to expose the temporal fascia and temporal muscle. The temporal artery and vein with superficial and deep branches was identified and preserved. An incision was made from the cranial ventral aspect to the dorsal aspect of the muscle and the superficial belly of the temporal muscle was dissected for transposition. After transposition the dorsal free margin of the flap was sutured on the medial aspect of the mandible at the periosteum, filling the gap that had been created. This procedure was performed bilaterally, after each osteotomy using a 4/0 glyconate suture (Figures 2 and 3). After the procedure, jaw movement was verified again and found to be without restriction or signs of crepitation; the immediate maxillomandibular distance was 35 mm.

Postoperative pain management was achieved with morphine 0.5 mg/kg q4h IM for 24 h followed by tramadol (Tramadol drops; Labesfal) 2mg/kg, PO, q 12h, for 10 days and meloxicam (Metacam; Boehringer Ingelheim) 0.05mg/kg q24h orally (PO) for 1 week. The cat was also



**Figure 2** Schematic drawing of the temporalis myofascial flap transposition. (a) Incision and elevation of the myofascial flap. Coloured areas illustrate the different osteotomies performed: blue indicates right condylectomy, orange indicates coronoid process osteotomy and green indicates zygomatic arch osteotomy, which were performed on both sides. (b) Flap repositioned. © Diogo Guerra 2015



**Figure 3** Photographs showing anterior dissection of the temporalis myofascial flap with the patient in (a) left lateral recumbency, and (b) ventral transposition and suture of the same flap with the patient in a right lateral recumbency.

given amoxicillin plus clavulanic acid (Synulox; Pfizer) 12.5 mg/kg q12h PO for 10 days.

The rehabilitation programme included daily forced manual mouth opening for 1 month, the provision of soft food every 2 h for 1 week and then a gradual return of hard food.

Two weeks after surgery, the cat was comfortable and showed functional occlusion with voluntary masticatory movements of the lower jaw. There were no signs of pain or friction on fully opening the mouth, and maxillomandibular distance was measured as 30 mm. However, bilateral facial nerve neuropraxia was observed, which gradually recovered within 3 weeks. The owners and referring veterinarian reported no signs of recurrence of mouth locking during the 1 year follow-up period (Figure 4).

## Discussion

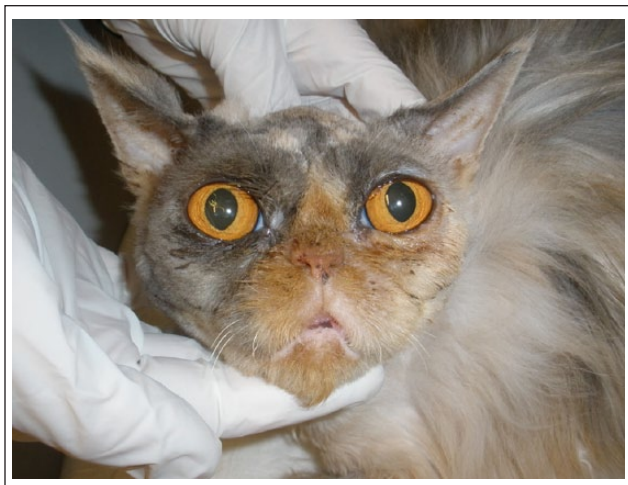True and false ankylosis can be distinguished by observing if the cause of blocking is an intra- or extra-capsular lesion, respectively.<sup>4</sup> Ankylosis can result from fibrous or

bony tissue resulting in a decreased range of motion. Although CT examination may not identify all soft tissue lesions, it is still superior to radiography in providing soft tissue information, and it has proved to be of great value in these cases.<sup>5</sup>

Excision arthroplasty is the recommended treatment for these conditions, with the elimination of ankylosed tissue.<sup>4,6</sup>

Mandibular drift and recurrence of the ankylosis have been reported after excision arthroplasty,<sup>2,7-9</sup> and a study performed in feline cadavers suggests that unilateral condylectomy causes a significant increase of laterolateral lower jaw movement, which could have an impact on occlusion.<sup>10</sup>

In this case, it was necessary to perform bilateral osteotomies: a right excision arthroplasty and a left pseudoankylosis excision. Reports of the surgical management of TMJ ankylosis in the cat, in particular with the use of bilateral surgery is, to our knowledge, uncommon in the veterinary literature. In this case, recurrence of the



**Figure 4** Postoperative appearance at 17 days

ankylosis might be expected owing to the fact that the cat underwent bilateral surgery. Additionally, there was masticatory muscle atrophy, which could eventually cause a reduced distance between the two bone fragments and therefore lead to a recurrence of the problem. Furthermore, temporal muscle atrophy presented at the time of surgery limited the flap thickness and was subsequently aggravated after the transposition.

In humans, various interposition materials (prosthetic, autogenous and alloplastic) have been reported and tested.<sup>11,12</sup> Autogenous materials used are temporal myofascial flaps, fascia lata, masseter muscle and auricular cartilage; alloplastic grafts include proplast, metallic fossa implants and acrylic marbles.<sup>11–13</sup> Prostheses are also made out of metal alloy materials with fossa and/or condyle replacement; most are custom made using stereolithographic three-dimensional models.<sup>13</sup> The objective is to maintain the gap, isolating the cut edges and preventing recurrence of ankylosis. In the present case, temporal myofascial flap was the most obvious option as it would avoid recurrence and minimise mandibular drift. The flap is easy to mobilise and transpose.

The temporal muscle occupies the temporal fossa – originating from the temporal crest – extends ventrally and inserts on the coronoid process of the mandible. It is the strongest muscle of the head in carnivores, and its tendinous branch fuses with the deep layer of the masseter muscle.<sup>14</sup> The main tributaries of this muscle originate from the caudal and rostral deep temporal artery in its deep ventral belly, where the masseter is attached, before and after the alar canal. These anatomical characteristics favour the transposition of the temporalis myofascial flap medially without disrupting vascularisation. At the same time, maintaining both partial insertion on the zygomatic process of the temporal bone and the original insertion of the deep fibres helps to preserve basal

flap vascularisation and survival of the transposed tissue. The fat content of this muscle may also help to prevent ossification and disrupt new bone formation.<sup>15</sup>

Studies of the use of temporal myofascial flaps in the cat are mostly experimental in the reconstruction of large maxillary defects;<sup>16</sup> there is one case report of the use of this procedure in one cat for the management of unilateral TMJ ankylosis.<sup>17</sup> This case also had a successful outcome, despite a longer duration of injury.

To our knowledge, this technique has never been attempted bilaterally or described in such detail. The patient tolerated this technique very well, the postoperative period proceeded without incident, and the cat experienced a quick recovery. The cat did not show pain on manipulation during the rehabilitation procedures and was eating voluntarily – soft food at first and then a regular diet. There was full recovery of lower jaw movement; maintenance of functional occlusion and mandibular occlusal forces appeared to be preserved.

Early rehabilitation after TMJ surgery is advisable by feeding small amounts of food various times a day and encouraging mouth opening by manual manoeuvres or playing with toys.<sup>5</sup> In this case, a programme of daily manual mouth opening and feeding soft food every 2 h for 1 week was used.

## Conclusions

The temporalis myofascial flap is an autogenous flap that could be considered as interposition material in the surgical management of TMJ ankylosis.

**Acknowledgements** We acknowledge Simon Orr for language correction and Panagiotis Mantis for imaging interpretation.

**Funding** Project PEst-OE/AGR/U10276/2014 (funded by FCT).

**Conflict of interest** The authors do not have any potential conflicts of interest to declare.

## References

- 1 Miller GA, Page HL and Griffith CR. **Temporomandibular joint ankylosis: review of the literature and report of two cases of bilateral involvement.** *J Oral Maxillofac Surg* 1975; 33: 792–803.
- 2 Çetinkaya MA. **Temporomandibular joint injuries and ankylosis in the cat.** *Vet Comp Orthop Traumatol* 2012; 25: 366–374.
- 3 Bonner SE, Reiter AM and Lewis JR. **Orofacial manifestations of high-rise syndrome in cats: a retrospective study of 84 cases.** *J Vet Dent* 2012; 29: 10–18.
- 4 Gatineau M, El-Warrak AO, Marretta SM, et al. **Locked jaw syndrome in dogs and cats: 37 cases (1998–2005).** *J Vet Dent* 2008; 25: 16–22.
- 5 Maas CP and Theyse LF. **Temporomandibular joint ankylosis in cats and dogs. A report of 10 cases.** *Vet Comp Orthop Traumatol* 2007; 20: 192–197.

- 6 Neomartino L, Fatone G, Brunetti A, et al. **Temporomandibular ankylosis in the cat: a review of seven cases.** *J Small Anim Pract* 1999; 40: 7–10.
- 7 Lantz GC. **Intermittent open-mouth locking of the temporomandibular joint in a cat.** *J Am Vet Med Assoc* 1987; 190: 1574
- 8 Eisner ER. **Bilateral mandibular condylectomy in a cat.** *J Vet Dent* 1995; 12: 23–26.
- 9 Okumura M, Kadosawa T and Fujinaga T. **Surgical correction of temporomandibular joint ankylosis in two cats.** *Aust Vet J* 1999; 77: 24–27.
- 10 El-Warrak AO, Ferrer GA, Lanthier T, et al. **Temporomandibular joint condylectomy and its effect over occlusion in cats: cadaveric study.** *J Small Anim Pract* 2011; 52: 158–162.
- 11 Su-Gwan K. **Treatment of temporomandibular joint ankylosis with temporalis muscle and fascia flap.** *Int J Oral Maxillofac Surg* 2001; 30: 189–193.
- 12 He D, Yang C, Chen M, et al. **Surgical treatment of traumatic temporomandibular joint ankylosis with medially displaced residual condyle: surgical methods and long term results.** *J Oral Maxillofac Surg* 2011; 69: 2412–2418.
- 13 Wolford LM and Karras SC. **Autologous fat transplantation around temporomandibular joint total joint prosthesis: preliminary treatment outcomes.** *J Oral Maxillofac Surg* 1997; 55: 245–251.
- 14 Liebich HG, Maierl J and Konig HE. **Fasciae and muscles of the head, neck and trunk.** In: Konig HE and Liebich HG (eds). *Veterinary anatomy of domestic animals*. 3rd ed. Munich: Schattauer, 2007, pp 115–123.
- 15 Driemel O, Braun S, Muller-Richter UD, et al. **Historical development of alloplastic temporomandibular joint replacement after 1945 and state of the art.** *Int J Oral Maxillofac Surg* 2009; 38: 909–920.
- 16 Cheung LK. **An animal model for maxillary reconstruction using a temporalis muscle flap.** *J Oral Maxillofac Surg* 1996; 54: 1439–1445.
- 17 Heo SY, Lee HB, Lee KC, et al. **Reconstruction of the temporomandibular joint ankylosis with temporalis myofascial flap in a cat: a case report.** *Vet Med* 2008; 53: 277–281.