

Case Report

# A Change of Heart: Yield of Cardiac Imaging in Acute Stroke Workup

Frans Kauw<sup>a</sup> Jan W. Dankbaar<sup>a</sup> Jesse Habets<sup>a</sup> Maarten J.M. Cramer<sup>b</sup>  
Hugo W.A.M. de Jong<sup>a</sup> Birgitta K. Velthuis<sup>a</sup> L. Jaap Kappelle<sup>c</sup>

<sup>a</sup>Department of Radiology, University Medical Center Utrecht, University of Utrecht, Utrecht, The Netherlands; <sup>b</sup>Department of Cardiology, University Medical Center Utrecht, University of Utrecht, Utrecht, The Netherlands; <sup>c</sup>Brain Center Rudolf Magnus, Department of Neurology and Neurosurgery, University Medical Center Utrecht, University of Utrecht, Utrecht, The Netherlands

## Keywords

Ischemic stroke · Computed tomography angiography · Dual-energy computed tomography · Recurrent stroke · Cardioembolic stroke · Acute stroke imaging

## Abstract

This case report describes a patient who experienced a recurrent ischemic stroke within 24 h. Dual-energy computed tomography (DECT) angiography on admission showed 2 intracardiac thrombi, 1 in the left ventricle and 1 in the left atrial appendage. Following the second ischemic event, repeated DECT angiography showed that the ventricular thrombus had considerably diminished, suggesting that the recurrent brain infarction was caused by cardioembolism. This case emphasizes (1) the potential benefit of cardiac evaluation through CT angiography in the acute stroke setting, and (2) the use of DECT angiography for the detection of thrombus and the differentiation between thrombus, the myocardial wall, and a slow flow of contrast.

© 2018 The Author(s)  
Published by S. Karger AG, Basel

## Background

Patients with a recent ischemic stroke are at risk for recurrence [1]. In 20–30% of all cases, an ischemic stroke is caused by cardioembolism [2]. Dysfunction of the atria or ventricles of the heart may cause blood stasis, which may lead to the formation of a thrombus. To prevent subsequent cardioembolic arterial occlusion in the brain, treatment with anticoagulants should be promptly considered in patients with an impaired mechanical function of the heart or atrial fibrillation (AF) [3, 4].

In current clinical practice, stroke patients are monitored by electrocardiography (ECG) for the presence of AF. Transthoracic echocardiography (TTE) or transesophageal echocardiography may be necessary in individual patients to check for the presence of intracardiac thrombus. Excluding thrombus in the left atrial appendage (LAA), with a complex anatomy, is particularly difficult on TTE [5]. The detection of intracardiac thrombus may be improved by visualizing the heart at the first presentation of stroke patients. It has been suggested to perform cardiac CT angiography (CTA) instead of echocardiography in addition to stroke imaging protocols [6, 7]. Dual-energy CT (DECT) can detect intracardiac thrombus and is considered better than conventional CT because of its superior tissue contrast. This improves the differentiation between thrombus, the myocardial wall, and areas with little contrast material such as the LAA [8].

In the University Medical Center Utrecht, the Netherlands, non-ECG-gated DECT angiography that covers the base of the heart up to the crown of the head is routinely performed in patients with an acute stroke. To show the potential importance of this new technique in the acute stroke setting, we describe a patient with 2 intracardiac thrombi who had a recurrent ischemic stroke within 1 day after admission.

## Case Description

A 76-year-old male was transferred to the emergency department after he had been found sitting in the garden with impaired speech and weakness of his left extremities. The patient was last seen well almost 4 h before his friends found him. Relevant past medical history included ischemic cardiomyopathy (left ventricular ejection fraction 30%), AF, pacemaker implantation, and chronic obstructive pulmonary disease. Medication included acenocoumarol, digoxin, antihypertensive medication, and a statin. Neurological examination showed dysarthria, left-sided hemianopia, left-sided facial palsy, and paralysis of the left extremities. ECG showed AF with a ventricular paced rhythm. The international normalized ratio was 1.4. A non-contrast head CT (IQon Spectral CT; Philips Healthcare, Cleveland, OH, USA) showed a hyperdense vessel sign of the right middle cerebral artery (MCA) and early signs of ischemic stroke (Fig. 1a). CTA, from head to heart, and CT perfusion showed an occlusion of the proximal right MCA with a large perfusion deficit in the MCA flow territory (Fig. 1b, c). Two intracardiac thrombi were visible on CTA, 1 in the left ventricle and 1 in the LAA (Fig. 2a–c). The visibility of the left ventricular thrombus was improved by using the iodine setting and low keV monoenergetic reconstructions of the DECT angiography. Atherosclerotic plaques were found in both internal carotid arteries, but there was no significant stenosis. The patient received intravenous rt-PA followed by endovascular treatment. Successful recanalization of the MCA was achieved at first pass using a penumbra suction system 1 h after presentation to the emergency room.

A few hours after endovascular treatment, consciousness of the patient deteriorated, and he developed respiratory failure. A repeated non-contrast head CT excluded cerebral hemorrhage, and thoracic CT excluded pneumonia or pneumothorax. TTE was inconclusive due to limited acoustic windows caused by chronic obstructive pulmonary disease.

One day later, at wake up in the following morning, the neurological examination showed a quadriplegia. A repeated stroke protocol CT showed a new hypodensity and perfusion deficit in the left hemisphere (Fig. 1d–f). On DECT angiography, the thrombus in the left ventricle of the heart was clearly reduced in size. The thrombus in the LAA was unaltered in size compared to admission DECT angiography (Fig. 2c–d). No arterial occlusion could be found on DECT angiography. No therapeutic options remained, and the patient died the same day. Autopsy was not permitted.

## Discussion

This case report describes an acute ischemic stroke patient with an MCA occlusion and 2 intracardiac thrombi as possible culprits on DECT angiography, 1 in the left ventricle and 1 in the LAA. Repeated imaging after early recurrence of ischemic stroke demonstrated a diminished left ventricular thrombus. The culprit was thereby identified.

Evidence on the presence of an intracardiac thrombus and the risk of recurrent ischemic stroke is scarce. Only 1 study investigated the relation between the presence of intracardiac thrombus and stroke recurrence prospectively, but no association was found [9]. However, the number of outcome events was low, the study was performed in a selected population, and the follow-up duration was limited.

In our case, a bilateral hemispheric stroke without significant carotid artery disease or dissection makes a cardioembolic source of the occlusion likely. The left ventricular thrombus was probably caused by myocardial wall motion abnormalities after previous myocardial infarction resulting in local blood stasis. The LAA thrombus was probably caused by blood stasis during the presence of AF. To detect an intracardiac thrombus, ECG-triggered cardiac CTA has been shown to be of comparable diagnostic value when compared to transesophageal echocardiography [7, 10]. However, the specificity of ECG-triggered cardiac CTA for detecting thrombus in the LAA is limited, because hypoattenuation in the LAA may reflect a slow blood flow in that area, which mimics the presence of thrombus. Slow-flow artifacts in areas such as the LAA can be avoided by giving a prebolus of contrast. In our stroke workup, the first bolus of contrast for the CT perfusion provided this precontrast. The accuracy of differentiating intracardiac thrombus from blood stasis can further be raised by using DECT angiography with split energy layers instead of conventional CTA [11]. In our case, the thrombi were best visible on the 40 keV images compared to the 120 kV images, and showed no iodine uptake on the iodine map, demonstrating the value of DECT with dual-layer detector.

DECT is a technique that gathers additional information through analysis of both high- and low-energy levels. This specific CT application has gained interest in the last decade, as it may improve the detection and differentiation of tissue types throughout the body [12, 13]. There are several methods of acquiring dual-energy data as well as depicting the iodine content in maps. Currently, 3 different CT types with dual-energy data can be used in the clinic: (1) dual-source DECT that has two X-ray tubes at different kV settings projecting on the corresponding 2 detectors, (2) single-source DECT projects that can rapidly switch between 2 kV settings on 1 detector, and (3) dual-layer detector CT that has 1 source and a single double-

layered detector, which enables differentiation between high- and low-energy levels. The advantage of DECT with dual-layer detector, which was used in our institution, is that the dual-energy information is always available and not only in predefined specific protocols as is the case in the other methods.

With the high speed of current CT scanners, cardiac CT can be implemented into the acute stroke imaging protocol without delaying the acute stroke workup [6]. However, there may be exposure to an additional low dose of radiation when a separate ECG-triggered cardiac CTA is added to the stroke imaging protocol. DECT using the dual-layer detector method can keep the radiation dose stable as the low kV data can be used to improve the contrast image quality and enable cardiac thrombus detection without ECG triggering. We think that the diagnostic yield of cardiac CTA and the clinical relevance outweighs the possible additional low dose of radiation for the patient.

### Conclusion

This case emphasizes the potential benefit of (1) cardiac evaluation through CTA in the acute stroke setting and (2) the use of DECT angiography for the detection of thrombus and for differentiating between thrombus, the myocardial wall, and a slow flow of contrast. Larger studies should demonstrate whether the implementation of cardiac DECT angiography into acute stroke imaging protocols is beneficial.

### Statement of Ethics

The need for informed consent was waived following the ethical guidelines and regulations.

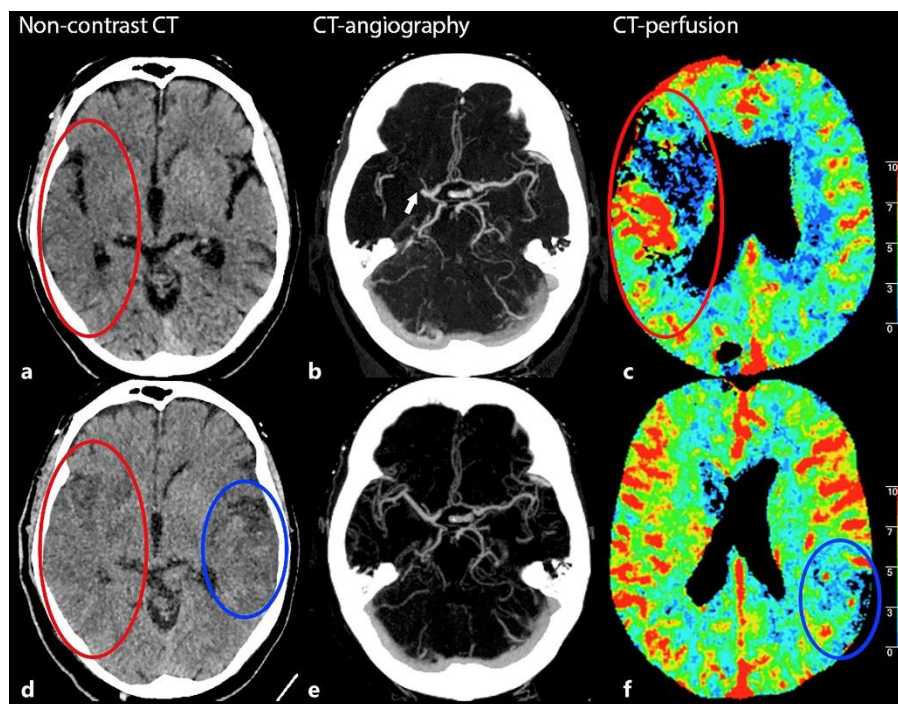
### Disclosure Statement

The authors declare that there are no conflicts of interest to disclose.

### References

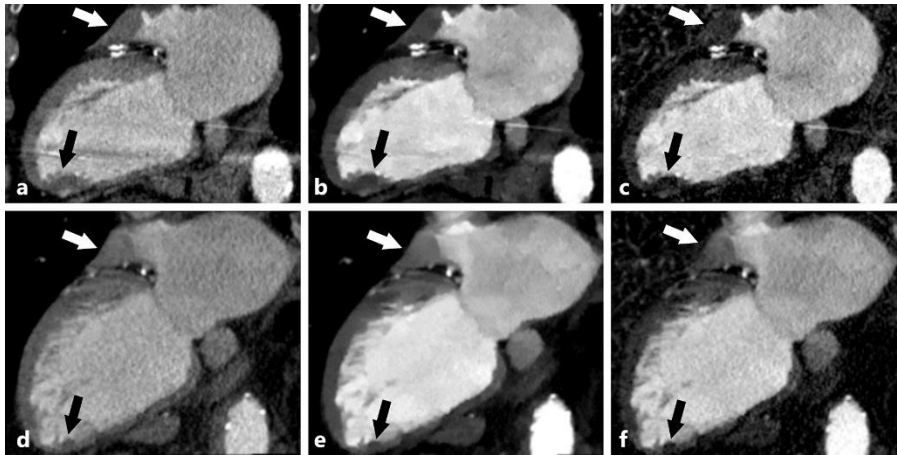
- 1 Benjamin EJ, Blaha MJ, Chiuve SE, Cushman M, Das SR, Deo R et al. American Heart Association Statistics Committee and Stroke Statistics Subcommittee. Heart Disease and Stroke Statistics-2017 Update: A Report From the American Heart Association. *Circulation*. 2017 Mar;135(10):e146–603.
- 2 Ferro JM. Cardioembolic stroke: an update. *Lancet Neurol*. 2003 Mar;2(3):177–88.
- 3 Zeitler EP, Eapen ZJ. Anticoagulation in Heart Failure: a Review. *J Atr Fibrillation*. 2015 May;8(1):31–8.
- 4 Lip GY, Nieuwlaat R, Pisters R, Lane DA, Crijns HJ. Refining clinical risk stratification for predicting stroke and thromboembolism in atrial fibrillation using a novel risk factor-based approach: the euro heart survey on atrial fibrillation. *Chest*. 2010 Feb;137(2):263–72.
- 5 Shrestha NK, Moreno FL, Narciso FV, Torres L, Calleja HB. Two-dimensional echocardiographic diagnosis of left-atrial thrombus in rheumatic heart disease. A clinicopathologic study. *Circulation*. 1983 Feb;67(2):341–7.
- 6 Furtado AD, Adraktas DD, Brasic N, Cheng SC, Ordovas K, Smith WS et al. The triple rule-out for acute ischemic stroke: imaging the brain, carotid arteries, aorta, and heart. *AJNR Am J Neuroradiol*. 2010 Aug;31(7):1290–6.
- 7 Hur J, Kim YJ, Lee HJ, Ha JW, Heo JH, Choi EY et al. Cardiac computed tomographic angiography for detection of cardiac sources of embolism in stroke patients. *Stroke*. 2009 Jun;40(6):2073–8.

- 8 Hur J, Kim YJ, Lee HJ, Nam JE, Ha JW, Heo JH et al. Dual-enhanced cardiac CT for detection of left atrial appendage thrombus in patients with stroke: a prospective comparison study with transesophageal echocardiography. *Stroke*. 2011 Sep;42(9):2471–7.
- 9 Lee K, Hur J, Hong SR, Suh YJ, Im DJ, Kim YJ et al. Predictors of Recurrent Stroke in Patients with Ischemic Stroke: Comparison Study between Transesophageal Echocardiography and Cardiac CT. *Radiology*. 2015 Aug;276(2):381–9.
- 10 Teunissen C, Habets J, Velthuis BK, Cramer MJ, Loh P. Double-contrast, single-phase computed tomography angiography for ruling out left atrial appendage thrombus prior to atrial fibrillation ablation. *Int J Cardiovasc Imaging*. 2017 Jan;33(1):121–8.
- 11 Hur J, Kim YJ, Lee HJ, Nam JE, Hong YJ, Kim HY et al. Cardioembolic stroke: dual-energy cardiac CT for differentiation of left atrial appendage thrombus and circulatory stasis. *Radiology*. 2012 Jun;263(3):688–95.
- 12 Sun YS, Zhang XY, Cui Y, Tang L, Li XT, Chen Y et al. Spectral CT imaging as a new quantitative tool? Assessment of perfusion defects of pulmonary parenchyma in patients with lung cancer. *Chin J Cancer Res*. 2013 Dec;25(6):722–8.
- 13 Graser A, Johnson TR, Chandarana H, Macari M. Dual energy CT: preliminary observations and potential clinical applications in the abdomen. *Eur Radiol*. 2009 Jan;19(1):13–23.



**Fig. 1.** Head computed tomography (CT) images of the patient at admission and at follow-up. Top row with admission imaging of **a** non-contrast CT with early signs of ischemic stroke (red oval), **b** CT angiography (CTA) with occlusion (white arrow) of the proximal middle cerebral artery, **c** and CT perfusion (CTP) showing perfusion deficit in the territory of the right middle cerebral artery (red oval). Bottom row with follow-up imaging of **d** non-contrast CT with ischemic alterations in both hemispheres (red and blue ovals), **e** follow-up CTA without a visible occlusion, **f** and CTP showing a new perfusion deficit in the left parietal region (blue oval).





**Fig. 2.** Cardiac dual-energy computed tomography (CT) angiography images of the patient at admission and at follow-up. CTA with a two-chamber view of the left ventricle at admission (top row) and follow-up after stroke recurrence (bottom row). Admission CTA with **a** conventional (120 kV), **b** 40 keV, and **c** iodine setting showing 2 thrombi, 1 in the left atrial appendage (white arrow) and 1 in the left ventricle (black arrow). Follow-up CTA with **d** conventional (120 kV), **e** 40 keV, and **f** iodine setting showing diminution of the ventricular thrombus (black arrow) and the unaltered left atrial appendage thrombus (white arrow).