

High-efficiency Combination Treatment of Submental Neck Fullness

Carl K.L. Cheng, MD

Background: Fat accumulation, skin laxity, and muscle contraction cause aging cervical fullness. Combining botulinum toxin to treat muscle contraction, and technique-oriented microfocused ultrasound for skin laxity, can improve cervical fullness without requiring lipolysis. Gel-assisted depth adjustment (GADA) is a depth-targeting, image-guided approach using an appropriate gel volume to precisely heat tissue layers during real-time visualization.

Methods: A 41-year-old woman presented with moderate submental neck fullness and saggy cheeks. An appropriate gel volume was applied as determined by the targeted tissue layer's distance from the skin. The submental and submandibular areas received 112 lines of 0.9 J/cm² microfocused ultrasound with visualization (MFU-V) from a 4.5-mm transducer and 0.3 J/cm² from a 3-mm transducer to treat the SMAS and dermosubcutis, respectively. For concomitant jowling, these transducers delivered 111 MFU-V lines to the lower cheek. Six units of incobotulinumtoxinA was injected in 1 point at the mandible to modulate hyperactive mentalis muscles. The platysma received 10U of incobotulinumtoxinA per cheek, whereas downturned mouth corners received 4U of incobotulinumtoxinA.

Results: One-month posttreatment, submentum improvements included changes of the vertical pogonion position, more mandible angularity, and a straighter mandibular line. Anterior chin projection was more pronounced and the pogonion had more inferior displacement, creating a younger appearance in the chin-neck complex. Patients followed-up for 3 months also demonstrated these changes.

Conclusions: Delivering MFU-V using the GADA technique effectively tightens submental and submandibular soft tissues. When combined with incobotulinumtoxinA, muscles in the chin and perioral area are relaxed. Thus, GADA yields significant clinical improvement and patient satisfaction. (*Plast Reconstr Surg Glob Open* 2019;7:e2306; doi: 10.1097/GOX.0000000000002306; Published online 25 July 2019.)

INTRODUCTION

Cervical aging develops due to fat accumulation, soft tissue laxity, mandible aging, and perioral and neck muscle hyperactivity. Excessive submental fat distorts the anterior cervicomental triangle,¹ causing skin sagging,² double

chins, or an aged appearance.³ Patients often request neck contouring and rejuvenation for submental fullness or jowling and skin laxity,⁴ and to improve cervical-facial curves. We have combined botulinum toxin injections with the Gel-assisted depth adjustment (GADA) method, which uses microfocused ultrasound to create a personalized, minimally invasive, and image-guided treatment for laxated submental skin. This causes less downtime and fewer side effects,⁵⁻⁷ as ultrasound energy is delivered only to the intended tissue layer identified during real-time visualization. In GADA, gel is applied in a quantity dependent on the target layer's distance from the skin surface, thus customizing the distance between the transducer and the target tissue plane, especially at the dermis-subcutis junction.

From the Haute Beauté Skin Clinic and The Bundles Skin Clinic, Taipei, Taiwan.

Received for publication January 20, 2019; accepted April 26, 2019.

Presented at the 17th Aesthetic & Anti-Aging Medicine World Congress, Taipei (AMWC Asia May 4-6, 2018) and 12th International Master Course on Aging Science Asia, Bangkok (IMCAS Asia July 13-15, 2018).

Copyright © 2019 The Author. Published by Wolters Kluwer Health, Inc. on behalf of The American Society of Plastic Surgeons. This is an open-access article distributed under the terms of the Creative Commons Attribution-Non Commercial-No Derivatives License 4.0 (CCBY-NC-ND), where it is permissible to download and share the work provided it is properly cited. The work cannot be changed in any way or used commercially without permission from the journal.

DOI: 10.1097/GOX.0000000000002306

Disclosure: Dr. Cheng received an honorarium from Merz to conduct the study and Merz sponsored all products used in the study. Editorial assistance, funded by Merz Asia Pacific Pte. Ltd. (Taiwan Branch), was provided by Shawna Tan. The preparation of this manuscript was sponsored by Merz Asia Pacific.

CASE PRESENTATION

Patient Selection and Evaluation

A 41-year-old female patient presented with mild-to-moderate submental neck fullness, saggy cheeks, fine wrinkles, and chin dimpling. Cephalometric analysis was performed pre- and postinjection, and the pogonion's vertical position relative to the Frankfort horizontal line was measured from photographs using Adobe Photoshop (Adobe Systems Inc. v19.1.6, San Jose, Calif.). Submental and jaw lines were graded as level 0: mandibular line disappearance and appearance of fat accumulation with bulge; level 1: mandibular line disappearance with fat accumulation, submental convexity, and uneven contour; level 2: mandibular line disappearance with fat accumulation, more submental convexity, and irregular contours; level 3: focal interruption of straight mandibular lines, and convexity disrupting the sharp mandibular angle; and level 4: distinct, straight mandibular line with sharp cervicomental angle. Changes to the cervicomental and mandibular lines were photographed with the patient resting and pouting.

Treatment Procedure and Assessment

Topical anesthetic (SINCAINE Cream 5%, Sinphar Pharmaceutical Co., Ltd, Taiwan) was administered to 2 target neck areas, 45–60 minutes preprocedure. First, the submental and submandibular areas above the thyroid cartilage received a total of 112 lines of microfocused ultrasound with visualization (MFU-V) at 0.9 J/cm² (Ultherapy, Merz, Germany GmbH) with the 4.5-mm transducer, and 0.3 J/cm² with the 3-mm transducer to heat and induce neocollagenesis and ne elastogenesis in the dual planes of the SMAS and dermo-subcutis.⁸ For concomitant jowling, these transducers delivered 111 MFU-V lines to the lower cheek area below the mouth-ear tragus line. A 27-gauge needle delivered 6U of incobotulinumtoxinA (Xeomin, Merz Pharmaceuticals GmbH) in 1 injection point, at the lower middle mandible, to modulate hyperactive mentalis muscles. The platysma received 10U of incobotulinumtoxinA, using the Nefertiti technique, in 5 points per cheek, above the mandibular line and 1

finger's width lateral to the marionette line but medial to the mandibular angle. Downturned mouth corners received 4U of incobotulinumtoxinA at 2 points in both depressor anguli oris. Immediately postprocedure, the patient returned to normal activities, but avoided hot tubs and spas for 1 week. Some redness, swelling, and tenderness occurred but resolved without treatment within a week.

Photographs of the patient's cervicomental and mandibular lines at rest were taken preprocedure, 1-week and 1–3 months postprocedure, and qualitatively scored by the author. Changes in vertical position were measured and scored.

RESULTS

One-month posttreatment (Fig. 1, left), the submentum improved from level 2 to 4 with vertical position changes (ΔB , 2.99 mm). At rest, the submental and jawline improved by 2 levels. The previously accumulated subcutaneous fat had improved with more mandible angularity and a straighter mandibular line. Anterior chin projection was more pronounced and the pogonion had more inferior displacement, creating a younger appearance and more aesthetically pleasing chin-neck complex. At longer terms, other patients also demonstrated these changes.

DISCUSSION

The GADA approach customizes the quantity of ultrasound gel to skin thickness—thinner dermis receives thicker gel layers, whereas thicker dermosubcutis receives a thinner layer. Cervical fullness with mild-to-moderate fat accumulation concomitant with skin laxity benefits most from this. The amount of fat deposition is assessed by pinching the submentum with the index finger and thumb and instructing patients to swallow. Ideal patients are those where fat withdrawal is felt between the fingers, as fat had accumulated within or below the platysma muscles. Otherwise, lipolysis was recommended. The GADA technique is applicable to Asians and Whites, because the number of lines delivered is deter-

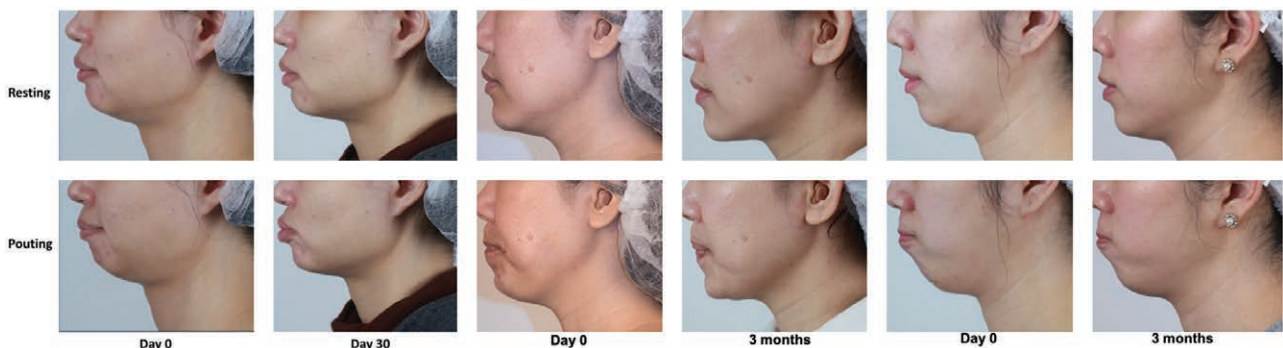


Fig. 1. Treatment of submental and submandibular fullness with MFU-V and incobotulinumtoxinA. Patients received 112 MFU-V lines with a 4.5-mm transducer, 111 MFU-V lines with a 3.0-mm transducer, and 26U of incobotulinumtoxinA. Left, 30 days posttreatment, the submental area improved to level 4, whereas the jawline had improved to level 3. Patients before and 3 months posttreatment, both reaching level 4 from level 2 (Middle) and level 1 (Right).

mined by the combined consequence of skin laxity and adiposity, not genetic background. No adverse events occurred other than those known to arise after MFU-V treatment. This in-treatment real-time visualization ensures that the appropriate quantity of gel is coupled to the transducer and precisely adjusts heating depths to achieve maximal tissue coagulation density. Muscles associated with pouting, including the mentalis, platysma, and depressor anguli oris, also exacerbate submental fullness and downturned mouth corners. This patient received incobotulinumtoxinA in multiple target areas to reduce hyperactivity of muscles associated with pouting, and when incobotulinumtoxinA is combined with energy-based modalities (MFU-V without lipolysis), lax neck skin is tightened while simultaneously improving both submental fullness and jowling within a single treatment session. Fifteen patients have now received the GADA procedure, with 140–180 MFU-V lines delivered to the submental and submandibular neck area, and/or if jowling is observed, 80–100 lines delivered to the lower mandibular area. Hyperactive mentalis muscles and the submandibular platysma also received incobotulinumtoxinA (4–12U and 20–28U, respectively, per treatment). Hyaluronic acid or calcium hydroxylapatite fillers can further augment and improve retruded chins, with hypoplastic mandibles of any severity, and subsequently produce jawline definition. Submental fullness and jowling improved in 12 patients as soon as 1-week posttoxin, with improvements continuing even at 1–3 months posttreatment when collagenesis enhances submental skin tightening. In future studies, it would be instructive to repeat these treatments on separate patient cohorts receiving either neuromodulator, MFU-V, or both as combination therapy. In the etiology of mild-to-moderate submental fullness and jowling, combining toxin with MFU-V without lipolysis synergistically addresses skin laxity and hyperactivity of muscles associated with pouting, without destroying fat formation.

CONCLUSIONS

Delivering MFU-V treatment using this innovative GADA technique effectively tightens submental and submandibular soft tissue. When combined with incobotulinumtoxinA, muscles in the chin and those responsible for pouting are also effectively suppressed. Thus, this simple, combined treatment strategy yields significant clinical improvement and patient satisfaction, without any of the risks associated with traditional neck-lifting surgery.

Carl K.L. Cheng, MD

2F, No. 291, Sec 5

Jhong Xiao East Rd

Taipei, Taiwan

E-mail: dermacarl@hotmail.com

REFERENCES

1. Raveendran SS, Anthony DJ, Ion L. An anatomic basis for volumetric evaluation of the neck. *Aesthet Surg J*. 2012;32:685–691.
2. Suh DH, Park JH, Jung HK, et al. Cryolipolysis for submental fat reduction in Asians. *J Cosmet Laser Ther*. 2018;20:24–27.
3. Lipner SR. Cryolipolysis for the treatment of submental fat: review of the literature. *J Cosmet Dermatol*. 2018;17:145–151.
4. Park JH, Kim JI, Park HJ, et al. Evaluation of safety and efficacy of noninvasive radiofrequency technology for submental rejuvenation. *Lasers Med Sci*. 2016;31:1599–1605.
5. Wu WT, Liew S, Chan HH, et al; Asian Facial Aesthetics Expert Consensus Group. Consensus on current injectable treatment strategies in the Asian face. *Aesthetic Plast Surg*. 2016;40:202–214.
6. Anand C. Facial contouring with fillers, neuromodulators, and lipolysis to achieve a natural look in patients with facial fullness. *J Drugs Dermatol*. 2016;15:1536–1542.
7. Chao YYY, Chhabra C, Corduff N, et al. PAN-ASIAN CONSENSUS-key recommendations for adapting the World Congress of Dermatology Consensus on combination treatment with injectable fillers, toxins, and ultrasound devices in Asian patients. *J Clin Aesthet Dermatol*. 2017;10:16–27.
8. Jeon H, Kim T, Kim H, et al. Multimodal approach for treating horizontal neck wrinkles using intensity focused ultrasound, cohesive polydensified matrix hyaluronic acid, and incobotulinumtoxinA. *Dermatol Surg*. 2018;44:421–431.